

Hemimasticatory Spasm Secondary to Biopercular Syndrome

Félix Javier Jiménez-Jiménez^a Inmaculada Puertas^a Hortensia Alonso-Navarro^b

^a Departamento de Medicina-Neurología, Hospital Príncipe de Asturias, Universidad de Alcalá, Alcalá de Henares, y

^b Sección de Neurología, Hospital Virgen de la Concha, Zamora, España

Hemimasticatory spasm (HMS) is an infrequent condition that consists of involuntary sustained unilateral contractions of masticatory muscles. After the first description by Gowers in 1897 as 'masticatory spasm' [1], at least 19 additional cases of HMS have been reported (table 1) [2–17], some of them associated with facial hemiatrophy [2, 3, 6, 7, 9, 11–13].

The characteristic electromyographic (EMG) findings of HMS are irregular bursts of motor unit potentials lasting from seconds to minutes, which correlate clinically with the involuntary twitches or spasms of the masticatory muscles [4, 10, 13]. Involuntary spasms are selectively confined to the masseter, temporalis and, occasionally, medial pterygoid muscles.

The pathophysiology of HMS is not well known. Some authors suggested a close similarity with hemifacial spasm [2, 5] and proposed that the spontaneous activity was generated in the trigeminal nerve fibers [2, 4]. On the other hand, other authors suggested the central nervous system, sympathetic ganglia or muscle dysfunction [3, 7]. Some reports support the trigeminal nerve dysfunction hypothesis, by which ectopic activity of motor fibers of the trigeminal nerve should cause decreased motor nerve conduction of the

affected nerve, increased latency or absence of the masticatory reflex and absence of the silent period of the masseter reflex during spasms [10, 13, 14, 17].

We report a patient who showed a typical HMS of 4.5 years of evolution, which had developed 6 months after a biopercular syndrome.

Case Report

A 45-year-old male patient was evaluated because of involuntary spasms in his right masseter muscle. Five years before, following an acute respiratory insufficiency which required endotracheal intubation, he had presented with dysarthria, bilateral (predominantly right) supranuclear facial and hypoglossal palsy, and inability to achieve tongue protrusion, difficulty in chewing and bilateral dystonia of the hands. At that time, the case of this patient was published because of the presence of bilateral asymmetrical hand dystonia associated with bilateral opercular lesions (Foix-Marie-Chavany syndrome) [18]; he did not have HMS and was lost to follow-up. Six months after the first admission to hospital (4.5 years before the new evaluation), he developed a progressive clinical picture of sustained involun-

tary contractions of the right masticatory muscles. Needle electromyography of the right temporal and masseter muscles showed no abnormal spontaneous activity during the resting state, and the activation and recruitment patterns of motor units were normal. However, during periods of involuntary spasms, the right temporalis and masseter muscles showed bursts of motor potential units at high frequencies. Needle electromyography of the left temporalis and masseter muscles showed no abnormalities. Blink reflexes, obtained by electrical stimulation of the supraorbital nerve on each side, were of normal latency and symmetrical on both the unaffected and affected sides. Masseter inhibitory reflexes, evoked by electrical stimulation of the mental nerves, showed normal values of the latencies and duration of the silent periods SP1 (monosynaptic) and SP2 (multisynaptic) on both the unaffected and affected sides. T₂- and FLAIR-weighted images in brain MRI showed hyperintense lesions in both parietal opercula (fig. 1a–c), and a ⁹⁹Tc-HMPAO SPECT showed reduced captation of the tracer in both parietal regions (fig. 2). The patient received local injection of botulinum toxin type A (Botox), 30 IU in the right masseter and temporalis muscles, with slight improvement, and was again lost to follow-up.

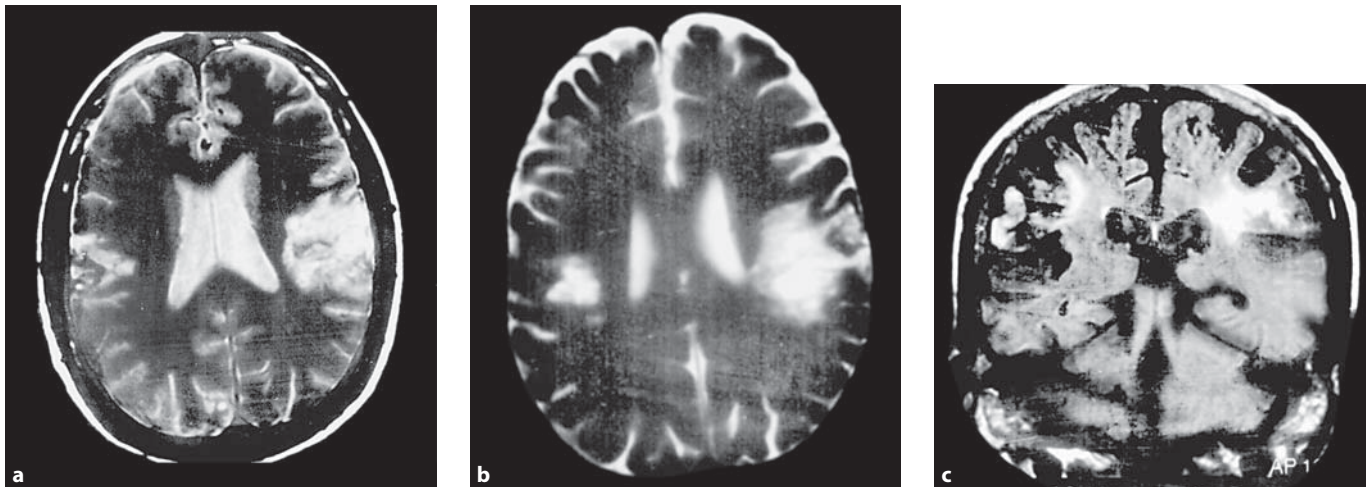


Fig. 1. T₂- (a, b) and FLAIR-weighted images (c) in brain MRI showing hyperintense lesions in both parietal opercula (taken from Puertas et al. [18], with permission of Viguera Editores, *Revista de Neurología*).

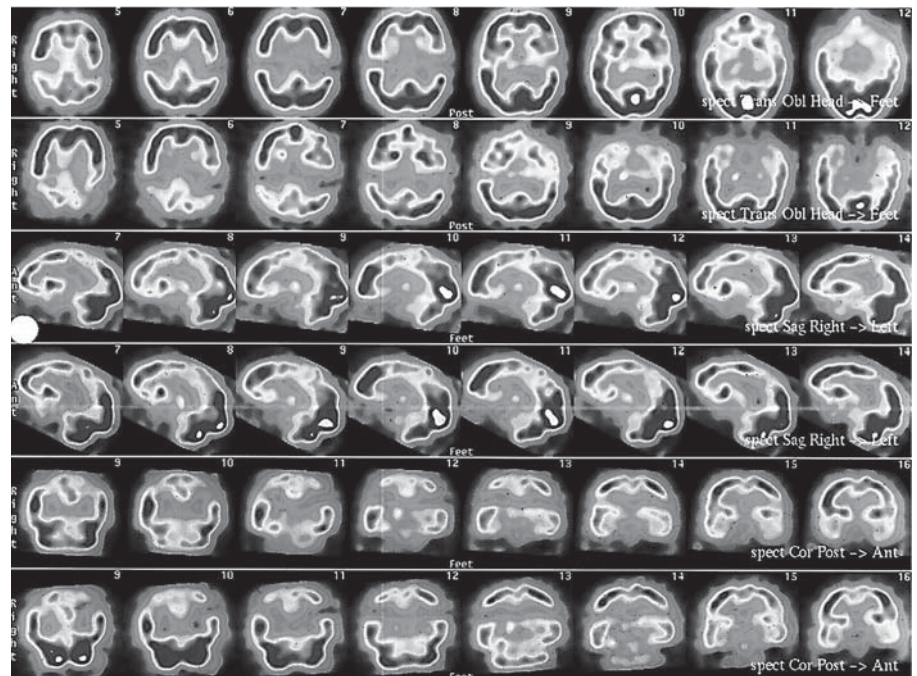


Fig. 2. ⁹⁹Tc-HMPAO SPECT showing reduced captation of the tracer in both parietal regions (taken from Puertas et al. [18], with permission of Viguera Editores, *Revista de Neurología*).

Discussion

The patient reported here showed typical clinical and EMG findings of HMS. However, he presented with 3 interesting features: (a) the latencies of the masseter inhibitory reflex were normal; (b) the clinical course of the HMS was progressive and started 6 months after an acute hypoxic-ischemic insult which caused biopercular lesions, and (c) previously, this patient

had developed acute bilateral hand dystonia.

Mastication is achieved by cooperation between facial, masticatory and lingual muscles [19]. According to anatomical findings and functional animal studies, the orofacial area is related with both hemispheres. Studies performed with rabbits have shown that after bilateral cortical masticatory area (CMA) ablation, the animal cannot manipulate food placed in the

front of the mouth for several days, with a following partial recovery [20], while repetitive stimulation of the CMA (which has projections to the ventral region of the putamen) elicits rhythmic jaw movements [21, 22]. While cats with unilateral lesion of the CMA showed no changes in mastication except for prolongation of the food intake and masticatory periods, cats with bilateral CMA lesions showed wide jaw opening during mastication, delay in the

Table 1. Cases of HMS reported in the literature

Authors	Sex	Age at onset years	Side	Muscles involved (assessed by EMG)	Electrophysiological study of trigeminal function	Proposed site of lesion and mechanisms	Response to botulinum toxin
Kaufman [2], 1980	F	25	left	masseter	n.d.	peripheral nerve	n.a.
Lapresle and Desi [3], 1982	F	15	right	masseter	n.d.	muscle and central nervous system	n.a.
Thompson and Carroll [4, 5], 1983	F	57	left	masseter, temporalis	normal blink reflexes	inflammatory disorder or vascular compression of peripheral nerve	n.a.
Thompson et al. [6], 1986	F	31	right	jaw-closing	normal blink reflexes; delayed masseter reflex	peripheral nerve	n.a.
Parisi et al. [7], 1987	F	38	right	masseter	n.d.	sympathetic cervical ganglia or peripheral nerve or nucleus	n.a.
Yoshii et al. [8], 1989	M	44	left	masseter, pterygoids	n.d.	peripheral nerve; vascular compression	n.a.
Auger et al. [9], 1992	F	20	right	masseter, temporalis	normal blink and masseter reflexes; absent silent periods	motor root or nucleus	yes
	F	17	right	pterygoid			n.a.
	F	20	right	masseter, temporalis			n.a.
Cruccu et al. [10], 1994	M	18	left	temporalis	normal blink and masseter inhibitory reflexes; delay of direct motor response	focal demyelination or peripheral nerve by compression	n.a.
	F	44	right	jaw-closing			n.a.
Kim et al. [11], 1994	M	44	right	masseter	normal blink reflexes; attenuation of silent periods	n.d.	yes
Ebersbach et al. [12], 1995	M	26	left	masseter, temporalis	normal blink and masseter reflexes; no attenuation of masseter silent periods	entrapment of peripheral nerve or hyperexcitability of motor nucleus	yes
	F	26	right	masseter, temporalis			yes
Kim et al. [13], 2000	F	34	right	masseter	normal blink reflexes and masseteric nerve conduction study; absent masseter reflexes and silent periods	focal demyelination of peripheral nerve by deep tissue damage	yes
Esteban et al. [14], 2002	F	47	left	masseter	initial normality and late deterioration of the jaw reflex; abolition or high attenuation of masseteric inhibitory reflex; normal blink reflexes	peripheral nerve	yes
Teive et al. [15], 2002	F	44	right	masseter, temporalis	n.d.	n.d.	yes
Cersosimo et al. [16], 2003	F	29	right	masseter, temporalis	n.d.	n.d.	yes
Mir et al. [17], 2006	M	26	left	masseter, temporalis	delayed jaw jerk; absent silent periods during spasms; normal blink reflexes; delayed M wave by magnetic trigeminal root stimulation; enhancement of blink reflex recovery cycle in both orbicularis oculi muscles after stimulation of left supraorbital nerve	peripheral nerve; secondary changes in the excitability of inhibitory circuits at a central level	yes
Jiménez-Jiménez et al., 2007	M	40	right	masseter, temporalis	normal blink and masseter inhibitory reflexes	asymmetric biopercular lesions (supranuclear)	yes

start of mastication, abnormal tongue protrusion and difficulty in manipulating food on the tongue [23, 24].

Kempainen et al. [25] performed a study in patients with unilateral cortical infarction in the region of the middle cere-

bral artery and showed no impairment of masticatory force and function. On the other hand, Cruccu et al. [26] studied the masseter inhibitory reflex in 15 patients with hemiplegia and found normal latencies of both SP1 and SP2 components of

this reflex, but reduced amplitude and increased habituation of the SP2 evoked by stimulation of the paretic side. These authors concluded that, though the masticatory nucleus receives bilateral innervation, the contralateral hemisphere should exert

a predominant control of voluntary activity and multisynaptic reflexes.

HMS is usually considered to be related with peripheral affection of the trigeminal nerve [2, 4, 10, 13, 14, 17]. This is supported by the presence of delayed jaw jerk [6, 10, 14, 16] and the absence of silent periods of the masseter inhibitory reflexes [9, 12, 13, 14, 17, 26] or 'efferent block' [26]. In patients with trigeminal neuropathy, both SP1 and SP2 components of the masseter inhibitory reflexes should be delayed or reduced in size, while a lesion to the masticatory nucleus or motor axons can cause an ipsilateral muscle weakness and a reduction in the voluntary EMG activity, but the reflex inhibition should remain evident [27].

Recently, Frontera and Pallesstrany [28] have reported a patient who developed acute trismus associated with biopercular syndrome due to stroke. A possible explanation of the fact that our patient developed a unilateral masticatory syndrome with a bilateral opercular lesion should be the asymmetry of these lesions (shown in fig. 1). Although there is no clear explanation for the delayed appearance of this syndrome, it could be speculated that it is due to the interruption of the corticopontine pathways, as it is was described with acute pseudobulbar or suprabulbar palsies, some of them related with opercular infarcts [29]. The present report raises the possibility that HMS could also be associated with bilateral asymmetrical cortical lesions like those presented by our patient with a previous biopercular syndrome. These data suggest the possible role of some cortical areas of the human brain in the control of mastication, as it has been reported in some experimental models.

References

- Gowers WR: A manual of disease of the Central Nervous System, ed 2. Philadelphia, Blakiston, 1897, vol 2, pp 221–224.
- Kaufman MD: Masticatory spasm in facial hemiatrophy. *Ann Neurol* 1980;7:585–587.
- Lapresle J, Desi M: Sclérodémie avec hémiatrophie faciale progressive et atrophie croisée de l'hémicorpos. *Rev Neurol (Paris)* 1982;138:815–825.
- Thompson PD, Carroll WM: Hemimasticatory spasm: a peripheral paroxysmal cranial neuropathy? *J Neurol Neurosurg Psychiatry* 1983;46:274–276.
- Thompson PD, Carroll WM: Hemimasticatory and hemifacial spasm: a common pathophysiology? *Clin Exp Neurol* 1983;19:110–119.
- Thompson PD, Obeso JA, Delgado G, Gallego J, Marsden CD: Focal dystonia of the jaw and the differential diagnosis of unilateral jaw and masticatory spasm. *J Neurol Neurosurg Psychiatry* 1986;49:651–656.
- Parisi L, Valente G, Dell'Anna C, Mariorenzi R, Amabile G: A case of facial hemiatrophy associated with linear scleroderma and homolateral masseter spasm. *Ital J Neurol Sci* 1987;8:63–65.
- Yoshii K, Seki Y, Aiba T: A case of unilateral masticatory spasm without hemifacial atrophy. *No To Shinkei* 1989;41:343–346.
- Auger RG, Litchy WJ, Cascino TL, Ahlskog JE: Hemimasticatory spasm: clinical and electrophysiologic observations. *Neurology* 1992;42:2263–2266.
- Cruccu G, Inghilleri M, Berardelli A, et al: Pathophysiology of hemimasticatory spasm. *J Neurol Neurosurg Psychiatry* 1994;57:43–50.
- Kim YH, Lee KS, Na JH, Kim BS, Ko YJ: A case of hemimasticatory spasm. *J Korean Neurol Assoc* 1994;12:175–178.
- Ebersbach G, Kabus C, Schelosky L, Terstegge L, Poewe W: Hemimasticatory spasm in hemifacial atrophy: diagnostic and therapeutic aspects in two patients. *Mov Disord* 1995;10:504–507.
- Kim HJ, Jeon BS, Lee KW: Hemimasticatory spasm associated with localized scleroderma and facial hemiatrophy. *Arch Neurol* 2000;57:576–580.
- Esteban A, Traba A, Prieto J, Grandas F: Long-term follow-up of a masticatory spasm. *Acta Neurol Scand* 2002;105:67–72.
- Teive HAG, Piovesan EJ, Germiniani FMB, Camargo CHA, Sa D, Scola RH, Werneck LC: Hemimasticatory spasm treated with botulinum toxin: case report. *Arq Neuropsiquiatr* 2002;60:288–289.
- Cersósimo MG, Bertoti A, Uribe-Roca C, Micheli F: Botulinum toxin in a case of hemimasticatory spasm with severe worsening during pregnancy. *Clin Neuropharmacol* 2004;27:6–8.
- Mir P, Gilio F, Edwards M, Inghilleri M, Bhatta KP, Rothwell JC, Quinn N: Alteration of central motor excitability in a patient with hemimasticatory spasm after treatment with botulinum toxin injections. *Mov Disord* 2006;21:73–78.
- Puertas I, García-Soldevilla MA, Jiménez-Jiménez FJ, Cabrera-Valdivia F, Jabbour T, García-Albea E: Mano distónica bilateral secundaria a síndrome biopercular o síndrome de Foix-Chavany-Marie. *Rev Neurol* 2002;35:430–433.
- Hiraba H, Sato T: Cerebral control of face, jaw, and tongue movements in awake cats: changes in regional cerebral blood flow during lateral feeding. *Somatosens Mot Res* 2005;22:307–317.
- Enemoto S, Schwartz G, Lund JP: The effects of cortical ablation on mastication in the rabbit. *Neurosci Lett* 1987;82:162–166.
- Masuda Y, Kim SK, Kato T, Iida S, Yoshida A, Tachibana Y, Morimoto T: Different corticostriatal projections from two parts of the cortical masticatory area in the rabbit. *Exp Brain Res* 2005;161:397–404.
- Roatta S, Windhorst U, Djupsjobacka M, Lytvynenko S, Passatore M: Effects of sympathetic stimulation on the rhythmic jaw movements produced by electrical stimulation of the cortical masticatory areas of rabbits. *Exp Brain Res* 2005;162:14–22.
- Hiraba H, Sato T: Cortical control for mastication in cats: changes in masticatory movements following lesions in the masticatory cortex. *Somatosens Mot Res* 2005;22:171–181.
- Hiraba H, Sato T: Cortical control for mastication in cats 2: Deficits of masticatory movements following a lesion in the motor cortex. *Somatosens Mot Res* 2005;22:183–192.
- Kempainen P, Waltimo A, Palomäki H, Salonen O, Könönen M, Kaste M: Masticatory force and function in patients with hemispheric brain infarction and hemiplegia. *J Dent Res* 1999;78:1810–1814.
- Cruccu G, Fornarelli M, Manfredi M: Impairment of masticatory function in hemiplegia. *Neurology* 1988;38:302–306.
- Cruccu G, Paulett G, Agostino A, Berardelli A, Manfredi M: Masseter inhibitory reflex in movement disorders: Huntington's chorea, Parkinson's disease, dystonia, and unilateral masticatory spasm. *Electroencephalogr Clin Neurophysiol* 1991;81:24–30.
- Frontera JA, Palestini D: Acute trismus associated with Foix-Marie-Chavany syndrome. *Neurology* 2006;66:454–455.
- Besson G, Bogousslavsky J, Regli F, Maeder P: Acute pseudobulbar or suprabulbar palsy. *Arch Neurol* 1991;48:501–507.