

ser photocoagulation to the tumor surface and surrounding retina was provided. Visual acuity continued to decrease to 20/70 OD at 17 months, so PDT was performed (**Figure**). The entire astrocytoma was treated with a single 83-second laser spot at 689 nm (50 J/cm²) following intravenous verteporfin (6 mg/m²). After treatment, resolution of macular exudation, edema, and subretinal fluid led to improved vision of 20/50 OD (at 1 month) and 20/30 OD (at 4, 8, and 12 months). The tumor showed minimal involution with decreased intrinsic vascularity.

Comment. Benign retinal astrocytic tumors include astrocytic hamartoma, acquired astrocytoma, and reactive retinal gliosis.¹ Astrocytic hamartoma is typically stable, recognized in early childhood, and often found in patients with tuberous sclerosis complex or neurofibromatosis.^{1,3} Acquired astrocytoma is a sporadic tumor with progressive growth, retinal detachment, and poor visual acuity and requires enucleation.^{1,2} This tumor is typically found in young or middle-aged adults and is not associated with tuberous sclerosis complex. Retinal gliosis generally occurs following trauma, inflammation, or infection.

Acquired retinal astrocytoma shows poor response to laser photocoagulation and radiotherapy. Mennel and associates⁴ described a similar case in which an astrocytoma produced a visual acuity of 20/200 OD from serous retinal detachment, exudation, and edema. After 166 seconds of PDT, the retinal findings gradually cleared during 1 year, with a final visual acuity of 20/30 OD. Surprisingly, the tumor nearly completely disappeared. In our case, the retinal findings and visual acuity cleared, but the tumor showed trace reduction in size at 8 months following PDT.

In other fields of oncology, the photodynamic technique is important in the detection and treatment of tumors, particularly brain tumors, such as malignant gliomas, metastatic tumors, and meningiomas. Photodynamic therapy provides targeted destruction of remaining tumor cells following surgical

excision and has been shown to increase patient survival.⁵

Carol L. Shields, MD
Miguel A. Materin, MD
Brian P. Marr, MD
Jaime Krepostman, MD
Jerry A. Shields, MD

Correspondence: Dr C. L. Shields, Ocular Oncology Service, Wills Eye Institute, Ste 1440, 840 Walnut St, Philadelphia, PA 19107 (carol.shields@shieldsoncology.com).

Author Contributions: Dr C. L. Shields had full access to all the data in the study and takes responsibility for the integrity of the data and the accuracy of the data analysis.

Financial Disclosure: None reported.

Funding/Support: This study was supported by the Retina Research Foundation of the Retina Society, Cape Town, South Africa (Dr C. L. Shields), the Paul Kayser International Award of Merit in Retina Research, Houston, Texas (Dr J. A. Shields), Michael, Bruce, and Ellen Ratner, New York, New York (Drs C. L. Shields and J. A. Shields), the Mellon Charitable Giving from the Martha W. Rogers Charitable Trust, Philadelphia, Pennsylvania (C. L. Shields), the LuEsther Mertz Retina Research Foundation, New York (C. L. Shields), and the Eye Tumor Research Foundation, Philadelphia (Drs C. L. Shields and J. A. Shields).

1. Shields JA, Shields CL. Glial tumors of the retina and optic disc. In: Shields JA, Shields CL, eds. *Atlas of Intraocular Tumors*. Philadelphia, PA: Lippincott Williams & Wilkins; 1999:269-286.
2. Shields CL, Shields JA, Eagle RC Jr, Cangemi F. Progressive enlargement of acquired retinal astrocytoma in two cases. *Ophthalmology*. 2004; 111(2):363-368.
3. Zimmer-Galler IE, Robertson DM. Long-term observation of retinal lesions in tuberous sclerosis. *Am J Ophthalmol*. 1995;119(3):318-324.
4. Mennel S, Hausmann N, Meyer CH, Peter S. Photodynamic therapy for exudative hamartoma in tuberous sclerosis. *Arch Ophthalmol*. 2006;124(4):597-599.
5. Eljamel MS. New light on the brain: the role of photosensitizing agents and laser light in the management of invasive intracranial tumors. *Technol Cancer Res Treat*. 2003;2(4):303-309.

Bitemporal Hemianopia Caused by an Intracranial Vascular Loop

Optic chiasmatal syndrome can be caused by a variety of lesions, in-

cluding tumors and carotid artery aneurysms¹; however, reports of bitemporal field loss from compression by an abnormal vessel are rare.² We describe a patient with a non-progressive bitemporal hemianopia in whom there appeared to be compression of the optic chiasm by an elongated right anterior cerebral artery (ACA).

Report of a Case. A bitemporal hemianopia was found in a 65-year-old woman with no vascular risk factors during a routine eye examination in 2003. Magnetic resonance imaging (MRI) results were normal. One year later, the bitemporal field defect was still present and a second MRI again showed no evidence of a compressive or infiltrative process.

The patient was subsequently referred to us for an assessment. On examination, her visual acuity was 20/20 OU with normal color vision and pupillary responses. The fundi appeared normal with no evidence of tilted optic discs or retinoschisis. A bitemporal hemianopic scotoma was detected by kinetic perimetry (**Figure 1A**), and static perimetry revealed a bitemporal hemianopic defect, denser inferiorly than superiorly, with a pattern and severity unchanged from the examination performed 20 months earlier (Figure 1B). Multifocal electroretinography results were normal, but visual evoked potentials showed a mild bilateral delayed response. It was noted that the 2 previous MRIs had been performed without magnification and did not consist of thin sections.

A repeat MRI with thin-slice and magnified views of the optic chiasm was obtained and showed a vessel indenting the optic chiasm superiorly (**Figure 2A**). A computed tomographic angiogram confirmed an elongated right ACA that dipped inferiorly, compressing the superior aspect of the optic chiasm before looping anteriorly (Figure 2B). The ACA loop was thought to be the cause of the patient's bitemporal hemianopia. We decided against neurosurgical intervention but recommended that the patient be evaluated at regular intervals.

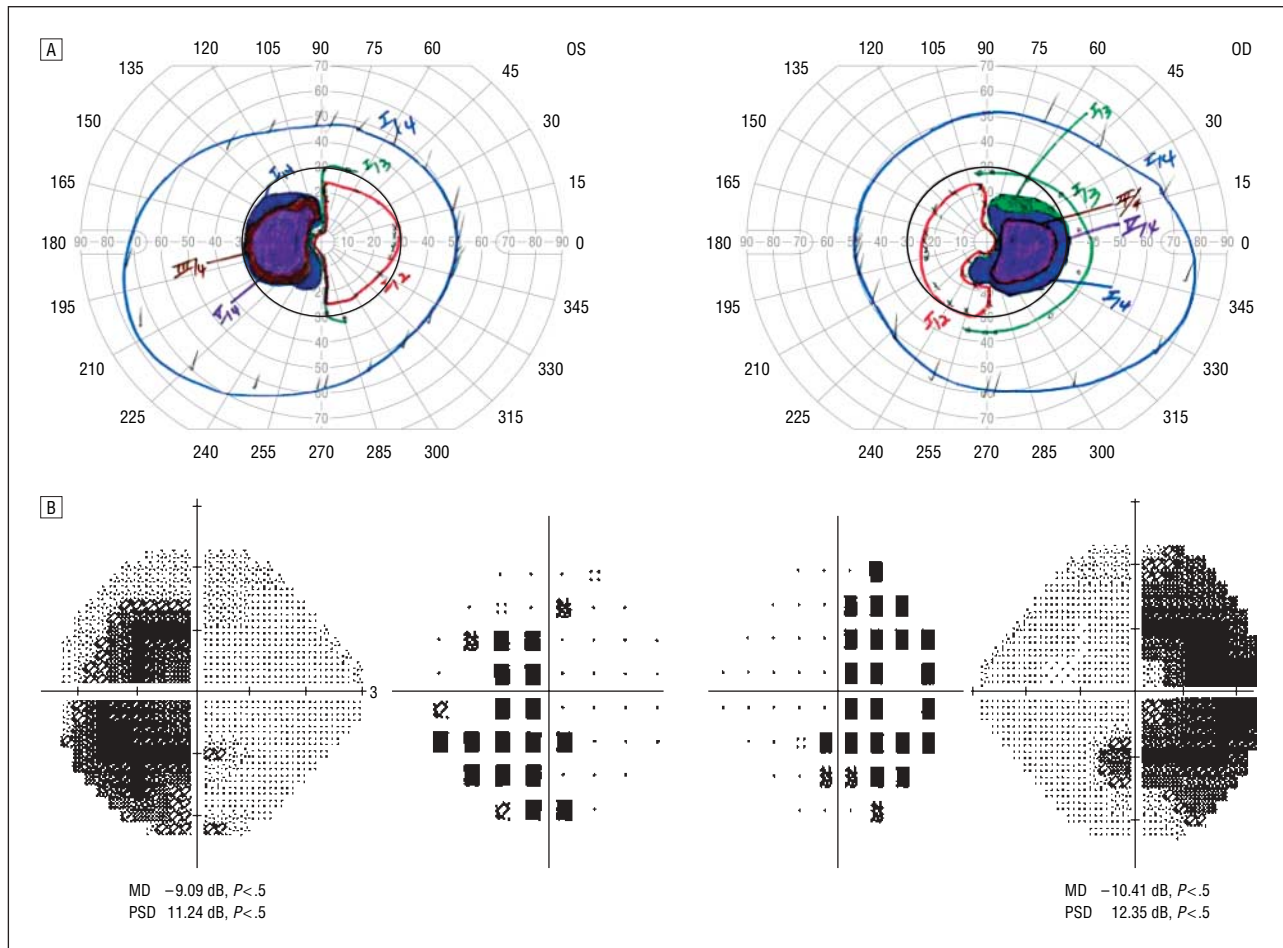


Figure 1. A, Kinetic perimetry showing a bimodal hemianopic scotoma. B, Static perimetry with Swedish interactive threshold algorithm fast 24-2 strategy showing a bimodal hemianopia that is denser inferiorly than superiorly. MD indicates mean deviation; PSD, pattern standard deviation.

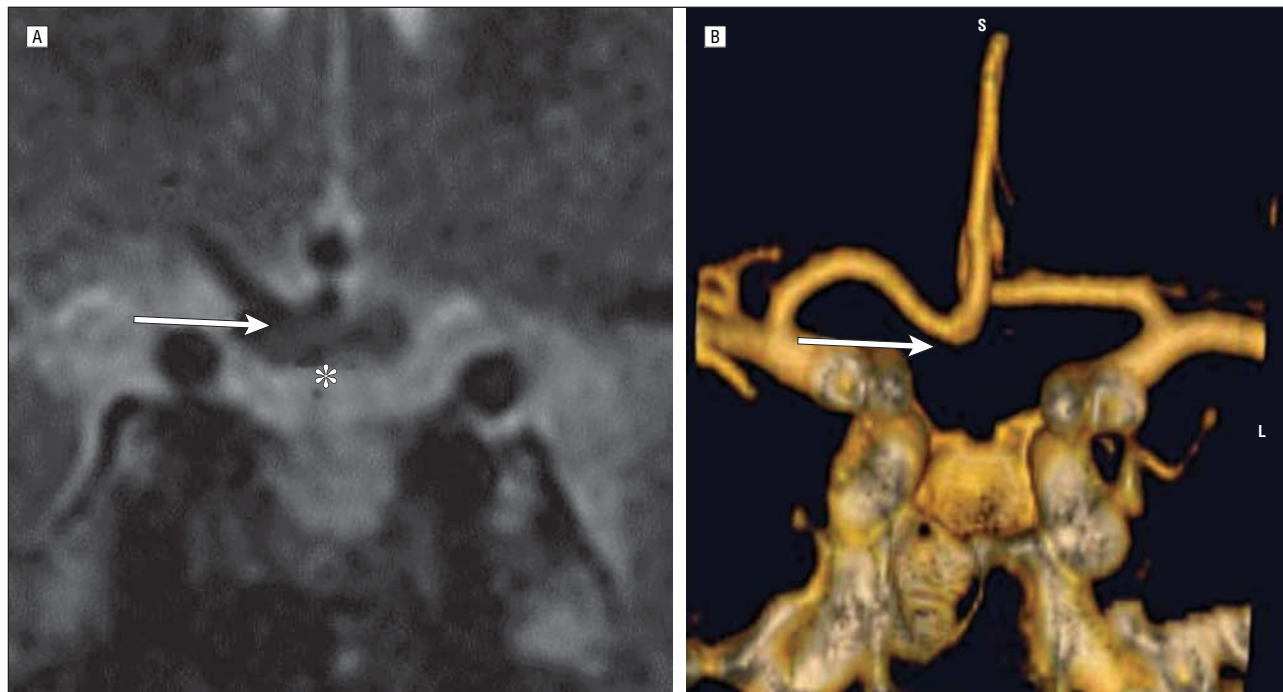


Figure 2. A, T2-weighted coronal magnetic resonance imaging showing impingement and downward displacement of the optic chiasm (asterisk) by a vessel (arrow). B, Reconstructed coronal computed tomographic angiography shows an elongated right anterior cerebral artery that curves downward, forming a loop (arrow) that corresponds to the point of contact with the optic chiasm. The opposite anterior cerebral artery has a normal structure.

Comment. Vascular compression of the optic chiasm causing a bitemporal field defect is most often due to an aneurysm of the ACA, internal carotid artery, or anterior communicating artery.¹ Rare cases of dolichoectatic and atherosclerotic ACAs that cause bitemporal hemianopia have been reported, but direct chiasmal impingement has not been described. The field defect in such cases is thought to result from traction on small perforating vessels causing a chiasmal infarction.² In addition, although Bergaust³ reported a patient with a bitemporal hemianopia that was thought to be caused by compression of the inferior aspect of the optic chiasm by an anomalous internal carotid artery, we are unaware of any cases of presumed vascular compression of the chiasm with production of a bitemporal field defect by a vascular loop.

Our case highlights the importance of not only obtaining appropriate neuroimaging studies but also specifying the region of interest. The presence of a bitemporal hemianopia in the absence of optic nerve or retinal pathology suggested a process involving the optic chiasm. By obtaining thin-sectioned, magnified views of this region, we were able to identify an anomalous loop of the right ACA, which appeared to be compressing and causing downward displacement of the chiasm, presumably causing the bitemporal defect. A computerized tomographic angiogram further clarified the process.

Although surgery can be performed in this setting,⁴ surgical manipulation may disrupt the small perforating vessels supplying the optic chiasm and result in worsening of a preexisting visual field defect or even complete blindness. Thus, unless there is clear evidence of pro-

gression, it is probably best to follow up in patients with this rare condition.

Celia S. Chen, MBBS, MPH
Phillipe Gailloud, MD
Neil R. Miller, MD


Correspondence: Dr Miller, Wilmer Eye Institute, Johns Hopkins Hospital, Maumenee 127, 600 N Wolfe St, Baltimore, MD 21287 (nrmiller@jhmi.edu).

Financial Disclosure: None reported.

1. Bakker SL, Hasan D, Bijvoet HW. Compression of the visual pathway by anterior cerebral artery aneurysm. *Acta Neurol Scand.* 1999;99(3):204-207.
2. Hilton GF, Hoyt WF. An arteriosclerotic chiasmal syndrome. *JAMA.* 1966;196(11):1018-1020.
3. Bergaust B. Unusual course of internal carotid artery accompanied by bitemporal hemianopia. *Acta Ophthalmol (Copenh).* 1963;41:270-274.
4. Post KD, Gittinger JW, Stein BM. Visual improvement after surgical manipulation of dolichoectatic anterior cerebral artery. *Surg Neurol.* 1981;15(4):321-324.

Ophthalmological Ephemera

In 1795, Dr Isaac Thompson concocted an eye water of zinc sulfate, saffron, camphor, and rose water. It was sold as late as 1939. This is 1 of a series of 32 medical trade cards advertising the product from 1875 through 1895.



DR. ISAAC THOMPSON'S
CELEBRATED
EYE WATER,
FOR ALL COMPLAINTS OF THE EYES.
Each Bottle is stamped with my Proprietary Stamp. None other Genuine.

THE GENUINE EYE WATER

Is enclosed in an engraved envelope, on which is the likeness of the Original Inventor, **DR. ISAAC THOMPSON**, New London, Conn., with a *fac-simile* of his signature; also the signature of **JOHN L. THOMPSON**, with a note of hand, signed by **JOHN L. THOMPSON**, 161 River Street, Troy, N. Y. *None other can be Genuine.*

This well-known and thoroughly efficient remedy has acquired a world-wide reputation, having been before the public for over eighty-five years, and it is a remarkable fact that its reputation has been sustained simply by the *merits of the medicine*, as the many thousands, who have used it, will bear testimony.

ITS MERITS STAND UNRIVALED.
In constant use since 1795.
Price.....25 Cents per Bottle.
JOHN L. THOMPSON, Prop'r, Troy, N. Y.

Courtesy of: Daniel M. Albert, MD, MS.