

SHORT COMMUNICATION

Bilateral cerebral hemispheric infarction associated with sildenafil citrate (Viagra®) use

K.-K. Kim^a, D. G. Kim^a, Y. H. Ku^a, Y. J. Lee^b, W.-C. Kim^a, O. J. Kim^a and H. S. Kim^a*Departments of ^aNeurology and ^bDepartment of Radiology, Pochon CHA University College of Medicine, Seongnam-si, Gyeonggi-do, South Korea***Keywords:**

cardioembolism, cerebral infarction, sildenafil

Received 26 September 2006

Accepted 23 January 2007

Sildenafil citrate (Viagra®) is one of the frequently prescribed drugs for men with erectile dysfunction. We describe a 52-year-old man with bilateral middle cerebral artery (MCA) territory infarction after sildenafil use. He ingested 100 mg of sildenafil and about 1 h later, he complained of chest discomfort, palpitation and dizziness followed by mental obtundation, global aphasia and left hemiparesis. Brain magnetic resonance imaging documented acute bilateral hemispheric infarction, and cerebral angiography showed occluded bilateral MCA. Despite significant bilateral MCA stenosis and cerebral infarction, systemic hypotension persisted for a day. We presume that cerebral infarction was caused by cardioembolism with sildenafil use.

Introduction

Sildenafil citrate (Viagra®; Pfizer US Pharmaceutical Group, New York, NY, USA) is the drug of choice for most men with erectile dysfunction. Its main adverse effects are headache, flushing, dyspepsia, nasal congestion, and visual disturbances to a mild degree [1]. In both placebo-controlled and open-label studies, sildenafil was not associated with an increased risk of stroke [2]. However, it should be prescribed with caution to patients with persistent hypotension and patients who have suffered a myocardial infarction, stroke, or life-threatening arrhythmia within the last 6 months [3]. We report a patient who had no past medical history of cerebrovascular risk factors and presented with bilateral hemispheric infarction shortly after sildenafil use.

Case report

A 52-year-old, right-handed man presented with a sudden onset of left hemiparesis and mental obtundation for 1 h. He had no previous medical history of hypertension, diabetes, hyperlipidemia, cardiac disease, or stroke. He smoked one pack of cigarettes per day for the past 30 years, and drank socially. He had not taken any medication for the last several months and he had not been prescribed sildenafil before. According to his spouse, he took 100 mg of sildenafil without achieving

an erection or participating in sexual intercourse. Then, chest discomfort, palpitation, dizziness, and dull headache appeared 1 h after sildenafil use. A neurological examination showed drowsy mental status, global aphasia, gaze preference to the right side, and left hemiparesis [Medical Research Council (MRC) scale III in his left arm and leg]. Tendon reflexes were hyperactive, but symmetric in all extremities without pathological reflexes. Vital signs were stable, and his heart rate was 105 beats/min with normal sinus rhythm. But his blood pressure was around 90/60 mmHg for initial 5 h. During this period, the lowest blood pressure was 85/50 mmHg and the highest blood pressure was 100/60 mmHg.

Brain computerized tomography (CT) showed suspicious loss of gray–white matter interface in bitemporal regions. Transfemoral cerebral angiography was started 5 h after the onset, and complete occlusion at the superior division of the left middle cerebral artery (MCA) and partial occlusion at the superior division of the right MCA with thrombus were documented (Fig. 1a and b). However, there was no carotid stenosis. We infused 300 000 units of urokinase in the left MCA (150 000 units were infused for 2 min first, followed by three times of 50 000 units, each for 1 min with 5-min interval), which was totally re-canalized. We also infused 100 000 units of urokinase in the right MCA (two times of 50 000 units, each for 1 min with 5-min interval), which was partially re-canalized with good collateral circulation. The patient showed improvement of left hemiparesis (up to MRC grade IV) immediately after re-canalization. Because the blood pressure remained around 90/60 mmHg with vigorous iv fluid replacement therapy, the patient was treated with dopamine (5–10 µg/kg/min) after the thrombolytic

Correspondence: Hyun Sook Kim, MD, Department of Neurology, Pochon CHA University College of Medicine, Yatap-dong 351, Bundang-gu, Seongnam-si, Gyeonggi-do, South Korea (tel.: + 82 31 780 5483; fax: + 82 31 780 5198; e-mail: hskim626@cha.ac.kr).

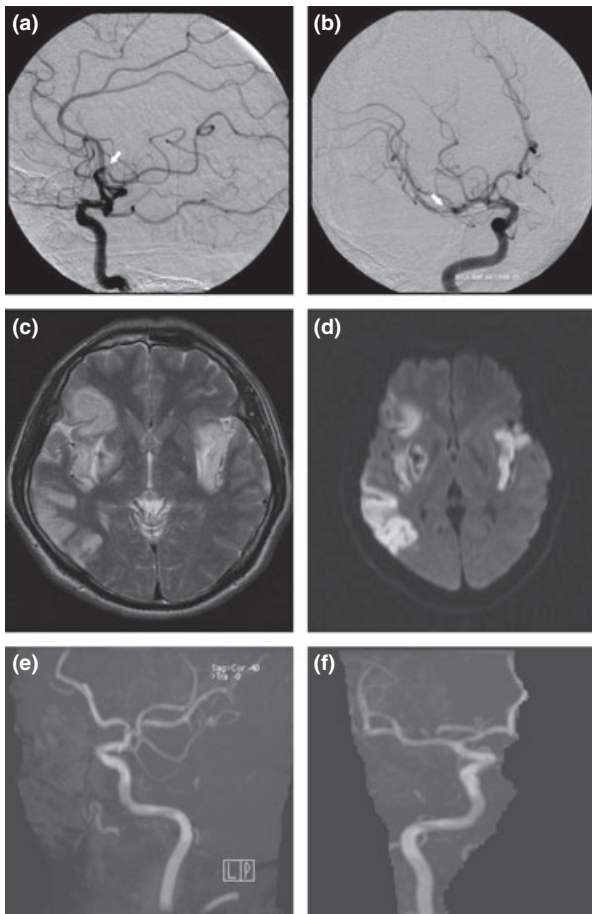


Figure 1 Cerebral angiography showed complete occlusion of the superior division of the left middle cerebral artery (a, white arrow) and partial occlusion of superior division of right middle cerebral artery (b, whiter arrow). Brain MRI showed increased signal intensities in bilateral middle cerebral artery territory on T2-weighted image (c), and diffusion weighted image (d). After thrombolysis, brain MRA showed re-canalized left (e) and right (f) middle cerebral arteries.

procedure. His blood pressure was above 120/80 mmHg and it could be maintained without dopamine after 1 day. After 3 days, brain magnetic resonance imaging (MRI) demonstrated bilateral MCA territory infarction and hemorrhagic transformation at right basal ganglia (Fig. 1c and d). And bilateral MCAs were normal on brain magnetic resonance angiography (Fig. 1e and f). The routine laboratory tests – including the blood glucose level, thyroid functions, creatine kinase (CK) and CK-myocardial band (MB) level, Protein C and S, plasma homocysteine level, and autoimmune screening tests were all within normal range. Serum total cholesterol level was 263 mg/dl, triglyceride was 300 mg/dl, and low-density lipoprotein cholesterol was 175 mg/dl. The transthoracic echocardiogram showed normal sized cardiac chambers with

normal global left ventricular (LV) systolic function (ejection fraction = 73%). The transesophageal echocardiogram showed a small thrombus in the left atrial appendage. The electrocardiogram at admission and at 12th hospital day, and 24 h holter monitoring resulted in normal findings.

About 1 week later, motor weakness improved up to MRC grade V and the patient could walk independently. Comprehensive function also recovered partially; however, motor aphasia and bulbar paralysis persisted. His blood pressure has been checked between 120/80 and 140/90 mmHg up to the present.

Discussion

Sildenafil inhibits cyclic guanosine monophosphate (cGMP)-specific phosphodiesterase type 5 (PDE5) and increased cGMP promotes the effect of nitric oxide (NO) [4]. Because relatively high levels of PDE5 are found in the human corpus cavernosum and in vascular, visceral, and tracheal smooth muscles, NO causes the vasodilatations not only in corpus cavernosum but also in systemic vessels. This modest vasodilating property produces an average decrease in blood pressure of 8.0/5.5 mmHg over the initial 24 h after a dose of the drug and necessitates caution when prescribing sildenafil to patients with cardiovascular disease [5,6]. Providentially, sildenafil citrate has much diminished selectivity for cAMP-specific PDE isoform-3, which is involved in regulating cardiac contractility [7]. Reported cardiovascular side effects in normal healthy populations are typically minor and transient. However, acute myocardial infarction, sudden cardiac death, symptomatic non-fatal ventricular arrhythmia, transient cerebral ischemic attacks *per se*, and hemorrhagic stroke are clearly documented in patients engaging in sexual exertion assisted with the use of sildenafil [8,9]. It is proposed that pre-sildenafil treadmill tests assessing the presence of stress-induced ischemia in patients with coronary artery disease can guide the relative risk of cardiac ischemia during sexual intercourse after sildenafil use [6].

Acute, symptomatic atrial fibrillation presenting with dyspnea, palpitations, and dizziness was reported after oral ingestion of sildenafil [5,10,11]. The mechanism of atrial fibrillation induced by sildenafil is uncertain. One explanation is that arterial vasodilatation induced by the drug produces an increased pressure gradient over the LV outflow tract, and previously existing cardiomyopathy are prone to producing the atrial fibrillation [5]. Otherwise, atrial fibrillation may be secondarily induced through increased sympathetic activity for hypotension [10,11]. It was believed that cardiac complications could occur in specific situations such as

sildenafil use accompanied with sexual activity or among the patients with previous cardiovascular risk factors [6,12]. However, there were patients with atrial fibrillation without participating in sexual intercourse [11] and in young healthy condition [10].

The etiology of vascular ischemia after sildenafil use is still obscure. A few reports hypothesized that hypotension, cardioembolism or hypercoagulation were responsible [9,13,14]. Although sildenafil has no direct effects on platelet function, it modestly potentiates the inhibitory effect of the NO donor sodium nitroprusside on ADP-induced platelet aggregation *ex vivo*. According to this mechanism of action, adverse bleeding episodes are the major concern [6], so, it is unlikely that sildenafil induces a hypercoagulable state. Hypotension and atrial fibrillation are relatively identified adverse effects of sildenafil and there was a case with atrial fibrillation and continuous hypotension induced by sildenafil use [11]. Moreover, left atrial thrombus formation does occur in patients with acute atrial fibrillation less than a few days in duration [15]. In another recent report, the proposed mechanism of stroke was unidentified effect of sildenafil on the already damaged blood vessel because of other disease like hypertension or diabetes [16]. However, this hypothesis is discrepant from that of our case, because our patient had no causative diseases that damage the blood vessels.

The initial symptoms of our patient, such as chest discomfort, palpitation, and dizziness were concordant with the manifestations of cardiac arrhythmia. Additionally, this patient showed prominent hypotension for a day. Sildenafil has a terminal half-life of about 4 h and maximum observed plasma concentrations are reached within 30–120 min (median 60 min) of oral dosing in fasting state [2,3]. The onset of symptoms 1 h after sildenafil ingestion is consistent with the time range of maximal plasma concentration of the drug. Transesophageal echocardiogram showed a thrombus in the left atrial appendage, and cerebral angiography showed thromboembolic occlusion in the bilateral MCA. We suggest that transient arrhythmic cardioembolism induced by an excessive catecholamine response to sildenafil-induced hypotension may be the etiology.

Sildenafil is a widely used drug for men with erectile dysfunction, but little is known about stroke risk in patients who take sildenafil. And the mechanism(s) of stroke after sildenafil use is still debatable. Because sexual activity, sildenafil, drug interactions, or the patient's underlying cardiovascular disease can all be implicated, it is more difficult to define the exact cause for the mechanism of the adverse effect of sildenafil. Our experience with the bilateral MCA territory infarction associated with sildenafil use suggests that

sildenafil must be prescribed with caution for the patients without risk factors of vascular events. Further studies regarding pathophysiology related to cerebral infarction are needed.

References

1. Goldstein I, Lue TF, Padma-Nathan H, Rosen RC, Steers WD, Wicher PA. Oral sildenafil in the treatment of erectile dysfunction. Sildenafil Study Group. *New England Journal of Medicine* 1998; **338**: 1397–1404.
2. Zusman RM, Morales A, Glasser DB, Osterloh IH. Overall cardiovascular profile of sildenafil citrate. *American Journal of Cardiology* 1999; **83**: 35C–44C.
3. US Food and Drug Administration. *Post-marketing Safety or Sildenafil citrate (VIAGRA)*. Available at: <http://www.fda.gov/cder/consumerinfo/viagra/safety3.htm> (accessed 20/09/2000).
4. Beavo JA. Cyclic nucleotide phosphodiesterase: functional implications of multiple isoforms. *Physiological Reviews* 1995; **75**: 725–748.
5. Awan GM, Balderon E, Dawood G, Alpert M. Acute, symptomatic atrial fibrillation after sildenafil citrate therapy in a patient with hypertrophic obstructive cardiomyopathy. *American Journal of Medical Sciences* 2000; **320**: 69–71.
6. Cheitlin MD, Hutter AM Jr, Brindis RG, *et al.* Use of sildenafil (Viagra) in patients with cardiovascular disease. Technology and Practice Executive Committee. *Circulation* 1999; **99**: 168–177.
7. Packer M, Carver JR, Rodeheffer RJ, *et al.* Effect of oral mirinone on mortality in severe chronic heart failure: The PROMISE Study Research Group. *New England Journal of Medicine* 1991; **325**: 1468–1475.
8. Lim PH, Moorthy P, Benton KG. The clinical safety of viagra. *Annals of New York Academy of Sciences* 2002; **962**: 378–388.
9. Morgan JC, Alhatou M, Oberlies J, Johnston KC. Transient ischemic attack and stroke associated with sildenafil (Viagra) use. *Neurology* 2001; **57**: 1730–1731.
10. Hahn IH, Hoffman RS. Aroused to atrial fibrillation? *American Journal of Emergency Medicine* 2000; **18**: 642.
11. Hayashi K, Minezaki KK, Narukawa M, Okubo M, Mitsuhashi T, Shimada K. Atrial fibrillation and continuous hypotension induced by sildenafil in an intermittent WPW syndrome patient. *Japanese Heart Journal* 1999; **40**: 827–830.
12. Koner RA. Sex and the patients with cardiovascular risk factors: focus on sildenafil. *American Journal of Medicine* 2000; **19**: 13S–21S.
13. Tripathi A, O'Donnell NP. Branch retinal artery occlusion: another complication of sildenafil. *British Journal of Ophthalmology* 2000; **84**: 934–935.
14. Egan RA, Pomeranz H. Transient ischemic attack and stroke associated with sildenafil (Viagra) use. *Neurology* 2002; **59**: 293–294.
15. Stoddard MF, Dawkins PR, Prince CR, Ammash NM. Left atrial appendage thrombus is not uncommon in patients with acute atrial fibrillation and a recent embolic event: a transesophageal echocardiographic study. *Journal of American College of Cardiology* 1995; **25**: 452–459.
16. Habek M, Petravic D. Stroke – an adverse reaction to sildenafil. *Clinical Neuropharmacology* 2006; **29**: 165–167.