

Ischemia

Ischemic stroke due to dissection of intracranial internal carotid artery: implications for early surgical treatment

Fumiaki Oka, MD^{a,b,*}, Hiroaki Shimizu, MD^a, Yasushi Matsumoto, MD^c,
Mika Watanabe, MD^d, Teiji Tominaga, MD^e

^aDepartment of Neurosurgery, Kohnan Hospital, Sendai, Japan

^bDepartment of Neurosurgery, Yamaguchi University School of Medicine, Ube, Yamaguchi, 755-8505, Japan

^cDepartment of Endovascular Neurosurgery, Kohnan Hospital, Sendai, Japan

Departments of ^dPathology and ^eNeurosurgery, Tohoku University Graduate School of Medicine, Sendai, Japan

Received 5 January 2007; accepted 9 April 2007

Abstract

Background: Intracranial ICA dissection is a rare pathology that frequently results in severe morbidity or mortality in young patients. This study examined the suitability of early surgical treatment.

Methods: We present and analyze 6 of our own cases and 39 other cases reported after 1980. The clinical courses were classified into 3 types: A, single attack and severe outcome; B, single attack and mild to moderate outcome; and C, recurrent attacks and various outcomes.

Results: Type A patients (n = 11) usually deteriorated quickly and severely so that early surgical treatment was not possible. Most type B patients (n = 12) did not require surgical intervention because of relatively stable courses. Only some type C patients (n = 10) are candidates for early surgery to prevent progressive deterioration. Twelve cases were unclassified because of insufficient information. We encountered 3 cases of type C, and emergency bypass surgery with parent ICA occlusion was planned in 2 patients. The surgery was successful with good prognosis in 1 patient; but the ICA and its branches were already occluded in the other patient, which precluded completion of bypass surgery and resulted in severe hemiparesis. Intraoperative findings and histologic examination of the MCA confirmed arterial dissection.

Conclusion: Young patients with intracranial ICA dissection manifesting as mild ischemic stroke should be considered for early bypass surgery with occlusion of the dissected ICA if any sign of progression or recurrence occurs after the onset.

© 2008 Elsevier Inc. All rights reserved.

Keywords:

Bypass; Cerebral ischemia; Dissection; Intracranial carotid artery; Surgery

Abbreviations: ACA, anterior cerebral artery; CT, computed tomography; ICA, internal carotid artery; MCA, middle cerebral artery; MR, magnetic resonance; STA, superficial temporal artery.

PII of original article: S0090-3019(07)00508-3.

* Corresponding author. Department of Neurosurgery, Yamaguchi University School of Medicine, Ube, Yamaguchi 755-8505, Japan. Tel.: +81 836 22 2295; fax: +81 836 22 2294.

E-mail address: oka6617@yamaguchi-u.ac.jp (F. Oka).

0090-3019/\$ – see front matter © 2008 Elsevier Inc. All rights reserved.

doi:10.1016/j.surneu.2007.04.002

1. Introduction

Cranio-cervical arterial dissections, including dissections of the carotid and vertebrobasilar systems in the cervical or intracranial portions, are the cause of 20% to 25% of cases of ischemic stroke in young adults [4]. Intracranial ICA dissection is relatively rare but often results in severe morbidity or mortality due to cerebral infarction in young individuals [8,21]. Although early bypass surgery in selected patients with improving symptoms has been proposed

sporadically [13,20,27,28], only one case has been actually treated with early bypass surgery [13], so that the clinical application is not well defined.

We have treated 6 patients with intracranial ICA dissection manifesting as ischemic stroke at Kohnan Hospital (Sendai, Japan) since 1997. Surgery for STA-MCA bypass

Table 1
Summary of reported cases of ischemic stroke due to intracranial ICA dissection^a

No.	Author	Age	Sex	Side	Activity at onset	Treatment	Clinical type ^b	Outcome at discharge ^c
1	Grosman et al [9]	23	M	L	NM	Heparin	C	D
2	Hegedüs [11]	13	M	R	NM	Mannitol	C	D
3	Nass et al [17]	8	M	R	NM	Aspirin, dipyridamole	B	GR
4 (same patient, 14 mo later)				L	NM	Steroids, anticonvulsants	A	D
5	Farrell et al [6]	20	M	L	Tug-of-war game	Mannitol	A	D
6		31	F	R	Raking leaves	Mannitol, steroids	A	D
7	O'Connell et al [18]	16	M	L	Basketball	NM	A	D
8	Steiner et al [28]	23	F	R	Frisbee	NM	A	D
9	Kitani et al [13]	14	M	R	Physical education	Dextran	C	D
10		18	M	R	Sleeping	Anticoagulants, STA-MCA anastomosis	C	MD or GR
11	Pessin et al [22]	46	F	L	Preparing for work	ICP control	A	D
12	O'Sullivan et al [20]	17	M	L	Fight, head-buttings	NM	A	D
13	Pozzati et al [23]	15	M	L	Cross-country race	NM	B	GR
14		8	F	R	Trivial frontal injury	Steroids	B	MD or GR
15		12	M	L	Bicycle race	Aspirin	B	MD or GR
16	Schievink et al [27]	4	F	L	^d	^e	Unclassified	MD or GR
17		8	F	L	^d	^e	Unclassified	MD
18		13	M	R	^d	^e	Unclassified	D
19		15	F	L	^d	^e	Unclassified	GR
20		17	M	L	^d	^e	Unclassified	MD
21		18	F	R	^d	^e	Unclassified	GR
22	Pelkonen et al [21]	18	M	L	NM	Heparin + anticoagulants	Unclassified	MD
23		20	M	R	NM	Heparin + anticoagulants	Unclassified	GR
24		49	M	R	NM	Heparin + anticoagulants	Unclassified	MD
25		31	M	L	NM	Heparin + anticoagulants	Unclassified	GR
26		5	M	L	NM	Steroid, aspirin	Unclassified	SD
27	Rhodes et al [24]	8	F	L	Playing	NM	A	D
28	Uchino et al [30]	12	M	L	Running	NM	C	GR
29	Chaves et al [5]	28	F	R	NM	^f	B	GR
30		38	F	R	NM	^f	B	GR
31		26	F	R	NM	^f	A	MD
32		35	F	L	NM	^f	B	GR
33		20	M	R	NM	^f	C	MD
34		35	F	L	NM	^f	C	GR
35		22	M	R	NM	^f	B	MD
36		59	M	L	NM	^f	B	GR
37		15	M	R	NM	^f	B	GR
38		25	M	L	NM	^f	B	GR
39	Ahn et al [1]	60	M	R	NM	Stent insertion	Unclassified	GR
40	Present	10	F	R	Swimming	Anticoagulants, hypertension	A	SD
41		15	M	R	Running	Antiplatelets	B	MD
42		33	M	R	Unknown	Fluid maintenance	A	SD
43		14	F	R	Table tennis	Edaravone	C	SD
44		11	F	R	Physical education	Edaravone	C	SD
45		26	M	R	Taking shower	Anticoagulants + antiplatelets	C	GR

F indicates female; L, left; M, male; NM, not mentioned; R, right; GR, good recovery; MD, moderately disabled; SD, severely disabled; D, dead.

^a Inclusion criteria: nontraumatic pathology; diagnosis of dissection is made by angiography (conventional or MR angiography) or autopsy; and clinical symptoms and outcome were described.

^b Clinical types are divided into 3 groups: A, single attack and severe outcome (cannot walk); B, single attack and mild to moderate outcome (can walk); and C, recurrent attack and various outcomes.

^c Glasgow Outcome Scale. In patients whose Glasgow Outcome Scale has not been mentioned, the present authors speculated if possible from the available information.

^d Among the 6 patients, 3 had onset during volleyball, tennis, or water skiing.

^e Among the 6 patients, 3 were treated with antiplatelet agents and 3 with only supportive measures.

^f Among the 10 patients, 6 were treated with anticoagulants, 3 with antiplatelet agents, and 1 with steroids.

with parent artery occlusion was planned in the acute stage for 2 patients. The surgery was successful in 1 of these patients and resulted in a good outcome. Here we discuss our 6 cases and 39 other reported cases with special reference to the role of early surgical treatment.

2. Clinical materials and methods

Inpatient records and conventional angiography reports at Kohnan Hospital since 1997 were reviewed systematically to identify patients who presented with sudden ischemic symptoms and had angiographic findings consistent with dissection of the intracranial ICA. Angiographic criteria included double lumen sign, intimal flap, stenosis with dilatation (pearl-and-string sign), dilatation without stenosis, stenosis without dilatation (string sign), and tapering occlusion [19]. Both conventional and MR angiography findings were considered valid as long as the quality was satisfactory.

A MEDLINE search was carried out to identify reports after 1980 of patients with intracranial ICA dissection manifesting as ischemic symptoms. Patients were included in the current analysis if nontraumatic pathology and the main clinical symptoms, angiographic (either conventional or MR) findings, and clinical outcomes were described. Demographic data, activity at onset, initial

treatment, clinical type, and outcome at discharge were tabulated. The clinical courses were classified into 3 types: A, single attack and severe outcome; B, single attack and mild to moderate outcome; and C, recurrent attacks and various outcomes.

3. Results

Six patients were identified from the inpatient records at Kohnan Hospital and 39 from the literature [1,5,6,9,11,13,17,18,20–24,27,28,30] (Table 1). There were 27 males and 18 females, with age ranging from 4 to 60 years (mean age, 21.4 years). The lesion was in the right hemisphere in 24 and in the left hemisphere in 21.

Two patients had a history of contralateral intracranial arterial dissection (cases 4 and 16). At least 20 of the 24 patients for whom there was a detailed description had an onset during some physical activity (mainly sports). Of our 6 patients, 5 had the onset during activity, during sports in 4 patients, and while taking a shower in 1 patient (Table 1).

The predominant prehospital course was sudden headache (usually 1-sided) followed by focal neurologic deficits including hemiparesis (usually contralateral to the side of headache) within minutes to hours. Symptoms on admission were mild to severe, probably depending on the site and size of the ischemic lesion and the degree of residual cerebral

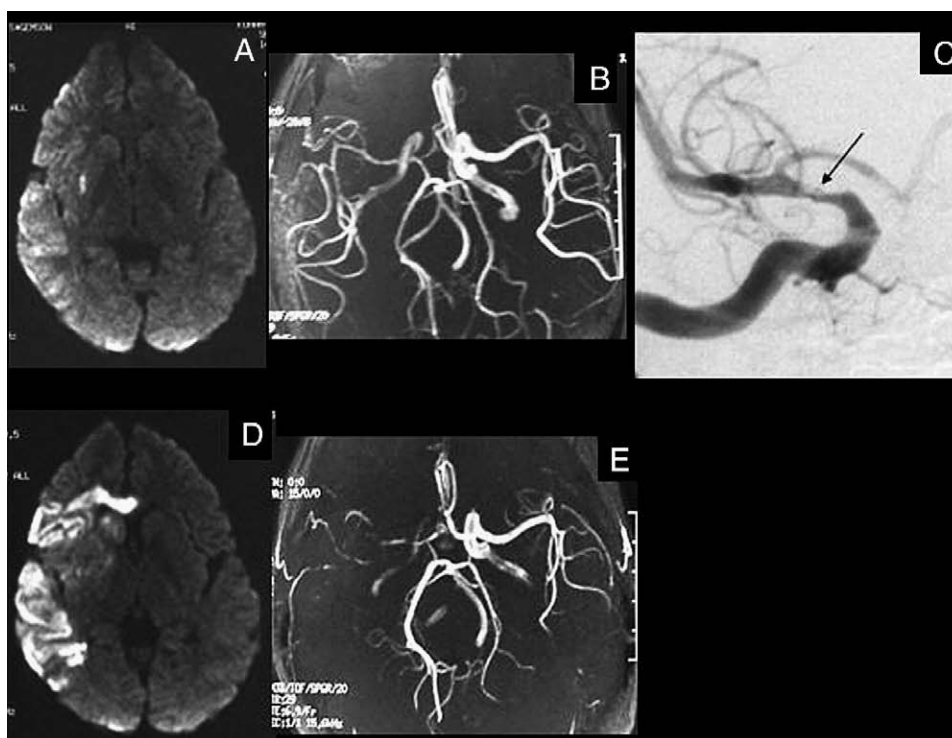


Fig. 1. Images from case 43. Diffusion-weighted MR image (A) and MR angiogram (B), both obtained 2 hours after onset. Multiple infarctions are seen in the right MCA territory (A). Stenosis is present in the right ICA filled through the MCA (B). C: Conventional right carotid angiogram obtained just after the MR study showing stenosis with “double lumen” sign (arrow) at the supraclinoid portion of the right ICA and mild stenosis in the M1 segment of the right MCA. Diffusion-weighted MR image (D) and MR angiogram (E), both obtained on the 10th day after the onset. Right ICA and MCA are severely stenotic but patent.

blood flow. Hemiparesis was present in 41 patients and consciousness disturbance in 17 (data not shown).

Conventional or MR angiography showed intracranial ICA steno-occlusive lesions at the supraclinoid portion in all reported cases leading to a diagnosis of dissection. In our patients, conventional angiographic findings compatible with dissection included double lumen ($n = 1$), tapering occlusion ($n = 1$), and stenosis with dilatation or a pearl-and-string sign ($n = 4$). Stenotic lesions continued into the MCA and/or ACA in 2 patients. Angiography or MR angiography revealed branch occlusion of the MCA or ACA in 3 patients, suggesting an embolism distal to the dissection.

Medical treatments in the acute stage varied, and there was no consensus regarding the use of anticoagulant or antiplatelet agents as shown in Table 1. Our patients were initially treated conservatively with anticoagulation therapy using argatroban ($n = 1$), antiplatelet agents ($n = 1$), both anticoagulation and antiplatelet agents ($n = 1$), the free radical scavenger edaravone ($n = 2$), or fluid maintenance therapy only ($n = 1$). Three of our patients (cases 40–42) did

not deteriorate significantly after admission, but moderate to severe neurologic deficits persisted as a result of the initial attack without recurrent attacks. Our other 3 patients (cases 43–45) had sudden aggravations after 7 to 15 days of uneventful acute course after the first attack due to recurrent attacks as determined by clinical and imaging findings.

Emergency STA-MCA bypass and proximal occlusion of the ICA were attempted in cases 43 and 45 (see representative cases). Surgery was not performed in case 44 because the existing cerebral infarction was relatively large. There is only one report in the literature of a single patient treated surgically with STA-MCA bypass with favorable outcome [13]. Parent artery occlusion was not performed because its role was not clear at that time.

Clinical outcome at discharge (Glasgow Outcome Scale) was good recovery in 16 patients, moderately disabled in 8, good recovery or moderately disabled in 4, and severely disabled in 5. Twelve patients died. Of our 6 patients, 4 had severe left hemiparesis and were dependent, and 1 had moderate left hemiparesis but was independent. Only 1

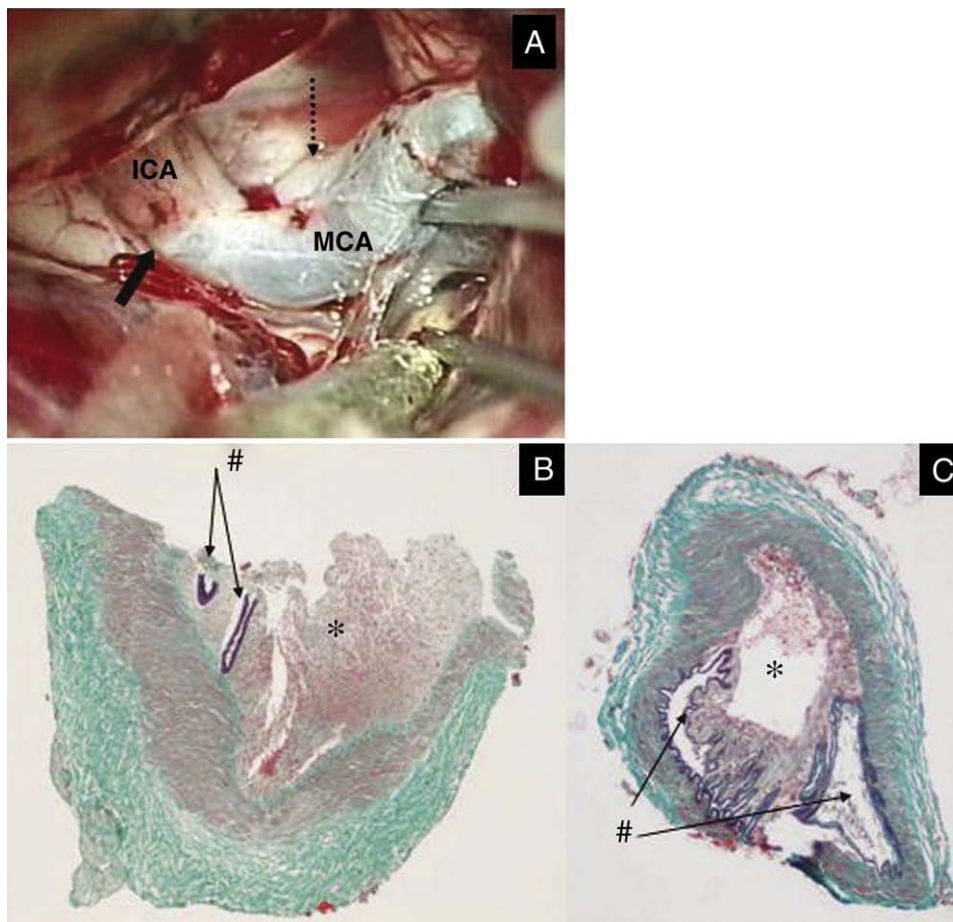


Fig. 2. Images from case 43. A: Intraoperative photograph taken at the second surgery for internal and external decompression. The right ICA dissection is an abrupt discoloration at the supraclinoid portion (thick arrow). The distal ICA and MCA have extensive thromboses through M4. Dashed arrow indicates posterior communicating artery. Photomicrographs of the histologic specimens from M1 (B) and M4 (C) showing typical fresh dissection causing the occlusion. The narrowed true lumen (number sign) and the pseudolumen (asterisk) are filled with fresh thrombus (Elastica-Masson staining [modified Masson trichrome staining], original magnification $\times 20$).

patient (case 45) who underwent successful early surgery returned home with no deficit (Table 1).

4. Representative cases

4.1. Case 43

A 14-year-old girl complained of sudden headache in the right temporal region while playing table tennis. A few minutes later, she became drowsy and unable to move her left arm and leg. On admission to a nearby hospital, she had moderate left hemiparesis including facial weakness. She was somnolent with conjugate eye deviation to the right but was able to speak. Computed tomography taken 1 hour after the onset showed no abnormalities. Diffusion-weighted MR imaging performed 1 hour after CT showed sporadic hyperintensity lesions in the right cerebral cortex and the right basal ganglia, and MR angiography revealed intracranial ICA stenosis (Fig. 1A and B). During these examinations, her neurologic deficits improved gradually. The patient was transferred to our hospital 3 hours after the onset. She had no consciousness disturbance and only mild left hemiparesis. Right carotid angiography demonstrated stenosis with “double lumen” sign at the supraclinoid portion of

the right ICA with some stenosis in the M1 segment of the right MCA (Fig. 1C).

After admission, her course was satisfactory with conservative therapy including edaravone, a free radical scavenger. She became alert and the left hemiparesis resolved completely by the third day. However, she suddenly complained of severe right-sided headache again on the 10th hospital day. She was treated with analgesics. Left hemiparesis and consciousness disturbance developed gradually during observation for a few hours. Diffusion-weighted MR imaging showed enlargement of the infarction, and MR angiography disclosed aggravation of the stenosis of the right ICA (Fig. 1D and E). She was transferred to an operating room for emergency STA-MCA bypass surgery 6 hours after onset of the second headache and 1.5 hours after the left hemiparesis became evident. However, the right ICA (abrupt discoloration at the supraclinoid portion) and the MCA (from M1 to M4) had extensive thromboses so bypass was not possible (Fig. 2A).

Three days later, external and internal decompression surgery was needed to manage severe brain edema associated with the right cerebral hemispheric infarction. Samples for histology from the right M1 and M4 were collected after obtaining informed consent from the parents.

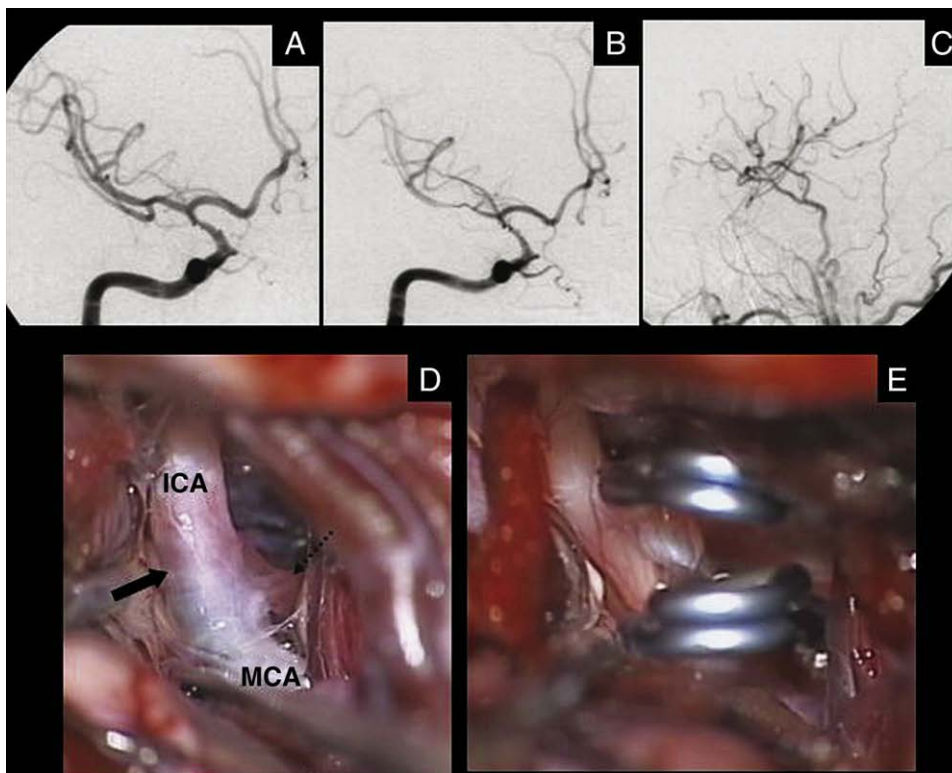


Fig. 3. Images from case 45. A: Right internal carotid angiogram taken 5 hours after onset showing irregular stenosis (pearl-and-string sign) at the supraclinoid portion of the right ICA. B: Right internal carotid angiogram taken 15 days after onset, showing aggravated wall irregularity and tapered stenosis at the supraclinoid ICA and steno-occlusive lesions in the MCA. C: Right external carotid angiogram taken 1 week after the right STA-MCA bypass surgery showing good patency of the bypass and occluded right ICA. D and E: Intraoperative photographs showing abrupt discoloration at the supraclinoid portion of the right ICA (thick arrow, D) and occlusion of the supraclinoid ICA with 2 titanium clips (E). The clips were applied proximal to the posterior communicating artery (dashed arrow) including the site of abrupt discoloration.

Both specimens were compatible with arterial dissection (Fig. 2B and C), suggesting that dissection had started at the supraclinoid portion of the ICA and propagated as far as the M4. She had moderate consciousness disturbance for a while but finally became fully conscious with severe left hemiparesis and was transferred to another hospital in a wheelchair for further rehabilitation.

4.2. Case 45

A 26-year-old man had sudden headache in the right temporal region while taking a shower. A few minutes later, he was unable to move his left arm and leg. He was alert but had severe left hemiparesis by the time he reached a nearby hospital 1 hour later. He was transferred to our hospital 3 hours after the onset. On admission he was alert with only slight left hemiparesis. Initial diffusion-weighted MR imaging showed a few small hyperintense lesions in the right cerebral cortex and white matter. Magnetic resonance angiography and right carotid angiography demonstrated wall irregularity and tapered stenosis of the right ICA at the supraclinoid portion (Fig. 3A). His left hemiparesis fully resolved during the first hospital day. He was treated with antiplatelet and anticoagulation therapy, and the clinical course was uneventful. However, on the 15th day, he suddenly noticed slight numbness in his left arm when he held his breath. Immediate MR angiography and right carotid angiography demonstrated aggravation of the right ICA stenosis (Fig. 3B). Diffusion-weighted MR imaging showed no new infarction.

To prevent further aggravation of dissection, we performed emergency surgery for therapeutic occlusion of the right ICA at the site of dissection after double STA-MCA anastomosis. During surgery, abrupt discoloration of the ICA at the supraclinoid portion compatible with dissection was confirmed (Fig. 3D and E). The MCA appeared normal in spite of poor opacification on angiography. Blood pressure was controlled carefully to prevent possible hyperperfusion, and the postoperative course was smooth. Follow-up angiography 1 week after surgery showed good patency of the STA-MCA bypass (Fig. 3C). He was discharged with no neurologic deficit.

5. Discussion

As reported previously, intracranial ICA dissections generally occur in younger patients [2,7]. Of the 45 patients whose records we reviewed, 25 were younger than 18 years and the mean age was 21.4 years old. This age range is much younger than that of patients with extracranial ICA or vertebrobasilar artery dissections, which is usually between 30 and 50 years, with a mean of approximately 40 years [14,26].

Poor outcome after intracranial ICA dissection has been reported previously. Fullerton et al [7] reported high mortality (as high as 51%) in children younger than 18 years. We found the mortality among reported cases of

intracranial ICA dissection after 1980 to be 30%. However, in some recent reports, the outcome of these patients has been significantly better [5,21,27]. This probably is due to the early correct diagnosis of this disease based on improved diagnostic methods, especially in patients with mild symptoms. In our patients, there were no deaths; however, 4 of 6 patients had severe neurologic deficits at discharge. Although intracranial ICA dissection can have a better prognosis than previously thought, it is still a catastrophic disease for young individuals.

The utility of anticoagulation and antiplatelet agents in the treatment of patients with intracranial ICA dissection with ischemic onset remains unclear. Some authors reported good prognosis with anticoagulation or antiplatelet therapy [5,21]. However, there are several reports showing that intracranial dissection with ischemic onset may bleed at the next attack [16,25,29].

Although some authors have advocated extracranial-intracranial arterial bypass [9,13,20,27,28], there has been only one patient who underwent the surgery in the acute stage [13]. We planned the surgery for STA-MCA bypass with parent artery occlusion in 2 patients and successfully accomplished it in one of these. Case 45 illustrates that early surgery for occlusion of the dissecting parent artery after STA-MCA bypass is an effective treatment. Case 43 confirmed that the dissection extended from the ICA to the distal MCA within only a few hours. We suggest that surgical intervention should include both revascularization by bypass and occlusion of the parent artery at the site of dissection to prevent distal extension of the dissection.

From the surgical point of view, it is important to identify patients who have recurrent attacks after mild to moderate initial events. Therefore, we classified the reported cases into 3 types. As shown in Table 1, 11 cases were classified as type A, 12 as type B, 10 as type C, and 12 were unclassified because of insufficient information. For type A patients, no conservative treatments have been effective and the opportunity for surgical treatment may be limited. Only patients admitted before the development of significant cerebral infarction are candidates for emergency surgery using either bypass or intravascular techniques. Type B patients respond well to conservative treatment and do not require surgical treatment. Type C patients should be regarded with caution because timely surgical treatment may influence the prognosis significantly. Case 43 may have had a better outcome if the bypass surgery had been attempted immediately after the second attack of headache.

Recently, endovascular interventions such as stenting and internal trapping have been one of the important treatment options for extracranial carotid and intracranial vertebral artery dissections [3,8,10,12,15,31]. Although there has been only 1 patient with intracranial ICA dissection who underwent successful endovascular treatment with stent placement [1], this treatment may be a good option for type C patients.

To decide the management plan, it is important to discriminate types B and C as early as possible, although we found no definitive way to do so based on the current information. Close observation for any clinical symptoms, including headache and temporary neurologic deficits, and repeated noninvasive studies, such as MR angiography every few days, for the first 2 weeks after the onset seem mandatory in possible type B or C patients. If there is any clinical recurrence (even only headache) or aggravation in imaging studies (aggravation of ICA dissection or recurrence of infarction), we recommend that STA-MCA bypass with occlusion of the dissecting ICA be considered as soon as possible.

6. Conclusion

Early surgical treatment should be considered for patients with intracranial ICA dissection manifesting as mild ischemic symptoms if there is any sign of recurrence or progression after the onset.

References

- [1] Ahn JY, Chung SS, Lee BH, et al. Treatment of spontaneous arterial dissections with stent placement for preservation of the parent artery. *Acta Neurochir (Wien)* 2005;147:265-73.
- [2] Bassetti C, Bogousslavsky J, Eskenasy-Cottier AC, et al. Spontaneous intracranial dissection in the anterior circulation. *Cerebrovasc Dis* 1994;4:170-4.
- [3] Bejjani GK, Monsein LH, Laird JR, et al. Treatment of symptomatic cervical carotid dissections with endovascular stents. *Neurosurgery* 1999;44:755-61.
- [4] Chabrier S, Lasjaunias P, Husson B, et al. Ischaemic stroke from dissection of the craniocervical arteries in childhood: report of 12 patients. *Eur J Paediatr Neurol* 2003;27:39-42.
- [5] Chaves C, Estol C, Esnaola MM, et al. Spontaneous intracranial internal carotid artery dissection: report of 10 patients. *Arch Neurol* 2002;59:977-81.
- [6] Farrell MA, Gilbert JJ, Kaufmann JC. Fatal intracranial arterial dissection: clinical pathological correlation. *J Neurol Neurosurg Psychiatry* 1985;48:111-21.
- [7] Fullerton HJ, Johnston SC, Smith WS. Arterial dissection and stroke in children. *Neurology* 2001;57:1155-60.
- [8] Gomez CR, May AK, Terry JB, et al. Endovascular therapy for traumatic injuries of the extracranial cerebral arteries. *Crit Care Clin* 1999;15:789-809.
- [9] Grosman H, Fornasier VL, Bonder D, et al. Dissecting aneurysm of the cerebral arteries. Case report. *J Neurosurg* 1980;53:693-7.
- [10] Halbach VV, Higashida RT, Dowd CF, et al. Endovascular treatment of vertebral artery dissections and pseudoaneurysms. *J Neurosurg* 1993;79:183-91.
- [11] Hegedüs K. Dissecting intracranial aneurysm. *Arch Psychiatr Nervenkr* 1982;232:25-32.
- [12] Iihara K, Sakai N, Murano K, et al. Dissecting aneurysm of the vertebral artery: a management strategy. *J Neurosurg* 2002;97:259-67.
- [13] Kitani R, Itouji T, Noda Y, et al. Dissecting aneurysms of the anterior circle of Willis arteries: report of two cases. *J Neurosurg* 1987;67:296-300.
- [14] Leys D, Moulin T, Stojkovic T, et al. Follow-up of patients with history of cervical artery dissection. *Cerebrovasc Dis* 1995;5:43-9.
- [15] Malek AM, Higashida RT, Phatouros CC, et al. Endovascular management of extracranial carotid artery dissection achieved using stent angioplasty. *AJNR Am J Neuroradiol* 2000;21:1280-92.
- [16] Naito I, Iwai T, Sasaki T. Management of intracranial vertebral artery dissections initially presenting without subarachnoid hemorrhage. *Neurosurgery* 2002;51:930-8.
- [17] Nass R, Hays A, Chutorian A. Intracranial dissecting aneurysm in childhood. *Stroke* 1982;13:204-7.
- [18] O'Connell BK, Towfighi J, Brennan RW, et al. Dissecting aneurysms of head and neck. *Neurology* 1985;35:993-7.
- [19] Ohkuma H, Suzuki S, Ogane K. Dissecting aneurysms of intracranial carotid circulation. *Stroke* 2002;33:941-7.
- [20] O'Sullivan RM, Robertson WD, Nugent RA, et al. Supraclinoid carotid artery dissection following unusual trauma. *AJNR Am J Neuroradiol* 1990;11:1150-2.
- [21] Pelkonen O, Tikkakoski T, Leionen S, et al. Intracranial arterial dissection. *Neuroradiology* 1998;40:442-7.
- [22] Pessin MS, Adelman LS, Barbas NR. Spontaneous intracranial carotid artery dissection. *Stroke* 1989;20:1100-3.
- [23] Pozzati E, Galassi E, Godano U, et al. Regressing intracranial carotid occlusion in childhood. *Pediatr Neurosurg* 1994;21:243-7.
- [24] Rhodes RH, Phillips S, Booth FA, et al. Dissecting hematoma of intracranial internal carotid artery in an 8-year-old girl. *Can J Neurol Sci* 2001;28:357-64.
- [25] Sagoh M, Hirose Y, Murakami H, et al. Late hemorrhage from persistent pseudoaneurysm in vertebral artery dissection presenting with ischemia: a case report. *Surg Neurol* 1999;52:480-4.
- [26] Scievink WI, Mokri B, O'Fallon WM. Recurrent spontaneous cervical-artery dissection. *N Engl J Med* 1994;330:393-7.
- [27] Schievink WI, Mokri B, Piepgras DG. Spontaneous dissections of cervicocephalic arteries in childhood and adolescence. *Neurology* 1994;44:1607-12.
- [28] Steiner H, Lammer J, Kleinert R, et al. Dissection aneurysm of cerebral arteries in congenital vascular deficiency. *Neuroradiology* 1986;28:331-4.
- [29] Tsutsumi M, Kawano T, Kawaguchi T, et al. Dissecting aneurysm of the vertebral artery causing subarachnoid hemorrhage after non-hemorrhagic infarction: a case report. *Neurol Med Chir (Tokyo)* 2000;40:628-31.
- [30] Uchino A, Sawada A, Takase Y, et al. Supraclinoid carotid dissection in a pediatric patient. *Clin Imaging* 2001;25:385-7.
- [31] Yamaura I, Tani E, Yokota M, et al. Endovascular treatment of ruptured dissecting aneurysms aimed at occlusion of the dissected site by using Guglielmi detachable coils. *J Neurosurg* 1999;90:853-6.

Commentary

Cerebral infarction in the young population is rare. Intracranial ICA dissection is one of the various causes of such ischemic disease. In this study, the authors reported 6 original cases, which were analyzed together with reported cases in the literature. In this excellent summary of cases, they showed that this disease is most prevalent in younger patients (21.4 years), compared with vertebral artery dissection, and carries a high risk of severe neurologic deficits or mortality (30%–40%). In their original series of 6 patients, the authors tried 2 emergency operations and successfully conducted STA-MCA bypass with ICA occlusion in one. Based on these observations, the authors recommended emergency bypass for patients with recurrent attack.