

## Endovascular Trapping of a Vertebral Artery Segment to Control PICA Origin Tearing

Thanh N. Nguyen, MD, Daniel Roy, MD, Francois Guilbert, MD, Jean Raymond, MD, Alain Weill, MD

From the Department of Neurology, Neurosurgery, and Radiology, Boston University Medical Center, Boston, MA (TNN); Department of Radiology, Centre Hospitalier de l'Université de Montréal, Notre-Dame Hospital, Montreal, Quebec, Canada (DR, FG, JR, AW).

### ABSTRACT

Iatrogenic perforation or rupture during aneurysm coiling can be difficult to manage and may lead to fatal bleeding. We describe a lifesaving technique of isolating the subarachnoid segment of the vertebral artery using two balloons to trap flow to a ruptured PICA aneurysm allowing time to coil the parent artery with the aneurysm.

### CASE

A 58-year-old woman presented with Hunt Hess Grade 3 subarachnoid hemorrhage due to a 3 mm left PICA aneurysm. During placement of the first coil, aneurysm perforation was noted. Despite conventional measures to manage the perforation (anticoagulation reversal, balloon inflation, placement of a second coil, and ventricular drain), contrast extravasation persisted after 45 minutes. A second balloon was positioned via the right vertebral artery at the right vertebrobasilar junction and inflated. The first balloon was pulled back, inflated, allowing trapping of the ruptured site. The aneurysm and adjacent vertebral segment were rapidly coiled to occlude the ruptured site under local flow arrest. The patient awoke with dysarthria, left-sided hemiparesis and dysphagia.

### CONCLUSION

Trapping an arterial segment with two balloons may help in the management of PICA origin aneurysm perforation refractory to medical and current endovascular strategies. This technique, while potentially lifesaving, may engender ischemic complications.

### Introduction

Hemorrhagic complications during endovascular therapy occur in 4% of ruptured aneurysms and are associated with neurological disability and mortality in approximately one-third.<sup>1</sup> The clinical repercussions may be more significant with perforations caused by coils and microcatheters, compared to microguidewires.<sup>1</sup> A ruptured aneurysm state and small aneurysm size are risk factors for perforation.<sup>2</sup> Immediate endovascular management of aneurysm perforation has been reported using adjacent balloon inflation<sup>3</sup>, additional coils<sup>4-6</sup> and a second microcatheter.<sup>7,8</sup>

We describe use of two balloons to trap an arterial segment of the vertebral artery in the management of a posterior inferior cerebellar artery (PICA) aneurysm, which demonstrated ongoing extravasation despite protamine therapy, placement of additional coils and single balloon hemostasis.

### Case

A 58-year-old woman with hypothyroidism and pernicious anemia presented with Hunt Hess Grade 3 subarachnoid hemorrhage with decreased level of consciousness and left sided hemiparesis. A right 8 × 7 mm carotid-ophthalmic aneurysm was thought to be responsible for the hemorrhage. An attempt to

clip this lesion was unsuccessful. The patient was transferred to our Center for Endovascular Management.

Cerebral angiography revealed, in addition to the right carotid-ophthalmic aneurysm, a 3 mm left PICA origin aneurysm (Fig 1A, B). Due to the clear preponderance of blood in the left cerebellar-pontine angle on the initial CT scan, it was felt that the left PICA aneurysm was responsible for the hemorrhage and ought to be treated first.

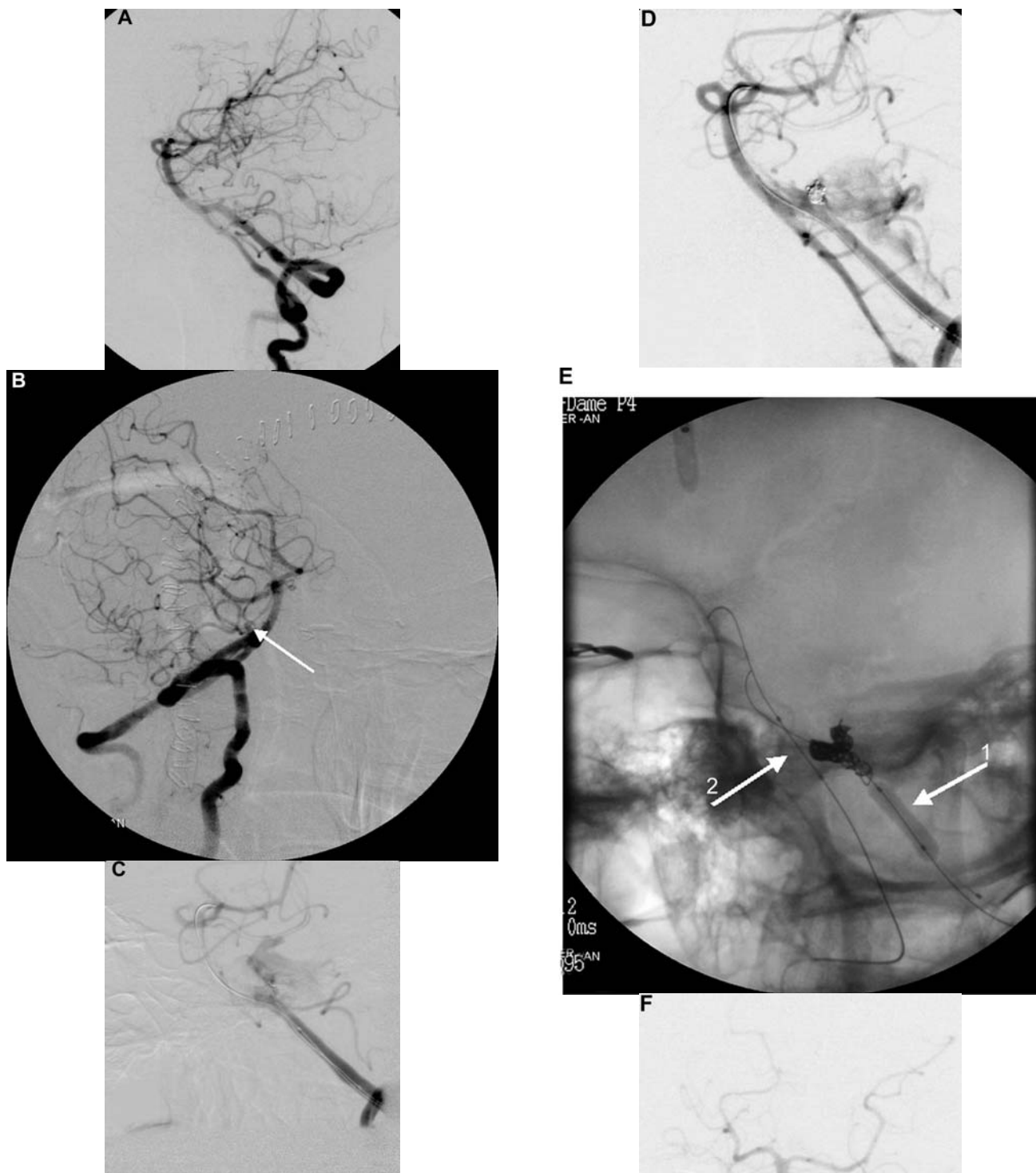
The procedure was performed under general anesthesia. After placement of a 6F femoral sheath, systemic heparin was administered. A 4 × 10 mm Hyperglide balloon (MicroTherapeutics, Irvine, CA) was mounted in the left vertebral artery adjacent to the left PICA aneurysm as a safety measure for hemostasis in case of procedural perforation. The aneurysm was catheterized using a Rebar-10 microcatheter (MicroTherapeutics, Irvine, CA). During placement of the first Guglielmi detachable coil (GDC soft, 3 mm × 4 cm, Boston Scientific, Natick, MA) aneurysm perforation was noted (Fig 1C) with transient elevation of systolic blood pressure from 100 to 170 mm Hg, and bradycardia to a pulse of 40. This was immediately controlled by balloon inflation, administration of protamine 50 mg, mannitol, thiopental, and hyperventilation. A second coil (GDC soft, 2 mm × 8 cm) was inserted while keeping the balloon inflated.

**Keywords:** Aneurysm, endovascular treatment, vertebral artery, complication, perforation.

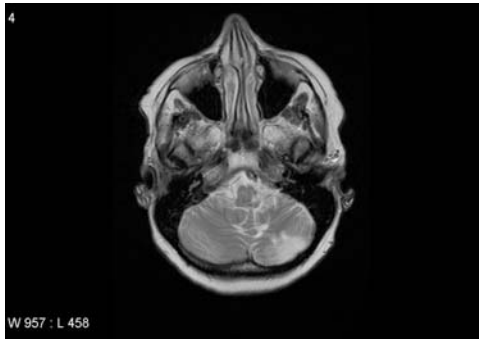
**Acceptance:** Received August 27, 2007. Accepted for publication August 27, 2007.

**Correspondence:** Address correspondence to Alain Weill, MD, Associate Professor, Department of Radiology, Notre Dame Hospital, 1560 Sherbrooke Street East Montreal, Quebec H2L 4M1. E-mail: alain.weill.chum@ssss.gouv.qc.ca

J Neuroimaging 2008;18:418-421.  
DOI: 10.1111/j.1552-6569.2007.00195.x



**Fig 1.** Cerebral angiograms during embolization of a ruptured PICA artery origin aneurysm. (A) Left and (B) right anterior oblique views of the left vertebral artery demonstrating the left 3mm PICA artery origin aneurysm (arrow, b); (C) Contrast extravasation noted following placement of the first coil; (D) persistent contrast extravasation following placement of the second coil; (E) coiling of the left vertebral V4 segment using two balloons to isolate the ruptured site, with the first balloon (arrow, 1) placed in proximal left V4, and second balloon placed (arrow, 2) at the vertebrobasilar junction through the right vertebral artery; (F) control angiogram showing good flow in the right vertebral, basilar artery, without retrograde opacification toward the rupture site.



**Fig 2.** T2 MRI 2 months postembolization with hyperintensities in the left dorsolateral medulla and cerebellum.

The balloon was deflated after 7 minutes and contrast extravasation was again noted (Fig 1D). The balloon was reinflated to arrest bleeding. An emergent ventriculostomy was placed in the angiosuite due to the change in vital signs suggestive of raised intracranial pressure. The drain was successfully placed by a right frontal approach. After 45 minutes, the balloon facing the aneurysm in the left vertebral artery was deflated, but an angiographic run continued to show contrast extravasation.

A second 4 × 10 mm Hyperglide balloon (MicroTherapeutics, Irvine, CA) was positioned via the contralateral vertebral artery at the right vertebrobasilar junction and inflated. The first balloon was deflated, slightly pulled back, and rapidly reinflated in the left V4 segment, proximal to the origin of the left PICA. This allowed flow trapping of the ruptured site.

Between the two occlusions, this isolated segment was coiled rapidly and sacrificed using the microcatheter already positioned for the aneurysm treatment. A total of 75 cm of platinum was deployed with GDC soft coils (Boston Scientific, Natick, MA) ranging in size from 2 to 5 mm (Fig 1E). Control angiography at the end of the procedure revealed good flow through the right vertebral and basilar arteries, and occlusion of the left V4 segment at the rupture site (Fig 1F).

The patient awoke with dysarthria, persistent 4/5 left hemiparesis, left hypoesthesia, and dysphagia. A head CT revealed higher density of subarachnoid hemorrhage in the basal cisterns diffusely, and no increase in ventricular size. The patient was discharged to rehabilitation 2 weeks after hospitalization, with improvement of her neurological status.

At follow-up, MRI obtained 2 months later revealed punctate ischemia in the left cerebellum and left medulla (Fig 2). At 6-month clinical follow-up, the patient had good recovery of the left hemiparesis, with a modified Rankin scale of 1. She continues with left sided hemisensory loss and mild gait ataxia.

## Discussion

We report a case with continued contrast extravasation refractory to medical reversal of anticoagulation, placement of a second coil, and a 45-minute period of balloon inflation in the parent artery. Because the aneurysm was small and chance of per coiling rupture high, surgical ligation was considered. However, due to the fact that the patient already had a recent craniotomy on the opposite side, the decision was to treat this

aneurysm by an endovascular route. A balloon was strategically positioned prior to coiling not for remodeling, but as a hemostatic adjunct given the known risk in such a small aneurysm. However, despite three attempts of balloon deflation over a 45-minute period, there was continued contrast extravasation. The prolonged balloon inflation in the left vertebral artery was relatively permissible because of the presence of a right vertebral artery providing flow to the basilar artery.

The diffuse relentless extravasation of contrast led us to believe that the tear not only compromised the fragile dome of the aneurysmal wall, but perhaps extended to the neck or even the parent artery carrying the aneurysm. Hence, it was felt that sacrifice of the V4 segment of this left vertebral artery segment and PICA origin with coils was indicated. Flow trapping in the parent artery to occlude the ruptured site was felt to be the most secure step. This was performed by placement and inflation of a second balloon at the right vertebrobasilar artery junction to control backflow, followed by brief deflation of the first balloon and reinflation proximal to the ruptured segment to control ascending flow. The ruptured segment was coiled thereafter with the microcatheter left in place. One balloon would not have protected the patient from extravasation because the balloon would have to be removed from the ruptured site to allow coiling of this segment. Ischemia of the left PICA artery distribution and potential V4 perforating branch arteries was anticipated.

To our knowledge, the strategy of isolating a ruptured intradural segment artery between two balloons has not been described before. This technique could apply to the ophthalmic segment of the carotid artery, if there is a posterior communicating artery large enough to allow navigation of a second balloon. Alternatives to management of this perforation include surgical repair of the artery, while keeping the balloon inflated en route to the operating room.

## Conclusion

Arterial trapping of an arterial segment using two balloons is a strategy that may be helpful to allow time to sacrifice the parent artery and the aneurysm when hemorrhagic complications are refractory to medical and current endovascular strategies. This technique, while potentially lifesaving, may engender ischemic complications.

## References

1. Cloft HJ, Kallmes DF. Cerebral aneurysm perforations complicating therapy with Guglielmi detachable coils: a meta-analysis. *AJNR Am J Neuroradiol* 2002;23:1706-1709.
2. Sluzewski M, Bosch JA, van Rooij WJ, Nijssen PC, Wijnalda D. Rupture of intracranial aneurysms during treatment with Guglielmi detachable coils: incidence, outcome, and risk factors. *J Neurosurg* 2001;94:238-240
3. Phatouros CC, Halbach VV, Malek AM, Dowd CF, Higashida RT. Simultaneous subarachnoid hemorrhage and carotid cavernous fistula after rupture of a paraclinoid aneurysm during balloon-assisted coil embolization. *AJNR* 1999;20:1100-1102.
4. Doerfler A, Wanke I, Egelhof T, Dietrich U, Asgari S, Stolke D, Forsting M. Aneurysmal rupture during embolization with Guglielmi Detachable Coils: causes, management and outcome. *AJNR* 2001;22:1825-1832.

5. Halbach VV, Higashida RT, Dowd CF, Barnwell SL, Hieshima GB. Management of vascular perforations that occur during neurointerventional procedures. *AJNR* 1991;12:319-327.
6. McDougall CG, Halbach VV, Dowd CF, Higashida RT, Larsen DW, Hieshima GB. Causes and management of aneurysmal hemorrhage occurring during embolization with Guglielmi detachable coils. *J Neurosurg* 1998;89:87-92.
7. Hirai T, Suginozawa K, Uemura S, Hamada J, Korogi Y, Takahashi M. Management of aneurysm perforation during Guglielmi electrodetachable coil placement. (Letter). *AJNR* 2000; 23: 738-739.
8. Willinsky R, terBrugge K. Use of a second microcatheter in the management of perforation during endovascular treatment of a cerebral aneurysm. *AJNR* 2000;21:1537-1539.