

## Leo Stent-Assisted Coil Embolization of a Giant Middle Cerebral Artery Aneurysm

Jung Yong Ahn, MD, Chang Ki Hong, MD, Sang Hyun Suh, MD, Jun Hyung Cho, MD, Yo Shik Shim, MD, Ji Soon Huh, MD

From the Department of Neurosurgery, Brain Research Institute, Yonsei University College of Medicine, Seoul, Republic of Korea (JYA, CKH, JHC, YSS); Department of Radiology, Yonsei University College of Medicine, Seoul, Republic of Korea (SHS); and Department of Neurosurgery, College of Medicine, Cheju National University Hospital, Jeju, Republic of Korea (JSH)

---

### ABSTRACT

We report a case of a 70-year-old man harboring a wide-necked thrombosed giant aneurysm of the left middle cerebral artery (MCA) on the M1 segment. The patient presented with generalized tonic-clonic seizures. A computerized tomography scan showed a calcified aneurysmal wall with perianeurysmal swelling. The aneurysm was successfully embolized using closed-cell nitinol stent-assisted coiling (Leo, BALT Co., Montmorency, France).

**Keywords:** Endovascular treatment, intracranial aneurysms, intracranial stent, middle cerebral artery.

**Acceptance:** Received August 23, 2007, and in revised form June 30, 2007. Accepted for publication October 22, 2007.

**Correspondence:** Address correspondence to Jung Yong Ahn, MD, Department of Neurosurgery, 146-92, Dogok-dong, Kangnam-gu, Seoul, 135-720, Republic of Korea. E-mail: jyahn@yumc.yonsei.ac.kr

J Neuroimaging 2008;18:332-335.  
DOI: 10.1111/j.1552-6569.2007.00221.x

### Introduction

Giant intracranial aneurysms, defined as those with a maximum diameter exceeding 2.5 cm. The natural history of these lesions, once it is diagnosed, is very unfavorable.<sup>1</sup> Giant aneurysms have a body and fundus that exceed the size of the parent artery incorporating almost invariably a significant proportion of the parent vessel either in a saccular aneurysm with wide neck or in a fusiform dilatation. Also, the disproportion between the size of the aneurysm and the parent artery may include several branches of the parent artery either in the fundus or neck of the aneurysm. These peculiarities have significant impact in both the surgical and endovascular treatment. Their location, morphological features, size, and type of associated symptoms may dictate different strategies for their appropriate treatment.

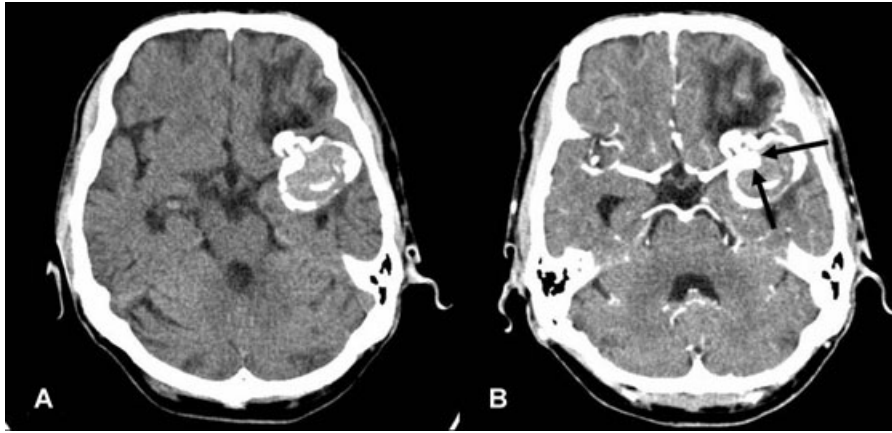
Direct surgical clipping of giant aneurysms poses substantial risks.<sup>1-3</sup> An effective and safe alternative to clipping is endovascular parent vessel occlusion, which can be preceded by bypass surgery if necessary.<sup>4-6</sup> Besides clipping and parent vessel occlusion, selective endovascular treatment with detachable coils can be considered.<sup>7,8</sup> However, the endovascular treatment of a giant aneurysm is difficult and is often associated with a high rate of complication and failure.<sup>8</sup>

Little has been published with regard to the endovascular treatment of giant middle cerebral artery (MCA) aneurysms.

Giant MCA aneurysms, which have a wide-necked, thrombosed fundus, or efferent vessels protruding from the aneurysm, may not be amenable to coil embolization. Stent-assisted coil embolization of wide-necked intracranial aneurysms using self-expanding stents is safe and effective, but technical improvements related to various mechanical difficulties during stent deployment are necessary.<sup>9-12</sup> Here, we present a case of a thrombosed MCA giant aneurysm that was successfully coiled using a new, self-expandable stent manufactured with braided nitinol wires (Leo, BALT Co., Montmorency, France).

### Case Report

A 70-year-old man with a history of hypertension presented to another hospital with generalized tonic-clonic seizures. A noncontrast computerized tomography (CT) scan of the head revealed a 3.5 × 2.8 cm sized thrombosed mass on the left temporal area with a calcified wall and surrounding edema (Fig 1A). On a contrast computerized tomography (CT) scan (Fig 1B), a residual vascular lumen in the thrombosed aneurysmal sac was noted. The initial angiogram demonstrated a residual wide-necked aneurysmal lumen of the left M1 segment (Fig 2). The patient underwent craniotomy, but aneurysmal clipping was failed due to hard calcified wall. And then, the



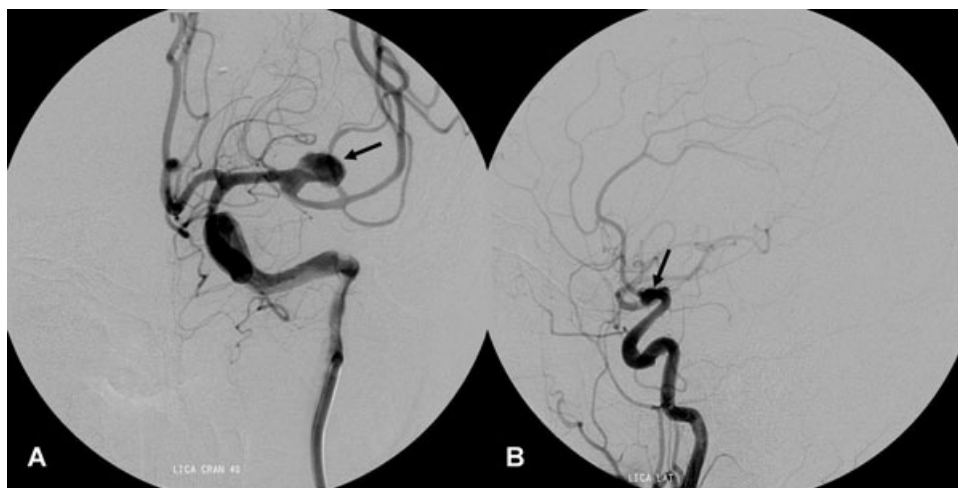
**Fig 1.** (A) A noncontrast CT scan of the head revealed a 3.5 cm × 2.8 cm sized thrombosed mass on the left temporal area with a calcified wall and surrounding edema. (B) A contrast CT scan showed a residual vascular lumen (arrows) in the thrombosed aneurysmal sac.

patient was referred to our institution for definitive treatment of the giant thrombosed aneurysm with calcified wall. The options for managing the lesion, including endovascular obliteration and surgical clip ligation with or without bypass surgery, were discussed in detail with the patient and his family. Previous surgical clipping via craniotomy were unsuccessful and the patient's age was old. In addition, the lateral lenticulostriate artery originated from the base of the wide-necked aneurysm. The patient was, therefore, scheduled for a stent-assisted coiling with preservation of the lateral lenticulostriate artery.

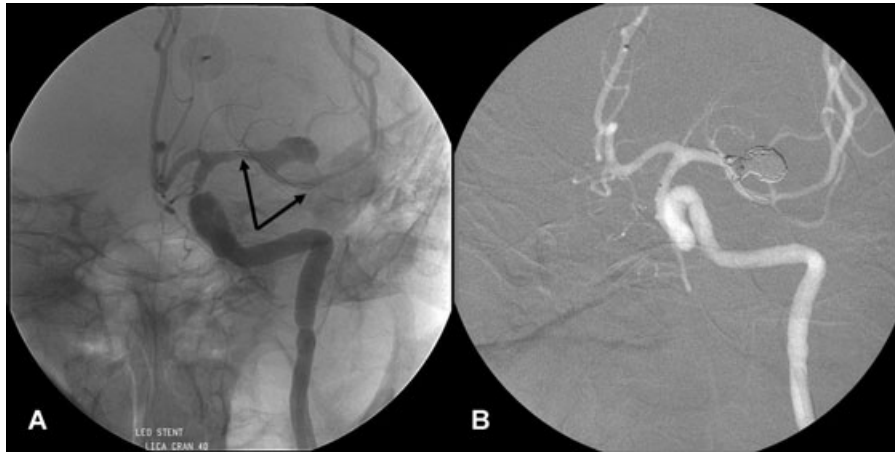
Treatment intervention was performed under general anesthesia. The patient was heparinized to an activated clotting time of 250 to 300 seconds. A 6 French Envoy guide catheter (Cordis, Johnson & Johnson, Miami, FL, USA ) was inserted into the left internal carotid artery. A microcatheter was placed first within the aneurysm lumen to allow for coil delivery. Then, the endovascular procedure consisted of stent placement across the aneurysm neck. A Vasco microcatheter (BALT Co., Montmorency, France) was positioned past the aneurysm neck by

different microguidewires (Transend 14, Target Therapeutics, Fremont, CA, USA ). A 2.5 mm/18 mm Leo self-expanding stent (BALT, Montmorency, France) was loaded into the Vasco microcatheter and gently advanced to be placed at the end of the catheter (Fig 3A). Under road-mapping guiding, the stent was deposited by slowly moving back the microcatheter while the pusher was held. Ten Matrix coils (Boston Scientific/Target Therapeutics, Fremont, CA, USA ) were then delivered into the aneurysm through the first microcatheter. Near complete obliteration of the aneurysm cavity was obtained without any compromise of distal flow (Fig 3B).

The patient was maintained on heparin for 24 hours after stent placement and coiling. Heparinization was discontinued 24 hours after treatment but was not reversed. The patient was also given a clopidogrel load of 450 mg and 325 mg of aspirin, immediately following the procedure. The postoperative course was uneventful, and the patient remained neurologically intact. He was discharged home with aspirin (100 mg) for at least 1 year, in combination with clopidogrel (75 mg) for 2 months. A



**Fig 2.** The initial angiogram (A: oblique view, B: lateral view) demonstrated a residual wide-necked aneurysmal lumen (arrow) of the left M1 segment with displacement of ipsilateral M2 segment to upward and lateral directions. The lateral lenticulostriate artery originated from the base of the aneurysm.



**Fig 3.** (A) A 2.5 mm/18 mm Leo self-expanding stent was deployed across the neck of the aneurysm in the M1 segment. Two highly radiopaque helical platinum filaments (arrows) ensured the visibility of the entire stent length. (B) Near complete obliteration of the aneurysm cavity was obtained without any compromise of distal flow.

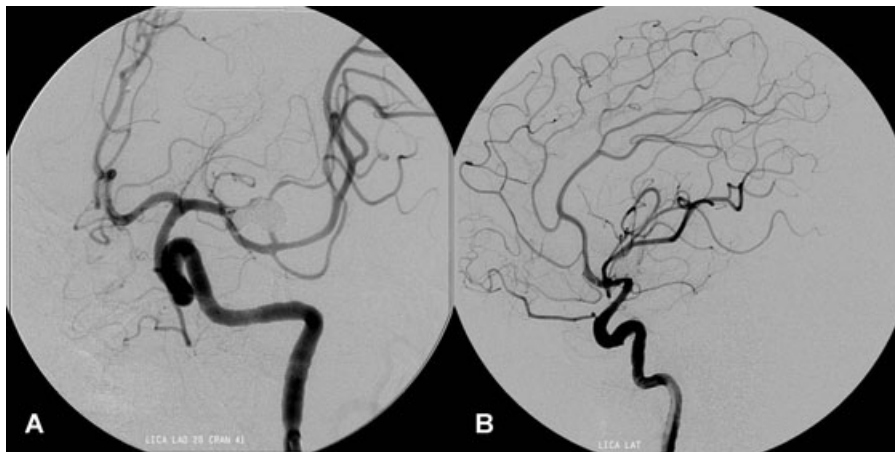
6-month follow-up angiogram (Fig 4) revealed continued obliteration of the aneurysm with patency of parent vessels. The patient's neurological status continues to remain unchanged, and there have been no more seizures.

### Discussion

This case report demonstrates the feasibility of stent-assisted coiling of a wide-necked giant M1 aneurysm. Given the patient's age, endovascular therapy was considered the primary therapeutic modality. Current techniques for the endovascular management of giant aneurysms can be grouped in two categories: deconstructive or reconstructive techniques. In our case, reconstructive procedure or bypass surgical procedures were mandatory because of poor retrograde blood flow from the anterior cerebral artery and posterior cerebral artery to the MCA.

Recently, the development of intravascular stents represents a promising advancement that may overcome important technical limitations in the endovascular therapy of giant or wide-

necked aneurysms. In an experimental study, the stent acts as a scaffold in the parent artery while coils are deposited into the aneurysmal lumen.<sup>13</sup> Experimental models have demonstrated that stent deployment promotes intraaneurysmal flow stasis,<sup>14</sup> reduces wall shear stresses,<sup>15</sup> and can prevent regrowth of the aneurysmal sac.<sup>16</sup> The latest developments have led to highly flexible, self-expanding nitinol stents, including the Neuroform, its upgraded version (Neuroform2/Treo, Boston Scientific, Fremont, CA, USA) and the Leo stent. The Neuroform has been evaluated for the endovascular treatment of wide-necked intracranial aneurysms in several series.<sup>9-12</sup> In contrast to the Neuroform stent, the Leo has a closed-cell design and is made of braided nitinol wires, giving it high radial force and homogeneous wall structure even in acute curves. Two highly radiopaque helical platinum filaments ensure the visibility of the entire stent length. Additionally, the advantage of the Leo stent is that it can be repositioned, which allows for very precise placement across the aneurysm neck.<sup>17</sup> The stent is attached to a pusher and introduced inside the lumen of the microcatheter.



**Fig 4.** A 6-month follow-up angiogram (A: oblique view, B: lateral view) revealed continued obliteration of the aneurysm with patency of parent vessels.

If the device is not correctly positioned across the aneurysm neck, the pusher allows for resheathing the repositioning. When the catheter is fully withdrawn over the pusher, the coupling wire releases, and the stent is deployed. It has been reported that the Leo stent-assisted coiling of wide-necked intracranial aneurysms is feasible and effective.<sup>17,18</sup>

Recently, Food and Drug Administration (FDA) approved Enterprise stent (Cordis Neurovascular, Miami, FL, USA), which is a new highly flexible nitinol stent designed for use in the endovascular treatment of intracranial wide-necked aneurysms.<sup>19,20</sup> The main advantage of the Enterprise stent compared with the Leo stent is its flexibility and in some situations its fixed closed cell design. Even though Leo stent has also a closed cell design, the gaps between the stent struts are not fixed and sliding between the stent struts during deployment may lead to difficulties, such as stretched stent, in arterial curves.<sup>20</sup> Thus, there may be no contact between the outer surface of the stent and the arterial wall.

Coil compaction remains a problem for giant aneurysms; subsequent treatments are very often necessary in these cases. Primary complete occlusion with coils of the aneurysmal lumen does not necessarily prevent recanalization, and therefore regrowth or rebleeding. This is especially relevant for partially thrombosed aneurysms, because the coils invariably settle into the thrombus and can cause the aneurysm to recanalize.<sup>21,22</sup> In a recent series of 31 patients with giant or very large aneurysms, Gruber et al.<sup>8</sup> reported 73.3% excellent to good recoveries after coils embolization with 13.3% procedure-related morbidity rate and a 6.7% mortality rate. However, in the angiographic follow-up, complete or almost complete occlusion was observed in only 71% of patients, and single procedure was definitive treatment for only 12.5% of the giant aneurysms. A very high 6.5% post-GDC treatment hemorrhage rate was also reported by this group. In the review of literature, the recanalization rate was approximately 55% in 164 giant aneurysms with extremely variable follow-up times.<sup>23</sup> Close angiographic follow-up is mandatory to permit the timely detection of early recanalization and of any indication for repeat coiling or other additional therapy.

Numerous challenging issues remain to be resolved in the treatment of giant aneurysms. Improvements in stent technology, specifically the development of covered stents or less porous stents with enhanced navigability into the intracranial circulation, may sufficiently alter the aneurysm inflow, which may produce complete exclusion of the circulation and thrombosis. The use of a covered stent could allow reconstruction of the vascular anatomy in a dysplastic segment of the MCA where no perforating arteries originate.<sup>24</sup>

## References

1. Drake CG. Giant intracranial aneurysms: experience with surgical treatment in 174 patients. *Clin Neurosurg* 1979;26:12-95.
2. Lawton MT, Spetzler RF. Surgical management of giant intracranial aneurysms: experience with 171 patients. *Clin Neurosurg* 1995;42:245-266.
3. Syman L, Vajda J. Surgical experience with giant intracerebral aneurysms. *J Neurosurg* 1984;61:1009-1028.
4. Fox AJ, Vinuela F, Pelz DM, Peerless SJ, Ferguson GG, Drake CG, Debrun G. Use of detachable balloons for proximal artery occlusion in the treatment of unclippable cerebral aneurysms. *J Neurosurg* 1987;66:40-46.
5. Higashida RT, Halbach VV, Dowd CF, Barnwell SL, Hieshima GB. Intracranial aneurysms: interventional neurovascular treatment with detachable balloons—results in 215 cases. *Radiology* 1991;178:663-670.
6. van Rooij WJ, Sluzewski M, Metz NH, et al. Carotid balloon occlusion for large and giant aneurysms: evaluation of a new test occlusion protocol. *Neurosurgery* 2000;47:116-122.
7. Gobin YP, Vinuela F, Gurian JH, et al. Treatment of large and giant fusiform intracranial aneurysms with Guglielmi detachable coils. *J Neurosurg* 1996;84:55-62.
8. Gruber A, Killer M, Bavinzski G, Richling B. Clinical and angiographic results of endovascular coiling treatment of giant and very large intracranial aneurysms: a 7-year, single-center experience. *Neurosurgery* 1999;45:793-804.
9. Alfke K, Straube T, Dörner L, Mehdorn HM, Jansen O. Treatment of intracranial broadneck aneurysms with a new self-expanding stent and coil embolization. *Am J Neuroradiol* 2004;25:584-591.
10. Benitez RP, Silva MT, Klem J, Veznedaroglu E, Rosenwasser RH. Endovascular occlusion of wide-necked aneurysms with a new intracranial microstent (Neuroform) and detachable coils. *Neurosurgery* 2004;54:1359-1367.
11. Fiorella D, Albuquerque F, Han P, MacDougall C. Preliminary experience using the Neuroform stent for the treatment of cerebral aneurysms. *J Neurosurg* 2004;54:6-16.
12. Lylyk P, Ferrario A, Pasbon B, Miranda C, Doroszuk G. Buenos Aires experience with the Neuroform self-expanding stent for the treatment of intracranial aneurysms. *J Neurosurg* 2005;102:235-241.
13. Szikora I, Guterman LR, Wells KM, Hopkins LN. Combined use of stents and coils to treat experimental wide-necked carotid aneurysms: preliminary results. *AJNR Am J Neuroradiol* 1994;15:1091-1102.
14. Lieber BB, Gounis MJ. The physics of endoluminal stenting in the treatment of cerebrovascular aneurysms. *Neurol Res* 2002;24(Suppl 1):S33-S42.
15. Liou TM, Liou SN, Chu KL. Intraaneurysmal flow with helix and mesh stent placement across side-wall aneurysm pore of a straight parent vessel. *J Biomech Eng* 2004;126:36-43.
16. Barath K, Cassot F, Rufenacht DA, Fasel JH. Anatomically shaped internal carotid artery aneurysm in vitro model for flow analysis to evaluate stent effect. *Am J Neuroradiol* 2004;25:1750-1759.
17. Lubicz B, Leclerc X, Levivier M, et al. Retractable self-expandable stent for endovascular treatment of wide-necked intracranial aneurysms: preliminary experience. *Neurosurgery* 2006;58:451-457.
18. Kis B, Weber W, Berlit P, Kühne D. Elective treatment of saccular and broad-necked intracranial aneurysms using a closed-cell nitinol stent (Leo). *Neurosurgery* 2006;58:443-450.
19. Higashida RT, Halbach VV, Dowd CF, Juravsky L, Meagher S. Initial clinical experience with a new self-expandable nitinol stent for the treatment of intracranial aneurysms: the Cordis Enterprise stent. *Am J Neuroradiol* 2005;26:1751-1756.
20. Weber W, Bendszus M, Kis B, et al. A new self-expanding nitinol stent (Enterprise) for the treatment of wide-necked intracranial aneurysms: initial clinical and angiographic results in 31 aneurysms. *Neuroradiology* 2007;49:555-561.
21. Ross IB, Weill A, Piotin M, Moret J. Endovascular treatment of distally located giant aneurysms. *Neurosurgery* 2000;47:1147-1153.
22. Sluzewski M, Menovsky T, van Rooij WJ, Wijnalda D. Coiling of very large or giant cerebral aneurysms: long-term clinical and serial angiographic results. *Am J Neuroradiol* 2003;24:257-262.
23. Parkinson RJ, Eddleman CS, Batjer HH, Bendok BR. Giant intracranial aneurysms: endovascular challenges. *Neurosurgery* 2006;59:S103-S112.
24. Pero G, Denegri F, Valvassori L, Boccardi E, Scialfa G. Treatment of a middle cerebral artery giant aneurysm using a covered stent. *J Neurosurg* 2006;104:965-968.