

Multiple infected cerebral hydatid cysts

R. Gana*, M. Skhissi, R. Maaqili, F. Bellakhdar

Department of Neurosurgery, Ibn Sina Hospital, Hôpital Avicenne, Sôuissi, Rabat, Morocco

Received 10 July 2006; accepted 1 November 2006

Abstract

We report an unusual patient with multiple infected cerebral hydatid cysts. A 20-year-old man presented with a 2-month history of headache and progressive left-sided hemiparesis. A cerebral CT scan showed a large and heterogeneous parieto-occipital lesion. During surgery an infected hydatid cyst was discovered with multiple daughter vesicles. Post-operatively the patient was treated with albendazol, cefotaxime and metronidazole. The clinical course was good with total recovery of the hemiparesis. A follow-up CT scan showed persistence of some small deep-seated cysts. Multiple infected cerebral hydatid cyst is uncommon and can be confused with other cystic brain lesions. The aim of surgery is to remove the cyst unruptured and this should be followed by antihelminthic and antibiotic treatment in order to avoid recurrences.

© 2007 Elsevier Ltd. All rights reserved.

Keywords: Cerebral hydatid cysts; Infection; Multiples cysts

1. Introduction

Hydatid disease (echinococcosis) is a worldwide zoonosis produced by the larval stage of the *Echinococcus* tapeworm. It is usually endemic in sheep-raising countries. These parasites live in the gastrointestinal tract of mammals. The lifecycle continues with the passage of eggs into the feces of the definitive host: the dog. The parasite penetrates the wall of the intestine of the intermediate host and spreads along venous channels and lymphatics. The agent is most often deposited in the liver (50–77%) and/or lung (8.5–43%), although the brain may also act as an end organ.¹ Cerebral involvement is seen in approximately 2% of patients infected with the parasite and this represents only 2% of all intracranial space-occupying lesions. Cerebral cystic echinococcosis is most commonly seen in children and young adults (approximately 50–70%).² Multiple cerebral cystic echinococcosis is very rare. Purulent infection of a hydatid cyst in the brain is rare. There are few patients with multiple infected cerebral hydatid cysts reported in the literature. We present a new case.

2. Case report

A 20 year-old right-handed man from a rural area was admitted to our department after a 2-month history of intense cervico-occipital headaches and left-sided weakness. The headaches were accompanied by nausea and vomiting. There was a history of mild head trauma 5 months previously. A neurological examination re-

vealed right-sided hemiparesis, bilateral abducens paresis, bilateral papilloedema and left homonymous hemianopsia. There was no cognitive deficit. Results of the general physical examination were normal except for the head, where there was bulging in the right occipital region of the skull with a healed scar, without any sign of contiguous skin inflammation. Laboratory findings included an elevated erythrocyte sedimentation rate (80 mm/h), white blood cell count of 16 000/mm³ and normal liver function. Skull X-rays showed a parieto-occipital lytic lesion (Fig. 1). Further investigations, including chest X-ray and abdominal ultrasonography, did not show any other

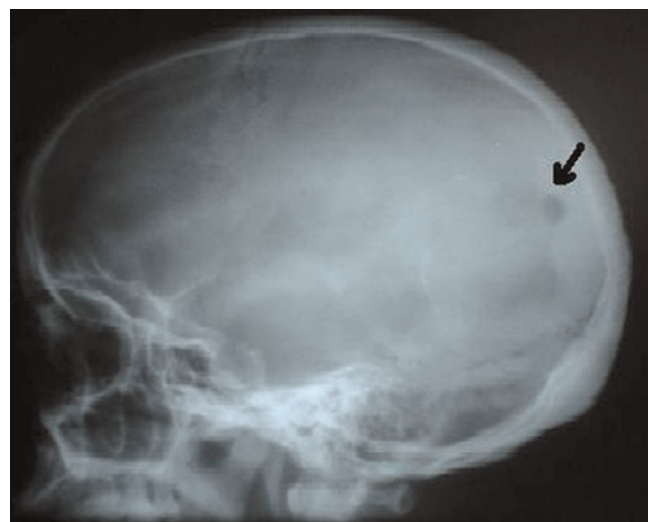


Fig. 1. Lateral skull X-rays showing a lytic lesion in the occipital bone (arrow).

* Corresponding author. Tel.: +212 61296531.

E-mail addresses: RachidGana96@hotmail.com (R. Gana).

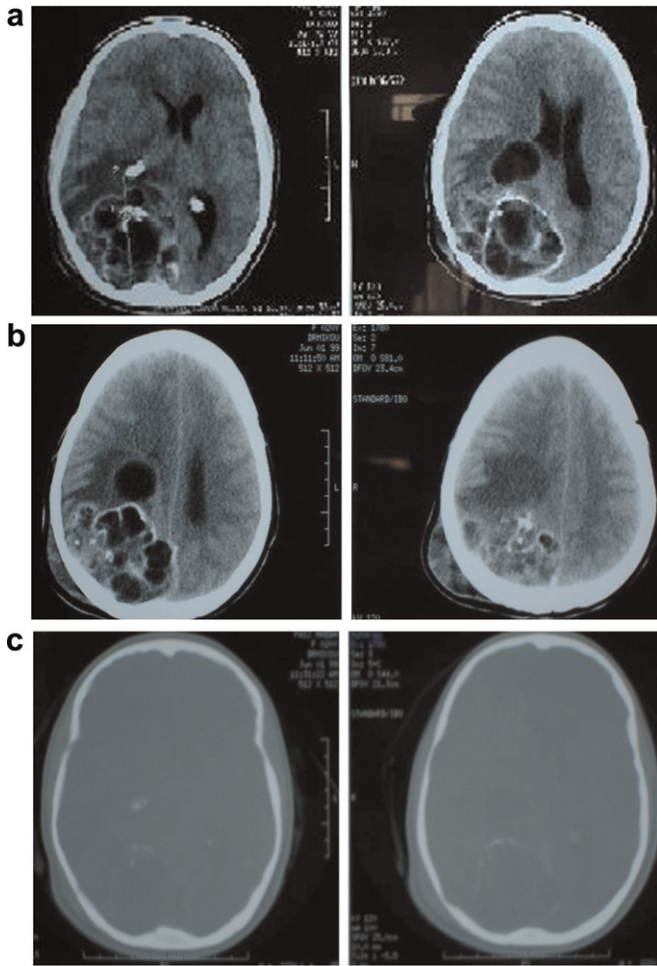


Fig. 2. a–c Cerebral axial CT scan showing a large heterogeneous mass in the right parietal-occipital region (a,b) with a thinning of occipital bone (bone window, c) and a subcutaneous collection.

abnormality. The cerebral CT scan showed a large heterogeneous mass in the right occipital lobe with two components. The first was cystic and deep-seated (paraventricular), measuring 2×2 cm with clearly de-

finied borders; the second was heterogeneous, including small calcifications, with marginal rim enhancement and perifocal oedema. There was mass effect on the ventricle and midline shift. In addition, the CT scan showed thinning of the occipital bone and a subcutaneous collection (Fig. 2). These findings were suggestive of multiple hydatid cysts, cystic tumour or cerebral abscess. We were not able to obtain an MRI and we decided to operate on the patient immediately. After skin incision we found a purulent subcutaneous collection and osteitis of the parietal bone. We performed a right parieto-occipital craniotomy. The dura was thick with signs of inflammation. Immediately after opening the dura, the solid part of the mass was visible on the cortex. The purulent material within the cyst was sampled and aspirated; then the capsule was removed easily. Later numerous small cysts were seen and all of these were aspirated; the bigger one was removed by a combination of the Valsalva manoeuvre and water dissection. The cavity was irrigated using hypertonic saline. The patient's post-operative course was uneventful and he received albendazol (400 mg twice daily), cefotaxime (2 g twice daily) and metronidazole (1500 mg/day). The patient's left hemiparesis improved gradually although he still had a left homonymous hemianopsia. Histopathological examination confirmed the hydatid cyst but no bacterial agent was isolated. The control CT scan performed 2 months after surgery showed a postoperative cavity and persistence of a residual cyst (Fig. 3) which was small and deeply seated. We decided not to operate further and instead treated with albendazole for 12 months under strict CT scan surveillance. The duration however, was only 6 months, as the patient was lost to follow-up.

3. Discussion

The lesions of cerebral hydatid disease are usually distributed in the territory of the middle cerebral artery,

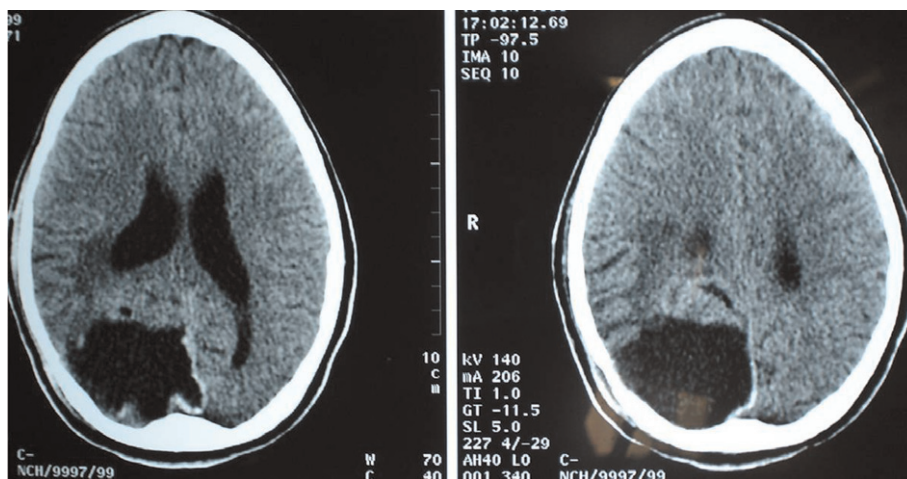


Fig. 3. Follow-up axial CT scan performed 2 months after surgery showing post-operative cavity and residual cysts.

especially in the parietal lobe. Most cysts are located in the supratentorial regions and quite rarely in the posterior cranial fossa or ventricles.^{2–4} Multiple cerebral hydatid cysts are very rare and result from spontaneous, traumatic or surgical rupture of a solitary primary cyst or as a consequence of a cyst rupture elsewhere and embolisation of hydatids to the brain.^{2–5} These secondary cysts, which are infertile, do not have a thick capsule.^{2,3} There are 81 patients with multiple cerebral hydatid cysts reported in the literature: 77 reported by Al Zain et al.,⁵ two by Tüzün et al.³ and two by Buktea et al.⁴ Multiple cerebral hydatid cysts may cause misinterpretation in neuroradiological investigations and the main differential diagnosis is cystic tumours of the brain and pyogenic abscess.^{6,7} Cystic tumours of the brain can be differentiated by enhancement of a mural nodule and the periphery of the tumour. When a pyogenic abscess has a cyst-like central necrotic area, peripheral oedema is almost always present and the rim enhances intensely following contrast administration.² Clinical and laboratory findings can also aid in the differential diagnosis of patients with cerebral abscess formation.

Based on the presence or absence of perifocal edema and contrast enhancement, El-Shamam et al.² classified hydatid cysts into simple (non-complicated) cysts with no edema or contrast enhancement and infected (complicated) cysts with edema and contrast enhancement. This series of 16 patients reported four cases of complicated cerebral hydatid cyst with perifocal edema and uniform marginal enhancement limited to the capsule, complete in one patient and incomplete in three others. Those four patients at operation and after pathologic examination showed evidence of cyst infection. The rim of enhancement may be prominent around a multivesicular, secondary cyst.² All the recurrent cysts in El-Shamam's series (6 patients), were surrounded by perifocal edema and showed marginal contrast enhancement. All these recurrent cases occurred after rupture of the primary cyst at operation. Thus edema and contrast enhancement can be explained in recurrent cases by previous cyst leakage which excites an inflammatory response. In 1995 Arana-Iniguez and Julians were the first authors to report a suppurating cyst with daughter vesicles.⁸ Another was reported in 1985 by Mathuria et al. in which the cyst was located in the foramen magnum.⁹ We were able to find eight other cases published in the English literature.^{2–4} Among them only three were multiple. Today the mechanism of this suppurating is still unknown and the source of infection could be haematogenous spread or contiguous contamination.¹⁰ In our case, the patient had mild head trauma with parietal scalp wound 5 months before admission. We suggest that this neglected head trauma caused a traumatic rupture of a hydatid cyst which became infected by contiguous diffusion from the scalp wound. Multiple and infected hydatid cysts may cause difficulties

for CT scan interpretation and may lead to confusion with brain abscess or cystic tumours; Therefore MRI is the modality of choice to confirm diagnosis and to plan surgery.^{2,4,7} However, in Morocco it is not always possible to obtain MRI for emergency patients. In addition, the progressive deterioration of our patient obliged us to operate without MRI investigation.

The aim of surgery is total removal of the cysts intact and evacuation of purulent matter. Postoperatively, the patient must receive antibiotic and albendazole (broad-spectrum oral antihelminthic at 10 mg/kg body weight, three times daily for 12 months).^{2,11,12} Because of its rarity, the prognosis of infected cerebral hydatid cysts is unknown. In El-Shamam et al. series² among the four patients with infected cerebral hydatid cyst there was one death (25%) and one recurrence (25%).

4. Conclusion

Multiple infected cerebral hydatid cysts is rare and may be confused with other cystic lesions of the brain, in particularly cystic tumours and brain abscess. MRI is superior for diagnosis and for planning surgery. Laboratory tests can confirm the diagnosis. The aim of surgical treatment is to remove cysts intact. This should be followed by antibiotic and antihelminthic treatment to avoid recurrence.

References

1. Abbassioun K, Rahmat H, Ameli NO, et al. Computerized tomography in hydatid cyst of the brain. *J Neurosurg* 1978;**49**:408–11.
2. El-Shamam O, Amer A, El-Atta MA. Magnetic resonance imaging of simple and infected hydatid cysts of the brain. *Magn Reson Imaging* 2001;**19**:965–74.
3. Tuzun M, Altinors N, Arda IS, et al. Cerebral hydatid disease CT and MR findings. *Clin Imaging* 2002;**26**:353–7.
4. Bukte Y, Kemaloglu S, Nazaroglu H, et al. Cerebral hydatid disease: CT and MR imaging findings. *Swiss Med Wkly* 2004;**134**:459–67.
5. Al Zain TJ, Al-Witry SH, Khalili HM, et al. Multiple intracranial hydatidosis. *Acta Neurochir (Wien)* 2002;**144**:1179–85.
6. Nazaroglu H, Ozates M, Bilici A, et al. Multilocular cerebral hydatid disease with extracalvarial extension. *AJR Am J Roentgenol* 1999;**172**:1455–6.
7. Tuzun M, Hekimoglu B. Hydatid disease of the CNS: imaging features. *AJR Am J Roentgenol* 1998;**171**:1497–500.
8. Arana-Iniguez R, Julians JS. Hydatid cyst of the brain. *J Neurosurg* 1955;**12**:332–52.
9. Mathuria SN, Arora OP, Khosla VK. Infected intradural hydatid cyst of foramen magnum. A case report. *Clin Neurol Neurosurg* 1985;**87**:283–5.
10. Erongun U, Ozkal E, Acar O, et al. Multiple and infected cerebral hydatid cyst. Case report. *Neurosurg Rev* 1994;**17**:77–81.
11. Singounas EG, Leventis AS, Sakas DE, et al. Successful treatment of intracerebral hydatid cysts with albendazole. Case report and review of the literature. *Neurosurgery* 1992;**31**:571–4.
12. Sinner WV. Advanced medical imaging and treatment of human cystic echinococcosis. *Semin Roentgenol* 1997;**4**:276–90.