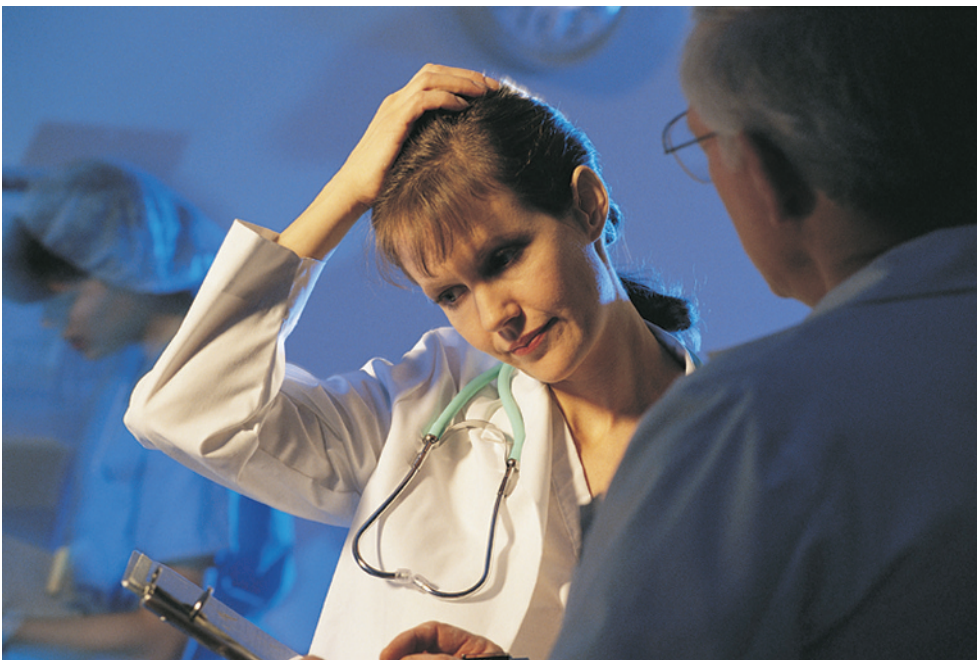

When the patient fails to respond to treatment: TIAs that go on, and on

Graeme J Hankey



Most transient ischaemic attacks (TIAs) stop, with or without treatment, but some are followed by stroke within days or longer. But if the TIAs do not stop then the diagnosis must be reviewed (are they really TIAs or could they be migraine or epilepsy?), and if they are TIAs, what are they caused by (atherothromboembolism, embolism from the heart, etc)? With this information, both the medical and any surgical treatment can be optimised, even though one must accept that the randomised controlled trials mostly have not addressed the particular issue of continuing TIAs.

Professor G J Hankey
Consultant Neurologist and Head
of Stroke Unit, Department of
Neurology, Royal Perth Hospital,
197 Wellington Street, Perth,
Australia 6001; gjhankey@cyllene.uwa.edu.au

TABLE 1 Differential diagnosis of transient ischaemic attack (in approximate order of frequency, depending on referral patterns)

- Pre-syncope or syncope
- Migraine aura (with or without headache)
- Labyrinthine disorders (benign paroxysmal positional vertigo and other peripheral vestibulopathies)
- Partial (focal) epileptic seizures (eg, transient inhibitory seizures or post-ictal Todd's paresis)
- Hyperventilation, anxiety or panic attacks, somatisation disorder
- Intracranial structural lesion:
 - meningioma
 - tumour
 - giant aneurysm
 - arteriovenous malformation
 - chronic subdural haematoma
- Transient global amnesia
- Acute demyelination (multiple sclerosis)
- Drop attacks
- Metabolic disorders: hypoglycaemia, hyperglycaemia, hypercalcaemia, hyponatraemia
- Mononeuropathy/radiculopathy (eg, Bell's palsy, radial neuropathy)
- Myasthenia gravis
- Cataplexy

Something must be done for the patient with frequent, perhaps even daily or more often, transient ischaemic attacks (TIAs); to stop the attacks themselves not only because they can be disabling and frightening, but also if the underlying disease is not controlled a stroke may follow.

ARE THEY REALLY TIAs?

The first step is to review the nature of the recurrent attacks and determine whether they are all the same, stereotyped event or multiple, different events; after all, even a genuine TIA patient may have other types of attack—for example, non-organic focal and other neurological episodes as the result of anxiety. The next step is to review the diagnosis of TIA for each event and very carefully check that non-vascular causes of recurrent transient focal neurological disturbances (table 1) have been excluded as far as it is possible to do so (repeat the history and look at the tests). Over-diagnosis of TIA is common, particularly in primary care and emergency settings, and these days this can lead to an enormous number of unnecessary drugs being prescribed for life with all their associated

adverse effects and costs, and serious consequences for life insurance and even travel insurance (case 1).

Case 1

A 40-year-old previously fit fireman presented with frequent episodes of pins and needles and heaviness of the left arm and leg, lasting from minutes to hours. He had no vascular risk factors, and all investigations were normal. Nonetheless he was started on aspirin, dipyridamole, simvastatin, perindopril and indapamide, but the attacks became more frequent and more prolonged, so much so that he had to stop work. At this point the attacks settled and he was referred to a neurologist because the fire service were not prepared to continue his employment. It then became apparent that the attacks followed a head injury sustained at work, had only ever occurred at work, involved the whole body including the face and head, as well as the left arm and leg (and so were not really focal), and were accompanied by a feeling of dissociation and breathlessness. They were, therefore, almost certainly situational panic attacks. After some negotiation, he retired from the fire service with a pension, stopped all his drugs, went to college to train as a social worker, and has remained well with no more attacks.

The diagnosis of brain TIA is based on the history and (lack of) neurological signs, backed up with a relevant ischaemic lesion or normal brain imaging (for eye TIAs, a normal ocular examination). The clinical features which favour the diagnosis are the sudden onset (that is, an exact time can be given) of symptoms of loss of focal neurological function (that is, anatomically-localising, "negative" symptoms—loss of power, loss of sensation, loss of vision, etc) which arise concurrently (that is, do not spread, or if they do, do so over seconds) (case 2). By definition, the symptoms resolve within 24 hours, but usually this happens in less than an hour, even in just minutes for amaurosis fugax particularly. The patient usually has risk factors for vascular disease (for example, hypertension, smoking, etc) or abnormal cardiac findings (for example, atrial fibrillation, heart murmur). Non-focal neurological symptoms (for example, generalised weakness, light

headedness, dizziness) and symptoms lasting only a few seconds are unlikely to be due to TIAs. Transient, *isolated* symptoms of vertigo, dysarthria or diplopia are also all less likely to represent a TIA, although there are exceptions.

Case 2

The neurology resident on call was telephoned by a very worried obstetrician who had just seen a 22-year-old woman in the last weeks of her first pregnancy. She had told him that she was having attacks of jumbled speech and he was concerned that she was about to have stroke. The neurologist telephoned the patient at once and got a rather different story: the woman had been having stereotyped episodes in the previous few weeks with gradual visual blurring and flashing on the right side lasting a few minutes, followed by jumbled speech for a few minutes and then heaviness of the right arm; in total the attacks were lasting 20 min. Although there was no headache, the attacks were clearly *migrainous* because they came on gradually involving one part of the brain after another, and the positive visual symptoms of “flashing” were very “migrainous”.

The diagnosis of TIA is facilitated by magnetic resonance diffusion-weighted imaging (MR-DWI) which will show a relevant area of restricted diffusion, consistent with recent focal brain ischaemia, in about half the patients who describe a brain (rather than eye) TIA in the preceding few days to weeks. The likelihood of detecting a relevant brain lesion on MR-DWI depends on the duration of the symptoms and how quickly the scan is performed after symptom onset—the longer the duration and the more recent the symptoms the more likely a positive scan (fig 1).

WHAT ARE THE TIAs CAUSED BY?

Having established the diagnosis of recurrent TIAs despite what is thought to be the appropriate treatment, the next step is to review their cause (tables 2 and 3).

The neuroanatomical location and arterial territory of the focal brain or ocular ischaemia can be a clue. This can be delineated from the clinical syndrome and, if positive, the MR-DWI scan (for example, recent ischaemic

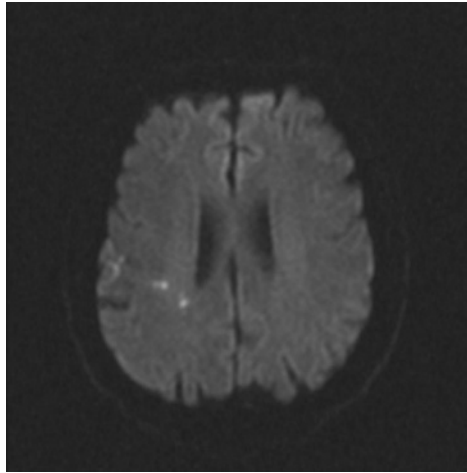


Figure 1
Magnetic resonance diffusion-weighted image (MR-DWI) of the brain showing multiple small areas of increased signal intensity, reflecting restricted diffusion of water due to brain ischaemia, in the right cerebral hemisphere of a patient who had experienced left arm and leg weakness of sudden onset two days previously which resolved within one hour.

lesions in both cerebral hemispheres are more likely the result of embolism from the heart or aortic arch than the carotid artery).

Recurrent total or partial anterior circulation syndrome TIAs are likely to be caused by thromboembolism from a proximal source in the heart, aortic arch or extracranial carotid system, and only sometimes in situ thrombosis of the origin of the middle cerebral artery. In these cases, the carotid artery should be imaged non-invasively, particularly if the patient has risk factors for atherosclerosis (for example, hypertension, smoking) or dissection (for example, recent neck trauma) of the origin of the internal carotid artery, or evidence of arterial disease elsewhere (for example, intermittent claudication, angina), or platelet or calcific emboli on funduscopy (fig 2). If clinical examination of the heart or ECG is abnormal (for example, atrial fibrillation, prosthetic heart valve), if there is a relevant history of a Valsalva manoeuvre at the onset of each attack, or physical signs consistent with a cardioembolic source such as infective endocarditis, or the

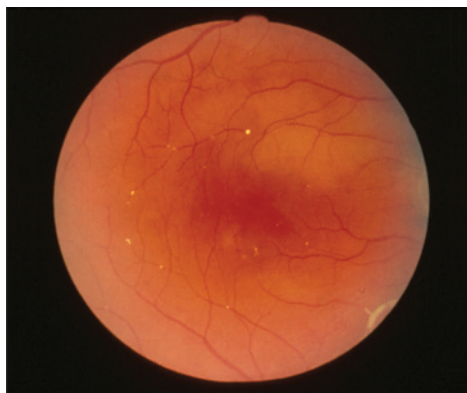

Figure 2
Fundus photograph showing multiple cholesterol emboli in the retinal arterioles (arrows). These had arisen from an ulcerated atherosclerotic plaque at the origin of the ipsilateral internal carotid artery in a patient with recurrent ipsilateral carotid territory TIAs of the brain.

TABLE 2 Clues from the history which may suggest the cause of the continuing transient ischaemic attacks**Precipitating factors**

- Standing up or sitting up quickly, heavy meal, hot weather, hot bath, warming the face, exercise, coughing, hyperventilation, chest pain or palpitations, starting or changing blood pressure-lowering drugs (systemic hypotension or low cerebral perfusion pressure)
- Head turning
- Valsalva manoeuvre (paradoxical embolism or low flow)
- Pregnancy/puerperium
- Drugs
 - blood pressure-lowering/vasodilators
 - sympathomimetics (amphetamines, cocaine, ephedrine, phenylpropanolamine, "ecstasy")
 - oral contraceptives
 - hypoglycaemic drugs
- Injury
 - chronic subdural haematoma
 - vertebral/carotid artery dissection

Associated symptoms*Headache*

- Carotid/vertebral dissection
- Migrainous TIA
- Intracranial venous thrombosis
- Giant-cell arteritis (or other inflammatory vascular disorders)
- Structural intracranial lesion

Epileptic seizures

- Intracranial venous thrombosis
- Mitochondrial diseases
- Non-vascular intracranial lesion

Malaise

- Inflammatory arterial disorders
- Infective endocarditis
- Cardiac myxoma
- Cancer and marantic endocarditis
- Thrombotic thrombocytopenic purpura
- Sarcoidosis

Chest pain

- Myocardial infarction
- Aortic dissection
- Paradoxical embolism

Self-audible bruits

- Internal carotid artery stenosis (distal)
- Dural arteriovenous fistula
- Glomus tumour
- Caroticocavernous fistula
- Raised intracranial pressure
- Intracranial venous thrombosis

Past medical history

- Inflammatory bowel disease
- Coeliac disease
- Homocystinuria
- Cancer
- Irradiation of the head or neck
- Recurrent deep venous thrombosis
- Recurrent miscarriages
- Recent surgery/long distance travel
- Family history of TIA, stroke or myocardial infarction (CADASIL)

patient is unlikely to have atheroma (young and no vascular risk factors), the heart should be imaged with transthoracic echocardiography, and possibly transoesophageal echocardiography too if valvular vegetations are suspected or the arch of the aorta may be an embolic source (although finding aortic arch atheroma does not change the management).

Some patients with recurrent TIAs describe recurrent episodes of pure hemimotor and/or hemisensory deficit, without any cognitive disturbance (for example, aphasia). Because of the brevity of the attacks it can be difficult to be sure, but these are probably lacunar TIAs and likely caused by ischaemia in the distribution of a small penetrating artery supplying the internal capsule (or pons). Usually this is the result of local small vessel disease, perhaps causing thrombosis or merely low flow. When there are very frequent attacks, this syndrome has been called the "capsular warning syndrome" because it is associated with a high risk (about 40%) of lacunar ischaemic stroke. If the patient has risk factors for atheroma, the underlying vascular disease is likely to be lipohyalinosis or microatheroma. If not, other small vessel diseases such as arteritis, Fabry's disease, cerebral amyloid angiopathy and CADASIL, need to be considered.

TIAs in the vertebrobasilar territory are more heterogeneous and may be due to large vessel atherothromboembolism, small vessel disease or embolism from the heart.

TIAs affecting the eye (amaurosis fugax or transient monocular blindness) are usually due to embolism from proximal extracranial arteries or the heart, but sometimes are caused by "low flow" alone (see below).

If the TIAs repeatedly follow a heavy meal, hot bath, or standing up, or if hypotensive drugs have just been started or the dosage increased, it is likely that the cause is low flow distal to a fixed stenosis or occlusion rather than embolism—so-called "haemodynamic" TIAs (usually in the presence of severe occlusive arterial disease in the neck).

However, even after repeat clinical assessments, there are still some patients with no reasonable explanation for their TIAs, and some patients where any putative cause is marginal (for example, patent foramen ovale, uncomplicated mitral leaflet prolapse, the oral

contraceptive pill without other prothrombotic abnormalities, etc). In these cases the TIAs are deemed "cryptogenic" but beware that "no cause for the TIAs" may mean that the patient has not had TIAs in the first place. Of course it is crucial to check that the appropriate investigations have been done and the results are available and have been seen and discussed.

IS THE TREATMENT DIRECTED AT THE CAUSE OF THE TIAS?

Given the range of possible causes of recurrent TIAs, it is unlikely that a single intervention would be effective in the treatment of all types of TIA and in the prevention of stroke. It may be that you are trying to treat the wrong type of TIA with the wrong interventions—double check that you have got the underlying cause of the TIA correct and proceed from there. A point to note is that the many randomised controlled trials in TIA patients were generally of interventions started some weeks or even months after the TIAs, and were not done in the present context—continuing TIAs. What to do in this context is therefore based on making sure that in general the correct interventions are being used in the right way based on intelligent understanding of the likely pathophysiology of the TIAs and the effectiveness of treatment, and clinical experience.

ATHEROTHROMBOEMBOLIC AND LACUNAR TIAs

Assuming that the patient is on sufficient aspirin to inhibit platelet aggregation (300 mg loading dose and then 75 mg daily) combined with modified release dipyridamol (200 mg twice daily), a statin has been started (for example, simvastatin 40 mg daily), and the blood pressure is being gradually brought under control (aiming for about 130/70 mmHg provided there are no adverse effects, particularly low flow or haemodynamic TIAs)—what next if the TIAs continue?

If the TIAs involve the carotid territory, imaging shows moderate or severe atherosclerotic stenosis at the origin of the symptomatic internal carotid artery (ICA) (which of course is unlikely if the TIAs are lacunar), and the patient is fit and willing to

TABLE 3 Clues to the cause of the continuing transient ischaemic attacks from investigations

First-line

- Full blood count
- Erythrocyte sedimentation rate/C-reactive protein
- Plasma glucose
- Urea and electrolytes
- Plasma cholesterol
- Urinalysis
- ECG
- Unenhanced CT brain scan

Second-line

Blood

- Liver function tests
- Calcium
- Thyroid function tests
- Syphilis serology
- Activated partial thromboplastin time, dilute Russell's viper time, antinuclear and other autoantibodies
- Serum proteins, serum protein electrophoresis, plasma viscosity
- Haemoglobin electrophoresis
- Protein C and S, antithrombin III, activated protein C resistance, thrombin time
- Blood cultures
- HIV serology
- Lipoprotein fractionation
- Serum homocystine
- Leucocyte α -galactosidase A
- Lactate
- Cardiac enzymes (troponin T or I)
- Drug screen
- Genetic analysis

Urine

- Amino acids
- Drug screen

Imaging

- Chest x ray
- MR brain with diffusion-weighted imaging
- Carotid ultrasound
- CT or MR angiography of the aortic arch, extracranial and intracranial circulations
- Catheter angiography

Cardiac

- Echocardiography: transthoracic, transoesophageal
- 24-hour/4 day ECG

Others

- Electroencephalogram
- CSF (cells, protein, glucose, lactate, oligoclonal bands)
- Temporal artery biopsy
- Skin biopsy

undergo surgery, then urgent carotid endarterectomy is indicated to remove the active source of thromboembolism (any evidence in

favour of stenting is at present very equivocal, unless perhaps the patient is too unwell for carotid surgery).^{1, 2} The benefits of surgery are likely to be greater if the patient is older and male, if the TIAs are recent (<2 weeks ago) and involve the brain (versus the eye), and if the symptomatic carotid plaque is irregular or ulcerated rather than smooth.¹ If carotid imaging shows occlusion or severe inoperable carotid stenosis, or the TIAs are in the vertebrobasilar territory where the opportunities for surgery and stenting are rather limited, any blood pressure-lowering treatments should be reviewed in case the continuing TIAs are due to low flow (see below).

If atherothrombotic or lacunar TIAs still continue there are four non-evidence-based options:

- increase the dose of aspirin on the assumption that the patient may in some way be so-called aspirin resistant (to 300 mg daily or twice daily)
- switch from aspirin to clopidogrel (300 mg loading dose followed by 75 mg daily)
- add clopidogrel to aspirin, but being aware this increases the intra- and extracranial bleeding risk
- anticoagulation with heparin followed by warfarin, and stop the antiplatelet drugs.³

If the TIAs stop, which they often do whether because of, or in spite of, one of these strategies, the combination of aspirin

and clopidogrel or anticoagulation can usually be withdrawn after a few months (to avoid the associated risks of bleeding) and replaced by lifelong aspirin and modified release dipyridamole.⁴

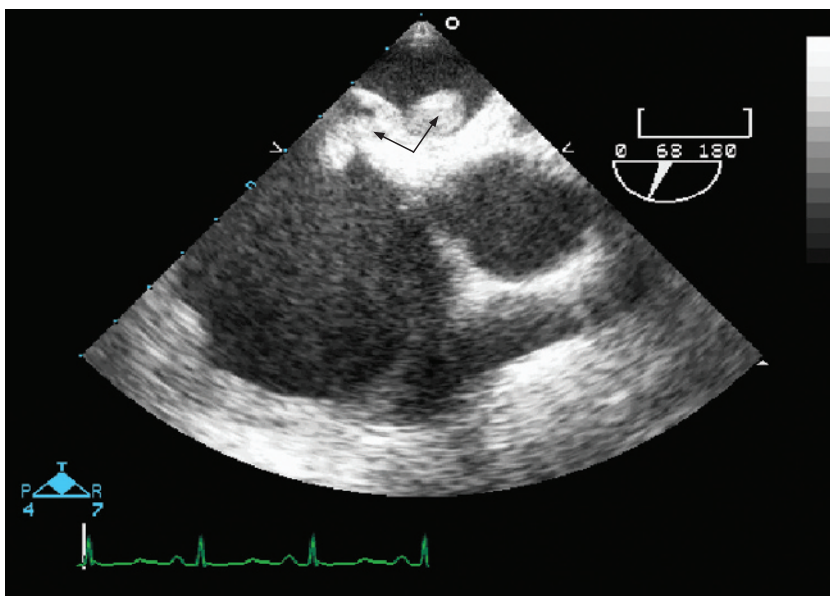
A few patients with continuing TIAs have middle cerebral artery stenosis (perhaps due to atheroma or dissection) but there is no evidence that stenting has anything to offer other than the inevitable risk.

EMBOLISM FROM THE HEART

If the likely cause is embolism of fibrin-rich thrombus from the left atrium or ventricle, then empirical therapy with intravenous unfractionated heparin is probably indicated until the patient is well anticoagulated with warfarin, and has an INR consistently between 2–3. Although there are no conclusive randomised controlled trials (RCTs) in this context of continuing TIAs, a recent meta-analysis of seven RCTs, involving 4624 patients with acute cardioembolic ischaemic stroke showed that, compared with other treatments (aspirin or placebo), anticoagulants were associated with a non-significant reduction in recurrent ischaemic stroke within 7–14 days (3.0% vs 4.9%, OR 0.68, 95% CI 0.44 to 1.06).⁵ Although any benefits in reducing ischaemic stroke were offset by a significant increase in symptomatic intracranial bleeding (2.5% vs 0.7%), it is less likely that this would occur after TIAs, and thus the benefit-to-harm ratio of anticoagulation should be greater.

Figure 3

Transoesophageal echocardiogram showing, in the upper apex of the image, a thrombus (arrow) in the left and right atrium, straddling a patent foramen ovale.



Case 3

A 60-year-old man presented with several right carotid TIAs. There was no carotid stenosis, his ECG was normal as were all his blood tests. Despite antiplatelet drugs, simvastatin and a diuretic his TIAs continued. He was readmitted and a medical student thought that he was in atrial fibrillation. However, when the consultant came round the patient was in sinus rhythm. Nonetheless, the resident ordered a 24-hour ECG which showed the patient was more often in atrial fibrillation than sinus rhythm. The aspirin was stopped, anticoagulation started and the TIAs stopped.

Of course one has to be alert to the very occasional possibility of bacterial endocarditis

and embolism of infected vegetations from the valvular endothelial surface, which should be treated for several weeks with antimicrobial therapy targeted to the pathogen isolated from cultures (cardiac surgery is also needed in about 50% of patients).

Case 4

A 65-year-old woman had definite TIAs with temporary blindness in the left eye. Apart from being a smoker, she was otherwise very healthy and investigations were negative. In spite of antiplatelet drugs, simvastatin and a normal blood pressure of 110/70 mmHg (without treatment) she continued to have TIAs. In view of that a transoesophageal echocardiogram was ordered and this showed valvular vegetations. CT thorax revealed a small bronchial tumour invisible on the earlier routine chest x ray.

For patients with a patent foramen ovale (PFO), it is often very uncertain whether it is coincidental or causal, and whether the risks associated with its closure or long-term anticoagulation exceed the potential benefits (case 5). If there is no other cause for the continuing TIAs, and if full anticoagulation is not helpful or acceptable, then certainly endovascular closure should be seriously considered.

Intracardiac tumours are very rare but are unlikely to respond to anticoagulants.

Case 5

A 50-year-old man was lifting a heavy concrete block when he suddenly went weak down his right side. When he tried to speak to his wife his words were jumbled up. He recovered within a

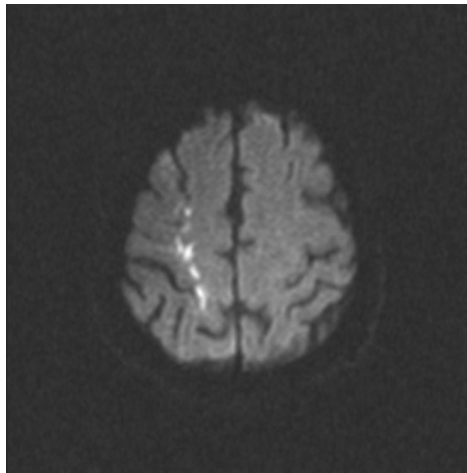


Figure 4

Brain MR-DWI showing multiple small areas of increased signal intensity in the deep white matter of the right cerebral hemisphere consistent with ischaemia in the internal border zone between the deep penetrating lenticulostriate arteries and cortical medullary arteries.

few hours. He presented to his general practitioner who started him on aspirin and a statin pending further investigation. He then had two further attacks and was admitted to hospital. It was then revealed that he had a past history of an unexplained deep venous thrombosis three years previously. An echocardiogram was ordered which showed a patent foramen ovale (fig 3). Venography showed extensive thrombosis in the deep venous system of his left leg (which had never been weak). He turned out to be protein S deficient (on repeated testing) and was anticoagulated. This combination of an attack precipitated by a Valsalva manoeuvre in a patient with thrombophilia and a patent foramen ovale is unusually persuasive for paradoxical embolism.

TREATMENT OF RECURRENT LOW FLOW (HAEMODYNAMIC) TIAs

Avoid extreme heat, alcohol, large meals, straining, getting up rapidly and drugs that

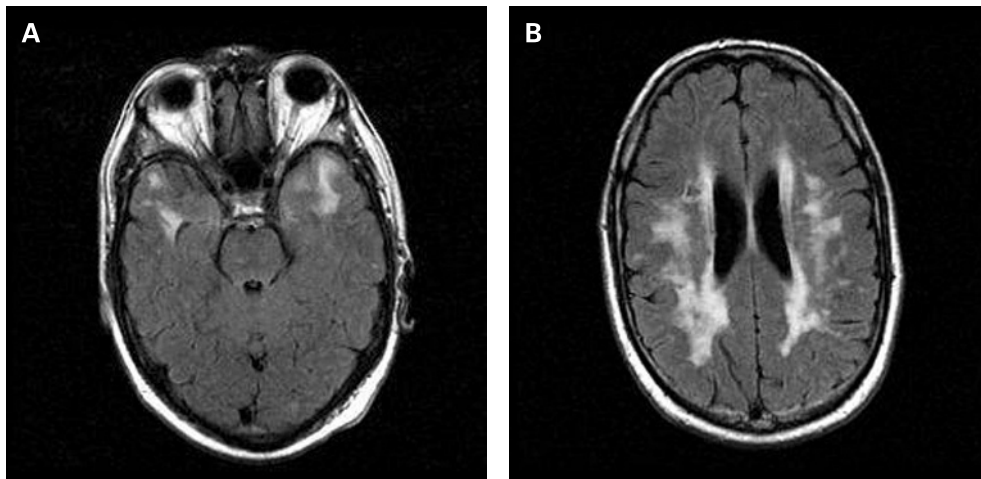


Figure 5

MR FLAIR brain scan showing typical changes of CADASIL with (A) bilateral involvement of the anterior temporal lobe white matter and (B) of the subcortical and periventricular white matter.

lower blood pressure, and consider raising the blood pressure in the short term:

- increase sodium and water intake
- fludrocortisone 0.1 to 0.5 mg orally daily and/or indomethacin 50 mg orally three times daily
- and revascularisation of any relevant arterial stenosis (case 6).

Case 6

A 60-year-old diabetic man with a past history of myocardial infarction and claudication presented with several attacks of left-sided weakness, lasting several minutes at a time. He was already on the full range of "vascular" drugs. Imaging revealed 90% stenosis of the right ICA, and the left ICA was occluded. Brain MR-DWI showed multiple small areas of increased signal intensity in the deep white matter of the right cerebral hemisphere consistent with ischaemia in the internal border zone between the deep penetrating lenticulostriate arteries and cortical medullary arteries (fig 4). His blood pressure was 170/100 mmHg and so nifedipine was added to reduce it, pending carotid surgery. The next day when he got out of bed he had a further attack, and then three more during the course of the morning. The nifedipine was withdrawn and after a right carotid endarterectomy his TIAs stopped. These TIAs were almost certainly due to "low flow" and were stopped by appropriate revascularisation.

TREATMENT OF ARTERITIC TIAs

Although antiplatelet drugs are usually given there is no formal evidence from randomised controlled trials that they are helpful, and certainly the patients should be started on corticosteroids, perhaps with induction with iv methylprednisolone, 1 g/day for three days, followed by oral prednisolone 60 mg/day decreasing gradually to a maintenance dose of perhaps 10–20 mg daily. If the TIAs continue then cyclophosphamide, azathioprine or methotrexate could be added.

TREATMENT OF TIAs DUE TO OTHER RARE CAUSES

Naturally a cause that is reasonably simple to remove should be removed (for example, atrial myxoma), but in other situations (for

example, CADASIL, Fabry's disease) it is very unclear what to do, in which case the patients are usually at least tried on aspirin, aspirin and clopidogrel, or even warfarin. However if the TIAs persist there seems little point in continuing. It is uncertain if TIAs are ever caused by vasospasm, but if there is some reason to suspect that they are (and they are not migrainous), they may respond empirically to a calcium-channel antagonist such as nimodipine (60 mg orally, 4-hourly for 10–14 days).

Case 7

A 45-year-old woman presented with several left carotid TIAs with weakness down the right side but no language disturbance. Apart from migraine she was very well, and on investigation all that was found was "small vessel disease" (that is, leukoaraosis) on her CT brain scan. She was treated with antiplatelet drugs, a statin and blood pressure lowering but the attacks continued. On further review the fact that her mother had had a stroke at an early age and had then become demented was elicited (a simple but inadequate family history consisting of the question "are your parents still alive?" had been answered in the affirmative). An MR brain scan revealed typical changes of CADASIL (fig 5) and she was found to be carrying one of the recognised NOTCH 3 mutations.

TREATMENT OF RECURRENT TIAs OF NO KNOWN CAUSE

If the attacks still persist, the differential diagnosis of the TIAs and their cause(s) should yet again be reconsidered (history from the patient and a relative/friend and review the tests). But if the diagnosis is secure and there are no vascular risk factors, the heart is normal, there is no evidence of vascular disease outside the brain, and all the relevant investigations are normal, there is little to be done except perhaps recommend aspirin as an antithrombotic drug, along with a statin (for a short time at least), and wait and see. Fortunately, recurrent TIAs with no discernable cause seldom seem to be followed by stroke, probably because they are not really TIAs. In general, the diagnostic problem is more often the lack of a good clinical history

than the lack of a key investigation or treatment.

ACKNOWLEDGEMENT

Charles Warlow, Edinburgh reviewed and contributed to the manuscript.

REFERENCES

1. Rothwell PM, Mehta Z, Howard SC, *et al.* Treating individuals 3: from subgroups to individuals: general principles and the example of carotid endarterectomy. *Lancet* 2005;**365**:256–65.
2. Kern R, Ringleb PA, Hacke W, *et al.* Stenting for carotid artery stenosis. *Nature Clinical Practice Neurology* 2007;**3**:212–20.
3. The ESPRIT Study Group. Medium intensity oral anticoagulants versus aspirin after cerebral ischaemia of arterial origin (ESPRIT): a randomised controlled trial. *Lancet Neurol* 2007;**6**:115–24.
4. Halkes PH, van GJ, Kappelle LJ, *et al.* Aspirin plus dipyridamole versus aspirin alone after cerebral ischaemia of arterial origin (ESPRIT): randomised controlled trial. *Lancet* 2006;**367**:1665–73.
5. Paciaroni M, Agnelli G, Micheli S, *et al.* Efficacy and safety of anticoagulants treatment in acute cardioembolic stroke. A meta-analysis of randomised controlled trials. *Stroke* 2007;**38**:423–30.

PRACTICE POINTS

- Review the nature of the recurrent attacks and determine whether they are the same, stereotyped event or multiple, different events.
- Review the diagnosis of transient ischaemic attacks (TIAs) for each event and exclude non-vascular causes of recurrent transient focal neurological disturbances.
- Review the underlying cause of the recurrent TIAs and make sure that any treatment is targeted at that cause.
- Treatment of atherothromboembolic and lacunar TIAs includes antiplatelet drugs, statins, sensible blood pressure lowering and, in patients with recent symptomatic moderate or severe carotid stenosis, urgent carotid revascularisation. Anticoagulation may also have a role in the short term.
- Treatment of cardioembolic TIAs includes anticoagulation for fibrin-rich thromboembolism, antibiotics for infected vegetations, surgery for atrial myxoma, and perhaps endovascular closure for patent foramen ovale.
- Treatment of low flow (haemodynamic) TIAs includes avoiding any precipitants, temporarily raising the blood pressure, and revascularisation of any relevant arterial stenosis.
- Treatment of arteritic TIAs includes corticosteroids with or without other immunosuppressants, such as cyclophosphamide.
- Not all treatments for TIAs are completely effective, and some patients will continue to have TIAs despite our current best therapies. Sometimes we have to accept this, as we have to accept recurrent epileptic seizures despite optimal antiepileptic drug therapy and surgery, and recurrent episodes of demyelination despite optimal immunomodulating therapy.