

Letters to the Editors Related to New Topics

Cervical Dystonia Due to Cerebellar Stroke

Sir,

Although poststroke dystonia is usually associated with lesions of the lentiform nucleus,¹ recent reports suggest that cerebellum plays a key role in the pathogenesis of dystonia.^{2,3} We describe a patient who developed cervical dystonia after ipsilateral cerebellar infarction.

CASE REPORT

A 48-year-old woman patient presented with a sudden onset of vertigo, vomiting, and ataxia. On admission, neurological examination revealed horizontal, bidirectional nystagmus and ataxia of the left limbs. Her previous medical history was unremarkable. She smoked 20 cigarettes per day.

Emergency MRI findings were consistent with acute cerebellar infarction in the irrigation area of the left superior cerebellar artery (Fig. 1a,b). Standard biochemistry, erythrocyte sedimentation rate, and complete blood count were within the normal limits. Immunologic tests (rheumatoid factor, antineutrophilic cytoplasmic antibodies, anticardiolipin antibodies, antinuclear antibodies) were negative. Chest X-ray and electrocardiogram were normal. Heart ultrasound was normal and did not show signs of patent foramen ovale. Fundus was normal.

On the second day of hospital stay, she started developing abnormal posturing of her head along with sustained involuntary contractions of the cervical muscles, and so the head was rotated to the right and down. She was discharged to stationary rehabilitation with almost complete recovery of left limb ataxia. Therapy with aspirin (100 mg) was introduced, and because of registered mild hypertension, ramipril (2.5 mg) in the morning was prescribed. However, involuntary movements progressed severely over the next few weeks, and so she could just temporarily move her head to the normal position, and hypertrophy of the left sternocleidomastoid muscle developed. Neck MRI was normal. Clonazepam (0.5 mg; three times daily) and baclofen (5 mg; three times daily) were introduced. This therapy led to slight improvement of symptoms. One month later, after the application of botulinum toxin, her symptoms improved significantly.

DISCUSSION

An interesting hypothesis that lesions of the cerebellum can cause dystonia has been proposed by Jinnah and Hess.² This is supported by recently published cases of patients with progressive ataxia associated with focal or segmental dystonia,³ and of cervical dystonia in patients with tumors of the

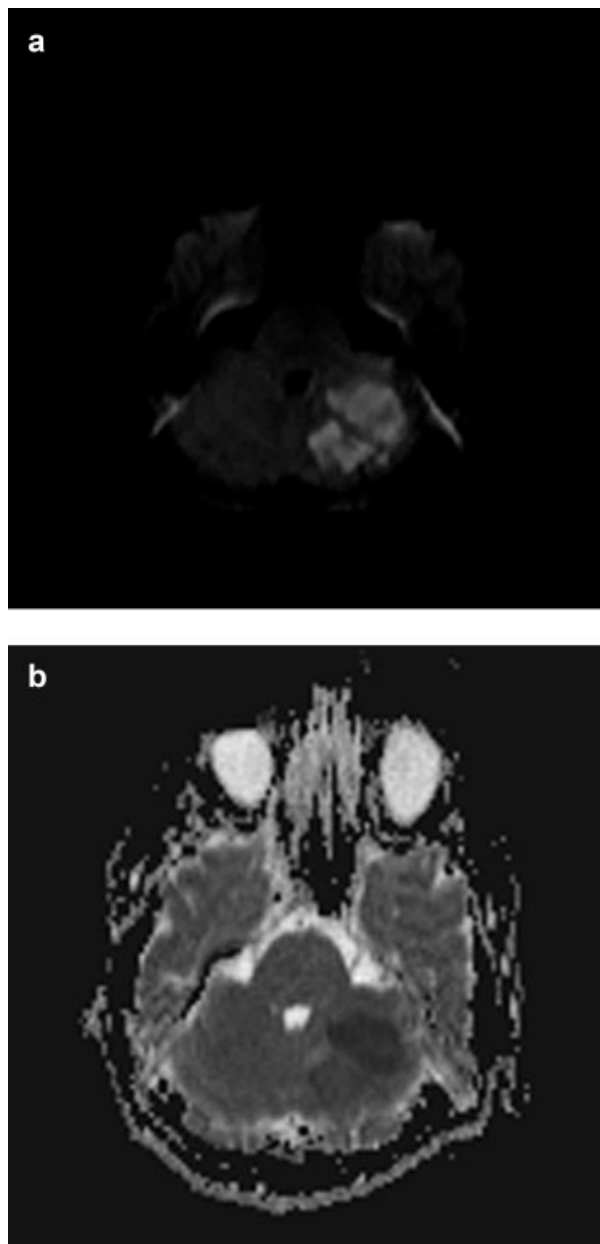


FIG. 1. Brain MRI. (a) Diffusion-weighted MR image ($b = 1,000$ s/mm²) shows the area of increased signal intensity in the left cerebellar hemisphere. (b) ADC map shows decreased ADC values in the same area. These findings are indicative of acute ischemia.

cerebellopontine angle.^{4,5} Another setting that clearly indicates a causal relationship is the reported case of a patient with cerebellar tuberculoma and ipsilateral focal limb dystonia that disappeared after tuberculostatic treatment.⁶

The most common lesions in patients with poststroke dystonia are those of the basal ganglia, thalamus, pons, or cerebral hemispheres.¹ There is only one case of dystonia associated with infarction of the cerebellum.⁷ However, this patient already had choreoathetoid movements from childhood, and dystonic movements appeared 2 months after stroke, thus implying a high possibility of incidental association.

LeDoux and Brady performed literature search and presented four additional patients with cervical dystonia associated with structural lesions of CNS.⁸ The authors identified only two cases with poor hemispheric cerebellar lesion associated with secondary cervical dystonia^{8,9}: one due to hemangioblastoma and one due to cavernous angioma. All other cases had lesions in the pons, medulla, spinal cord, or anterior limb of the internal capsule, and one feature common to most of these lesions is disruption of the olivocerebellar pathway.⁸

Although cerebellar stroke is common, and there are only few reports that link cerebellum and dystonia, the case presented provides further insight into this association. It is possible that destruction of the olivocerebellar pathway causes abnormal output of Purkinje cells and thus leads to dystonia. Close temporal relationship between stroke and cervical dystonia and the earlier proposed mechanisms together with other cases strongly support the hypothesis of cerebellar involvement in the pathogenesis of dystonia.

Ivana Zadro, MD
Vesna V. Brinar, MD, PhD
Barbara Barun, MD
*University Department of Neurology
Zagreb Medical School and University Hospital Center
Zagreb, Croatia*

David Ozretić, MD
*University Department of Radiology
Zagreb Medical School and University Hospital Center
Zagreb, Croatia*

Mario Habek, MD*
*University Department of Neurology
Zagreb Medical School and University Hospital Center
Kišpatićeva 12, HR-10000
Zagreb, Croatia
E-mail: mhabek@mef.hr

References

1. Alarcon F, Zijlmans JC, Duenas G, Cevallos N. Post-stroke movement disorders: report of 56 patients. *J Neurol Neurosurg Psychiatry* 2004;75:1568–1574.
2. Jinnah HA, Hess EJ. A new twist on the anatomy of dystonia: the basal ganglia and the cerebellum? *Neurology* 2006;67:1740–1741.
3. Le Ber I, Clot F, Vercueil L, et al. Predominant dystonia with marked cerebellar atrophy: a rare phenotype in familial dystonia. *Neurology* 2006;67:1769–1773.
4. Krauss JK, Seeger W, Jankovic J. Cervical dystonia associated with tumors of the posterior fossa. *Mov Disord* 1997;12:443–447.
5. Boisen E. Torticollis caused by an infratentorial tumour: three cases. *Br J Psychiatry* 1979;134:306–307.
6. Alarcon F, Tolosa E, Munoz E. Focal limb dystonia in a patient with a cerebellar mass. *Arch Neurol* 2001;58:1125–1127.
7. Rumbach L, Barth P, Costaz A, Mas J. Hemidystonia consequent upon ipsilateral vertebral artery occlusion and cerebellar infarction. *Mov Disord* 1995;10:522–525.
8. LeDoux MS, Brady KA. Secondary cervical dystonia associated with structural lesions of the central nervous system. *Mov Disord* 2003;18:60–69.
9. Tranchant C, Maquet J, Eber AM, Dietemann JL, Franck P, Warter JM. Cerebellar cavernous angioma, cervical dystonia and crossed cortical diaschisis. *Rev Neurol (Paris)* 1991;147: 599–602.