

Pseudotumoral Neuroparacoccidioidomycosis: One Case Report

Vitorino Modesto dos Santos · Rogério Martins Xavier ·
Jacira Azevedo Cortes · Ernesto Misael Cintra Osterne ·
Maria de Worisch Ferreira Lopes

Received: 5 December 2007 / Accepted: 17 March 2008 / Published online: 26 March 2008
© Springer Science+Business Media B.V. 2008

Abstract Neuroparacoccidioidomycosis is the central nervous system involvement by *Paracoccidioides brasiliensis*, a condition that may be underdiagnosed and has been scarcely reported. We describe a case of neuroparacoccidioidomycosis in a diabetic male with

antecedent of heavy cigarette smoking and alcohol abuse. Thirty years before, he lived in the Amazon area and exerted rural activities in more recent years. The patient's main complaints were headache, visual deficit, hemiparesis, and weight loss. Imaging studies detected changes in the lungs and right adrenal gland, in addition to brain lesions. *Paracoccidioides brasiliensis* was found in tissue samples collected by the lung and brain biopsies. The patient is under ambulatory surveillance and in use of trimethoprim-sulfamethoxazole.

V. M. dos Santos
Catholic University Medical Course and Armed Forces Hospital (HFA), Brasilia, DF, Brazil

V. M. dos Santos · R. M. Xavier ·
E. M. C. Osterne · M. de Worisch Ferreira Lopes
Department of Internal Medicine from HFA, Armed Forces Hospital, Estrada do Contorno do Bosque s/n, Brasilia, DF 70630-900, Brazil

R. M. Xavier
e-mail: rogermxavier@yahoo.com.br

J. A. Cortes
Section of Pathology from HFA, Armed Forces Hospital, Estrada do Contorno do Bosque s/n, Brasilia, DF 70630-900, Brazil
e-mail: fazeco@abordo.com.br

E. M. C. Osterne
e-mail: ernestoosterne@yahoo.com.br

M. de Worisch Ferreira Lopes
e-mail: lourdesworisch@uol.com.br

V. M. dos Santos (✉)
SMPW Quadra 14 Conjunto 2 Lote 7 Casa A, Brasilia, DF 71745-140, Brazil
e-mail: vitorinomodesto@gmail.com

Keywords Central nervous system · Diagnosis · Neuroparacoccidioidomycosis · *Paracoccidioides brasiliensis* · Paracoccidioidomycosis.

Abbreviations

NPCM Neuroparacoccidioidomycosis
PCM Paracoccidioidomycosis
(T-SM) Trimethoprim-sulfamethoxazole

Introduction

Paracoccidioides brasiliensis is a dimorphic thermo-dependent fungus agent of paracoccidioidomycosis (PCM), a chronic disease that affects the skin, mucous membranes, lymph nodes, spleen, lungs, liver, adrenals, genitourinary tract, bones and joints, and the nervous system [1]. Paracoccidioidomycosis is the

most important human mycosis in Latin America and is endemic in areas of temperate humid climate [1–3]. Among all the reported cases in the whole world, 80% occurred in Brazil [4]. The inhalation of chlamydospores constitutes the main way of infection in PCM and is followed by a subclinical primary lung involvement. Reactivations can occur associated with immune depression and may originate the disseminated form of PCM, which affects the central nervous system (CNS) [2]. Neuroparacoccidioidomycosis (NPCM) is observed from 9.65 to 27.27% of these cases, presenting with meningitis, abscesses, or pseudotumoral manifestations [1–3]. Most patients are rural work males, with a mean age between 41.6 and 44.0 years [2, 5, 6]. The diagnosis of NPCM is often difficult and depends on the physician awareness. Asymptomatic or atypical presentations, unskilled neurological evaluation, and unavailable diagnostic methods play a role in the diagnostic pitfalls. The definitive diagnosis of NPCM is established by demonstration of *P. brasiliensis* in samples from the CNS. Treatment includes trimethoprim-sulfamethoxazole (T-SM), fluconazole, itraconazole, and amphotericin B [1, 3–5]. Neuroparacoccidioidomycosis mortality may reach 20% [1]; however, late detection usually results in worst prognosis [3, 4].

The aim of this report is to highlight the role of NPCM in the differential diagnosis of the CNS changes in people who have visited or lived in endemic areas of PCM.

Case Report

A 57-year-old man presented with severe occipital headache and reduced visual acuity. During the preceding 3 months, he noticed a progressive right hemiparesis, gait disturbance, anorexia, and loss of weight. There was a history of tobacco smoking (86 pack-years), in addition to of heavy alcoholism (for 43 years) with recent secondary diabetes mellitus. The patient had lived for 2 years in Manaus, Amazonas, Brazil, 30 years ago, and has frequently visited rural areas on the periphery of Brasilia-DF [1–3].

In another Hospital, he was submitted to a campimetry study, which revealed central scotoma in the temporal hemifield of right eye, and scotoma in the nasal hemifield of left eye. In addition, a

computed tomography (CT) of the head showed nodular lesions in the brain and in the cerebellum. With the diagnosis of intracranial hypertension due to the mass effect, a stereotactic brain biopsy was performed and dexametasone was prescribed associated to phenytoin. As the initial study of the samples showed very intense glial proliferation, the hypothesis of grade II fibrillary astrocytoma was raised and the patient was sent to oncology. The magnetic resonance imaging (MRI) of the head showed multiple lesions appearing hypointensive in T1 and hyperintensive in T2 and FLAIR (Fig. 1, Panels a–d), in addition to a conspicuous vasogenic edema indicative of an infectious etiology.

After the results of the MRI became known, a CT study of the chest and abdomen was done and disclosed nodular lesions scattered in both lungs (Fig. 1, Panel e), in addition to an expansive lesion in the right adrenal (Fig. 1, Panel f). Thence, a lung biopsy was done and the patient was referred to our Hospital. On admission, his Karnofsky score was 30 [4]. He was confused and dysphasic, presenting nystagmus, right hemiparesis, and ipsilateral Babinski sign, but without meningeal signs. There was no fever. The chest examination revealed sparse rhonchi that disappeared with coughing. His hemodynamical condition was stable, and the remaining physical data were unremarkable. Except for hemoglobin 10.3 g/dl, hematocrit 30.4%, and glucose 215 mg/dl, the routine laboratorial exams resulted within the normal range. In addition, the serologic tests for HIV 1 and HIV 2 were negative.

On the fourth day of admission, the fungus was found in the study of lung biopsy samples (Fig. 1, Panel g) and the diagnosis of pulmonary PCM was established. Thereafter, a very careful histopathological revision study was performed in the brain samples, and typical inflammatory changes with giant cells containing *P. brasiliensis* were finally disclosed (Fig. 1, Panel h). Furthermore, the double immunodiffusion test for *P. brasiliensis* was positive $\frac{1}{4}$, and pseudotumoral NPCM with intense reactive gliosis could be definitively characterized.

The patient initially received trimethoprim (480 mg daily) plus sulfamethoxazole (2,400 mg daily) associated with dexametasone (16 mg daily). During the first 5 months of treatment, a slowly progressive improvement has occurred, and Karnofsky score reached 50.

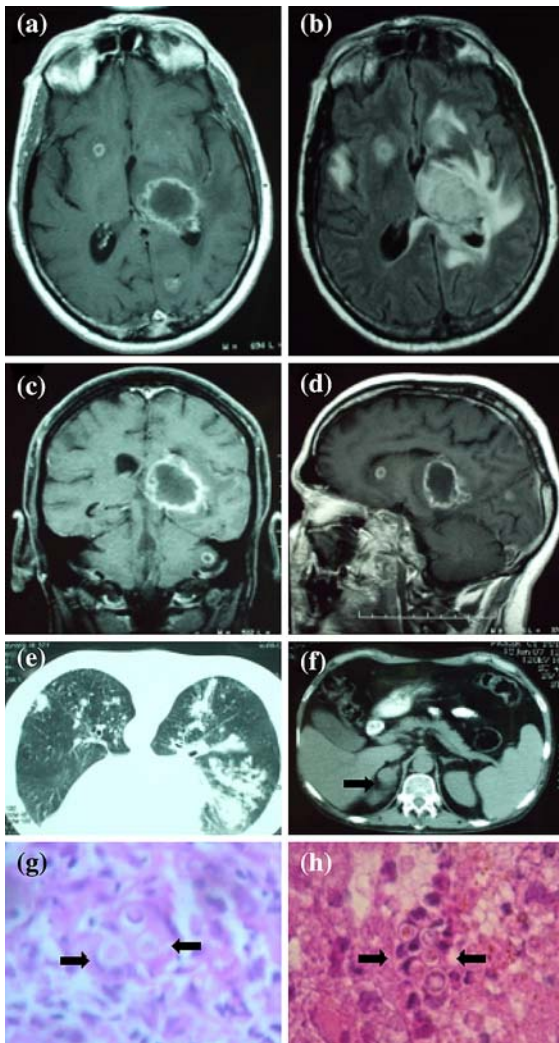


Fig. 1 Panel a–d shows T1 and T2-weighted images of the cerebral and the cerebellar lesions, with ring enhancement after the contrast injection. The changes appear with low-intensity signal in T1 (Panels a, c, and d), and are hyperintense in T2 and FLAIR (Panel b). Panel e shows the multiple nodular lesions revealed by CT in both lung fields. Panel f shows the expansive lesion disclosed by CT in the adrenal gland (arrow). Panel g shows the microscopic features of the lung biopsy, with conspicuous granulomatous inflammation and the giant cells' phagocytosis of fungi (arrows) that appears with characteristics of *P. brasiliensis* (hematoxylin and eosin stain, 40× magnification). Panel h shows the microscopic aspect of brain tissue, demonstrating great number of *P. brasiliensis* (arrows) inside a granuloma (hematoxylin and eosin stain, 40× magnification)

Discussion

Based on clinical reports, the involvement of CNS occurs in up to 27.27% of the cases of disseminated

PCM [1] and can reach 36% of cases in autopsy studies [7]. Neuroparacoccidioidomycosis diagnosis depends on demonstration of the agent in samples from the CNS or positive serology test (as double immunodiffusion) [2, 3, 5] associated to imaging compatible with involvement of the CNS by *P. brasiliensis*. Paracoccidioidomycosis can cause subacute or chronic meningoencephalitis [3, 4, 7, 8]; however, the pseudotumoral clinical presentation due to CNS granuloma is more frequent. Typical granulomas appear as hypodense images with nodular or annular contrast enhancing. They are frequently multiple and occur in the cerebral hemispheres, thalamus, cerebellum, or brainstem, and have been scarcely found in the spinal cord [3, 4, 6, 9, 10]. The symptoms of NPCM may appear before, simultaneously, or after the systemic symptoms [2, 5]. The most common manifestations are headache, paresis, seizures, and gait disturbance [2, 6]. The pseudotumoral presentations must be differentiated from CNS primary and secondary tumors, abscesses, cysts, and other granulomatous diseases [1, 3, 4, 7]. As the differential diagnosis among these expanding lesions is commonly difficult [2], in special if surgical, stereotactic biopsy, or autopsy specimens are not disposable [8], authors believe that NPCM is more frequent than previously admitted [1, 2, 7, 9].

The patient is HIV negative. As disseminated PCM and NPCM have been associated with primary or secondary immunodepression [2–4, 7], a major concern is about possible role of heavy alcoholism and diabetes mellitus in mechanisms that modify the cellular immunity or IFN-gama production [1, 3, 6]. Moreover, the long time between the probable date of infection and the onset of symptoms suggests some permissive change in his immunological system.

In the present case, there was an initial histopathologic misdiagnosis with the fibrillary grade II astrocytoma. This problem occurs because an increased cellularity and some nuclear atypia may be seen both in grade II astrocytoma and reactive gliosis due to CNS damage [11]. Diagnostic pitfalls between gliomas and pseudotumoral NPCM may also be due to some features in common: male gender, age at onset over 40 years, presenting symptoms (headache, mental changes, neurological deficit, and seizures), and MRI images that appear hypointense on T1 and hyperintense on T2 and may show contrast enhancement [11]. Notwithstanding, the patient was

not submitted to an unwanted surgery as could occur in such mistaken cases [12]. Although the finding of multiple CNS lesions did not favor a primary cancer, the exact nature of his brain changes started to be cleared only during the oncology procedures (previous to “astrocytoma” resection and radiation therapy), because scattered nodules were shown by chest CT and a diagnostic lung biopsy was mandatory. Due to his antecedent heavy smoking, another concern was about possible secondary or primary lung cancers, with CNS metastases.

The patient was treated with T-SM plus corticosteroids, and the clinical response is considered satisfactory. Indeed, T-SM constitutes a major therapeutic option against NPCM, either alone or in association with amphotericin B or imidazoles [3–5, 7]. Although a possible concern could be about the use of corticosteroids in fungus infections, these drugs have been employed to reduce the inflammatory edema observed around the CNS granulomas [4, 7].

A high index of suspicion about NPCM should be raised because clinical and CT data were indicative of CNS expansive process in an individual who had lived in endemic area [2]. However, the evidence of infection appeared in this patient for a very long time after leaving the endemic region [2, 3], fact that makes more difficult to establish a causal relationship.

Neuroparacoccidioidomycosis usually occurs in inhabitants or individuals who have visited endemic areas. The importance of NPCM in the differential diagnosis of CNS tumors is highlighted, because the prognosis of both conditions depends on the precocity of diagnosis and specific therapy.

References

1. Tristano AG, et al. Central nervous system paracoccidioidomycosis: case report and review. *Invest Clin.* 2004; 45:277–88.
2. de Almeida SM. Central nervous system paracoccidioidomycosis: an overview. *Braz J Infect Dis.* 2005;9:126–33.
3. Leal Filho MB, et al. Paracoccidioidomycose em hemisfério cerebral e tronco encefálico: relato de caso. [Paracoccidioidomycosis in cerebral hemisphere and brainstem: case report]. *Arq Neuropsiquiatr.* 2006;64:686–9.
4. Fagundes-Pereyra WJ, et al. Paracoccidioidomycose do sistema nervoso central. [Central nervous system paracoccidioidomycosis: analysis of 13 cases]. *Arq Neuropsiquiatr.* 2006;64:269–76.
5. de Almeida SM, et al. Central nervous system paracoccidioidomycosis: clinical features and laboratorial findings. *J Infect.* 2004;48:193–8.
6. Paniago AM, et al. Neuroparacoccidioidomycosis: analysis of 13 cases observed in an endemic area in Brazil. *Trans R Soc Trop Med Hyg.* 2007;101:414–20.
7. Silva CEAP, et al. Paracoccidioidomycose do sistema nervoso central. [Paracoccidioidomycosis of the central nervous system: case report]. *Arq Neuropsiquiatr.* 2000;58:741–7.
8. Lorenzoni PJ, et al. Meningite paracoccidioidomycótica. [Paracoccidioidomycosis meningitis]. *Arq Neuropsiquiatr.* 2002;60:1015–8.
9. Elias J Jr, et al. Central nervous system paracoccidioidomycosis: diagnosis and treatment. *Surg Neurol.* 2005;63: S13–S21.
10. Plá MP, et al. Neuroparacoccidioidomycosis: case reports and review. *Mycopathologia.* 1994;127:139–44.
11. Wessels PH, et al. Supratentorial grade II astrocytoma: biological features and clinical course. *Lancet.* 2003;2:395–403.
12. Lambertucci JR, et al. Paracoccidioidomycose do sistema nervoso central. [Paracoccidioidomycosis of the central nervous system]. *Rev Soc Bras Med Trop.* 2001;34:395–6.