


available at www.sciencedirect.comjournal homepage: www.elsevier.com/locate/cortex

Letter to Cortex

Incomplete ipsilesional hallucinations in a patient with neglect

Gu drun M.S. Nys^{a,*}, Tanja C.W. Nijboer^{b,c} and Edward H.F. de Haan^{b,c}

^aLaboratory for Neuropsychology, Department of Neurology, Ghent University, Belgium

^bDepartment of Experimental Psychology, Helmholtz Institute, Utrecht University, The Netherlands

^cUniversity Medical Center Utrecht, Department of Neurology, The Netherlands

Visual hallucinations (VH) have been reported in a variety of neurological conditions, such as occipital epilepsy, migraine, and Lewy Body Dementia (Manford and Andermann, 1998). A substantial number of patients with a posterior stroke initially experience VH (e.g., De Haan et al., 2007), often receding in the ensuing weeks. These hallucinations usually occur in the contralesional hemianopic field. There are only a few reports on the coexistence of hemi-neglect and VH (Chamorro et al., 1990; Mesulam, 1981). In this study, we describe a patient with left-sided neglect who experienced incomplete (right-side-only) hallucinations in the right intact hemifield. She does not have a history of alcohol abuse, delirium, psychiatric problems or psycho-stimulant medication use. We investigated her visuosensory status, visual perception and neglect.

1. Case report

LZ is a 66-year-old right-handed female, who suffered a subarachnoid haemorrhage in September 2000. One day post-surgery (clipping), LZ developed vasospasms resulting in a large right-hemispheric infarction involving occipital, parietal, temporal and frontal regions. Retrospection of early neuropsychological reports suggested perceptual impairment and severe left-sided neglect. In 2005, LZ's husband noticed that she experienced language problems and she was brought into the hospital where a subdural haematoma was detected in the left hemisphere. The language disorder disappeared following the placement of a subdural drain.

1.1. Report of hallucinations

When LZ was admitted to our lab (July 2006), she reported regularly perceiving objects or animals which were not actually there. She experienced these VH since her first stroke. She had never informed her husband because she feared being delusional. The hallucinations were realistic and appeared consistently in the right hemifield or occasionally in central areas. LZ realised that these images were hallucinations because “in contrast to the rest of the world, these images are incomplete on the left”. The images always fit in the environment and always had the correct colour or form; they moved, but when she moved her eyes or head in any direction or closed her eyes the images disappeared. The images were only present during the day and appeared only briefly (seconds). As an example, she told us that she frequently saw incomplete ducks (only right-side visible) in the canal in front of her house. During the week following this interview, LZ told her husband that she saw half of a duck again. Apparently, there was a duck but her husband reported that it was swimming somewhere else on her left side. Other examples consisted of children on hemi-bicycles in her street or hemi-rabbits in the park, and it remained unclear whether these objects were actually present on the left as the content of the ‘hallucination’ usually fit the scene. According to LZ, unrealistic images were rare and were basically limited to the early phase post-stroke. For example, a frequent hallucination at that time was that she constantly saw her (deceased) mother on the painting in the hospital.

* Corresponding author. Laboratory for Neuropsychology, Ghent University Hospital, De Pintelaan 185 (4K3), B-9000 Ghent, Belgium.

E-mail address: gu drun.nys@ugent.be (G.M.S. Nys).

0010-9452/\$ – see front matter © 2007 Elsevier Masson Srl. All rights reserved.

doi:10.1016/j.cortex.2007.10.009

1.2. Neuropsychological examination

LZ showed left-sided neglect on the Behavioural Inattention Test (Wilson et al., 1987): Line-Bisection 3/9, Star-Cancellation 47/54, Letter-Cancellation 35/40, Line-Cancellation 30/36, Figure-and-Shape-Copying 1/4, and Representational-Drawing 2/3. Dynamic perimetry showed consistent misses in the left visual field which – in addition to her neglect – could be indicative of a comorbid hemianopia. As a test for representational neglect (Rousseaux et al., 2001), LZ was asked to imagine the map of the Netherlands and name as many towns as possible from Workum (town in the north where she lives) looking south and from Breda (town in the south) looking north (2 min per viewpoint). She solely named locations towards the right from the imagined viewpoint (Fig. 1).

Object recognition was intact (Boston Naming Test short form: 81/90), but LZ was impaired on degraded object perception (Visual Object and Space Perception battery – VOSP: Warrington and James, 1991). Space perception was severely impaired; she typically perceived items in the left field as appearing on the right side (VOSP), and showed spatial transposition of contralesional items towards the right side while copying (Rey Complex Figure) and in visual memory (modified

Location Learning Task) (Kessels et al., 2006) (Fig. 1). This transposition from left to right on both perceptual and visuo-motor tasks has frequently been termed ‘allochiria’ (Lepore et al., 2004).

2. Discussion

This is the first report of incomplete hemi-hallucinations in a patient with neglect. So far, incompleteness of hallucinations has only once been reported in a patient who suffered from an occipital stroke resulting in a quadrantanopia (Vogelely and Curio, 1998). The VH consisted of the lower half of human figures which were limited to the borders of the patients’ quadrantanopic field defect. The authors attributed the incompleteness of the hallucinations to ‘an aperture effect’, as if the deafferented quadrant of the primary visual cortex was allowing in a part of the endogenously created image only at that location in the visual field (i.e., left lower quadrant). In our patient, such an aperture effect cannot account for the incomplete hallucinations as LZ demonstrated no field effects on the right side of space where she hallucinated.

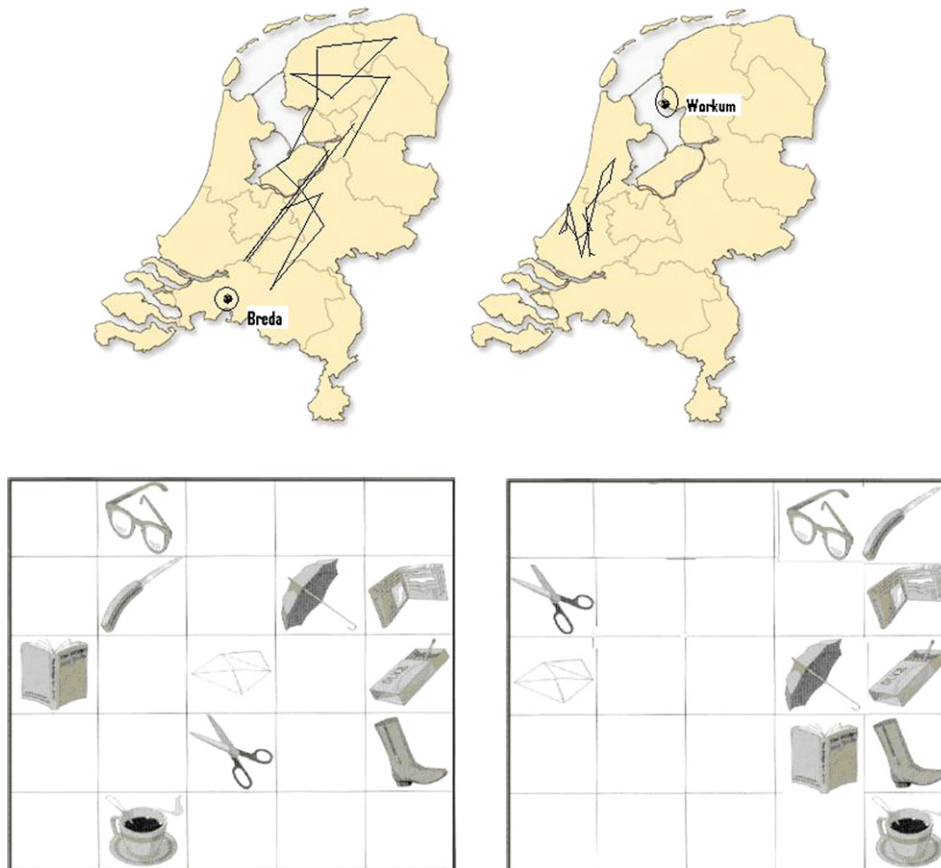


Fig. 1 – Top: left: LZ’s enumeration of Dutch towns/villages from the Breda viewpoint when looking at the north of the Netherlands and right: LZ’s enumeration of Dutch towns/villages from the Workum viewpoint when looking at the south of the Netherlands. From both viewpoints, only right-sided locations are reported. Bottom: original stimulus material (mLLT) (left) and objects placed on trial 3 (right).

Intriguingly, LZ was fully aware of the missing parts in her 'hallucinations', whereas she was rarely aware that she missed items on the left in real life or when forming an endogenous image to command (e.g., the map of the Netherlands). Although it is well-known that neglect patients may show a dissociated spatial performance in processing imagined versus realistic images (Bisiach and Luzzatti, 1978), this is the first report of a dissociation in neglect-related awareness between imagining objects to command and spontaneous endogenously generated images.

Several mechanisms may account for LZ's hallucinations. First, given LZ's allochiria, a potential neuropsychological mechanism is that she displaced real objects on the left towards the right, which due to additional hemianopia and/or object-based neglect resulted in an incomplete image. In other words, this could mean that LZ was misinterpreting real objects in her left hemifield as hallucinations, i.e., a kind of reverse hallucination, in that perception of real objects – because of an incomplete rendering and a shift in location – are perceived as “not real”. An alternative explanation might be that the patient suffers from endogenously created hallucinations, perhaps partly triggered by the environmental context, which are incomplete because of her representational neglect.

In conclusion, our patient experienced neglect and complex hemi-hallucinations in the attended hemifield for years. This is the first report of hemi-hallucinations in a patient with neglect with an intriguing selectiveness in location and awareness, i.e., she was aware of the incompleteness of the hallucinations but she was rarely aware that she neglected items in real life.

Acknowledgements

This study was performed when the first author was still working at Utrecht University. GN is now working as a post-doctoral researcher for FWO (Belgium). We thank the patient and her husband for their never ending cooperation and good humor. We would like to thank Dr. Ralph Hoffman and an anonymous reviewer for their suggestions on an earlier draft of this manuscript.

REFERENCES

- Bisiach E and Luzzatti C. Unilateral neglect of representational space. *Cortex*, 14: 129–133, 1978.
- Chamorro A, Sacco RL, Ciecierski K, Binder JR, Tatemichi TK, and Mohr JP. Visual hemineglect and hemihallucinations in a patient with a subcortical infarction. *Neurology*, 40: 1463–1464, 1990.
- De Haan EHF, Nys GMS, Van Zandvoort MJE, and Ramsey NF. The physiological basis of visual hallucinations after damage to the primary visual cortex. *Neuroreport*, 18: 1177–1180, 2007.
- Kessels RPC, Nys GMS, Brands AMA, Van den Berg E, and Van Zandvoort MJE. The modified location learning test: norms for the assessment of spatial memory function in neuropsychological patients. *Archives of Clinical Neuropsychology*, 21: 841–846, 2006.
- Lepore M, Conson M, Ferrigno A, Grossi D, and Trojano L. Spatial transpositions across tasks and response modalities: exploring representational allochiria. *Neurocase*, 10: 386–392, 2004.
- Manford M and Andermann F. Complex visual hallucinations. Clinical and neurobiological insights. *Brain*, 121: 1819–1840, 1998.
- Mesulam MM. A cortical network for directed attention and unilateral neglect. *Annals of Neurology*, 10: 309–325, 1981.
- Rousseaux M, Beis JM, Pradat-Diehl MY, Bartolomeo P, Bernati T, Chokron S, Leclercq M, Louis-Dreyfus A, Marchal F, Perennou D, Prairial C, Rode G, Samuel C, Sieroff E, Wiart L, and Azouvi P. Presenting a battery for assessing spatial neglect. Norms and effects of age, educational level, sex, hand and laterality. *Revue Neurologique*, 157: 1385–1400, 2001.
- Vogele K and Curio G. Pictorial pseudohallucinations with an “aperture effect” in a patient with quadrantanopia. *Journal of Neurology, Neurosurgery and Psychiatry*, 65: 275–277, 1998.
- Warrington EK and James M. *Visual Object and Space Perception Battery*. Bury St. Edmunds, UK: Thames Valley Test Company, 1991.
- Wilson B, Cockburn J, and Halligan P. Development of a behavioral test of visuospatial neglect. *Archives of Physical Medicine and Rehabilitation*, 68: 98–102, 1987.

Received 4 April 2007

Reviewed 30 July 2007

Revised 18 September 2007

Accepted 29 October 2007

Action editor Yves Rossetti

Published online 27 December 2007