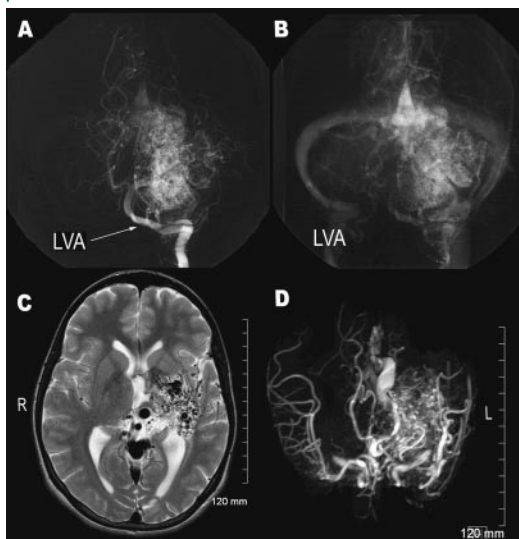


Giant arteriovenous malformation presenting as pediatric task-specific dystonia



Figure 1 Left vertebral artery (LVA) angiogram, sagittal T2 MR imaging, and MRA



Arterial (A) and venous phase (B) of the LVA angiogram in anteroposterior view showing the giant arteriovenous malformation (AVM) that involves the left thalamus and putamen and extends to the left medial temporal lobe. The giant AVM presented as task-specific dystonia that progressed to right hemidystonia. (C) Sagittal T2 MR imaging demonstrates the large left cerebral hemispheric AVM involving the left temporal lobe, left basal ganglia, and left thalamus. (D) MRA demonstrates the large tangle of vessels in the left hemisphere consistent with the AVM.

Figure 2 Posturing of the right upper limb as part of right hemidystonia associated with the left deep hemispheric arteriovenous malformation



An 11-year-old girl presented with difficulties writing and playing the flute for 6 months. Her dystonic symptoms progressively involved her right shoulder and arm muscles, and by age 16 right hemidystonia was diagnosed (see video on the *Neurology*[®] Web site at www.neurology.org). Brain MRI revealed a Spetzler–Martin grade V (>6 cm)¹ left deep hemispheric arteriovenous malformation (AVM). Arteriography confirmed the finding (figure 1). Embolizations did not produce clinical benefit. Surgical radiotherapy and deep brain stimulation were contraindicated. Oral medications failed to control symptoms and botulinum toxin type A injections improved dystonia but were associated with limb weakness. Although rare,² AVMs should be considered in the differential diagnosis of pediatric task-specific dystonia (figure 2).

Spiridon Papapetropoulos, MD, PhD, Carlos Singer, MD, Cenk Sengun, MD, and Bruno V. Gallo, Miami, FL

Disclosure: The authors report no conflicts of interest.

Address correspondence and reprint requests to Dr. Spiridon Papapetropoulos, Department of Neurology, University of Miami, Miller School of Medicine, 1501 NW 9th Avenue (NPF), Room 2017, Miami, FL 33136; spapapetropoulos@med.miami.edu

1. Spetzler RF, Martin NA. A proposed grading system for arteriovenous malformations. *J Neurosurg* 1986;65:476–483.
2. Kurita H, Sasaki T, Suzuki I, Kirino T. Basal ganglia arteriovenous malformation presenting as “writer’s cramp.” *Childs Nerv Syst* 1998;14:285–287.

Neurology[®]

Giant arteriovenous malformation presenting as pediatric task-specific dystonia

Spiridon Papapetropoulos, Carlos Singer, Cenk Sengun, et al.

Neurology 2008;70;1294

DOI 10.1212/01.wnl.0000306637.14628.76

This information is current as of April 7, 2008

Updated Information & Services	including high resolution figures, can be found at: http://www.neurology.org/content/70/15/1294.full.html
Supplementary Material	Supplementary material can be found at: http://www.neurology.org/content/suppl/2008/04/07/70.15.1294.DC1.html
References	This article cites 2 articles, 0 of which you can access for free at: http://www.neurology.org/content/70/15/1294.full.html##ref-list-1
Subspecialty Collections	This article, along with others on similar topics, appears in the following collection(s): Arteriovenous malformation http://www.neurology.org/cgi/collection/arteriovenous_malformation Dystonia http://www.neurology.org/cgi/collection/dystonia
Permissions & Licensing	Information about reproducing this article in parts (figures, tables) or in its entirety can be found online at: http://www.neurology.org/misc/about.xhtml#permissions
Reprints	Information about ordering reprints can be found online: http://www.neurology.org/misc/addir.xhtml#reprintsus

Neurology® is the official journal of the American Academy of Neurology. Published continuously since 1951, it is now a weekly with 48 issues per year. Copyright . All rights reserved. Print ISSN: 0028-3878. Online ISSN: 1526-632X.

