

# Multifocal glioblastoma multiforme with synchronous spontaneous hemorrhage: case report

Ronald J. Benveniste · Glen Manzano ·  
Carol K. Petito

Received: 15 January 2008 / Accepted: 28 March 2008 / Published online: 12 April 2008  
© Springer Science+Business Media, LLC. 2008

**Abstract** We report a 65 year old man who presented with left hemiparesis, and was found to have multiple, discrete, peripherally enhancing, hemorrhagic intra-axial masses in the right hemisphere of the brain. Workup for malignancy elsewhere in the body was negative, and biopsy confirmed glioblastoma multiforme. The patient responded clinically to treatment with radiation therapy and temozolomide. We discuss the unusual aspects of this case and stress the importance of tissue diagnosis in managing suspected intracranial malignancies.

**Keywords** Biopsy · Glioma · Hemorrhage · Multifocal glioblastoma multiforme

## Introduction

Malignant glioma generally presents radiographically as a single, contrast enhancing mass on MRI. In rare cases, malignant gliomas may show multicentricity or true multifocality. A minority of malignant gliomas present with spontaneous hemorrhage. We report a patient with multiple hemorrhagic brain tumors in whom metastasis was strongly suspected; however, biopsy confirmed glioblastoma

multiforme, which resulted in a significant change in treatment strategy.

## Case report

A 65 year old, right handed man presented with several days of left sided weakness. He was not taking aspirin or anticoagulants. On examination, he was alert and cooperative. Visual fields were full to confrontation. He had a dense left hemiparesis affecting the upper greater than the lower extremity, and left sided sensory loss. Magnetic resonance imaging showed three, peripherally enhancing masses in the right hemisphere, all of which showed evidence of spontaneous hemorrhage (Fig. 1). The masses were separated by normal appearing brain, although there was T2 and FLAIR signal change surrounding the lesions that was thought to represent vasogenic edema. Steroids and anticonvulsants were administered.

CT of the chest, abdomen, and pelvis was negative. A large mole on the leg was biopsied by a dermatologist and was negative for melanoma. The patient underwent a frameless stereotactic biopsy of the right parieto-occipital lesion.

Microscopic analysis of the biopsy specimen showed a glioblastoma multiforme, with nuclear atypia, endothelial hyperplasia, and areas of necrosis with pseudopalisading (Fig. 2a). The tumor cells were immunoreactive for glial fibrillary acidic protein (GFAP; Fig. 2b). Markers for melanoma (HMB-45 and melan-A) and renal cell carcinoma antigen were negative.

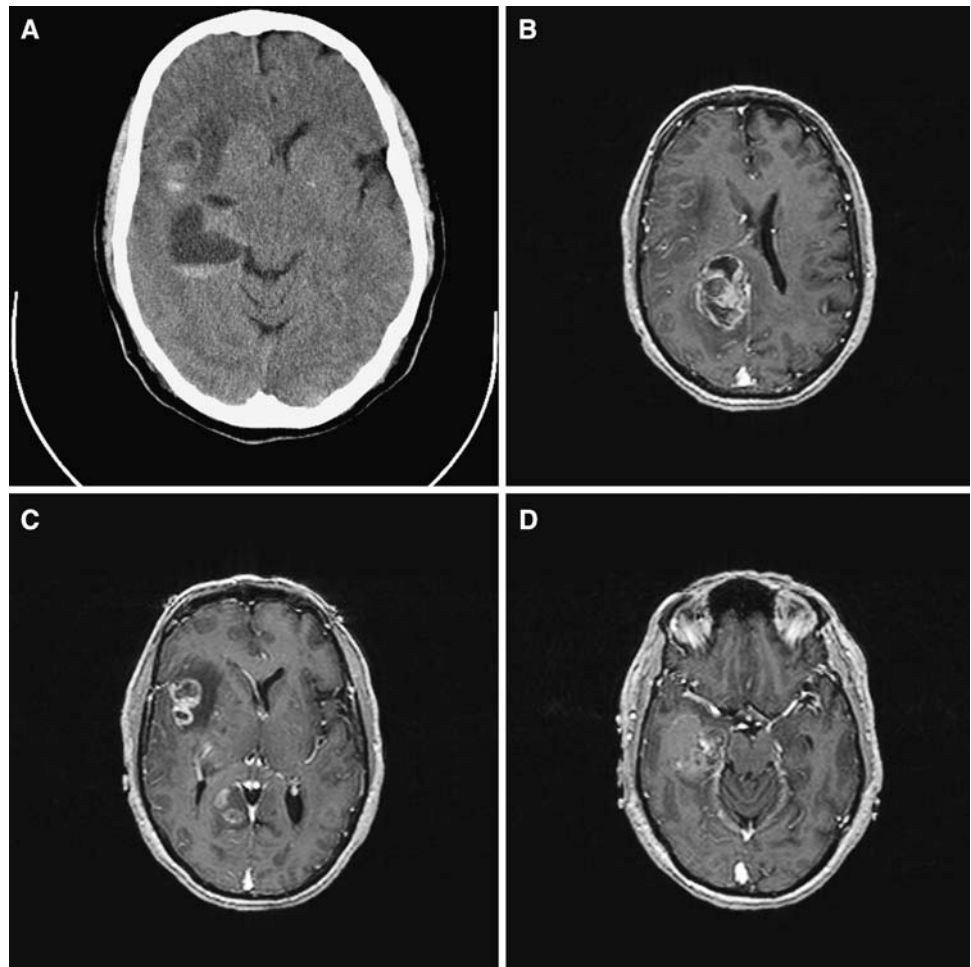
The patient was treated with 59.4 Gy of radiation therapy with concurrent and adjuvant temozolomide. His hemiparesis rapidly improved, and after a course of rehabilitation

---

R. J. Benveniste (✉) · G. Manzano  
Department of Neurosurgery, University of Miami Miller School of Medicine, Lois Pope LIFE Center, 1095 NW 14th Terrace (D4-6), Miami, FL 33136, USA  
e-mail: RBenveniste@med.miami.edu

C. K. Petito  
Department of Pathology, University of Miami Miller School of Medicine, Miami, FL, USA

**Fig. 1 (a):** Nonenhanced CT scan shows hemorrhage into right temporal and Sylvian fissure tumors **(b, c, d):** Gadolinium-enhanced MRI scan shows discrete, peripherally enhancing tumors in the right frontal-parietal lobe **(b)**, right Sylvian fissure **(c)**, and right temporal lobe **(d)**



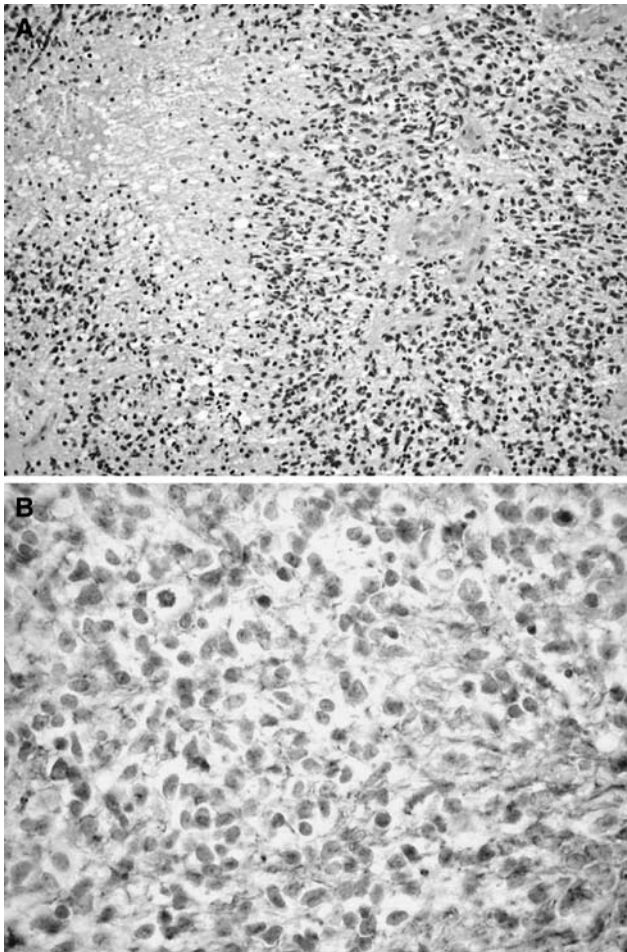
he was discharged home four weeks postoperatively with only minimal weakness in the left upper extremity.

## Discussion

### Incidence and significance of multifocal and multicentric glioma

Most malignant gliomas present as single, contrast enhancing masses. However, glioma cells are widely distributed through the brain even in patients harboring these typical appearing tumors [1]. Dissemination of glioma cells through the brain may be related to origin in the subventricular zone [2], and generally proceeds along both white matter tracts and blood vessels [3]. This wide dissemination of glioma cells is occasionally manifested radiographically as a multiple glioma, in which areas of mass effect and/or contrast enhancement are separated by radiographically normal or abnormal appearing brain [4]. Cytogenetic analysis and sequencing of mutated genes in biopsies of multiple glioma show that the separate lesions

represent dissemination of a single clone of tumor cells [5]. In older literature, the terms “multicentric glioma” and “multifocal glioma” were often used interchangeably to describe multiple gliomas [6, 7], while in some cases “multicentric gliomas” referred only to multiple tumors without radiographic or histologic connection [8]. More recently, in the MRI era, other classification schemes have been proposed. Under one classification scheme, multicentric gliomas are those in which focal lesions are arranged along contiguous white matter tracts, while multifocal gliomas are those in which the focal lesions are not connected by white matter tracts [9]. Under another commonly used scheme, multicentric gliomas are those in which either known white matter tracts or radiographically abnormal brain connects the mass lesions, while multifocal lesions are not connected in either of these ways [10]. In the MRI era, about 1% of malignant gliomas are multiple at the time of diagnosis, with the incidence increasing to 10% or more at the time of tumor progression [11]. There are no reliable radiographic criteria for distinguishing multiple gliomas from multiple metastases [4]. Multiple gliomas are associated with a worse prognosis than more focal gliomas



**Fig. 2** (a): Photomicrograph of biopsy specimen showing typical glioblastoma multiforme with nuclear atypia, endothelial proliferation, and necrosis (hematoxylin and eosin, 200 $\times$ ). (b): Immunohistochemistry with antisera to glial fibrillary acidic protein (GFAP) shows strong labeling of tumor cells (400 $\times$ )

particularly if the dissemination occurs at the time of tumor progression following initial treatment [11]. Treatment is radiation therapy with or without concurrent chemotherapy; survival is similar whether the radiation fields encompass only the radiographically visible tumor with a margin, or the entire brain [10].

#### Incidence of spontaneous hemorrhage into glioblastoma

Malignant brain tumors prone to spontaneous hemorrhage include metastases from melanoma, renal cell carcinoma, and choriocarcinoma, and glioblastoma multiforme. Previously published reports described spontaneous hemorrhage into malignant gliomas in infants with congenital glioblastoma [12], as well as in adults [13, 14]. This report is the first in which synchronous spontaneous hemorrhage has been described in a multifocal glioblastoma. We cannot explain the mechanism of synchronous

hemorrhage in this patient without a history of bleeding disorder or treatment with anticoagulants or antiplatelet agents. Koebbe et al. (2001) reported two cases of multifocal glioma in which surgery on one tumor mass resulted in hemorrhage into a noncontiguous tumor mass, and suggested that coagulopathy induced by manipulation of tumor tissue, combined with hemodynamic changes and fragile blood vessels at distant tumor sites, might explain this phenomenon [15]. If this model is accurate, we may speculate that spontaneous hemorrhage into one lesion in this patient may have induced hemorrhage into the other lesions.

#### Importance of tissue diagnosis in patients with malignant brain tumors

When confronted with multiple, hemorrhagic brain lesions, metastasis from melanoma, renal cell carcinoma, or less likely other systemic cancers is the most likely diagnostic possibility. This is particularly true in patients with known histories of cancer, in whom 91% of contrast enhancing brain lesions in the era spanning CT and early MR imaging were shown to be metastasis at surgery [16]. However, as shown by this case report, multiple glioma is also a possible cause of multiple, hemorrhagic brain tumors. 30 Gy of whole brain radiation in 10 fractions would be appropriate for unresectable multiple brain metastases [17], while 59 Gy of radiation therapy delivered to the visible tumor plus margin, or alternatively the whole brain, with concurrent or adjuvant temozolomide, is the most widely accepted therapy for multifocal glioblastoma [10].

#### Conclusions

We describe the first reported case in the English language literature of multifocal glioblastoma with spontaneous hemorrhage into multiple lesions. This presentation is most commonly associated with metastases from melanoma or renal cell carcinoma, which would be treated differently than glioblastoma. This case emphasizes the importance of tissue diagnosis in optimizing the treatment of patients with malignant brain tumors.

#### References

1. Silbergeld DL, Chicoine MR (1997) Isolation and characterization of human malignant glioma cells from histologically normal brain. *J Neurosurg* 86:525–531
2. Lim DA, Cha S, Mayo MC, Chen MH, Keles E, VandenBerg S, Berger MS (2007) Relationship of glioblastoma multiforme to neural stem cell regions predicts invasive and multifocal tumor. *Neuro-oncol* 9:424–429

3. Guillema JS, Lisovsky F, Christov C, Le Guérinel C, Defer GL, Peschanski M, Lefrançois T (2001) Migration pathways of human glioblastoma cells xenografted into the immunosuppressed rat brain. *J Neurooncol* 52:205–215
4. Lafitte F, Morel-Precetti S, Martin-Duverneuil N, Guermazi A, Brunet E, Heran F, Chiras J (2001) Multiple glioblastomas: CT and MR features. *Eur Radiol* 11:131–136
5. Krex D, Mohr B, Appelt H, Schackert HK, Schackert G (2003) Genetic analysis of a multifocal glioblastoma multiforme: a suitable tool to gain new aspects in glioma development. *Neurosurgery* 53:1377–1384
6. Barnard RO, Geddes JF (1987) The incidence of multifocal cerebral gliomas: a histologic study of large hemisphere sections. *Cancer* 60:1519–1531
7. Van Tassel P, Lee YY, Bruner JM (1988) Synchronous and metachronous malignant gliomas: CT findings. *AJNR Am J Neuroradiol* 9:725–732
8. Djalilian HR, Shah MV, Hall WA (1999) Radiographic incidence of multicentric malignant gliomas. *Surg Neurol* 51:554–557
9. Ampil F, Burton GV, Gonzalez-Toledo E, Nanda A (2007) Do we need whole brain irradiation in multifocal or multicentric high-grade cerebral gliomas? Review of cases and the literature. *J Neurooncol* 85:353–355
10. Showalter TN, Andrel J, Andrews DW, Curran WJ Jr, Daskalakis C, Werner-Wasik M (2007) Multifocal glioblastoma multiforme: prognostic factors and patterns of progression. *Int J Radiat Oncol Biol Phys* 69:820–824
11. Parsa AT, Wachhorst S, Lamborn KR, Prados MD, McDermott MW, Berger MS, Chang SM (2005) Prognostic significance of intracranial dissemination of glioblastoma multiforme in adults. *J Neurosurg* 102:622–628
12. Seker A, Ozek MM (2006) Congenital glioblastoma multiforme. Case report and review of the literature. *J Neurosurg* 105(6 Suppl):473–479
13. Schrader B, Barth H, Lang EW, Buhl R, Hugo HH, Biederer J, Mehdorn HM (2000) Spontaneous intracranial haematomas caused by neoplasms. *Acta Neurochir (Wien)* 142:979–985
14. Misra BK, Steers AJW, Miller JD, Gordon A (1988) Multicentric glioma presenting with hemorrhage. *Surg Neurol* 29:73–76
15. Koebe CJ, Sherman JD, Warnick RE (2001) Distant wounded glioma syndrome: Report of two cases. *Neurosurgery* 48:940–944
16. Patchell RA, Tibbs PA, Walsh JW, Dempsey RJ, Maruyama Y, Kryscio RJ, Markesbery WR, Macdonald JS, Young B (1991) A randomized trial of surgery in the treatment of single metastases to the brain. *New Engl J Med* 322:494–500
17. Chang SD, Adler JR Jr (2000) Current treatment of patients with multiple brain metastases. *Neurosurg Focus* 9(2):e5