

M. Elena Erro Aguirre
Teresa Ayuso Blanco
Teresa Tuñón Álvarez
María Herrera Isasi

Brain hemorrhage as a complication of chronic hepatitis C virus-related vasculitis

Received: 7 February 2007
Received in revised form: 10 July 2007
Accepted: 21 August 2007
Published online: 5 May 2008

Sirs: Central nervous system involvement in chronic hepatitis C virus (HCV) infection is rare [7]. The presumed mechanism of brain damage is attributed to ischemia [10, 11] and extensive brain hemorrhages have rarely been reported [4, 5]. We describe a patient with HCV infection and cryoglobulinemia who suffered fatal hemorrhagic stroke.

A 76 year-old woman was referred to us with a 2-year history of cutaneous purpura, arthralgias, asthenia, numbness and paresthesias in all four limbs. An axonal sensorimotor polyneuropathy was evident on electrophysiologic study. HCV serology revealed a chronic infection with cryoglobulinemia and six months later she was admitted for the performance of a liver biopsy (Table 1). Four days after the procedure she sud-

Table 1 Laboratory findings

Cryoglobulin level (g/dL)	64
Cryoglobulin type	polyclonal IgG, IgA and IgM (type III)
HCV RNA (eq/ml)	1,127,000
HCV genotype	1b
AST (U/L)	29
ALT (U/L)	42
Platelet count*	277,000
Prothrombin time*	85%
Fibrinogen (mg/dL)*	221

* coagulation parameters performed the day of the first brain hemorrhage

denly developed a decrease of consciousness and the computerized tomography (CT) scan showed a left fronto-parietal brain hemorrhage (Fig. 1A). Four days later she suffered left partial seizures and the CT revealed another large right hemispheric hemorrhage with subdural extension (Fig. 1B). The patient died and a post-mortem examination was performed. The gross pathology of the brain showed bilateral parenchymal and subdural hemorrhage (Fig. 1C, D). No thrombus appeared in the longitudinal sinus. Microscopic findings displayed a leukocytoclastic vasculitis of medium size corticomeningeal arterioles (Fig. 1E, F). The inflammatory infiltrate was composed of polymorphonuclear neutrophils and mononuclear cells. Segmental fibrinoid necrosis could be observed suggestive of PAN-type vasculitis that was also found in the muscle and nerve. Beta-amyloid immunohistochemistry was negative.

This patient with chronic HCV infection and cryoglobulins developed fatal hemorrhagic stroke. A vasculitic process seems to be the leading pathogenic factor. Hypertension or coagulopathy were absent and a PAN-type vasculitis of corticomeningeal arterioles was found on post-mortem study. An amyloid angiopathy was ruled out

by means of beta-amyloid immunohistochemistry.

Chronic HCV infection may be associated with two types of vasculitis: mixed cryoglobulinemia and PAN-type vasculitis [1–3]. Differentiation between both types may be controversial since they may share the same clinical manifestations [2]. Even more, mixed cryoglobulinemia may be present in the serum in both groups [1]. Pathologic lesions are different. The classic PAN-type vasculitis involves medium and small size vessels with a mixed inflammatory infiltrate of mononuclear and polymorphonuclear cells and a necrotizing angiitis, whereas mixed cryoglobulinemia involves small size vessels with an inflammatory infiltrate of mononuclear cells with no necrotizing lesions. Patients with HCV PAN-type vasculitis have been reported to have very severe acute clinical manifestations, with polyvisceral failure often life threatening, unlike those with HCV mixed cryoglobulinemia [1]. When patients with chronic HCV infection develop severe extrahepatic manifestations they were reported to have cutaneous leukocytoclastic vasculitis [9, 10, 12]. Central nervous system disease has been reported only rarely in patients with HCV infection and mixed cryoglobulinemia [1, 3, 7, 10]. Stroke episodes and encephalopathic syndromes are the most common clinical presentations and have been attributed to ischemia [4, 10]. Radiological findings in those cases consist of small or large hyperintense lesions in the white matter on MRI [3, 7, 10] and cerebral angiography has occasionally suggested vasculitis demonstrating focal narrowing and irregularities [5, 7]. Fatal central nervous system involvement in the form of hemorrhagic stroke has been scarcely described in patients with chronic HCV infection and there have been

M. E. Erro Aguirre (✉) · T. Ayuso Blanco ·
M. Herrera Isasi
Servicio de Neurología
Hospital de Navarra
C/Irunlarrea 3
31008 Pamplona (Navarra), Spain
Tel.: +34-948/422292
Fax: +34-948/422303
E-Mail: elena.erro.aguirre@cfnavarra.es

T. Tuñón Álvarez
Anatomía Patológica
Hospital de Navarra
Pamplona (Navarra), Spain

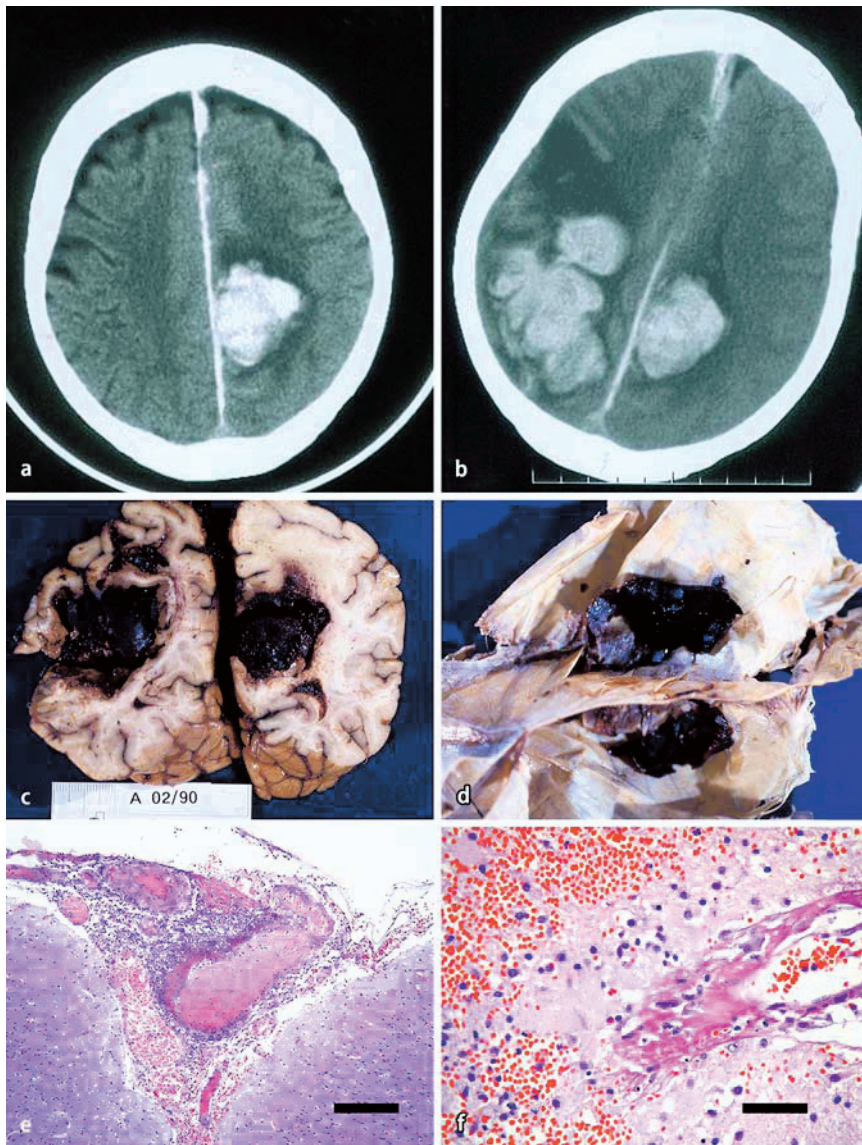


Fig. 1 **A** Brain CT showing the first left frontal hemorrhage. **B** Brain CT showing the appearance of a second right frontal lobar hemorrhage with subdural extension four days after **A**. **C, D** The gross pathology of the brain shows the bilateral parenchymal hemorrhage and the subdural extension of the bleeding. **E** Microphotograph showing a corticomeningeal medium size arteriole with a transmural inflammatory process, the vessel wall is interrupted and destroyed by a mixed polymorphonuclear and mononuclear cell infiltrate (calibration bar: 200 μ m). **F** Higher magnification microphotograph of another small arteriole with segmental fibrinoid necrosis (calibration bar: 50 μ m)

few instances of histopathological documentation of vasculitis involving brain vessels. Changes of a granulomatous angiitis were found on a leptomenigeal biopsy in one case [5]. Spontaneous intracerebral hemorrhage in chronic HCV infection has been attributed to a sub-clinical clotting disorder secondary to hepatopathy, to vessel wall

friability resulting from hypocholesterolemia [8] or to the adverse effects of HCV treatment [6].

We conclude that chronic HCV infection associated PAN-type vasculitis may also have an effect on the CNS leading to brain hemorrhages as was documented in this case.

References

1. Cacoub P, Maisonobe T, Thibault V, Gatel A, Servan J, Musset L, Piette J-C (2001) Systemic vasculitis in patients with hepatitis C. *J Rheumatol* 28: 109–118
2. Cacoub P, Renou C, Rosenthal E, Cohen P, Loury I, Loustaud-Ratti V, Yamamoto A-M, Camproux A-C, Hausfater P, Musset L, Veyssier P, Raguin G, Piette J-C (2000) Extrahepatic manifestations associated with hepatitis C virus infection. A prospective multicenter study of 321 patients. *Medicine* 79:47–56
3. Cacoub P, Saadoun D, Limal N, Léger JM, Maisonobe T (2005) Hepatitis C virus infection and mixed cryoglobulinemia vasculitis: a review of neurological complications. *AIDS* 19 (S3):S128–S134
4. Cacoub P, Sbaï A, Hausfater P, Papo T, Gatel A, Piette J-C (1998) Atteinte neurologique centrale et infection par le virus de l'hépatite C. *Gastroentérol Clin Biol* 22:631–633
5. Dawson TM, Starkebaum G (1999) Isolated central nervous system vasculitis associated with hepatitis C infection. *J Rheumatol* 26:2273–2276
6. Ferencz S, Batey R (2003) Intracerebral haemorrhage and hepatitis C treatment. *Journal of Viral Hepatitis* 10: 401–403
7. Heckmann JG, Kayser C, Heuss D, Manger B, Blum HE, Neundörfer B (1999) Neurological manifestations of chronic hepatitis C. *J Neurol* 246: 486–491
8. Karibe H, Niizuma H, Ohyama H, Shirane R, Yoshimoto T (2001) Hepatitis C virus (HCV) infection as a risk factor for spontaneous intracerebral hemorrhage: hospital based case control study. *J Clin Neurosci* 8:423–425
9. Méndez P, Saeian K, Rajender R, Younossi ZB, Kerdel F, Badalamenti S, Jeffers LJ, Schiff ER (2001) Hepatitis C, cryoglobulinemia and cutaneous vasculitis associated with unusual and serious manifestations. *Am J Gastroenterol* 96:2489–2493
10. Origi I, Vanoli M, Carbone A, Grasso M, Scorza R (1998) Central nervous system involvement in patients with HCV-related cryoglobulinemia. *Am J Med Sci* 315:208–210
11. Petty GW, Duffy J, Huston J (1996) Cerebral ischemia in patients with hepatitis C virus infection and mixed cryoglobulinemia. *Mayo Clin Proc* 71:671–678
12. Tembl JJ, Ferrer JM, Sevilla MT, Lago A, Mayordomo F, Vilchez JJ (1999) Neurologic complications associated with hepatitis C virus infection. *Neurology* 53:861–864