

Metastatic choriocarcinoma with multiple neoplastic intracranial microaneurysms

Case report

IN BOK CHANG, M.D.,¹ BYUNG MOON CHO, M.D., PH.D.,¹ SE HYUCK PARK, M.D., PH.D.,¹
DAE YOUNG YOON, M.D., PH.D.,² AND SAE MOON OH, M.D., PH.D.¹

Departments of ¹Neurosurgery and ²Radiology, Hallym University, College of Medicine, Seoul, Korea

✓The authors report on a case of a metastatic choriocarcinoma that mimicked systemic necrotizing vasculitis on a cerebral angiogram. A 35-year-old woman presented with right hemiplegia and a drowsy mental state. A computed tomography (CT) scan revealed an intracerebral hemorrhage in the left frontal region. A cerebral angiogram showed multiple microaneurysms arising from the bilateral anterior cerebral arteries and middle cerebral arteries, and the renal angiogram showed multiple microaneurysms arising from the left distal renal artery. A chest CT scan revealed multiple metastatic lesions in the left lower lung field. The hematoma and microaneurysms were surgically removed. Choriocarcinoma was diagnosed after histological examination. Despite receiving postoperative chemotherapy, the patient died 1 month after the operation. (DOI: 10.3171/JNS/2008/108/5/1014)

KEY WORDS • choriocarcinoma • intracerebral hematoma • neoplastic aneurysm • polyarteritis nodosa

CHORIOCARCINOMA is the malignant form of gestational trophoblastic disease, which includes a clinical spectrum consisting of the benign hydatidiform mole, the invasive mole, and the highly malignant choriocarcinoma.¹⁵ It usually disseminates hematogenously to the lungs, vagina, brain, kidney, and ovaries.¹³ Cerebral metastases occur in 10–20% of patients with choriocarcinoma.¹ Choriocarcinoma with cerebral metastases has been associated with intracerebral hematoma, embolic vascular occlusion, subdural hematomas, arterial aneurysms, and a spinal epidural hematoma.^{1,15} Even though there have been some reports of metastatic choriocarcinomas with single cerebral neoplastic aneurysms, reports of multiple cerebral neoplastic aneurysms with metastatic choriocarcinoma confirmed by preoperative angiograms are rare.^{5,10} Many aneurysms might have remained undiscovered on angiograms or necropsies due to compression from a hematoma. Although rare, similar findings have been reported in patients with polyarteritis nodosa.⁹ We report a case of metastatic choriocarcinoma associated with multiple intracranial microaneurysms and ICH.

Case Report

Presentation and Examination. This 35-year-old woman

was admitted to the Department of Neurosurgery complaining of severe headache, nausea, vomiting, and progressive somnolence. She had delivered a normal full-term infant 7 years ago and had a history of artificial (intentional) abortion at a local clinic 2 years ago. Her mental status was drowsy, and her pupils were promptly reactive to light. She had right hemiplegia and hyperesthesia on admission. Because she was of childbearing age, her urine was checked for β -HCG, which was positive. A CT scan of the brain revealed a 3 \times 5-cm hemorrhagic mass in the left upper-frontal region with vasogenic edema. An MR image of the brain showed a hematoma with multiple enhancing nodular lesions in the left frontal and right parietal regions (Fig. 1). The cerebral angiograms revealed multiple microaneurysms arising from the bilateral ACAs and MCAs (Fig. 2). A renal angiogram was performed to rule out simultaneous systemic vasculitis, and it also showed multiple microaneurysms arising from the left distal renal artery. The patient's serum β -HCG level on admission was at an elevated level of 9354.5 mIU/ml, leading to suspicion of an ectopic pregnancy, but her pelvic CT scan, transvaginal ultrasonography, and endometrial biopsy specimen were negative for ectopic pregnancy or other diseases. Furthermore, a pelvic MR image revealed no definitive primary lesion in the uterus. The patient was in a high-risk group (> 8) according to the World Health Organization classification of gestational trophoblastic disease.¹²

Operation. Emergency stereotactic aspiration of the hematoma was performed, resulting in a reversal of her neurological deterioration. Due to rebleeding, however, a cra-

Abbreviations used in this paper: ACA = anterior cerebral artery; β -HCG = beta-human chorionic gonadotropin; CT = computed tomography; EMACO = etoposide, methotrexate, actinomycin D, cyclophosphamide, and vincristine; ICH = intracerebral hemorrhage; MCA = middle cerebral artery; MR = magnetic resonance.

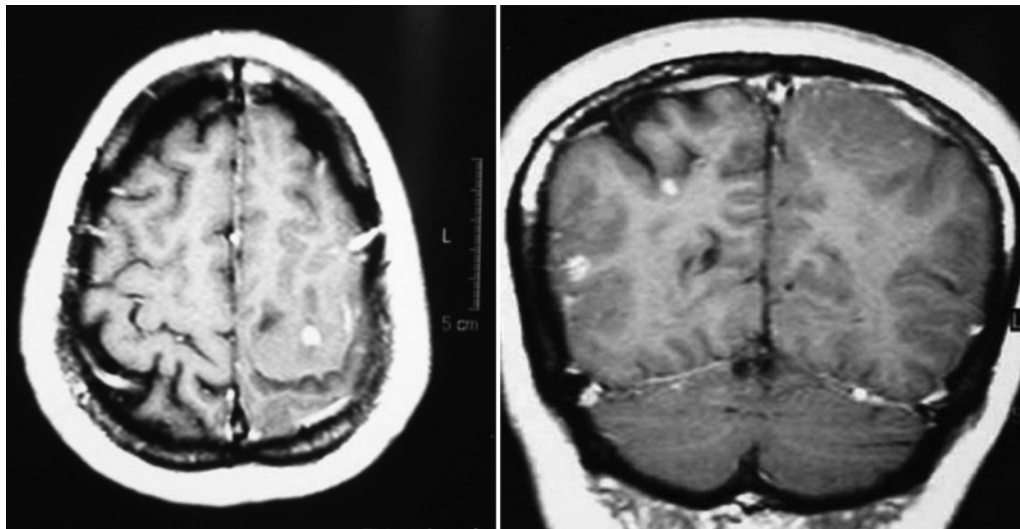


FIG. 1. Preoperative CT scan (left) showing ICH in the left parietal region and coronal Gd-enhanced T1-weighted MR image (right) demonstrating enhancing nodular lesions.

niotomy and removal of a hematoma (along with a biopsy procedure) was performed. In the operative field, neoplastic microaneurysms were exposed on the cortex of the left frontal region, which was coagulated and resected, and the intracerebral hematoma was evacuated (Fig. 3). The cerebrospinal fluid β -HCG level obtained after hematoma evacuation remained elevated at 134.1 mIU/ml.

Histological Examination. Histological examination of the hematoma was compatible with a diagnosis of choriocarcinoma. The specimens showed several atypical pleomorphic trophoblastic cells on a necrotic background and some scattered trophoblasts in the hematoma and invading the vessel wall. Immunohistochemical study revealed positive staining for β -HCG in the tumor cells (Fig. 4), but the endometrial biopsy specimen showed no evidence of chorionic villi, trophoblasts, or decidual reaction.

Postoperative Course. After the surgery, a chest CT scan revealed multiple metastatic lesions in the left lower lung field. The patient underwent combination chemotherapy with EMACO. Despite aggressive therapy, recurrent bleeding occurred and the patient died 1 month after her initial presentation.

Discussion

The incidence of choriocarcinoma after a normal pregnancy is 1 in 50,000 live births, whereas the development of this tumor after a nonmolar abortion is unknown.¹⁴ Tidy and colleagues¹⁴ reported that choriocarcinoma after nonmolar pregnancies represents 17% of the total gestational trophoblastic tumors requiring treatment.¹² In our case, the patient had delivered a normal full-term infant 7 years pre-

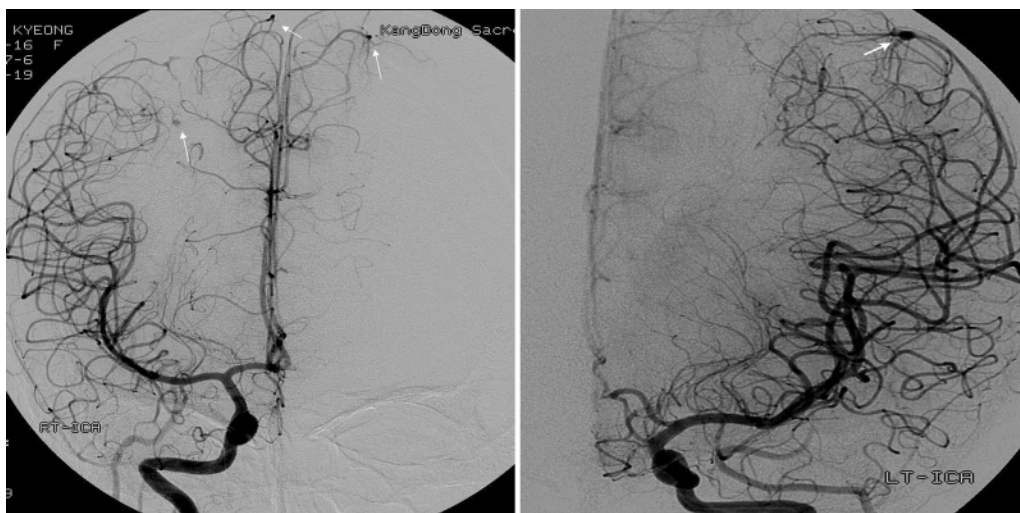


FIG. 2. Cerebral angiograms showing multiple microaneurysms. A right internal carotid artery angiogram (left) showing microaneurysms in the MCA and both ACAs (arrows) and a left internal carotid artery angiogram (right) showing a microaneurysm in the left MCA (arrow).

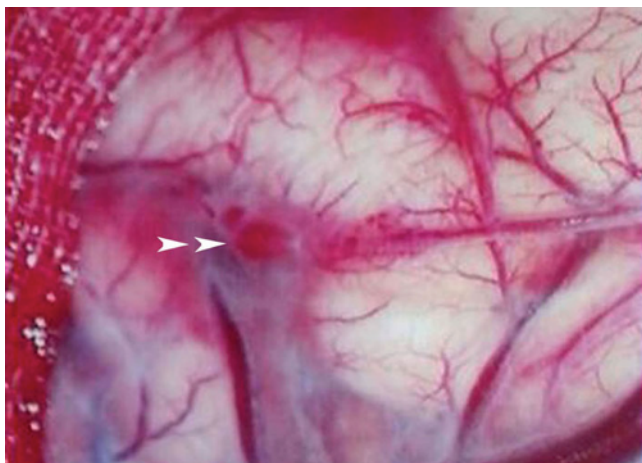


FIG. 3. Intraoperative photograph showing a neoplastic microaneurysm on the cortex of the brain (arrowheads).

viously and had had an artificial abortion at a local clinic 2 years ago; however, the type of abortion (molar or nonmolar) was unclear.

Choriocarcinoma has a tendency to rapidly and hematogenously spread to the lungs, vagina, brain, liver, kidney, and ovaries.¹³ Cerebral metastases occur in 10–20% of patients with choriocarcinoma. In these patients, however, cerebral metastasis is the major cause of death.¹ Choriocarcinomas with cerebral metastases have been associated with intracerebral hematoma, embolic vascular occlusion, subdural hematoma, arterial aneurysm, and a spinal epidural hematoma.^{1,13} The trapped neoplastic cells, with a form of emboli in the cerebral circulation, have a predilection for invading the vessel wall, which can result in a hemorrhage within the tumor, or partial disruption of the vessel wall that can lead to aneurysm formation and subsequent hemorrhage.^{3,15} There are 2 mechanisms for neoplastic aneurysm formation. First, after tumor embolization in the distal cerebral vessels, focal destruction of the intima, internal elastic lamina, and media layers may cause a true neoplastic aneu-

rysm. Second, lodging of the tumor embolus in the vasa vasorum and involvement of the internal elastic lamina may lead to aneurysm formation in the final stage.⁵ Neoplastic aneurysm and pseudoaneurysm formation may be the most common cause of ICH in choriocarcinoma.⁶

Fewer than 20 cases of neoplastic cerebral aneurysm with metastatic choriocarcinoma have been reported, and only 3 cases of multiple neoplastic cerebral aneurysms have been reported. Most reported aneurysms were solitary and located on one of the terminal branches of the MCA. In our case, the multiple microaneurysms were located in the bilateral ACAs and MCAs.

This case was uniquely rare for several reasons. First, the patient had no history of molar pregnancy (gestational trophoblastic disease). Second, no primary focus was found. According to the scientific literature, metastatic choriocarcinomas were reported without evidence of choriocarcinomas in the pelvic cavity, suggesting that pelvic choriocarcinomas can regress after metastasis. Third, the patient had metastases to the brain, lung, and kidney with microaneurysms visible on angiograms. These angiographic findings are rare, but similar angiographic findings have been found in patients with polyarteritis nodosa, a form of systemic necrotizing vasculitis.⁸

Treatment of metastatic choriocarcinoma using chemotherapy and/or radiotherapy produces long-term survival rates of as high as 80%.¹ Patients with a low risk have been treated with single-agent chemotherapy using methotrexate or actinomycin D, but EMACO therapy has been considered the most effective treatment regimen for patients in the high-risk group.⁷ Our patient belonged to the high-risk group because she had multiple metastases as well as a high serum β -HCG level. She died 1 month after the initial presentation in spite of the hematoma evacuation and intensive chemotherapy.

The effectiveness of surgical treatment for cerebral metastases has been reported. Surgery is indicated in patients with significant mass effect due to intracranial hemorrhage or tumor mass, cerebral aneurysms that have been angiographically proven to be the source of bleeding, or chemotherapy-resistant intracranial metastatic deposits.¹¹

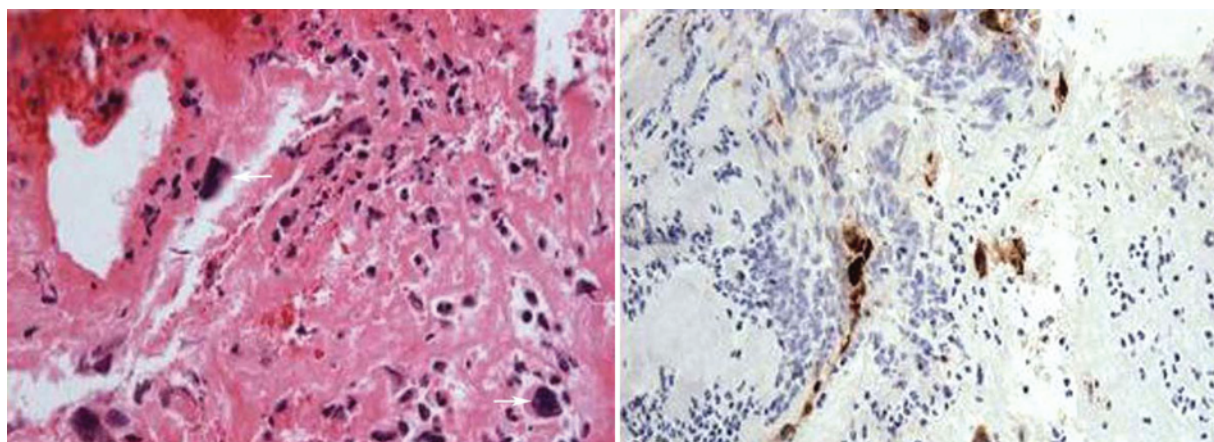


FIG. 4. Photomicrographs of the hematoma specimen showing some scattered trophoblasts in the hemorrhage and invasion of the vessel wall (left, arrows) and positive immunoreactivity for β -HCG (right). H & E, original magnification $\times 400$ (left) and $\times 200$ (right).

The usefulness of radiation therapy for cerebral metastases has also been reported.^{4,16} In the study of Yordan and associates,¹⁶ in the patients who received combined chemotherapy and radiation therapy, the survival rate was higher than that of the patients who received only chemotherapy. Ghaemmaghami et al.⁴ reported that they had no patient complications after treatment with the combination of chemotherapy and whole-brain radiotherapy. Combination chemotherapy with whole-brain radiotherapy might be effective for choriocarcinoma with multiple cerebral metastases.

Despite such improvements in treatment, the prognosis in patients with cerebral metastasis is still poor.² Because these patients generally have a poor outcome within a few weeks after initiating presentation, the earlier recognition of choriocarcinoma might enable the treating physician to reduce the mortality rate and make an earlier diagnosis.^{6,14}

Conclusions

The authors suggest that metastatic choriocarcinoma should be considered as a cause of bleeding when intracranial hemorrhagic lesions in unusual locations occur in women of childbearing age. Use of hematoma biopsy specimens and β -HCG levels are mandatory for making an accurate diagnosis.

References

1. Athanassiou A, Begent RH, Newlands ES, Parker D, Rustin GJ, Bagshawe KD: Central nervous system metastases of choriocarcinoma. 23 years' experience at Charing Cross Hospital. **Cancer** **52**:1728–1735, 1983
2. Buckley JD: The epidemiology of molar pregnancy and choriocarcinoma. **Clin Obstet Gynecol** **27**:153–159, 1984
3. Fujiwara T, Mino S, Nagao S, Ohmoto T: Metastatic choriocarcinoma with neoplastic aneurysms cured by aneurysm resection and chemotherapy. Case report. **J Neurosurg** **76**:148–151, 1992
4. Ghaemmaghami F, Behtash N, Memarpour N, Soleimani K, Hanjani P, Hashemi FA: Evaluation and management of brain metastatic patients with high-risk gestational trophoblastic tumors. **Int J Gynecol Cancer** **14**:966–971, 2004
5. Giannakopoulos G, Nair S, Snider C, Amenta PS: Implications for the pathogenesis of aneurysm formation: metastatic choriocarcinoma with spontaneous splenic rupture. Case report and a review. **Surg Neurol** **38**:236–240, 1992
6. Kalafut M, Vinuela F, Saver JL, Martin N, Vespa P, Verity MA: Multiple cerebral pseudoaneurysms and hemorrhages: the expanding spectrum of metastatic cerebral choriocarcinoma. **J Neuroimaging** **8**:44–47, 1998
7. McDonald TW, Ruffolo EH: Modern management of gestational trophoblastic disease. **Obstet Gynecol Surv** **38**:67–83, 1983
8. Newlands ES, Bagshawe KD, Begent RH, Rustin GJ, Holden L, Dent J: Developments in chemotherapy for medium- and high-risk patients with gestational trophoblastic tumours (1979–1984). **Br J Obstet Gynaecol** **93**:63–69, 1986
9. Oran I, Memis A, Parildar M, Yuntun N: Multiple intracranial aneurysms in polyarteritis nodosa: MRI and angiography. **Neuroradiology** **41**:436–439, 1999
10. Seigle JM, Caputy AJ, Manz HJ, Wheeler C, Fox JL: Multiple oncotic intracranial aneurysms and cardiac metastasis from choriocarcinoma: case report and review of the literature. **Neurosurgery** **20**:39–42, 1987
11. Semple PL, Denny L, Coughlan M, Soeters R, Van Wijk L: The role of neurosurgery in the treatment of cerebral metastases from choriocarcinoma: a report of two cases. **Int J Gynecol Cancer** **14**:157–161, 2004
12. Smith DB, O'Reilly SM, Newlands ES: Current approaches to diagnosis and treatment of gestational trophoblastic disease. **Curr Opin Obstet Gynecol** **5**:84–91, 1993
13. Tai KS, Chan FL, Ngan HY: Renal metastasis from choriocarcinoma: MRI appearance. **Abdom Imaging** **23**:536–538, 1998
14. Tidy JA, Rustin GJ, Newlands ES, Foskett M, Fuller S, Short D, et al: Presentation and management of choriocarcinoma after non-molar pregnancy. **Br J Obstet Gynaecol** **102**:715–719, 1995
15. Weir B, MacDonald N, Mielke B: Intracranial vascular complications of choriocarcinoma. **Neurosurgery** **2**:138–142, 1978
16. Yordan EL Jr, Schlaerth J, Gaddis O, Morrow CP: Radiation therapy in the management of gestational choriocarcinoma metastatic to the central nervous system. **Obstet Gynecol** **69**:627–630, 1987

Manuscript submitted June 7, 2007.

Accepted August 16, 2007.

Address correspondence to: Byung Moon Cho, M.D., Ph.D., Department of Neurosurgery, Kangdong Sacred Heart Hospital, Hallym University, College of Medicine, 445 Gil-dong, Gangdong-gu, Seoul 134-701, Korea. email: nschbm@hanmail.net.