

MULTIPLE CATECHOLAMINE-SECRETING PARAGANGLIOMAS: DIAGNOSIS AFTER HEMORRHAGIC STROKE IN A YOUNG WOMAN

Luigi Petramala, MD,¹ Giuseppe Cavallaro, MD,² Andrea Polistena, MD,²
Dario Cotesta, MD,¹ Antonella Verrienti, MD,¹ Antonio Ciardi, MD,²
Professor Piernatale Lucia, MD,¹ Professor Sebastiano Filetti, MD,¹
Professor Emilio D'Erasmus, MD,¹ Professor Giorgio De Toma, MD,²
and Professor Claudio Letizia, MD¹

ABSTRACT

Objective: To describe a case of multiple catecholamine-secreting paragangliomas, with a hemorrhagic stroke as the main clinical manifestation.

Methods: We present a case report with clinical, laboratory, histologic, and genetic details.

Results: A 23-year-old woman with a history of hypertension treated with orally administered medications presented to our emergency department because of sudden onset of hemiplegia of the left side of the body. A computed tomographic scan of the brain showed a right frontoparietal hematoma, and her blood pressure was 185/115 mm Hg. She was admitted to the Department of Neurosurgery, and an external drain was inserted to evacuate the hematoma. She was then referred to the Department of Clinical Sciences, where a search for possible secondary causes of hypertension was undertaken. Substantially elevated urinary levels of vanillylmandelic acid and metanephrines were found, and a pheochromocytoma was suspected. Abdominal computed tomographic scans revealed a large retroperitoneal mass (3.6 by 4 cm) and similar smaller lesions in the right adrenal gland, between the aorta and the vena cava, and in the left para-aortic area. Iodine I 123 metaiodobenzylguanidine scintigraphy showed high uptake in those same areas, consistent with the diagnosis of multiple catecholamine-secreting paragangliomas. After adequate control of the patient's hypertension was achieved with an α_1 -adrenergic receptor blocker, a Ca²⁺ antagonist, and a β -adrenergic blocking agent, the tumors were excised in the Department of Surgery. The histopathologic findings confirmed the diagnosis of multiple paragangliomas. The genetic analysis demonstrated an exon 4 mutation in codon 109 (CAA>TAA, Gln>Stop) of the *SDHD* gene.

Conclusion: Although cerebral hemorrhage is an unusual complication of pheochromocytomas or paragangliomas, early recognition of the characteristic symptoms of headache, palpitations, and diaphoresis in a patient with hypertension and prompt appropriate intervention can minimize the morbidity associated with such tumors and prevent a potentially fatal outcome. (**Endocr Pract.** 2008; 14:340-346)

Abbreviations:

CT = computed tomographic; SDH = succinate dehydrogenase; VMA = vanillylmandelic acid

INTRODUCTION

Pheochromocytomas are rare tumors of chromaffin cells that produce and secrete catecholamines. The term "pheochromocytoma" is also currently applied to the catecholamine-secreting paragangliomas that are intra-abdominal (adrenal and extra-adrenal) or thoracic tumors (1). In contrast, paragangliomas of the neural crest-derived cells of the parasympathetic-associated ganglia are generally nonsecreting (2).

The increased and disorderly production of catecholamines is the main cause of the clinical picture associated with pheochromocytomas or paragangliomas, including hypertension, headache, sweating, palpitations, and visual blurring (3). The laboratory diagnosis of a pheochromocytoma or a paraganglioma is based on the serum and urinary levels of catecholamines or their metabolites. The combination of urinary metanephrines and vanillylmandelic acid (VMA) has been reported to have a diagnostic sensitivity of 98% in detecting a pheochromocytoma or a paraganglioma (4,5).

Both pheochromocytomas and paragangliomas can be managed with minimal associated morbidity if they are recognized early; however, if they are untreated, they can be fatal. To date, relatively few cases of pheochromocytoma with complications of cerebral hemorrhage have been reported (6-10). In this report, we describe a patient

Submitted for publication May 18, 2007

Accepted for publication September 24, 2007

From the Departments of ¹Clinical Sciences and ²Surgery "Pietro Valdoni," University of Rome "Sapienza," Rome, Italy.

Address correspondence and reprint requests to Professor Claudio Letizia, Department of Clinical Sciences, University of Rome "Sapienza," Policlinico "Umberto I," Viale del Policlinico, 155, 00165 Rome, Italy.

© 2008 AACE.

with multiple catecholamine-secreting paragangliomas who presented with a spontaneous intracerebral hematoma.

CASE REPORT

A 23-year-old woman with a history of hypertension, which had been treated during the past 6 months with anti-hypertensive drugs (50 mg/d of atenolol and 100 mg/d of losartan), had sudden development of hemiplegia of the left side of the body. She presented to the emergency department with a blood pressure of 185/115 mm Hg, and a brain computed tomographic (CT) scan showed a right frontoparietal hematoma (Fig. 1). The patient was then admitted to the Department of Neurosurgery. She had experienced paroxysmal attacks of hypertension (maximal blood pressure, 220/140 mm Hg) as well as palpitations, headache, and excessive sweating during physical activity for 6 months preceding her admission. The patient underwent craniotomy and evacuation of the right frontoparietal hematoma. Blood pressure control was also achieved by oral administration of multiple antihypertensive agents.

The patient's clinical condition was improved with intensive rehabilitation therapy, and she was admitted to the Department of Clinical Sciences. Because she was a young patient with a blood pressure that was difficult to control, a search for possible secondary causes of hypertension was performed. No sign of cardiomegaly was observed on chest radiography, electrocardiography, or echocardiography. An ultrasound study of the kidneys showed that they were normal in size and had normal echogenicity; no renal artery stenosis was evident. Urinary investigations, however, revealed substantially increased catecholamine secretion. The 24-hour VMA value (determined by a liquid chromatographic-spectrophotometric method with a sensitivity of 1.5 mg/L [FAR, Verona, Italy]) was 23 mg/d (reference range, <10), and urinary metanephrines (determined by a specific radioimmunoassay [BioSource Europe, Nivelles, Belgium], with intra-

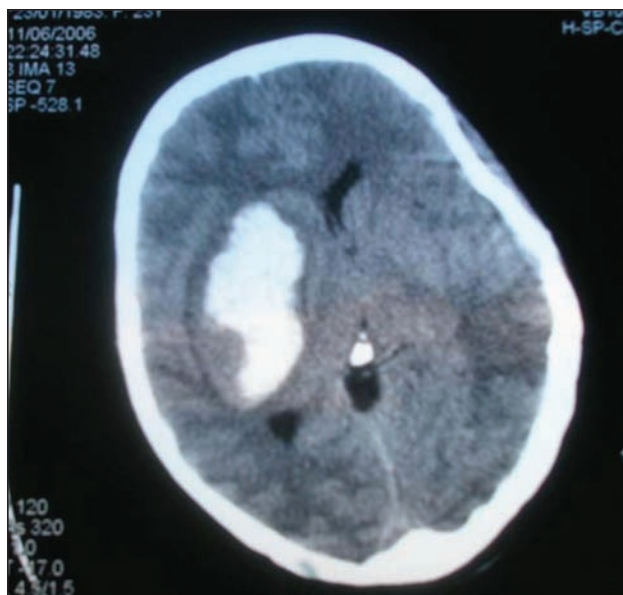


Fig. 1. Computed tomographic scan of the brain of the study patient, showing a right frontoparietal hematoma.

assay and interassay coefficients of variation of 4.2% and 13%, respectively) were 485 μ g/d (reference range, 20 to 345). At the time of collection of the urinary specimen, the patient presented with paroxysmal attacks of severe hypertension. On the basis of clinical features and laboratory findings, we suspected a catecholamine-secreting tumor.

CT scan of the abdomen revealed a large contrast-enhanced lesion (3.6 by 4 cm) in the retroperitoneal area, with compression of the aorta and vena cava. Similar smaller lesions were detected in the right adrenal gland (1.8 cm), between the aorta and the vena cava (2 cm) near the origin of the right renal artery, and in the left para-aortic area (1.2 cm) close to the origin of the superior mesenteric artery (Fig. 2). An iodine I 123 metaiodobenzylguanidine scintiscan showed high uptake in the same areas as the lesions noted in the CT scan (Fig. 3).

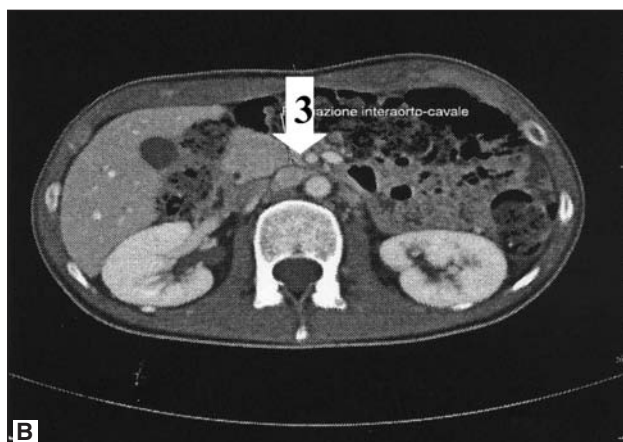
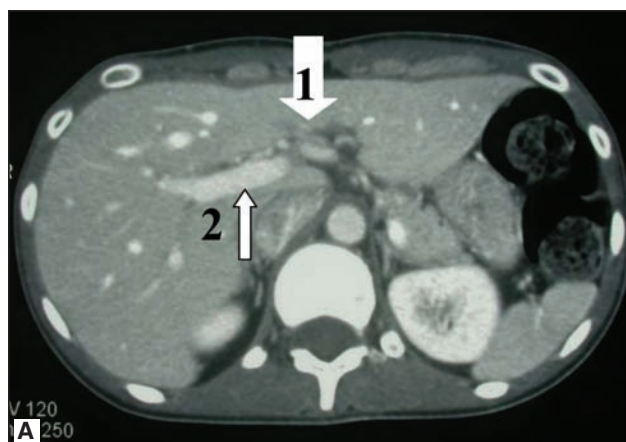


Fig. 2. Abdominal computed tomographic scans. **A**, Coronal view, showing large contrast-enhanced lesion (3.6 by 4 cm) in the retroperitoneal area, with aortic and vena caval compression (1) and the vena cava (2). **B**, Lesion between the aorta and the vena cava (3).

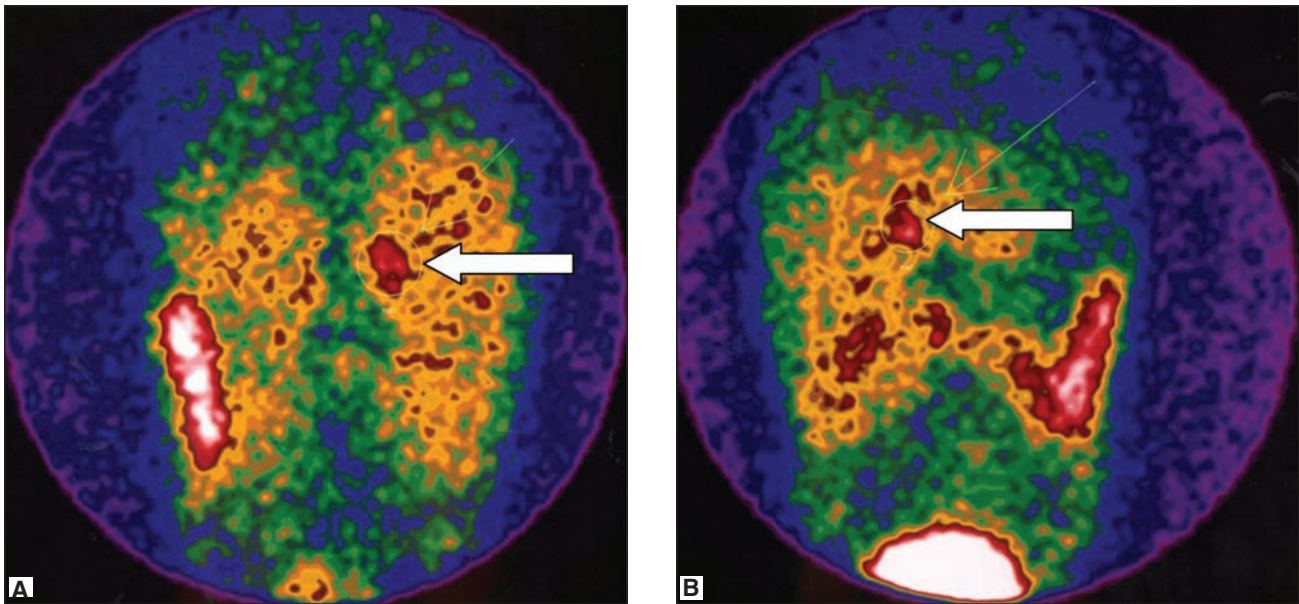


Fig. 3. Iodine I 123 metaiodobenzylguanidine scintiscans. *A*, Increased uptake of tracer in right adrenal gland and right paramedian region (posterior view). *B*, Increased uptake of tracer in the interaortocaval lesion.

On the basis of the aforementioned findings, the lesions were diagnosed as multifocal catecholamine-secreting tumors (pheochromocytomas or paragangliomas). The patient's hypertension was adequately controlled with an α_1 -adrenergic receptor blocker (doxazosin, 4 mg/d), a Ca^{2+} antagonist (amlodipine, 10 mg/d), and a β -adrenergic blocking agent (propranolol, 40 mg/d), and excision of the tumors was scheduled. With the patient under general anesthesia, the operation was performed through a median laparotomy, and wide exploration of the retroperitoneum allowed the identification of a mass close to the right adrenal gland, which was removed en bloc after complete liver mobilization. After exploration of the

lymphatic and fat tissue within the region of the left renal vein, aorta, and left gonadal veins, an interaortocaval lesion, a para-aortic lesion, and a preaortic lesion were resected (Fig. 4).

The macroscopic evaluation of the surgical specimens revealed a normal adrenal gland and 3 well-encapsulated lesions. The dimensions were 4 by 3 by 2 cm for the interaortocaval lesion, 2.5 by 1.5 by 1 cm for the para-aortic lesion, and 4 by 2 by 1 cm for the preaortic lesion.

Histopathologic Examination

Microscopic examination of the adrenal gland showed no histologic or cellular alterations. Examination of the 3

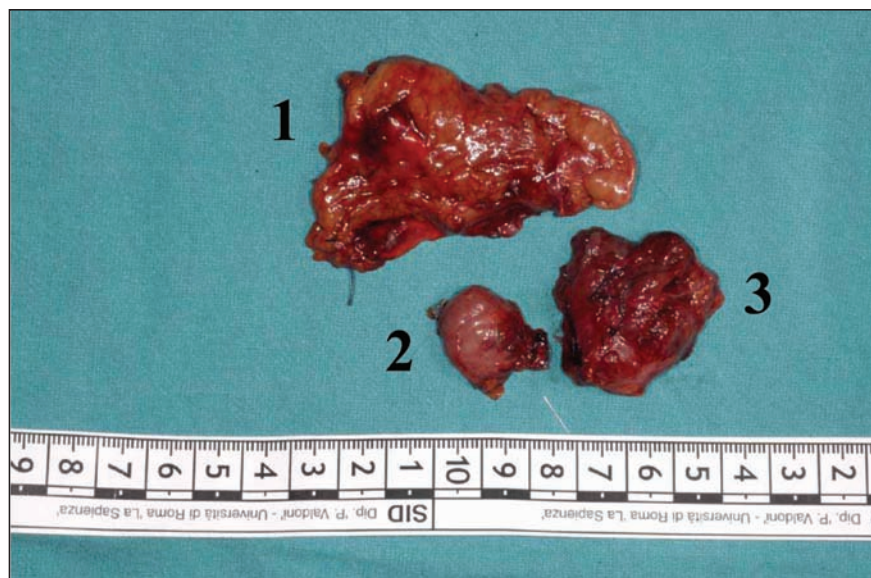


Fig. 4. Surgical specimens: interaortocaval lesion (1), para-aortic lesion (2), and preaortic lesion (3).

lesions revealed a well-defined tumor cell nest (*Zellballen*) surrounded by a delicate fibrovascular stroma. The lesions were composed of large polyclonal cells arranged in an alveolar growth pattern. The cellular population varied considerably in size and shape; the finely granular eosinophilic cytoplasm had scattered hyaline globuli and round to ovoid nuclei with prominent nucleoli. Immunohistochemical staining demonstrated strong immunoreactivity for chromogranin and synaptophysin. These histopathologic findings confirmed the diagnosis of multiple paragangliomas.

Follow-up

No major complications were observed during the postoperative course, and the patient was discharged from the hospital on the 20th postoperative day. The patient was referred to a rehabilitation unit to aid in recovery from the hemiplegia. Three weeks after the surgical procedure, measurements of urinary VMA (6 mg/d) and metanephrines (170 μ g/d) were in the reference ranges. At 3-month follow-up, she was doing well, although she still required low-dosage medical treatment to control her blood pressure.

Whole-body positron emission tomography with use of fluorine F 18-labeled dihydroxyphenylalanine was performed 4 months after the surgical procedure. No tracer uptake was detected (Fig. 5).

Genetic Evaluation

Peripheral blood samples (5 to 10 mL) from the proband were collected in 0.2% DNA-containing tubes after written informed consent was obtained. Genomic DNA was prepared from peripheral blood leukocytes with

use of a commercial kit (Nucleon Pramacia Biotech, Milan, Italy). Isolated DNA was solubilized in TE buffer (1 mM tromethamine hydrochloride; 0.1 mL of ethylenediaminetetraacetic acid; pH 8) and stored at -20°C . Genomic DNA was amplified, and the polymerase chain reaction products were sequenced in both directions by using the ABI PRISM 310 Genetic Analyzer (Applied Biosystems, Foster City, California) in accordance with PRISM dye terminator and dye primer cycle sequencing chemistries. Screening for mutations in the 8 exons and flanking intron regions of *SDHB* and the 4 exons and flanking intron regions of *SDHD* revealed a heterozygotic transition at codon 109 (CAA>TAA, Gln>Stop) of the *SDHD* gene.

DISCUSSION

Pheochromocytomas are rare tumors, occurring in about 1 to 2 persons per 100,000 adults (1). These tumors commonly arise from the adrenal medulla, but approximately 10% of pheochromocytomas appear extra-adrenally (2). Pheochromocytomas originate from pheochromocytes, which constitute the chromaffin system in the adrenal medulla, the paraganglia near the aorta, and the ganglia of the sympathetic nervous system.

In our patient, multiple extra-adrenal pheochromocytomas within the organs of Zuckerkandl caused the paroxysms of hypertension and associated symptoms. The organs of Zuckerkandl are paired bodies of extra-adrenal chromaffin tissue and are the most common site of extra-adrenal pheochromocytomas (11). They are usually united across the front of the aorta by a horizontal mass that lies immediately above the origin of the inferior mesentery

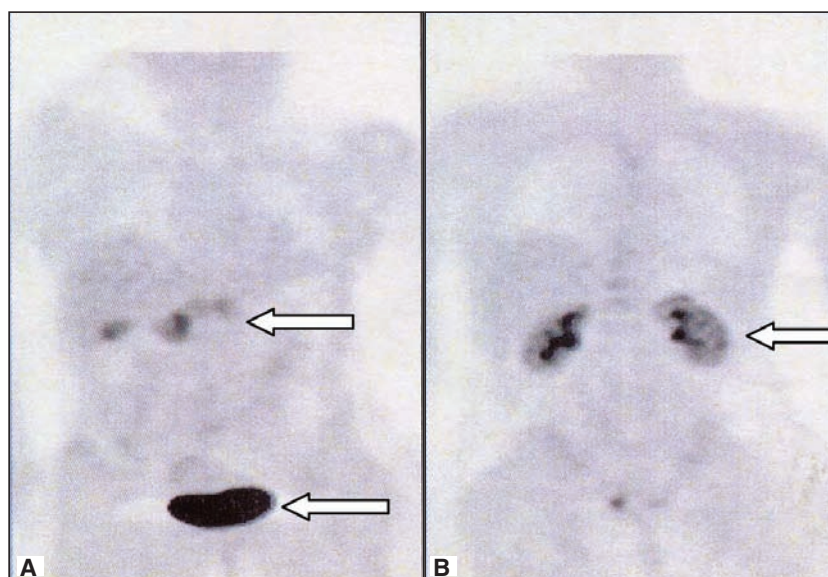


Fig. 5. Whole-body positron emission tomography with use of fluorine F 18-labeled dihydroxyphenylalanine, performed 4 months postoperatively, showed no tracer uptake. *A*, Anterior view. *B*, Posterior view. *White arrows* indicate physiologic uptake of tracer in liver, gallbladder, kidneys, and urinary bladder.

artery so as to form, collectively, an inverted horseshoe or H-shaped arrangement. The constituent cells undergo dispersal and some atrophy, and investigators have indicated that, by the age of 14 years, these cells are completely disintegrated. The chromaffin cells of the para-aortic bodies are thought to subserve the adrenal medulla as sources of catecholamines, particularly in prenatal and early postnatal life when the adrenal medulla and the autonomic nervous system are not fully differentiated (12).

Symptoms and signs attributable to a pheochromocytoma or paraganglioma result from an uncontrolled release of catecholamines (norepinephrine and epinephrine). Most patients have hypertension, which can be paroxysmal or sustained (13).

Catecholamine-secreting tumors such as pheochromocytomas are often accompanied by complications in other organs. Cerebral hemorrhage is an unusual complication (7,14,15), and cerebral hemorrhage caused by pheochromocytoma is rare (7-10) (Table 1). Cerebrovascular disease is a serious complication in patients with pheochromocytoma, but its incidence is low; some authors have reported that cerebral infarction was found in 3% and cerebral hemorrhage occurred in 2% of 100 studied cases of pheochromocytoma (6). In an autopsy study, Sutton et al (16) found that 13% of 54 young patients with clinically unsuspected pheochromocytoma died of cerebrovascular hemorrhage. Thus, especially in young patients with

hypertension, the potential presence of a pheochromocytoma should be investigated.

Recent research has indicated that approximately 20% to 25% of pheochromocytomas are hereditary and caused by mutations in 1 of 4 genes that are responsible for the heritable tumor syndromes, including multiple endocrine neoplasia type 2 (attributable to mutations of the *RET* gene), von Hippel-Lindau disease (due to mutations of the *VHL* gene), neurofibromatosis type 1 (caused by mutations of the *NFI* gene), and the recently defined paraganglioma syndromes type 1 and type 4 (caused by mutations of the *SDHD* and *SDHB* genes, respectively) (17-19). These genes encode 2 subunits of complex II of the respiratory chain, also known as succinate ubiquinone oxidoreductase. Succinate dehydrogenase (SDH) is a mitochondrial enzyme linking the respiratory chain and Krebs cycle, which oxidizes succinate to fumarate (19,20). The *SDH* genes are tumor suppressor genes, and the heterozygous germline *SDH* mutation is generally associated with somatic loss of the wild-type allele in the tumor tissue. This *SDH* gene inactivation induces the selective and complete loss of SDH activity regardless of the gene mutation—whether that gene encodes an anchorage subunit (*SDHD*) or a catalytic subunit (*SDHB*) (20,21). In our patient, genetic testing demonstrated an exon 4 mutation in codon 109 of the *SDHD* gene, suggesting potential high risk of recurrence; in contrast, patients with *SDHB*

Table 1
Overview of Clinical Characteristics of All Patients in
Published Reports of Pheochromocytoma and Cerebral Hemorrhage

Case	Age (y) and sex		Symptoms ^a	Hypertension	Area of hemorrhage	Adrenal or extra-adrenal	Single or multiple	Hereditary pheochromocytoma (gene involved)	Reference
1	26	M	Yes	Yes	Subarachnoid, due to rupture of aneurysm	Adrenal	Bilateral	Yes (<i>VHL</i>)	8
2	44	M	Yes	Yes	Temporal	Adrenal	Single	No	8
3	45	F	Yes	Yes	Intraventricular	Adrenal	Single	No	9
4	18	M	Yes	Yes	Frontoparietal	Extra-adrenal (para-aortic area)	Single	No	7
5	6	M	Yes	Yes	Occipital	Adrenal	Single	No	14
6	24	F	Yes	Yes	Pontine	Adrenal	Single	No	15
7	51	M	Yes	Yes	Putamen	Extra-adrenal (urinary bladder)	Single	No	10
8	23	F	Yes	Yes	Frontoparietal	Extra-adrenal	Multiple	Yes (<i>SDHD</i>)	Current case

^aHeadaches, palpitations, sweating, and paroxysmal episodes of hypertension.

germline mutations have a high risk of a malignant tumor (22). The mutation of the *SDHD* gene (localized on chromosome 11q23) is related to long-term hypoxic stimulation, cellular proliferation, and specifically the development of paragangliomas (23).

As in our case, this genetic susceptibility might lead to the development of multiple paragangliomas in the head, neck, and abdomen, with high risk also, even after a thorough preoperative study and surgical treatment, of residual and recurrent lesions, signified by poorly controlled hypertension. Genetic testing is recommended for patients younger than 20 years with an apparently sporadic pheochromocytoma who have a family history or have features suggestive of hereditary pheochromocytoma or for patients with sympathetic paragangliomas. For patients who do not meet these criteria, genetic testing is optional (24).

Our particular case illustrates the importance of a thorough search for secondary causes of hypertension in young patients. Common causes include renal pathologic conditions, such as renal artery stenosis (fibromuscular dysplasia) and glomerular disease. Endocrine-related causes also exist, such as pheochromocytoma. With this tumor, the most important diagnostic studies are the biochemical evaluation of the urine and blood, which disclose catecholamine production by the tumor, and radiologic studies for localization of a mass.

The biochemical tests for pheochromocytoma are based on the detection of abnormally increased levels of several free catecholamines or metabolites in the urine or blood and are routinely used in the evaluation of patients with hypertension (3,4). Accurate tumor localization is essential, and CT, magnetic resonance imaging, and iodine I 123 (or I 131) metaiodobenzylguanidine scintigraphy are the imaging techniques of choice (3).

In our patient, the initial assessment and management at the peripheral hospital appear to have been suboptimal. The classic triad of headache, palpitations, and diaphoresis associated with hypertension should arouse suspicion of a pheochromocytoma, and these symptoms were present before the diagnosis of cerebral hematoma. The initiation of nonselective β -adrenergic blocking therapy without prior α -adrenergic blockade in a patient with pheochromocytoma may precipitate a crisis with hemodynamic consequences (25). Nonselective β -blockade leads to loss of β_2 -receptor-mediated vasodilation, resulting in arterial hypertension, which can cause myocardial dysfunction, pulmonary edema, intracerebral hemorrhage, and even death. Nonselective β -adrenergic blocking agents should be avoided in any patient who could conceivably have a pheochromocytoma, until that possibility has been excluded.

CONCLUSION

Surgical resection of the tumor is the only curative therapy for pheochromocytoma or paraganglioma but

should be performed as an elective procedure after careful preoperative preparation. Surgical intervention itself is associated with a very high risk of evoking a massive release of catecholamines into the circulation, resulting in one or more of the serious complications mentioned previously.

The goals of preoperative pharmacologic treatment are optimal control of hypertension and of the other pheochromocytoma-related symptoms as well as prevention of perioperative and postoperative complications (26,27). Medical treatment is planned primarily by internists or endocrinologists in accordance with the clinical conditions, the advancements in pharmacologic agents, and the response of patients to the various drugs. Several drugs have been recommended, including α - and β -adrenoreceptor antagonists, calcium channel blockers, and drugs that inhibit catecholamine synthesis. Administration of a β -antagonist is absolutely contraindicated in the absence of α -receptor blockade because unopposed stimulation of α -receptor-mediated vasoconstriction and loss of the β -receptor-mediated vasodilation may cause a dangerous increase in blood pressure (28).

DISCLOSURE

The authors have no conflicts of interest to disclose.

REFERENCES

1. De Lellis RA, Lloyd RV, Heitz PU, Eng C, eds. *Pathology and Genetics of Tumours of Endocrine Organs: World Health Organization Classification of Tumours*. Lyon, France: IARC Press, 2004: 159.
2. Bausch B, Boedeker CC, Berlis A, et al. Genetic and clinical investigation of pheochromocytoma: a 22-year experience, from Freiburg, Germany to international effort. *Ann N Y Acad Sci.* 2006;1073:122-137.
3. Lenders JW, Eisenhofer G, Mannelli M, Pacak K. Pheochromocytoma. *Lancet.* 2005;366:665-675.
4. Lenders JW, Pacak K, Walther MM, et al. Biochemical diagnosis of pheochromocytoma: which test is best? *JAMA.* 2002;287:1427-1434.
5. Kudva YC, Sawka AM, Young WF Jr. Clinical review 164: the laboratory diagnosis of adrenal pheochromocytoma: the Mayo Clinic experience. *J Clin Endocrinol Metab.* 2003;88:4533-4539.
6. Thomas JE, Rooke ED, Kvale WF. The neurologist's experience with pheochromocytoma: a review of 100 cases. *JAMA.* 1966;197:754-758.
7. Moritani H, Sakamoto M, Yoshida Y, Nasu H, Nemoto R, Nakamura I. Pheochromocytoma of the urinary bladder revealed with cerebral hemorrhage. *Intern Med.* 2001;40:638-642.
8. Gelis A, Pelissier J, Blard JM, Pagès M. Intracranial haemorrhage associated with phaeochromocytoma [article in French]. *Rev Neurol (Paris).* 2004;160:945-948.
9. Rajendra T, Kumar K, Liang LH. Hypertensive primary intraventricular hemorrhage due to a phaeochromocytoma. *ANZ J Surg.* 2006;76:664-667.
10. Park SK, Lee JK, Joo SP, et al. Spontaneous intracerebral haemorrhage caused by extra-adrenal phaeochromocytoma. *J Clin Neurosci.* 2006;13:388-390.

11. **Zuckermandl E.** Ueber Nebenorgane des Sympathicus in retroperitoneal Raum des Menschen. *Anat Anz.* 1901;15:97-114.
12. **West GB, Shepherd DM, Hunter RB, MacGregor AR.** The function of the organs of Zuckermandl. *Clin Sci (Lond).* 1955;12:317-325.
13. **Prys-Roberts C.** Pheochromocytoma—recent progress in its management [published correction appears in *Br J Anaesth.* 2001;86:605]. *Br J Anaesth.* 2000;85:44-57.
14. **Chuang HL, Hsu WH, Hsueh C, Lin JN, Scott RM.** Spontaneous intracranial hemorrhage caused by pheochromocytoma in a child. *Pediatr Neurosurg.* 2002;36:48-51.
15. **Scardigli K, Biller J, Brooks MH, Cespedes LE, Posniak HV.** Pontine hemorrhage in a patient with pheochromocytoma. *Arch Intern Med.* 1985;145:343-344.
16. **Sutton MG, Sheps SG, Lie JT.** Prevalence of clinically unsuspected pheochromocytoma: review of a 50-year autopsy series. *Mayo Clin Proc.* 1981;56:354-360.
17. **Neumann HP, Berger DP, Sigmund G, et al.** Pheochromocytomas, multiple endocrine neoplasia type 2, and von Hippel-Lindau disease [published correction appears in *N Engl J Med.* 1994;331:1535]. *N Engl J Med.* 1993;329:1531-1538.
18. **Gimenez-Roqueplo AP, Favier J, Rustin P, et al (COMETE Network).** Mutations in the SDHB gene are associated with extra-adrenal and/or malignant pheochromocytomas. *Cancer Res.* 2003;63:5615-5621.
19. **Neumann HP, Pawlu C, Peczkowska M, et al (European-American Paraganglioma Study Group).** Distinct clinical features of paraganglioma syndromes associated with SDHB and SDHD gene mutations [published correction appears in *JAMA.* 2004;292:1686]. *JAMA.* 2004;292:943-951.
20. **Baysal BE, Ferrell RE, Willett-Brozick JE, et al.** Mutations in SDHD, a mitochondrial complex II gene, in hereditary paraganglioma. *Science.* 2000;287:848-851.
21. **Astuti D, Latif F, Dallol A, et al.** Gene mutations in the succinate dehydrogenase subunit SDHB cause susceptibility to familial pheochromocytoma and to familial paraganglioma [published correction appears in *Am J Hum Genet.* 2002;70:565]. *Am J Hum Genet.* 2001;69:49-54.
22. **Benn DE, Gimenez-Roqueplo AP, Reilly JR, et al.** Clinical presentation and penetrance of pheochromocytoma/paraganglioma syndromes. *J Clin Endocrinol Metab.* 2006;91:827-836.
23. **Novosel A, Heger A, Lohse P, Schmidt H.** Multiple pheochromocytomas and paragangliomas in young patient carrying an SDHD gene mutation. *Eur J Pediatr.* 2001;163:701-703.
24. **Jiménez C, Cote G, Arnold A, Gagel RF.** Review: should patients with apparently sporadic pheochromocytomas or paragangliomas be screened for hereditary syndromes? *J Clin Endocrinol Metab.* 2006;91:2851-2858.
25. **van der Horst-Schrivers AN, Kerstens MN, Wolffenbuttel BH.** Preoperative pharmacological management of pheochromocytoma. *Neth J Med.* 2006;64:290-295.
26. **Kinney MA, Narr BJ, Warner MA.** Perioperative management of pheochromocytoma. *J Cardiothorac Vasc Anesth.* 2002;16:359-369.
27. **Fernández-Cruz L, Taurá P, Sáenz A, Benarroch G, Sabater L.** Laparoscopic approach to pheochromocytoma: hemodynamic changes and catecholamine secretion. *World J Surg.* 1996;20:762-768.
28. **Prichard BN, Ross EJ.** Use of propranolol in conjunction with alpha receptor blocking drugs in pheochromocytoma. *Am J Cardiol.* 1966;18:394-398.