

# Neurology<sup>®</sup>

## **Teaching Video *NeuroImage*: Foix–Chavany–Marie syndrome**

Peter L. Konieczny, Benjamin H. Eidelman and William D. Freeman

*Neurology* 2008;70:e88

DOI 10.1212/01.wnl.0000312516.55722.dd

**This information is current as of May 19, 2008**

The online version of this article, along with updated information and services, is located on the World Wide Web at:

<http://www.neurology.org/content/70/21/e88.full.html>

*Neurology*® is the official journal of the American Academy of Neurology. Published continuously since 1951, it is now a weekly with 48 issues per year. Copyright . All rights reserved. Print ISSN: 0028-3878. Online ISSN: 1526-632X.



# Teaching Video NeuroImage: Foix–Chavany–Marie syndrome



Peter L. Konieczny,  
MD  
Benjamin H.  
Eidelman, MD, PhD  
William D. Freeman,  
MD

Address correspondence and  
reprint requests to Dr. William  
D. Freeman, Department of  
Neurology, Mayo Clinic, 4500  
San Pablo Road, Jacksonville,  
FL 32224  
freeman.william1@mayo.edu

A 79-year-old woman with a history of prior right frontal infarction presented with sudden inability to speak (figure, A). Examination revealed anarthria, yet intact comprehension, writing, and limb function (video). Voluntary tongue, swallowing, and mouth movements were absent, while cough and swallow reflexes were preserved (video). An acute left hemispheric ischemic stroke causing Foix-Chavany-Marie syndrome (FCMS) was diagnosed, and IV recombinant tissue plasminogen activator was administered. Left frontal infarction was confirmed on MRI (figure, B).

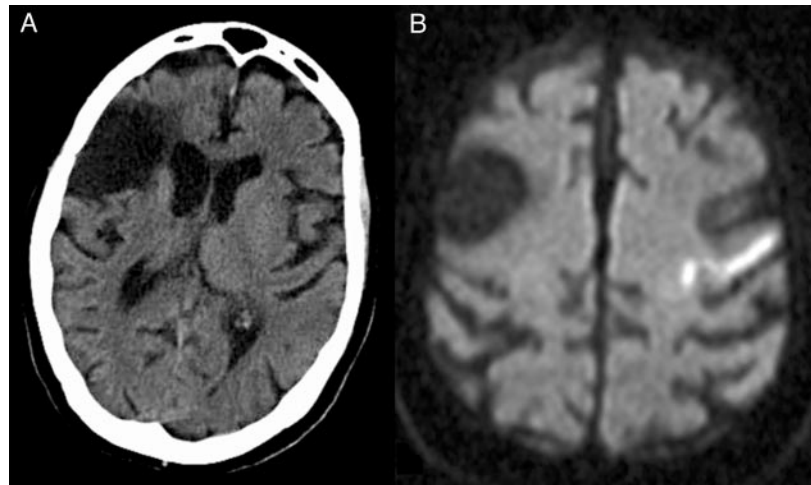
FCMS involves lesions of the bilateral frontal operculum<sup>1</sup> or the cortical-subcortical areas of

primary motor cortex.<sup>2</sup> Voluntary control of facio-pharyngo-glosso-masticatory muscles is lost, while reflex movements and limb strength are preserved.

## REFERENCES

1. Foix C, Chavany J-A, Marie J. Diplégie facio-linguo-masticatrice d'origine cortico sous-corticale sans paralysie des membres (contribution à l'étude de la localisation des centres de la face du membre supérieur), par MM. *Rev Neurol* 1926;33:214–219.
2. Weller M. Anterior opercular cortex lesions cause dissociated lower cranial nerve palsies and anarthria but no aphasia: Foix-Chavany-Marie syndrome and “automatic voluntary dissociation” revisited. *J Neurol* 1993; 240:199–208.

**Figure** (A) CT scan without contrast showing area of old right-sided infarct encompassing the frontoparietal opercular cortex; (B) diffusion-weighted MRI with restricted diffusion in the left precentral gyrus



**Teaching Video *NeuroImage*: Foix–Chavany–Marie syndrome**  
Peter L. Konieczny, Benjamin H. Eidelman and William D. Freeman  
*Neurology* 2008;70:e88  
DOI 10.1212/01.wnl.0000312516.55722.dd

**This information is current as of May 19, 2008**

<b>Updated Information &amp; Services</b>	including high resolution figures, can be found at: <a href="http://www.neurology.org/content/70/21/e88.full.html">http://www.neurology.org/content/70/21/e88.full.html</a>
<b>Supplementary Material</b>	Supplementary material can be found at: <a href="http://www.neurology.org/content/suppl/2008/05/16/70.21.e88.DC1.html">http://www.neurology.org/content/suppl/2008/05/16/70.21.e88.DC1.html</a>
<b>References</b>	This article cites 2 articles, 0 of which you can access for free at: <a href="http://www.neurology.org/content/70/21/e88.full.html##ref-list-1">http://www.neurology.org/content/70/21/e88.full.html##ref-list-1</a>
<b>Permissions &amp; Licensing</b>	Information about reproducing this article in parts (figures, tables) or in its entirety can be found online at: <a href="http://www.neurology.org/misc/about.xhtml#permissions">http://www.neurology.org/misc/about.xhtml#permissions</a>
<b>Reprints</b>	Information about ordering reprints can be found online: <a href="http://www.neurology.org/misc/addir.xhtml#reprintsus">http://www.neurology.org/misc/addir.xhtml#reprintsus</a>

