

Case Report

Microangiopathy of the Brain, Retina, and Ear: Improvement Without Immunosuppressive Therapy

David Lee Gordon, MD; Sohan Singh Hayreh, MD, PhD, DSc; and Harold P. Adams Jr., MD

We describe a pregnant young woman with branch retinal arteriolar occlusions, encephalopathy, and hearing loss in whom we demonstrated a patent foramen ovale. She improved while receiving anticoagulants and no immunosuppressive therapy. The microangiopathic syndrome of retinopathy, encephalopathy, and deafness may be due to a disturbance of coagulation and/or microembolism. (*Stroke* 1991;22:933–937)

Since 1973 several reports have described a “microangiopathy” causing retinopathy, encephalopathy, and deafness in young women.^{1–8} Ophthalmoscopy and brain biopsy have suggested that an arteriopathic process is responsible for this syndrome. Although no immunologic or inflammatory etiology has been found, all previously reported patients were treated with steroids and/or other immunosuppressive agents. Many patients were said to have improved with therapy. Yet a closer look at these cases reveals that this syndrome runs a fluctuating and progressive course that eventually stabilizes regardless of treatment. We report a case in which the patient improved without immunosuppressive therapy.

Case Report

On May 30, 1989, a 28-year-old previously healthy woman in her 28th week of pregnancy experienced the sudden, painless appearance of a black spot in front of the lower, inner quadrant of her right eye. She had noted periodic imbalance over the previous 2 months. Examination of the fundus on June 2 demonstrated a superotemporal retinal infarct secondary to superior temporal retinal arteriolar occlusion and a cotton-wool spot (Figure 1A). It was not possible to find an embolus at the site of occlusion because of marked opacity of the retinal tissue in the region. The anterior segment and vitreous in the right eye showed no abnormality. Carotid duplex scan was normal, antinuclear antibody (ANA) titer

was elevated at 1:160 (speckled pattern), and the erythrocyte sedimentation rate (ESR) was 42 mm/hr.

On June 11, the patient developed slurred speech and personality changes. Later the same day she had difficulty sitting and walking, with a tendency to fall to the left. She was admitted to a hospital where a computed tomogram (CT scan) of the brain, electrocardiogram, screening blood work (including ANA and cardiolipin antibody titers), blood cultures, evoked potentials, and deep-venous Doppler sonograms of the lower extremities were normal. The ESR was 50 mm/hr, and contrast echocardiography revealed a right-to-left shunt with Valsalva maneuver, consistent with a patent foramen ovale. She was treated with intravenous heparin and improved slightly, although her dysarthria persisted. She was discharged on June 18 taking subcutaneous heparin (5,000 units every 12 hours).

Over the next 48 hours, her speech deteriorated and she developed decreased interest in her environment, perioral numbness, and unsteady gait with falling to the right. She was readmitted and given intravenous heparin. T2-weighted magnetic resonance imaging (MRI) of the brain performed on June 22 showed multifocal areas of increased signal intensity in the deep white matter, anterior corpus callosum, and brain stem. One week later she was transferred to the University of Iowa Hospitals and Clinics for further care.

On arrival her vital signs were normal. She had a gravid uterus and a 2/6 systolic murmur over the precordium. She had a flat affect, and she was dysarthric. There was a retinal infarct in the superior temporal sector of the right fundus. Her gait was broad-based and ataxic. She had bilateral Babinski's signs.

After admission, intravenous heparin was continued. Her mentation worsened; she became disori-

From the Department of Neurology, Division of Cerebrovascular Diseases (D.L.G., H.P.A.), and the Department of Ophthalmology (S.S.H.), the University of Iowa College of Medicine, Iowa City, Iowa.

Address for correspondence: David Lee Gordon, MD, Department of Neurology, University of Iowa College of Medicine, Iowa City, IA 52242.

Received November 29, 1990; accepted March 14, 1991.

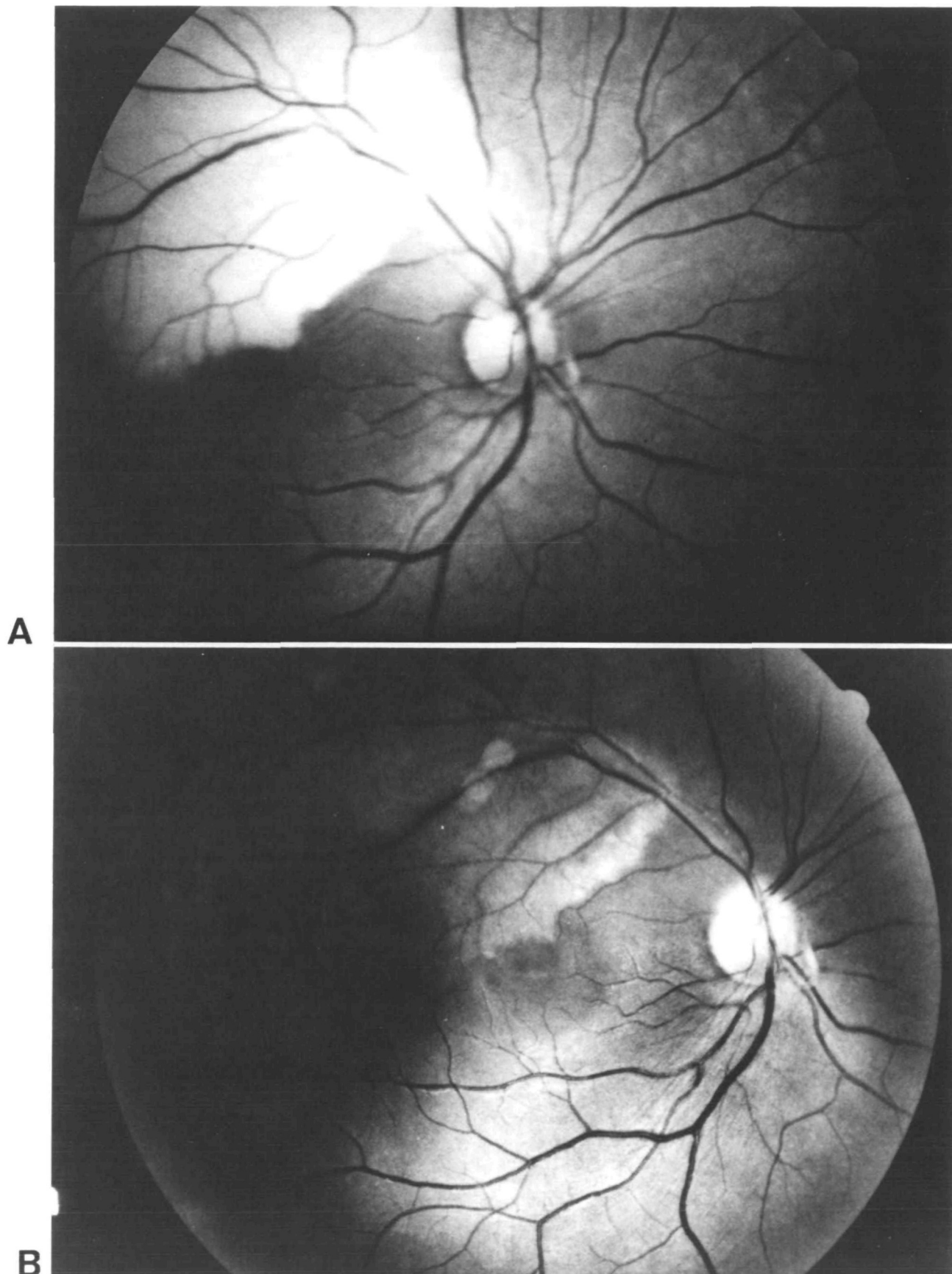


FIGURE 1. Right eye. A: Fundus photograph on June 2, 1989, shows infarction of superior temporal retina in distribution of superior temporal retinal arteriole. B: Fundus photograph on July 17, 1989, shows resolving infarct.

ented, responded minimally to questions, and had little interest in her environment. No new lateralizing signs developed. A repeat carotid duplex scan was normal. Repeat contrast echocardiography showed a right-to-left shunt without maneuvers. Thyroid studies and C-reactive protein and double-stranded deoxyribonucleic acid antibody titers were normal. Blood cultures were negative. Visual evoked potentials were abnormal in the left eye. Somatosensory evoked potentials and brain stem auditory evoked potentials were normal. An electroencephalogram (EEG) showed diffuse slowing. Formal neurobehavior testing showed moderate to severe impairments in virtually all assessed aspects of cognitive function including attention, memory, behavioral organization, praxis, and language. She also showed perseverative tendencies and poor awareness of her condition. These findings were believed to be consistent with multifocal brain dysfunction. A CT scan of the brain without contrast done on July 1 was normal. Anticoagulants were stopped, and cerebrospinal fluid (CSF) examination revealed a protein concentration of 207 mg/dl with a glucose concentration of 55 mg/dl (serum glucose concentration 89 mg/dl), 2 white blood cells/mm³, a normal myelin-basic protein concentration and IgG index, and absent oligoclonal bands. Another CT scan without contrast done on July 5 showed small areas of hypodensity in the genu of the corpus callosum and the periventricular white matter. Four days later she delivered a healthy infant boy. A cerebral arteriogram done 4 days after the delivery was normal. A second CSF examination showed a protein concentration of 144 mg/dl, a glucose concentration of 59 mg/dl, 1 white blood cell/mm³, and a normal immunoelectrophoresis pattern.

Fundus examination on July 17 demonstrated four branch retinal arteriolar occlusions in the left eye, lesions consistent with white platelet emboli at the sites of occlusion, and a cotton-wool spot (Figure 2). Fluorescein angiography showed occlusion of retinal arterioles during the transit phase (Figure 2B) and, during the late phase, showed no vessel wall staining or leakage of fluorescein at the occlusion sites, suggesting that microembolism, rather than vasculitis, caused the arteriolar occlusions. There was marked ophthalmoscopic resolution of the previously noted retinal infarct in the right eye (Figure 1B). Visual field plotting revealed corresponding field defects in both eyes. The anterior segment and vitreous in both eyes showed no abnormality. Audiometry demonstrated mild bilateral sensorineural hearing loss. Serum complement levels were mildly elevated (C3 196 mg/dl [normal range 70–176 mg/dl] and C4 45 mg/dl [normal range 16–45 mg/dl]).

After delivery, the patient's mental status, dysarthria, and ataxia gradually improved, although she remained amnesic for many of the events of the past month. She was discharged taking warfarin on July 25. Ultrafast (cine) CT scan of the heart done as an outpatient was normal. Six weeks after her discharge, her examination was remarkable only for persistent

visual field deficits in both eyes; her mental status, speech, coordination, and gait were normal. She took warfarin for 8 months without further episodes. She then took 325 mg aspirin per day, and on April 13, 1990, a hypercoagulability profile including partial thromboplastin time; thrombin time; fibrinogen, anti-thrombin III, protein C, protein S, and plasminogen concentrations; platelet count; and platelet aggregation studies was normal.

Discussion

The clinical features of this syndrome affecting arteriolar vascular distributions may be categorized within the triad of encephalopathy, retinopathy, and hearing loss. Our patient had all the typical clinical features of this syndrome. She is a woman within the age range of 18–40 years. She had an encephalopathy manifested by personality change, dementia, ataxia, long-tract signs, and dysarthria. She had multifocal branch retinal arteriolar occlusions with associated retinal infarcts and scotomas. She had bilateral sensorineural hearing loss detected by audiometry. She had a marked elevation of the CSF protein concentration without a marked pleocytosis. Her initial CT scan was normal and MRI showed multifocal areas of increased signal intensity in the cerebral white matter on T2-weighted images. Her cerebral arteriogram was normal. Her EEG showed diffuse slowing. She had a moderately elevated ESR, but there was no other evidence for vasculitis or for systemic lupus erythematosus.

Hearing loss was not a prominent symptom of our patient. Only two of the 17 previously reported patients did not complain of hearing loss, but neither patient underwent audiometry.¹ Thus, the hearing loss may be subclinical and patients with other findings suggestive of this syndrome should have audiometry to detect hearing dysfunction.

Our patient is the second to have her initial symptoms while pregnant.⁵ A third patient delivered a stillborn, anencephalic child during a remission and suffered a recurrence immediately postpartum.³ Two other women experienced amenorrhea as an early symptom.⁷ The significance of an obstetric or gynecologic association with this syndrome is unclear; the syndrome affects young women and so such an association may be no more than coincidence. Still, a transient hypercoagulable state such as that associated with pregnancy may play a role in the pathophysiology of this syndrome.

Branch retinal arteriolar occlusions are most often due to emboli.⁹ Retinal emboli are fleeting by nature, and thus the absence of emboli on fundus examination does not prove that they were not responsible for the arteriolar occlusions. We recorded lesions consistent with platelet emboli in some of the occluded retinal arterioles of our patient (Figure 2A). It is possible that the basic lesion in this syndrome is a coagulation abnormality, with disseminated focal ischemic lesions in the brain, retina, and auditory apparatus responsible for the signs and symptoms. It

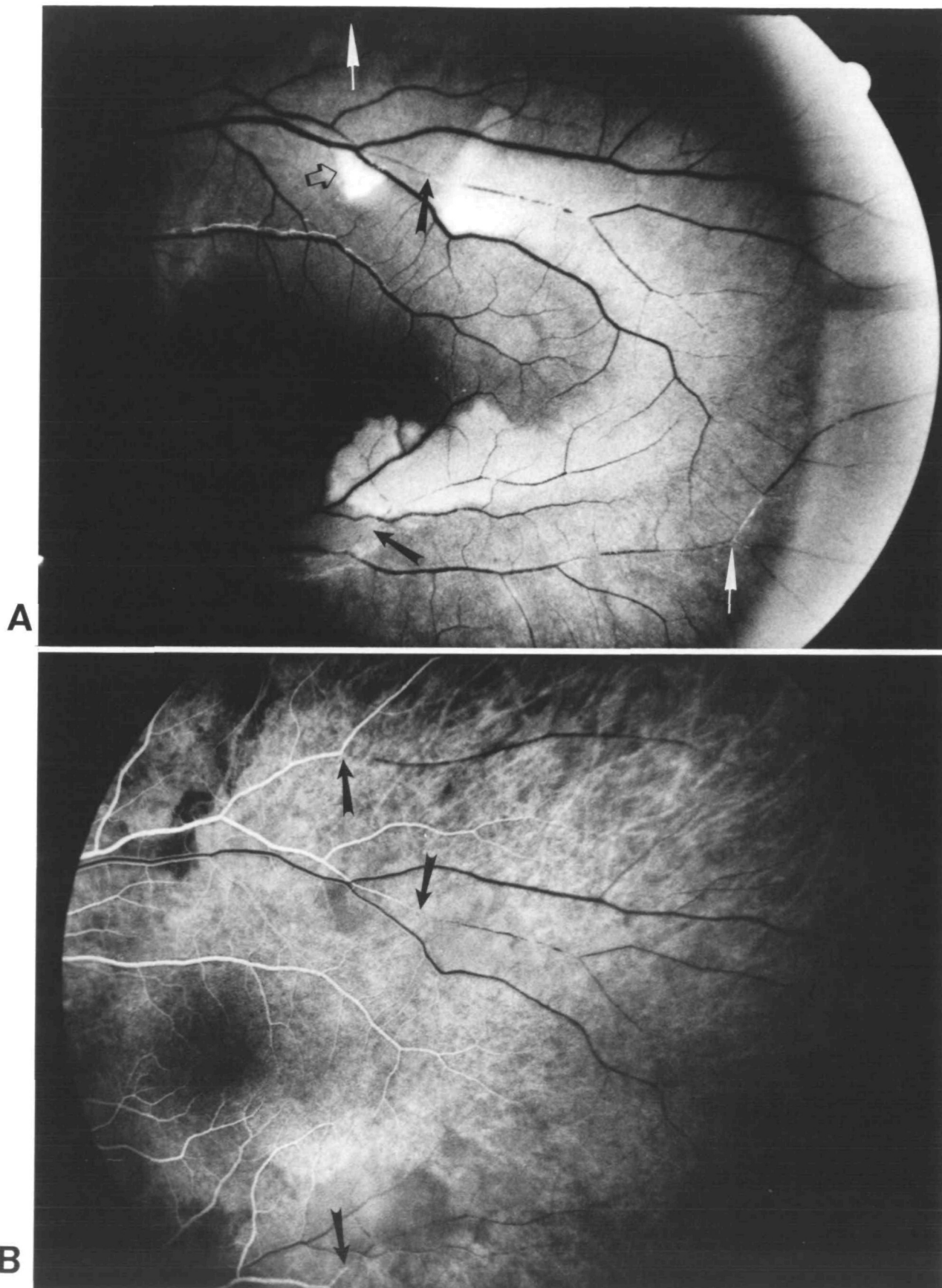


FIGURE 2. Left eye. A: Fundus photograph on July 17, 1989, shows multiple sites (arrows) of retinal arteriolar occlusion; more recent occlusions show retinal opacity in their distributions because of retinal infarction. In addition to retinal arteriolar occlusions, there is one cotton-wool spot (open arrow) that represents focal retinal infarct. B: Fluorescein fundus angiogram from same day shows sites of retinal arteriolar occlusion (arrows) and nonperfusion of retina in distributions of occluded arterioles. Late-phase angiogram revealed no staining of vessel wall or leakage of fluorescein at occlusion sites, making vasculitis unlikely cause of occlusions.

is also possible that similar microembolization is occurring in other organs without causing detectable symptoms.

Our patient was shown to have a patent foramen ovale. Only two other patients with this syndrome were reported to undergo echocardiography, and in neither case was contrast echocardiography mentioned.^{2,3} Two recent studies found a patent foramen ovale by contrast echocardiography in 40–50% of young patients with stroke compared with 10–15% of healthy controls.^{10,11} Perhaps the patent foramen ovale of our patient contributed to the dissemination of microemboli and resulted in her condition.

Our patient improved with anticoagulation. Other investigators have reported improvement with steroids and/or other immunosuppressive therapy. Of the 17 previously reported patients, however, six had a remission without treatment and 11 either worsened or showed no change while receiving immunosuppressive therapy. The natural course of this syndrome appears to fluctuate, progress, and eventually stabilize, and with both the pathophysiology and natural course of the syndrome not yet clarified, one cannot accurately determine the effect of any therapeutic modality. Our case report suggests that this

uncommon “microangiopathy” of brain, retina, and ear may in fact be due to microembolism in young women with a transient hypercoagulable state and a patent foramen ovale.

References

1. Pfaffenbach DP, Hollenhorst RW: Microangiopathy of the retinal arterioles. *JAMA* 1973;225:480–483
2. Susac JO, Hardman JM, Selhorst JB: Microangiopathy of the brain and retina. *Neurology* 1979;29:313–316
3. Coppeto JR, Currie JN, Monteiro MLR, Lessell S: A syndrome of arterial-occlusive retinopathy and encephalopathy. *Am J Ophthalmol* 1984;98:189–202
4. Monteiro MLR, Swanson RA, Coppeto JR, Cuneo RA, DeArmond SJ, Prusiner SB: A microangiopathic syndrome of encephalopathy, hearing loss, and retinal arteriolar occlusion. *Neurology* 1985;35:1113–1121
5. MacFadyen DJ, Schneider RJ, Chisolm IA: A syndrome of brain, inner ear and retinal microangiopathy. *Can J Neurol Sci* 1987;14:315–318
6. Mass M, Bourdette D, Bernstein W, Hammerstad J: Retinopathy, encephalopathy, deafness associated microangiopathy (the RED M syndrome): Three new cases (abstract). *Neurology* 1988;38(suppl 1):215
7. Heiskala H, Somer H, Kovanen J, Poutiainen E, Karli H, Haltia M: Microangiopathy with encephalopathy, hearing loss and retinal arteriolar occlusions: Two new cases. *J Neurol Sci* 1988;86:239–250
8. Bogousslavsky J, Gaio J-M, Caplan LR, Regli F, Hommel M, Hedges TR III, Ferrazzini M, Pollak P: Encephalopathy, deafness and blindness in young women: A distinct retinocochleocerebral arteriopathy? *J Neurol Neurosurg Psychiatry* 1989;52:43–46
9. Wilson LA, Warlow CP, Ross Russell RW: Cardiovascular disease in patients with retinal arterial occlusion. *Lancet* 1979;1:292–294
10. Lechat P, Mas JL, Lascault G, Loron P, Theard M, Klimczak M, Drobinski G, Thomas D, Grosgeat Y: Prevalence of patent foramen ovale in patients with stroke. *N Engl J Med* 1988;318:1148–1152
11. Webster MWI, Chancellor AM, Smith HJ, Swift DL, Sharpe DN, Bass NM, Glasgow GL: Patent foremen ovale in young stroke patients. *Lancet* 1988;2:11–12

KEY WORDS • arterial occlusive diseases • cerebrovascular disorders • deafness

Microangiopathy of the brain, retina, and ear: improvement without immunosuppressive therapy.

D L Gordon, S S Hayreh and H P Adams, Jr

Stroke. 1991;22:933-937

doi: 10.1161/01.STR.22.7.933

Stroke is published by the American Heart Association, 7272 Greenville Avenue, Dallas, TX 75231

Copyright © 1991 American Heart Association, Inc. All rights reserved.

Print ISSN: 0039-2499. Online ISSN: 1524-4628

The online version of this article, along with updated information and services, is located on the World Wide Web at:

<http://stroke.ahajournals.org/content/22/7/933>

Permissions: Requests for permissions to reproduce figures, tables, or portions of articles originally published in *Stroke* can be obtained via RightsLink, a service of the Copyright Clearance Center, not the Editorial Office. Once the online version of the published article for which permission is being requested is located, click Request Permissions in the middle column of the Web page under Services. Further information about this process is available in the [Permissions and Rights Question and Answer](#) document.

Reprints: Information about reprints can be found online at:
<http://www.lww.com/reprints>

Subscriptions: Information about subscribing to *Stroke* is online at:
<http://stroke.ahajournals.org/subscriptions/>