

Diffuse Multicystic Encephalomalacia in a Preterm Baby Due to Homozygous Methylenetetrahydrofolate Reductase 677 C→T Mutation

Canan Aygun, MD, Bilge Tanyeri, MD, Meltem Ceyhan, MD, Hasan Bagcı, PhD, and Sukru Kucukoduk, MD

Methylenetetrahydrofolate reductase catalyzes the formation of 5-methyltetrahydrofolate from 5,10-methylenetetrahydrofolate and produces folate for the methylation of homocysteine to methionine. Due to insufficient conversion of homocysteine to methionine, plasma homocysteine levels increase in methylenetetrahydrofolate reductase deficiency. Homocysteine is an amino acid that contains a neurotoxic sulfur molecule and can induce neuronal apoptosis. Methylenetetrahydrofolate

reductase deficiency is 1 of the etiological factors that causes neurological symptoms and signs in the newborn and childhood period. Here, we report a premature baby with prenatal onset diffuse multicystic encephalomalacia and cerebellar atrophy due to homozygous methylenetetrahydrofolate reductase mutation.

Keywords: multicystic encephalomalacia; methylenetetrahydrofolate reductase mutation

Methylenetetrahydrofolate reductase catalyzes the formation of 5-methyltetrahydrofolate from 5,10-methylenetetrahydrofolate and produces folate for the methylation of homocysteine to methionine. The gene for methylenetetrahydrofolate reductase is located on chromosome 1p36.3, and defects of this gene result in inherited disorders of folate metabolism.¹ In methylenetetrahydrofolate reductase deficiency, due to insufficient conversion of homocysteine to methionine, plasma homocysteine levels increase. Homocysteine is an amino acid that contains a neurotoxic sulfur molecule and can induce neuronal apoptosis. Additionally, it increases neuronal vulnerability to excitotoxicity.² The association between plasma homocysteine levels and increased risk of thrombosis and stroke has been demonstrated.³ There also are reports showing that methylenetetrahydrofolate reductase deficiency is 1 of the etiological factors causing neurological symptoms and signs

in the newborn and childhood period.⁴ Here, we report a premature baby with prenatal onset diffuse multicystic encephalomalacia and cerebellar atrophy due to homozygous methylenetetrahydrofolate reductase mutation.

Case Report

A male infant was the second child of unrelated parents. He was born at 30 weeks of gestation by means of vaginal delivery from an uncomplicated pregnancy. The 19-year-old mother, without appropriate antenatal care, did not have any obstetric ultrasonographic evaluation that reported vaginal hemorrhage before the onset of labor. He weighed 1450 grams (75–90 percentile), height was 40 cm (75–90 percentile), head circumference was 27.5 cm (25–50 percentile). He was transferred to the neonatal intensive care unit of a local hospital because of respiratory distress. Apgar scores were not recorded. The baby was hypotonic and hypothermic on admission with a bulging 1 × 1 cm anterior fontanel. Moro and sucking reflexes were absent. The baby was diagnosed as respiratory distress syndrome, and he was put on a mechanical ventilator and received 1 dose of exogenous surfactant. He had an umbilical vein catheter that was kept in place for 9 days. On the fourth day of life, his clinical situation deteriorated, sepsis work-up was performed, and antibiotic therapy

From the Department of Pediatrics, Neonatology Unit (CA, BT, SK), Department of Radiology (MC), and Department of Medical Biology (HB), Ondokuz Mayıs University Faculty of Medicine, Samsun, Turkey.

Address correspondence to: Bilge Tanyeri, MD, Ondokuz Mayıs Üniversitesi Tıp Fakültesi Neonatoloji Ünitesi 9.kat Kurupelit, 55139, Samsun, Turkey; e-mail: btanyer@yahoo.com.

Aygun C, Tanyeri B, Ceyhan M, Bagcı H, Kucukoduk S. Diffuse multicystic encephalomalacia in a preterm baby due to homozygous methylenetetrahydrofolate reductase 677 C→T mutation. *J Child Neurol*. 2008;23:695-698.

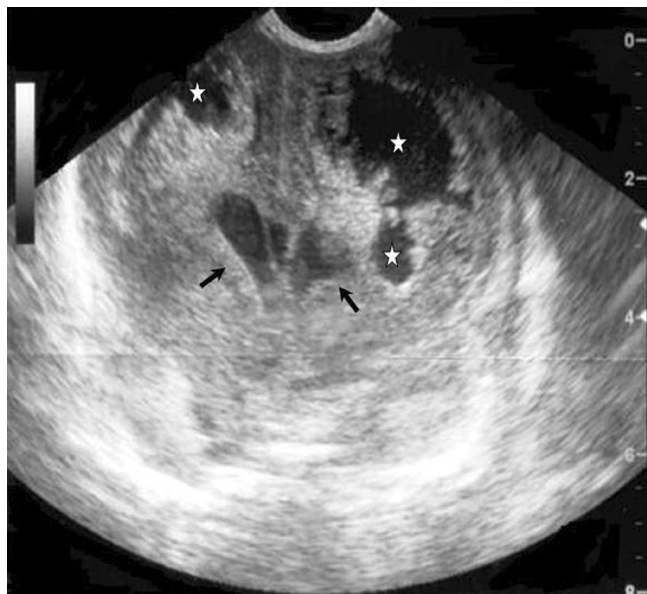

Figure 1. Coronal cranial ultrasonography images reveal dilated lateral ventricles and periventricular cysts. White star, cystic encephalomalacia; black arrow, dilated lateral ventricles.

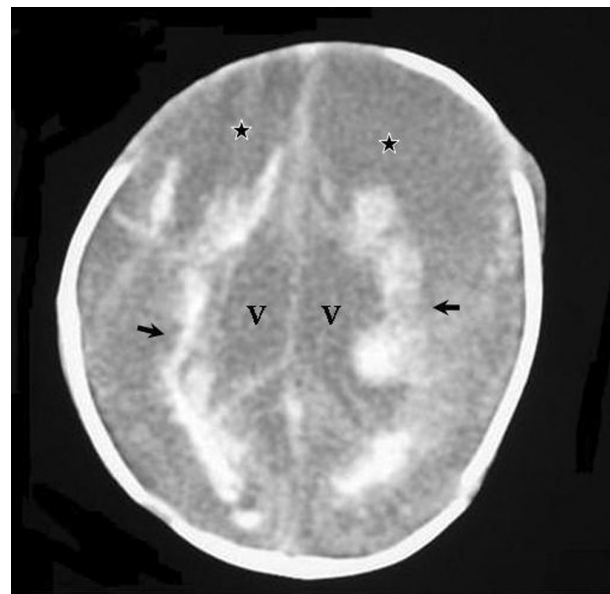


Figure 2. Cranial computerized tomography shows conglomerated large cysts on the frontal area, dilated lateral ventricles and periventricular hemorrhage. Black star, cystic encephalomalacia; black arrow, periventricular hemorrhage; V, lateral ventricle.

was started. Meanwhile, he developed acute renal failure and because of resistant hyperkalemia, peritoneal dialysis was performed. Due to the unavailability of portable ultrasonography, cranial ultrasonography could not be done until the fifth day of life, which showed periventricular and parenchymal anechoic cysts and dilated lateral ventricles (Figure 1). According to these results, tests for thrombophilia were ordered. Protein C and protein S and antithrombin levels were within the normal limits. Prothrombin 20210 A mutation was not detected. Cranial computerized tomography was performed on the 19th day of life and showed diffuse cysts conglomerated in the frontal region. Periventricular white matter hemorrhage and bilateral lateral ventricle dilatation were also shown (Figure 2).

The patient died on the 32nd day of life. Blood culture results were negative. Postmortem cranial magnetic resonance imaging demonstrated diffuse bilateral hemisphere cystic encephalomalacia and hypoplastic cerebellum. There were bilateral hyperintensities on T1-weighted images in hemispherical white matter areas that revealed multifocal hemorrhages and dilated lateral ventricles (Figure 3). Homozygous methylenetetrahydrofolate reductase mutation (677 C→T) was detected after the baby's death, so plasma homocysteine levels could not be studied. His family refused autopsy.

Discussion

The defect on the elimination of homocystine by transsulfuration is a 677 C→T mutation. Homozygosity for methylenetetrahydrofolate reductase 677 C→T gene variant, which is the most common genetic defect in folate metabolism, is reported as high as 10–15% in North American and European populations.⁵ The mutation modifies the risk for several multifactorial diseases such as vascular arteriosclerotic or thrombotic disease, colonic cancer, acute leukemia, neural tube defects, and pregnancy complications.⁶ Otherwise severe methylenetetrahydrofolate reductase deficiency is a rare cause of inborn error of metabolism. Patients with severe methylenetetrahydrofolate reductase deficiency exhibit developmental delay, motor and gait abnormalities, peripheral neuropathy, hypotonia, and seizures.⁷

Recently, the changes in the central nervous system due to methylenetetrahydrofolate reductase deficiency have been identified. Al Tawari et al reported 4 siblings with methylenetetrahydrofolate reductase deficiency who had demyelination in the white matter and cerebral atrophy in cranial computerized tomography and cranial magnetic resonance imaging.⁸ One child of this family had ventriculomegaly and hypoplasia of pons, medulla, and

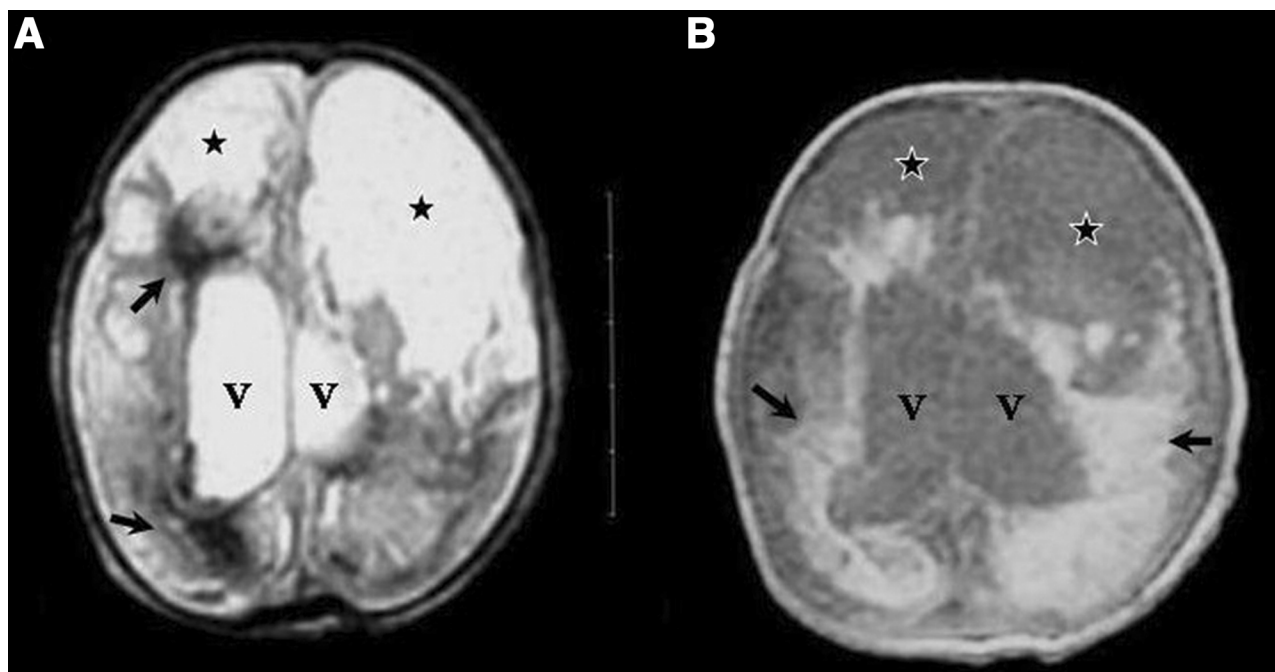


Figure 3. Postmortem cranial magnetic resonance imaging images (A) T2-weighted hypointensity (B) T1-weighted hyperintensity periventricular hemorrhage (black arrow). Dilated lateral ventricle (V) and cystic encephalomalacia on frontoparietal region (black star).

cerebellum on magnetic resonance imaging. Baethmann et al also discussed the unknown etiology of hydrocephaly and its possible relationship with methylenetetrahydrofolate reductase deficiency.⁹ Chen et al showed a reduction in cerebellar size and dilation of lateral ventricles in homozygous methylenetetrahydrofolate reductase-deficient mice, which were similar to our patient.¹⁰

The response of the brain to pre-, peri-, or postnatal anoxia, inflammation, and trauma shows different pathological findings according to the time of the insult. Cerebral malformations may occur in the first and second trimester, and after the second trimester, white and gray matter damage and necrosis, cavitation, and gliosis may be observed. Generally, cystic formation within white matter occurs in 1 to 3 weeks.¹¹⁻¹³ Cysts were detected on the fifth day of life in our patient, indicating the beginning of the brain damage in the intrauterine period. Chou et al reported a baby whose twin died in utero.¹⁴ The first cranial ultrasonography of that baby was normal but diffuse encephalomalacia was found in the cranial ultrasonography performed at the first month of life. In this baby, the ultrasonography and cranial computerized tomography showed cerebral hemispherical density loss in the 8th and 12th day of life. These findings also suggest that the time required for the cystic changes to appear is nearly 2 weeks in a newborn.

Increased prevalence of heterozygous inhibitor deficiencies have been described in newborns with porencephaly and intracerebral hemorrhage.¹⁵ Deficiencies in the anticoagulant pathways leading to perinatally acquired porencephalic

cysts have been investigated by Debus et al. They retrospectively studied 24 neonates and children for the presence of factor V Leiden mutation, protein C deficiency, antithrombin, lipoprotein A, and antiphospholipid antibodies. They showed genetically acquired thrombophilic risk factors in 16 of these babies.¹⁶ Methylenetetrahydrofolate reductase mutation was not studied in these series, but the study is important to highlight the association between thrombophilia and perinatally acquired porencephalic cysts.

According to the available data, multicystic encephalomalacia in our patient had begun in intrauterine life and methylenetetrahydrofolate reductase deficiency is the etiological factor for these lesions. We conclude that searching for this mutation in encephalomalacic lesions of the brain in newborns will reveal the effect of this mutation on brain development and perinatal thrombosis.

Acknowledgment

We thank Hande Turker, MD (Ondokuz Mayıs University Hospital), for the English revision of the manuscript.

References

1. Födinger M, Wagner OF, Hörl WH, et al. Recent insights into the molecular genetics of the homocysteine metabolism. *Kidney Int.* 2001;59:238-242.

2. Kruman II, Culmsee C, Chan SL, et al. Homocysteine elicits a DNA damage response in neurons that promotes apoptosis and hypersensitivity to excitotoxicity. *J Neurosci*. 2000;20:6920-6926.
3. Günther G, Junker R, Sträter R, et al. Symptomatic ischemic stroke in full-term neonates: role of acquired and genetic prothrombotic risk factors. *Stroke*. 2000;31:2437-2441.
4. Larsen TB, Norgaard-Pedersen B, Lundemose JB, et al. Sudden infant death syndrome, childhood thrombosis, and presence of genetic risk factors for thrombosis. *Thromb Res*. 2000;98:233-239.
5. Frosst P, Blom HJ, Milos R, et al. A candidate genetic risk factor for vascular disease: a common mutation in methylenetetrahydrofolate reductase. *Nat Genet*. 1995;10:111-113.
6. Schwahn B, Rozen R. Polymorphisms in the methylenetetrahydrofolate reductase gene: clinical consequences. *Am J Pharmacogenomics*. 2001;1:189-201.
7. Rossenblatt DS, Fenton W. Inherited disorders of folate and cobalamin transport and metabolism. In: Scriver CR, Beaudet AL, Sly WS, Vale D, eds. *The Metabolic and Molecular Bases of Inherited Disease*. 8th ed. New York: McGraw-Hill; 2001:3897-3933.
8. Al Tawari AA, Ramadan DG, Neubauer D, et al. An early onset form of methylenetetrahydrofolate reductase deficiency: a report of a family from Kuwait. *Brain Dev*. 2002;24:304-309.
9. Baethmann M, Wendel U, Hoffmann GF, et al. Hydrocephalus internus in two patients with 5,10- methylenetetrahydrofolate reductase deficiency. *Neuropediatrics*. 2000;31:314-317.
10. Chen Z, Schwahn BC, Wu Q, et al. Postnatal cerebellar defects in mice deficient in methylenetetrahydrofolate reductase. *Int J Dev Neurosci*. 2005;23:465-474.
11. Barkovich AJ. *Pediatric Neuroimaging*. 3rd ed. Philadelphia: Lippincott, Williams & Wilkins; 2000:157-250.
12. Barnes PD. Imaging of the central nervous system in pediatrics and adolescence. *Pediatr Clin North Am*. 1992;39:743-776.
13. Naidich TP, Chakera TMH. Multicystic encephalomalacia: CT appearance and pathologic correlation. *J Comput Assist Tomogr*. 1984;8:631-636.
14. Chou YH, Tsou Yau KI, Wang PJ, et al. Multicystic encephalomalacia in a surviving monochorionic twin. *Zhonghua Min Guo Xiao Er Ke Yi Xue Hui Za Zhi*. 1993;34:474-479.
15. Albizetti M, Andrew M, Monagle P. Hemostatic abnormalities. In: de Alarcón PA, Werner EJ, eds. *Neonatal Haematology*. Cambridge: Cambridge University Press; 2005:310-348.
16. Debus O, Koch HG, Kurlemann G, et al. Factor V Leiden and genetic defects of thrombophilia in childhood porencephaly. *Arch Dis Child Fetal Neonatal Ed*. 1998;78:F121-F124.