

Temporal change of 3-T magnetic resonance imaging/angiography during symptomatic cerebral hyperperfusion following superficial temporal artery–middle cerebral artery anastomosis in a patient with adult-onset moyamoya disease

Misaki Kohama · Miki Fujimura · Shunji Mugikura · Teiji Tominaga

Received: 15 October 2007 / Revised: 7 March 2008 / Accepted: 20 April 2008 / Published online: 12 June 2008
© Springer-Verlag 2008

Abstract Superficial temporal artery–middle cerebral artery (STA–MCA) anastomosis is a safe and effective treatment for moyamoya disease, although recent evidence suggests its substantial risk for symptomatic cerebral hyperperfusion. The diagnostic value of single-photon emission computed tomography (SPECT) for postoperative hyperperfusion in moyamoya patients is well established, but that of magnetic resonance (MR) imaging/angiography is undetermined. A 22-year-old woman with hemorrhagic-onset moyamoya disease underwent STA–MCA anastomosis on the right hemisphere, but she suffered from transient left hemiparesis and facial paresis owing to cerebral hyperperfusion from 3 to 11 days after surgery as delineated by SPECT. The time-sequential 3-T MR angiography revealed intense high signal of donor STA and dilated branches of MCA around the site of the anastomosis. These findings were most prominent at 8 days after surgery, when her neurologic signs were most apparent. Intensive blood pressure control relieved her symptom and she was discharged without neurologic deficit. MR findings normalized 3 months later. The characteristic findings of 3-T MR angiography, which was not evident by 1.5-T MR angiography in the previous studies, may reflect intrinsic pathology of postoperative cerebral hyperperfusion.

It could be a useful diagnostic tool after revascularization surgery for moyamoya disease.

Keywords Moyamoya disease · Cerebral hyperperfusion · Magnetic resonance imaging

Introduction

Moyamoya disease is a chronic, occlusive cerebrovascular disease with unknown etiology characterized by bilateral steno-occlusive changes at the terminal portion of the internal carotid artery and an abnormal vascular network at the base of the brain [13]. Surgical revascularization for moyamoya disease prevents cerebral ischemic attacks by improving cerebral blood flow (CBF), and superficial temporal artery–middle cerebral artery (STA–MCA) anastomosis with or without indirect pial synangiosis is generally employed as the standard surgical treatment for moyamoya disease [2, 7]. Despite its favorable long-term outcome, increasing evidence suggests that direct revascularization surgery for moyamoya disease could result in temporary neurologic deterioration owing to cerebral hyperperfusion at the site of the anastomosis during the acute stage [1–4, 6, 9]. Since the clinical manifestation of cerebral hyperperfusion in patients with moyamoya disease includes transient focal neurologic deficit mimicking cerebral ischemic attack [2, 6], it is clinically important to make accurate diagnosis of symptomatic hyperperfusion and to conduct its adequate management such as intensive blood pressure control for avoiding hemorrhagic complication such as delayed intracerebral hemorrhage [4]. The diagnostic value of N-isopropyl-*p*-[¹²³I] iodoamphetamine single-photon emission computed tomography (¹²³I-IMP-SPECT) for

M. Kohama · M. Fujimura · S. Mugikura · T. Tominaga
Departments of Neurosurgery and Radiology,
Tohoku University Graduate School of Medicine,
Sendai, Japan

M. Fujimura (✉)
Department of Neurosurgery,
Tohoku University Graduate School of Medicine,
Seiryō-machi, Aoba-ku,
Sendai 980-8574, Japan
e-mail: fujimur@nsg.med.tohoku.ac.jp

cerebral hyperperfusion has been reported [2, 3], but SPECT is not available in all institutions or all of the time. Perfusion computed tomography (CT) or magnetic resonance (MR) imaging/angiography could be the alternative method to evaluate postoperative status during the acute stage, while their efficacy for the diagnosis of cerebral hyperperfusion in moyamoya disease is undetermined. In the present study, we conducted time-sequential 3-T MR imaging/angiography examination before and after STA–MCA anastomosis in a patient with adult-onset moyamoya disease, who incidentally suffered from symptomatic hyperperfusion.

Case report

A 22-year-old woman presented with severe headache due to right thalamic hemorrhage and was admitted to another hospital where she was treated conservatively. She experi-

enced repeated numbness in the left upper limb during the past 5 years. She was discharged without neurologic deficit and was introduced to our service. Cerebral angiography delineated steno-occlusive changes at the terminal portions of the bilateral internal carotid arteries and abnormal network-like vessels were apparent at the bilateral basal ganglia, the bilateral orbit. The diagnosis was stage III moyamoya disease according to the criteria of the Research Committee on Spontaneous Occlusion of the Circle of Willis of the Ministry of Health, Labor, and Welfare, Japan [5]. Preoperative ^{123}I -IMP-SPECT showed her bilateral CBF and cerebrovascular reserve capacities were markedly compromised (Fig. 1a). Bilateral bypass surgery was planned and STA–MCA anastomosis with pial synangiosis was performed on the right hemisphere 3 months after the onset of hemorrhage. After exploration of the frontal branch of the right STA, frontotemporoparietal craniotomy was performed. The recipient artery at the M4 segment of the MCA that supply the frontal lobe was explored and

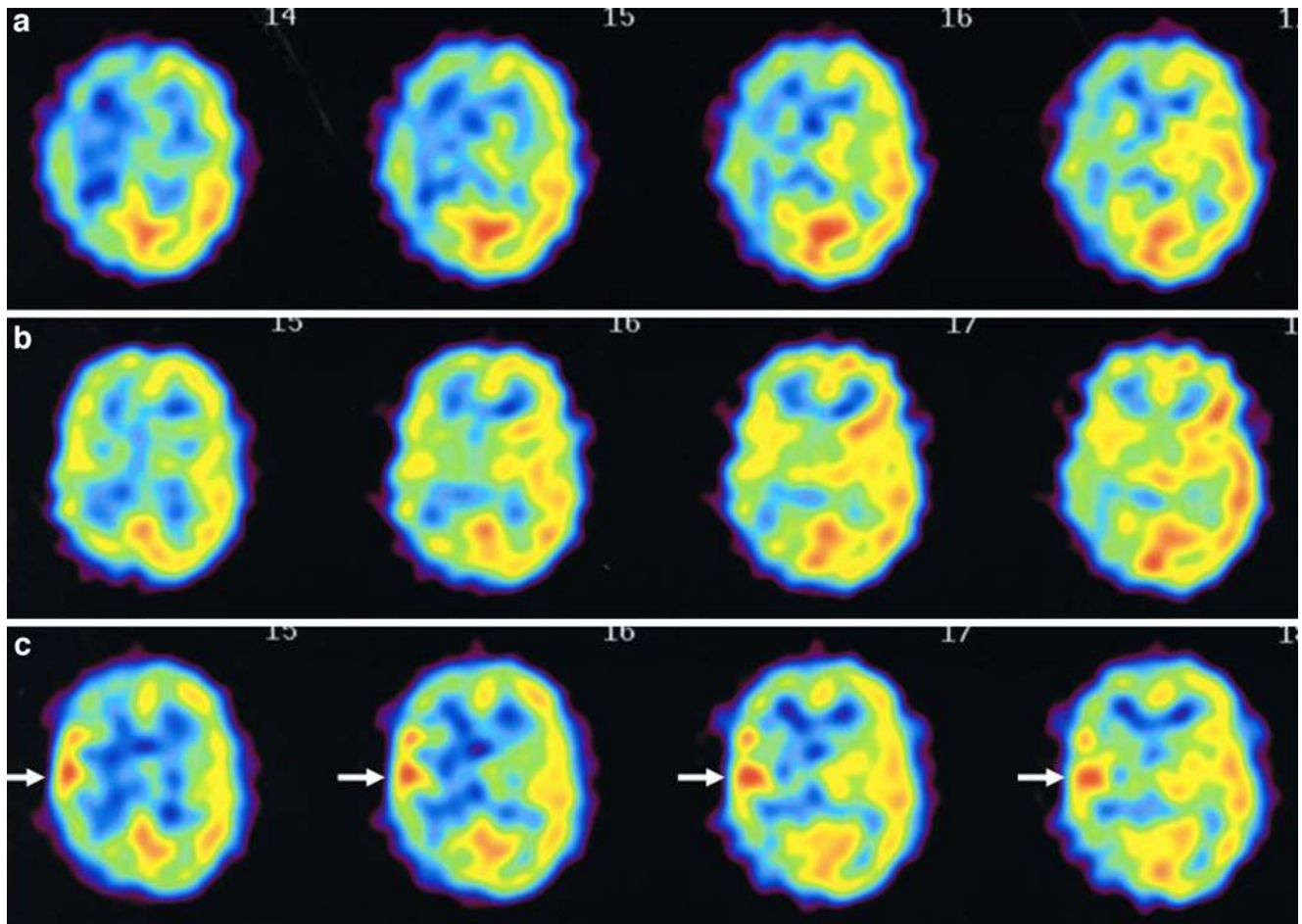


Fig. 1 N-isopropyl- p - ^{123}I iodoamphetamine single-photon emission computed tomography (^{123}I -IMP-SPECT) scans before surgery (**a**) and 1 (**b**) and 7 days (**c**) after surgery. As compared to preoperative finding (**a**), a mild increase in CBF was evident 1 day after surgery (**b**) which preceded the manifestation of transient left hemiparesis at

postoperative day 3. Significant increase in CBF at the site of the anastomosis was evident 7 days after surgery (arrows in **c**), when the patient suffered from severe symptom that resolved 11 days after surgery

anastomosis was performed between the stump of the STA and the M4 segment. Then, encephalo-duro-myosynangiosis (EDMS) and dural pedicle insertion were performed. She showed no neurologic deficit immediately after surgery. The ^{123}I -IMP-SPECT 1 day after surgery (Fig. 1b) showed a slight increase in CBF on the hemisphere operated on compared to the preoperative findings (Fig. 1a). All MR images were performed with 3-T MR unit (Philips Intera Achieva 3.0T Quasar Dual) without the use of contrast material. Postoperative 3-T MR angiography demonstrated the apparently patent STA–MCA bypass (asterisk in Fig. 2b) as thick high signal intensity compared to preoperative finding (Fig. 2a). The dilated branches of MCA supplied by bypass was also demonstrated (arrow in Fig. 2b), which was not seen before surgery (Fig. 2a). One day later, she experienced fluctuating weakness on the left limbs and slight left facial palsy. Emergency computed tomography showed subarachnoid hemorrhage (SAH) around the site of anastomosis, which was not evident 1 day after surgery by CT scan (data not shown). Her symptoms deteriorated from 3 to 8 days after surgery, when ^{123}I -IMP-SPECT showed focal intense increase in CBF at the site of anastomosis (Fig. 1c). The 3-T MR angiography 8 days after surgery demonstrated that the thick high signal of donor STA (asterisk in Fig. 2c) and dilated branches of MCA around the site of the anastomosis (arrow in Fig. 2c) were further prominent, as compared to the previous MR angiography (Fig. 2b) taken during the asymptomatic period. Diffusion-weighted MR imaging showed no evidence of ischemic change, and SAH was shown around the site of the anastomosis by fluid attenuated inversion recovery (FLAIR) (Fig. 3c), which was not evident before surgery (Fig. 3a) and 2 days after surgery

(Fig. 3b). Based on the diagnosis of symptomatic cerebral hyperperfusion, intensive blood pressure control and the use of free radical scavenger relieved her symptoms, which completely disappeared 11 days after surgery. She was discharged without neurologic deficit. Three months later, she underwent left STA–MCA anastomosis with EDMS without complication, when the characteristic findings of MR imaging/angiography on the right hemisphere disappeared (Fig. 3d). She did not experience neurologic deterioration during the follow-up period of 11 months.

Discussion

The present study demonstrated, for the first time, the characteristic pattern of 3-T MR imaging/angiography during symptomatic cerebral hyperperfusion after STA–MCA anastomosis in a patient with moyamoya disease. Cerebrovascular reconstruction surgery including carotid endarterectomy or extracranial–intracranial bypass in patients with atherosclerotic cerebral steno-occlusive diseases can cause a rapid increase in CBF in the chronic ischemic brain, resulting in complications such as ‘cerebral hyperperfusion syndrome’ [10–12, 14]. The preoperative cerebrovascular reactivity and the severity of intraoperative ischemia are known to be the predictive factors for postoperative hyperperfusion syndrome after carotid endarterectomy [8]. Recent evidence suggest that STA–MCA anastomosis for moyamoya disease could also result in symptomatic cerebral hyperperfusion despite its low flow revascularization [2–4, 6, 9]. Our recent study by routine postoperative ^{123}I -IMP-SPECT during the acute stage after

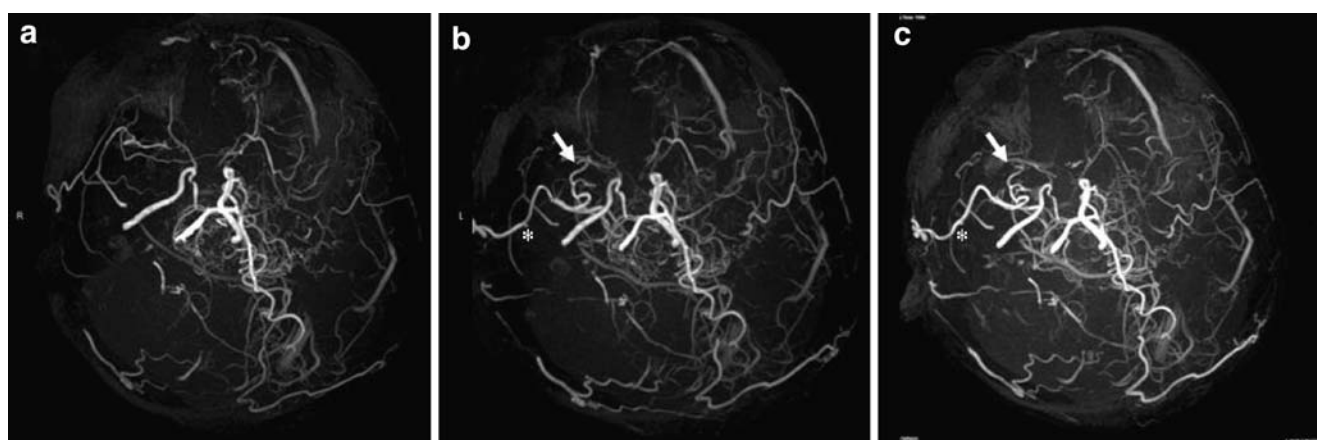
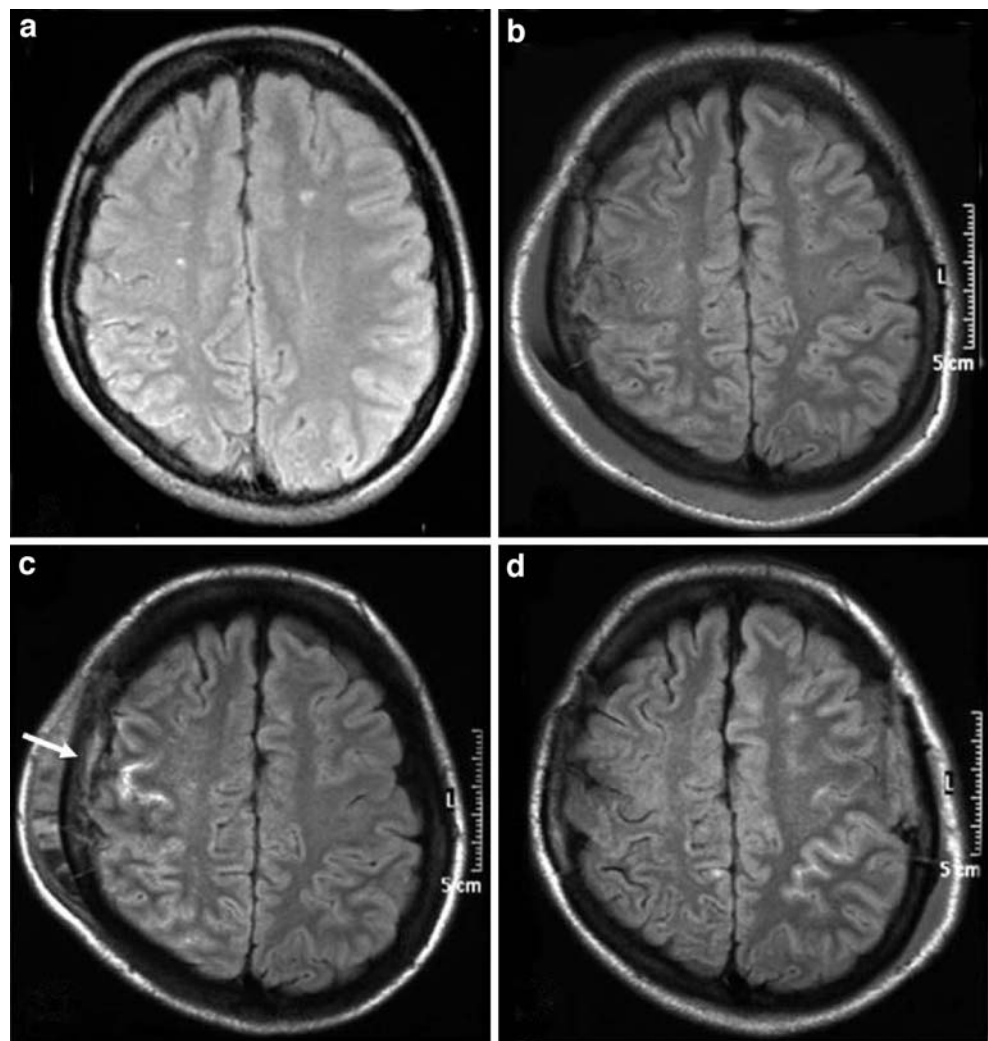


Fig. 2 Temporal changes of 3-T MR angiography (*oblique view*) before (a) and after (b, c) surgery. The MR angiography on admission (a) showed bilateral steno-occlusive changes at the terminal portion of the internal carotid artery and moyamoya vessels at the base of the brain. Two days after surgery, increase in the signal of superficial temporal artery (STA) on the operated hemisphere (asterisk in b), as

well as the appearance of the dilated branches of MCA around the site of anastomosis (arrow in b), was demonstrated. The characteristic findings of thick STA signal (asterisk in c) and dilated branches of MCA supplied by bypass (arrow in c) were furthermore evident 7 days after surgery (arrow in c), when the patient suffered from symptomatic hyperperfusion

Fig. 3 The MR images of FLAIR before surgery (**a**), 1 day (**b**), 7 days (**c**), and 3 months (**d**) after surgery. In accordance with the manifestation of transient hemiparesis from 2 to 11 days after surgery, subarachnoid hemorrhage was evident as the laminar high intensity signal on the right hemisphere at postoperative day 7 (arrow in **c**). Similar sign was evident on the contralateral hemisphere after left STA–MCA anastomosis 3 months later (**d**)



surgery showed that the incidence of symptomatic hyperperfusion is as high as 38.2% in patients with adult-onset moyamoya disease, while the final outcome of these patients was excellent [2]. Nevertheless, we sought to stress that the accurate diagnosis of symptomatic hyperperfusion is clinically important because the management of hyperperfusion is contradictory to that for ischemia [2, 3, 7]. Regarding the diagnostic value of MR imaging/angiography, we have reported that thick high signal of donor STA on the operated hemisphere may be related to the pathology of cerebral hyperperfusion in moyamoya disease using 1.5-T MR imaging/angiography [2, 3], while the exact correlation between this finding and the clinical course was undetermined. In the present case, 3-T MR angiography allowed us not only to detect the thick high signal of STA but also to identify remarkable dilatation of peripheral branches of MCA supplied by donor STA, which was not evident by 1.5-T MR angiography [2–4]. Furthermore, temporal profile of MR angiography findings was completely in accordance with her clinical course. Taken together with the detection of

SAH by FLAIR, these findings may strongly support the diagnosis of cerebral hyperperfusion. In fact ^{123}I -IMP-SPECT showed typical focal intense increase in CBF at the vascular territory supplied by the dilated branches of MCA in accordance with the manifestation of transient hemiparesis.

The exact mechanism by which the MR angiography shows thick high signal of donor STA as well as the dilatation of the branches of MCA is unclear. Since we employ time-on-flight method for MR angiography, both the increase in blood flow speed inside donor STA and the enlargement of the diameter of STA may contribute to these characteristic findings of MR angiography during symptomatic hyperperfusion. Alternatively, in light of the fact that patients with further increase in cerebral blood volume by perfusion-weighted imaging compared to preoperative status could have higher risk for symptomatic hyperperfusion [1], a sudden increase of blood inflow into the vaso-paralytic cortical vessels, which had been exposed under the chronic ischemia for a lengthy period,

may result in transient cerebral hyperperfusion in patients with moyamoya disease. Further evaluation with larger number of patients is necessary to address this important issue.

References

1. Fujimura M, Mugikura S, Shimizu H, Tominaga T (2006) Diagnostic value of perfusion-weighted MRI for postoperative alteration of cerebral hemodynamics following STA–MCA anastomosis in patients with moyamoya disease. *No Shinkei Geka* 34:801–809 (Jpn.)
2. Fujimura M, Kaneta T, Mugikura S, Shimizu H, Tominaga T (2007) Temporary neurologic deterioration due to cerebral hyperperfusion after superficial temporal artery–middle cerebral artery anastomosis in patients with adult-onset moyamoya disease. *Surg Neurol* 67:273–282
3. Fujimura M, Kaneta T, Shimizu H, Tominaga T (2007) Symptomatic hyperperfusion after superficial temporal artery–middle cerebral artery anastomosis in a child with moyamoya disease. *Childs Nerv Syst* 23:1195–1198
4. Fujimura M, Shimizu H, Mugikura S, Tominaga T (2008) Delayed intracerebral hemorrhage after superficial temporal artery–middle cerebral artery anastomosis in a patient with moyamoya disease: possible involvement of cerebral hyperperfusion and increased vascular permeability. *Surg Neurol* [Epub ahead of print]
5. Fukui M (1997) Guidelines for the diagnosis and treatment of spontaneous occlusion of the circle of Willis ('moyamoya' disease). Research Committee on Spontaneous Occlusion of the Circle of Willis (Moyamoya Disease) of the Ministry of Health and Welfare, Japan. *Clin Neurol Neurosurg* 99(Suppl 2):S238–S240
6. Furuya K, Kawahara N, Morita A, Momose T, Aoki S, Kirino T (2004) Focal hyperperfusion after superficial temporal artery–middle cerebral artery anastomosis in a patient with moyamoya disease. Case report. *J Neurosurg* 100:128–132
7. Houkin K, Ishikawa T, Yoshimoto T, Abe H (1997) Direct and indirect revascularization for moyamoya disease: surgical techniques and peri-operative complications. *Clin Neurol Neurosurg* 99 (Suppl 2):S142–S145
8. Komoribayashi N, Ogasawara K, Kobayashi M, Saitoh H, Terasaki K, Inoue T, Ogawa A (2005) Cerebral hyperperfusion after carotid endarterectomy is associated with preoperative hemodynamic impairment and intraoperative cerebral ischemia. *J Cereb Blood Flow Metab* 26:878–884
9. Ogasawara K, Komoribayashi N, Kobayashi M, Fukuda T, Inoue T, Yamada K, Ogawa A (2005) Neural damage caused by cerebral hyperperfusion after arterial bypass surgery in a patient with moyamoya disease: case report. *Neurosurgery* 56:E1380
10. Piepgras DG, Morgan MK, Sundt TM Jr, Yanagihara T, Mussman LM (1988) Intracerebral hemorrhage after carotid endarterectomy. *J Neurosurg* 68:532–536
11. Solomon RA, Loftus CM, Quest DO, Correll JW (1986) Incidence and etiology of intracerebral hemorrhage following carotid endarterectomy. *J Neurosurg* 64:29–34
12. Sundt TM Jr, Sharbrough FW, Piepgras DG, Kearns TP, Messick JM, O'Fallon WM (1981) Correlation of cerebral blood flow and electroencephalographic changes during carotid endarterectomy: with results of surgery and hemodynamics of cerebral ischemia. *Mayo Clin Proc* 56:533–543
13. Suzuki J, Takaku A (1969) Cerebrovascular 'moyamoya' disease. Disease showing abnormal net-like vessels in base of brain. *Arch Neurol* 20:288–299
14. van Mook W, Rennenberg RJ, Schurink GW, van Oostenbrugge RJ, Mess WH, Hofman PA, de Leeuw PW (2005) Cerebral hyperperfusion syndrome. *Lancet Neurol* 4:877–888

Comments

Uwe Spetzger, Karlsruhe, Germany

The present case report details the diagnostic value of 3-T MR imaging and MR angiography (MRA) for the hyperperfusion state after STA–MCA bypass in a moyamoya patient. The authors demonstrate that 3-T MR angiography perfectly visualize moyamoya vessels pre- and postoperatively. However, similar findings have been shown by using 1.5-T MRA in a previous article of the same authors. According to perfusion SPECT studies following revascularization, CBF chronologically increases and usually hyperperfusion develops. SPECT data in the present case clearly correspond with these findings.

The weak point of this paper is that the MRA findings demonstrated are not specific to 3-T MR but can be seen more clearly on 3-T MRI than on 1.5-T MRI. However, the authors can show that 3-T MR angiography demonstrated apparently patent bypass as a higher intensity signal compared to the contralateral STA and that significant visualization of the branches of MCA around the site of anastomosis with 3-T MR angiography was also evident compared to the preoperative state in this patient.

This interesting article is of practical significance and the data presented in the paper are valuable for neurosurgeons dealing with the problem of hyperperfusion following bypass surgery in moyamoya disease.

Masao Sugita and Hiroyuki Kinouchi, Yamanashi, Japan

This report has a potential clinical relevance for moyamoya disease concerning the possibility to detect hyperperfusion syndrome following STA–MCA bypass, which could result in persistent cerebral injury and cognitive impairment, in the same session of routine postoperative magnetic resonance imaging. In addition, not only its feasibility but also this concept has the advantage of its repetitiveness with a less invasive method.

This is the first report to document the chronological changes of the 3-T high resolution time-of-flight (TOF) MR angiography findings together with the conventional CBF study and clinical symptoms of the hyperperfusion status following bypass surgery in moyamoya disease. The authors demonstrated the dilated small cortical vessels using 3-T high resolution image, which were not detected by 1.5-T MR angiography documented in the authors' previous reports, suggesting the superiority of the 3-T MR image to depict enlarged small vessels as a consequence of hyperperfusion.

However, as the authors mentioned in the discussion, the signal intensity of the vessels in TOF MR angiography are regulated by the flow speed and the diameter of the vessels, we should pay attention that the enlarged caliber of the vessels does not always represent increased blood flow. Therefore, further studies should be necessary to establish the correspondence of the thick high signals of MR angiography in donor and recipient vessels with the authentic CBF measurement values.