

---

**BRIEF REPORT****CEREBRAL VASCULOPATHY ASSOCIATED WITH COLLATERALIZATION RESEMBLING MOYA MOYA PHENOMENON AND WITH ANTI-Ro/SS-A AND ANTI-La/SS-B ANTIBODIES**

THOMAS T. PROVOST, HOWARD MOSES, EDWARD L. MORRIS, JEREMY ALTMAN, JOHN B. HARLEY, ELAINE ALEXANDER, and MORRIS REICHLIN

**We describe a 48-year-old, previously healthy, anti-Ro/SS-A and anti-La/SS-B antibody positive black woman with negative risk factors for atherosclerosis, who developed mental status and personality changes over a 6–12-month period, and progressive cortical blindness over a 2-week period. Angiographic and computed axial tomographic studies of the brain demonstrated multiple large areas of infarction correlating with stenosis and occlusions of the internal carotid and posterior cerebral arteries. Moya moya–like findings were prominent radiographically. Results of angiographic, computed tomographic, and magnetic resonance imaging studies were interpreted as being compatible with large, medium, and small vessel disease, most likely a vasculitis.**

From the Department of Dermatology, the Department of Neurology, and the Division of Rheumatology, Department of Medicine, The Johns Hopkins University School of Medicine, the Department of Radiology and the Department of Medicine, The Greater Baltimore Medical Center, Baltimore, Maryland, and the Division of Rheumatology, Department of Medicine, The University of Oklahoma, Oklahoma City.

Supported by US Public Health Service NIH grants RO1 AM-25650, AM-32233, A0-970101, A0-991905, AI-21568, and HL-34723, a gift from the Noxell Corporation, a gift from the O'Neill Fund at The Good Samaritan Hospital, and a grant from the Kroc Foundation.

Thomas T. Provost, MD: The Johns Hopkins School of Medicine; Howard Moses, MD: The Johns Hopkins School of Medicine; Edward L. Morris, MD: The Greater Baltimore Medical Center; Jeremy Altman, MD: The Greater Baltimore Medical Center; John B. Harley, MD, PhD: The University of Oklahoma; Elaine Alexander, MD, PhD: The Johns Hopkins University School of Medicine; Morris Reichlin, MD: The University of Oklahoma.

Address reprint requests to Thomas T. Provost, MD, The Johns Hopkins University School of Medicine, Department of Dermatology, Blalock 920, 600 North Wolfe Street, Baltimore, MD 21205.

Submitted for publication August 10, 1990; accepted in revised form February 21, 1991.

Isolated central nervous system vasculitis is an uncommon entity characterized by vasculitis restricted to the vessels of the central nervous system; the condition is often fatal (1,2). The most common symptoms and signs of isolated intracerebral vascular disease include severe headache, altered higher cortical function (i.e., memory defects or cognitive dysfunction), and focal neurologic deficits. Systemic signs and symptoms (i.e., arthritis, arthralgia, and myalgias) occur in fewer than 20% of the reported cases. Moya moya (meaning smoke) phenomenon, initially described in Japanese patients, is a distinct central nervous system radiographic finding characterized by large vessel disease at the base of the brain, resulting in establishment of extensive collateral circulation in the vascular compromised area (3,4).

We report a case of diffuse cerebral vasculopathy (thought to be vasculitis) associated with the moya moya radiologic phenomenon and the presence of anti-Ro/SS-A antibodies in the cerebrospinal fluid (CSF) and serum. There was no clinical evidence of systemic lupus erythematosus (SLE) or Sjögren's syndrome (SS) detected in this patient.

**CASE REPORT**

**Clinical findings.** The patient was a 48-year-old black woman with a 6–12-month history of change in mental status. Two weeks before presenting to us, she had been evaluated by her physician for systemic disease and had been noted to have a positive result on a lupus erythematosus preparation (LE prep; performed in a commercial laboratory). The patient's family history was significant in that her sister was diagnosed as having a mixed connective tissue disease

**Table 1.** Results of cerebrospinal fluid (CSF) studies

IgG index (normal $\leq 0.7$ )*	0.7
CSF protein (mg/dl; normal $< 45$ )	55
CSF IgG (mg/dl; normal $> 6$ )	3.1
Oligoclonal bands (normal 0)	0
Ro/SS-A (units)†	$2.4 \times 10^4$
La/SS-B†	Undetectable
Antipertussis concentration (serum:CSF ratio)†	120:1
Anti-Ro/SS-A concentration (serum:CSF ratio)†	67:1

\* See ref. 5.

† By enzyme-linked immunosorbent assay.

syndrome, with high-titer antinuclear antibodies (ANA; titer 1:2,560) and RNase-sensitive extractable nuclear antigen antibodies (nuclear RNP [nRNP; U1 RNP] titer 1:500,000).

Physical examination revealed the patient to be demented and psychotic. She had bare light perception with bilateral homonymous hemianopias. The remainder of the physical examination findings, with the exception of left facial weakness, were essentially normal.

The complete blood cell count, differential cell count, and urinalysis results were within normal limits. The erythrocyte sedimentation rate was 46 mm/hour. A VDRL result was negative. Lumbar puncture revealed 1 white blood cell and 2 red blood cells/mm<sup>3</sup>. Findings on cytologic analysis of the CSF were negative, and cryptococcal antigen was not detected. The CSF glucose level was normal. The protein concentration was mildly elevated at 55 mg/dl. The CSF IgG index (5) was 0.7. No oligoclonal bands were detected. These findings are summarized in Table 1.

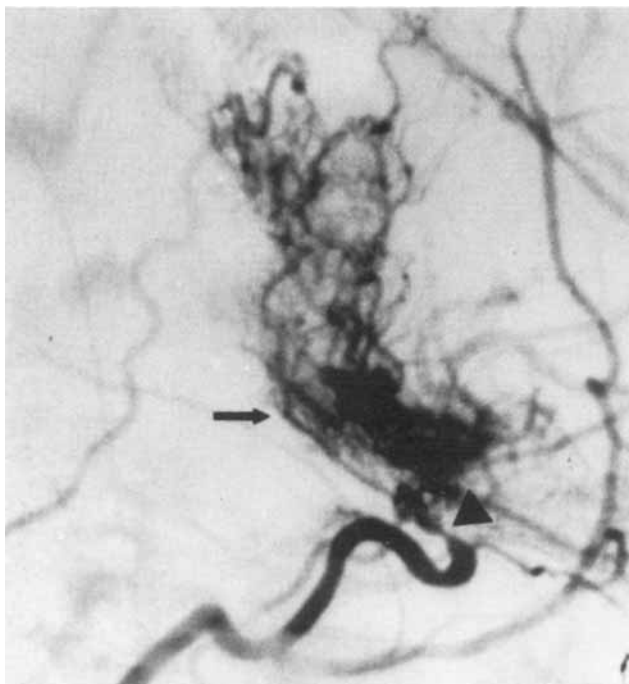
An enhanced computed tomography (CT) scan of the brain demonstrated an old left occipital lobe infarct, a recent enhancing infarct of the right occipital lobe, and infarction in the right temporal lobe of undetermined duration. Cerebral angiography showed sharply demarcated, nearly occlusive narrowings of the supraclinoid segments of both internal carotid arteries. Prominent lenticulostriate artery collaterals were present in the basal ganglia on the right side, resembling the moya moya phenomenon (Figure 1). Right vertebral angiography demonstrated segmental narrowings in both posterior cerebral arteries. More extensive filling of the collaterals in the posterior basal ganglia and pericollousal region occurred during this angiographic sequence.

Magnetic resonance imaging (MRI) of the brain showed multiple areas of abnormal signal intensity in the deep cerebral white matter, the periventricular

zones, the brain stem, and the cerebellar hemispheres. The angiographic, CT scan, and MRI findings were interpreted as demonstrating a diffuse cerebral vasculopathy involving small, medium, and large vessels, most consistent with a diffuse vasculitis.

Results of an echocardiogram, electrocardiogram, and Holter monitoring were normal. No evidence of SLE was detected. All mucous membranes were moist, and serial sectioning of a lip biopsy specimen failed to reveal evidence of inflammation of minor salivary glands.

The patient was treated with pulse methylprednisolone (1 gm infused over a 4-hour period, on 3 consecutive days). However, she remained psychotic, demented, and blind. She was discharged to a nursing home, on a regimen of prednisone (100 mg/day) and later cyclophosphamide (50 mg twice a day). Her clinical condition remained essentially unchanged over the next 18 months. Two years after the onset of her central nervous system disease, the patient developed convulsions and was admitted to another hospital, where she died suddenly. An autopsy was not performed.



**Figure 1.** Angiogram of the patient's right common carotid artery (lateral cranial view). The supraclinoid segment of the internal carotid is severely narrowed (arrowhead). Extensive collaterals are present in the basal ganglia (arrow). Branches of the anterior cerebral artery are faintly seen.

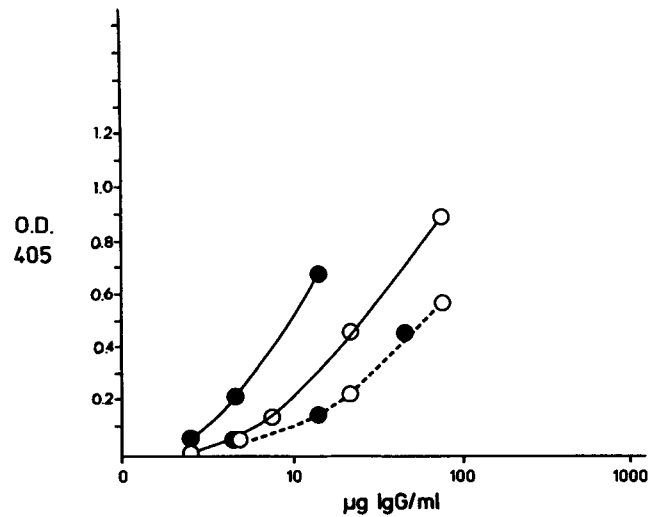
**Serologic and CSF studies.** The patient's serum was examined for antinuclear, histone, Sm, U1 RNP, Ro/SS-A, La/SS-B, and antiribosomal P antibodies, using immunofluorescence, precipitin, immunoblot, and enzyme-linked immunosorbent assay (ELISA) techniques (6-8). Serum immune complexes were assayed with a solid-phase anti-C3 immune complex assay, and anticardiolipin antibodies were assayed using a modification (5,9) of an ELISA described by Lockshin et al (10).

IgG was quantitated, in both the serum and the CSF, by sandwich ELISA using affinity-purified goat anti-human IgG (2.0  $\mu\text{g/ml}$ ) to coat the plates. Standard curves were constructed with Cohn fraction II as a source of IgG. Antiimmunoglobulin alkaline phosphatase conjugation and spectrophotometric evaluation of the plates were carried out as previously described (9). An ELISA for antibody to pertussis was performed with commercial *Bordetella pertussis*-killed organisms (Calbiochem, La Jolla, California) as coating antigen, at a concentration of  $2.5 \times 10^9$  organisms per milliliter of fluid.

Cerebrospinal fluid analysis included isoelectric focusing and determination of the IgG index (5). Serum and CSF anti-Ro/SS-A and anti-La/SS-B antibodies were quantitated in an ELISA (6). The ratio of the quantity of serum antibody:CSF antibody was then determined, as an indicator of the integrity of the blood-brain barrier.

**Serologic and CSF results.** ANA Antinuclear antibodies were detected at a titer of 1:160 with a speckled pattern. No cytoplasmic staining was detected. No antibodies to histone, Sm, nRNP (U1 RNP), native DNA, or cardiolipin were detected. No antiribosomal P antibodies were detected by gel double diffusion utilizing purified rat ribosomes, by ELISA using the C-terminal-reactive peptide of ribosomal P conjugated to bovine serum albumin, by ELISA utilizing rat purified ribosomes, or by Western blot analysis. Rheumatoid factor was present at a titer of 1:80. No circulating immune complexes were detected.

Anti-Ro/SS-A and anti-La/SS-B autoantibodies were identified in the patient's serum, by gel double diffusion. The anti-Ro/SS-A level (by ELISA) was  $3.8 \times 10^6$  units (normal  $\leq 1 \times 10^4$ ), and the anti-La/SS-B level was  $2 \times 10^4$  units (normal  $\leq 1 \times 10^3$ ). The anti-Ro/SS-A findings, as well as antipertussis activity (also quantitated by ELISA), are depicted in Figure 2, in which absorbance at 405 nm is plotted against the IgG concentration of the serum and CSF. As is seen in



**Figure 2.** Anti-Ro/SS-A and antipertussis activity in the patient's serum ( $\circ$ ) and cerebrospinal fluid ( $\bullet$ ). Optical density (O.D.; absorbance at 405 nm) is plotted as a function of IgG concentration. Color values were generated on bovine Ro/SS-A-coated plates ( $\text{---}$ ) and pertussis-coated plates ( $\text{-----}$ ).

the figure, the serum and CSF antipertussis values fell on the same curve, whereas the CSF had about twice as much anti-Ro/SS-A activity per unit of IgG as did the serum. The fact that the antipertussis activity per unit of IgG was the same in the serum and the CSF suggested enrichment of anti-Ro/SS-A antibodies in the CSF relative to the serum. Preincubation of the serum with 10  $\mu\text{g}$  of purified Ro/SS-A and La/SS-B inhibited the Ro/SS-A and La/SS-B antibody responses, by 90% and 60%, respectively.

## DISCUSSION

Multiple isolated cerebrovascular insults were demonstrated to have occurred in this relatively young woman, without clinical evidence of connective tissue disease or cutaneous vasculitis. Despite the negative clinical findings, the patient's family history of a sister with a mixed connective tissue disease, the presence of a significant ANA titer, a history of a positive LE prep result, and the presence of Ro/SS-A and La/SS-B antibodies suggest the occurrence of a subclinical connective tissue disease process.

The serologic findings in this patient were unique in that she was positive for anti-Ro/SS-A and anti-La/SS-B antibodies. We know of no other reported case of a patient with a similar diffuse cerebral vascular disease or isolated cerebral vasculitis in whom these autoantibodies were present.

The interpretation of the elevated level of Ro/

SS-A antibody in the patient's CSF is complex. There are 3 possible factors that could contribute to the CSF Ro/SS-A antibody concentration: passive transfer of the Ro/SS-A antibody from the serum into the central nervous system, local synthesis of the Ro/SS-A antibody in the central nervous system, or specific depletion of the Ro/SS-A antibody by binding to the Ro/SS-A autoantigen in the brain. Whether the approximately 2-fold enhanced concentration of Ro/SS-A antibody in the patient's CSF versus her serum was significant, suggesting intrathecal synthesis, is unknown at the present time.

During the course of our studies on SLE and SS patients who are positive for anti-Ro/SS-A, we have seen, in addition to the patient described here, 3 anti-Ro/SS-A antibody positive patients who have developed vasculitis involving medium-to-large-sized arteries. In only 1 of these cases, however, was there histologic confirmation of the vasculitis (11). In 1 SS patient, the vasculitis involved the anterior spinal artery and resulted in a fatal subarachnoid hemorrhage (11). Another patient, who had both SLE and SS, developed Takayasu arteritis. The third patient, who had SLE, developed bilateral cerebellar infarcts.

It appears that the patient described herein had a diffuse cerebral vasculitis. It is possible that other cases of isolated cerebral vasculitis in association with the presence of the Ro/SS-A antibody will be identified.

#### REFERENCES

1. Cupps TR, Moore PM, Fauci AS: Isolated angiitis of the central nervous system: prospective diagnostic and therapeutic experience. *Am J Med* 74:97-105, 1983
2. Moore P: Diagnosis and management of isolated angiitis of the central nervous system. *Neurology* 39:167-173, 1989
3. Kudo T: Spontaneous occlusion of the circle of Willis: a disease apparently confined to Japanese. *Neurology* 18:485-496, 1968
4. Kendall R: Cerebral angiography in vasculitis affecting the nervous system. *Eur Neurol* 23:400-406, 1984
5. Alexander EL, Lijewski JE, Jerdan MS, Alexander GE: Evidence of an immunopathogenic basis for central nervous system disease in primary Sjögren's syndrome. *Arthritis Rheum* 29:1223-1231, 1986
6. Harley JB, Alexander EL, Bias WB, Fox OF, Provost TT, Reichlin M, Yamagata H, Arnett FC: Anti-Ro (SS-A) and anti-La (SS-B) in patients with Sjögren's syndrome. *Arthritis Rheum* 29:196-206, 1986
7. Provost TT, Talal N, Harley J, Reichlin M, Alexander E: The relationship between anti-Ro(SS-A) antibody positive Sjögren's syndrome and anti-Ro(SS-A) antibody positive lupus erythematosus. *Arch Dermatol* 124:63-71, 1988
8. Francouer AM, Peebles CL, Heckman KJ, Lee TC, Tan EM: Identification of ribosomal protein autoantigens. *J Immunol* 135:2378-2384, 1985
9. Provost TT, Watson RM, Gaither KK, Harley JB: The neonatal lupus erythematosus syndrome. *J Rheumatol* 14:199-205, 1987
10. Lockshin MD, Druzin ML, Goli S, Qamar T, Magid MS, Jovanovic L, Ferenc M: Antibody to cardiolipin as a predictor of fetal distress or death in pregnant patients with systemic lupus erythematosus. *N Engl J Med* 313:152-156, 1985
11. Alexander EL, Craft C, Provost TT, Dorsch C, Moser R, Alexander GE: Necrotizing arteritis and spinal subarachnoid hemorrhage in Sjögren's syndrome. *Ann Neurol* 11:632-635, 1982