

# Acute Cerebral Paragonimiasis Presenting as Hemorrhagic Stroke in a Child

Zhi Chen, MD, Gang Zhu, MD, PhD,  
Jiangkai Lin, MD, PhD,  
Nan Wu, MD, and Hua Feng, MD, PhD

A hemorrhagic stroke in children is rarely secondary to cerebral paragonimiasis. We describe a 9-year-old boy in whom an intracerebral hemorrhage was the leading clinical indication of acute cerebral paragonimiasis. He was hospitalized because of a sudden onset of headache, right hemiparesis, and dysarthria. A computed tomography scan revealed an intracerebral hemorrhage in the left parietal lobe. Magnetic resonance angiography did not confirm any vascular abnormalities at the location of the hematoma. Four weeks later, he presented with right hemiparesis again, and fever. A diagnosis of cerebral paragonimiasis was based on repeated magnetic resonance imaging of the brain and an enzyme-linked immunosorbent assay for paragonimiasis. The patient gradually recovered with praziquantel treatment. Cerebral paragonimiasis should be considered in the differential diagnosis of hemorrhagic strokes in children in areas where paragonimiasis is epidemic. © 2008 by Elsevier Inc. All rights reserved.

Chen Z, Zhu G, Lin J, Wu N, Feng H. Acute cerebral paragonimiasis presenting as hemorrhagic stroke in a child. *Pediatr Neurol* 2008;39:133-136.

## Introduction

Paragonimiasis is a parasitic disease caused by the genus *Paragonimus*. As a typical foodborne parasitic zoonosis, this disease is prevalent in Asia, West Africa, and Latin America [1,2]. In addition, paragonimiasis was also described among immigrants in the United States [1,3] and Australia [4]. Human infection is mainly spread by eating raw or inadequately cooked crabs or crayfish, which are the second intermediate hosts for the organism during its transition from cercaria to metacercaria. The lung is the principal habitat in the human host. The encysted metacercariae penetrate the gut wall and migrate to the lung, where they mature into adult worms and produce eggs. The eggs are discharged from bronchial secretions, and are coughed up or passed in feces. These then hatch and pass through a suitable snail host (first intermediate host) before encysting in the tissues of a freshwater crustacean (crabs or crayfish) to repeat the life cycle [1,3,5].

Cerebral paragonimiasis is probably caused by the migration of worms from the lungs through the soft tissues of the neck to the jugular foramen and to the brain [5]. The reported frequency of cerebral involvement varies between 0.8-45% [5,6]. Cerebral paragonimiasis with hemorrhagic stroke is rarely reported [2,7,8], but its incidence may be underestimated. We describe an unusual pediatric case presenting clinically and radiologically with acute intracerebral hemorrhage. He was diagnosed with cerebral paragonimiasis 1 month after onset of the hemorrhage.

## Case Report

This 9-year-old, previously healthy boy presented with sudden onset of headache associated with nausea and vomiting after getting up in the morning. He soon developed right hemiparesis and dysarthria. He was sent to a nearby hospital. A computed tomography scan (Fig 1) was performed the next day, and revealed an acute intracerebral hematoma in the left parietal lobe. The patient was transferred to our hospital on day 3 of his previous admission. A neurologic examination revealed dysarthria and right hemiparesis (grade II in his upper limb, and grade IV in his lower limb), with moderate ipsilateral hyperreflexia. No meningeal signs were found. Chest x-ray films produced normal results. Routine laboratory findings such as a complete blood count, erythrocyte sedimentation rate, urinalysis, and stool examination produced normal results, except for low blood sodium (130 mmol/L). Magnetic resonance findings of the brain were consistent with the computed tomography scan, and were suggestive of an acute intracerebral hemorrhage. There

From the Department of Neurosurgery, Southwest Hospital, Third Military Medical University, Chongqing, China.

Communications should be addressed to:  
Dr. Feng; Department of Neurosurgery, Southwest Hospital; Third Military Medical University; Gaotanyan Street; Shapingba District; Chongqing 400038, People's Republic of China.

E-mail: a65427851@cta.cq.cn

Received January 24, 2008; accepted April 7, 2008.

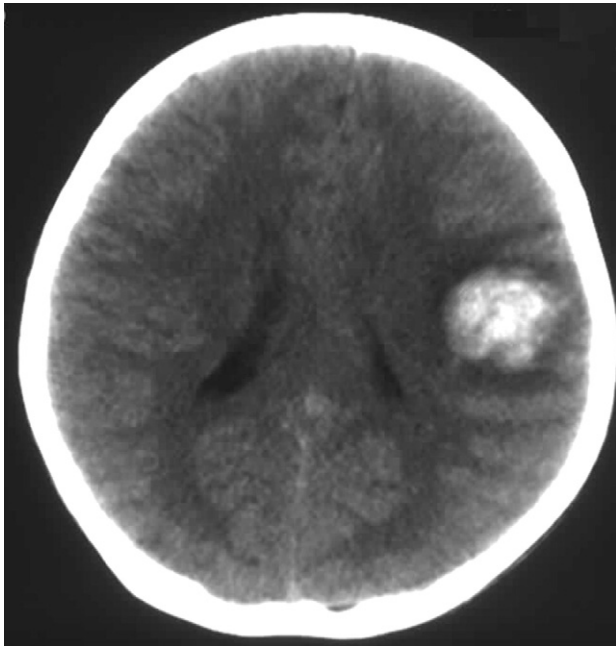


Figure 1. Axial computed tomography scan reveals an acute cerebral hemorrhage in the parietal lobe.

was no other enhancement on the postcontrast magnetic resonance images (Fig 2), and no obvious vascular abnormality on magnetic resonance angiography. Conventional angiography was suggested, but was not accepted by his family. The patient was treated without surgery, and his dysarthria and right hemiparesis improved.

One month later, the patient developed a cough, chill, and fever, as well as a recurrence of right hemiparesis. A neurologic examination revealed mild hemiparesis in his right upper limb (grade III). Follow-up magnetic resonance imaging of the brain revealed multiple newly developed lesions located medially to the partly absorbed hematoma. These lesions proved to be hyperintense on a T<sub>2</sub>-weighted image, with a slightly hyperintense wall on a T<sub>1</sub>-weighted image. Postcontrast magnetic resonance images (Fig 3) revealed clustered ring-enhancing lesions and an enhancement of meninges beside the lesions and the previous hematoma, resembling the characteristic appearance of cerebral paragonimiasis. His total white blood cell count consisted of  $13.5 \times 10^9$  cells/L, and an absolute count of his eosinophils consisted of  $0.5 \times 10^9$  cells/L, which increased 3 days later to  $3 \times 10^9$  cells/L. A computed tomography scan of the chest revealed patchy opacity in the right lower lung zone, combined with pleural effusion. His dietary history was retaken, and it disclosed that he and his classmates had eaten raw crabs that they had caught in the rural creeks, without adult supervision. Enzyme-linked immunosorbent assays for multiple parasites were performed on his serum, which was positive for *P. skrjabini* specific immunoglobulin G antibody and negative for others. When the diagnosis of cerebral paragonimiasis was established, therapy with praziquantel was initiated. The patient was treated with praziquantel at a dose of 75 mg/kg/day for 3 days, and with another course of praziquantel at the same dosage 1 week after the first course. His hemiparesis improved rapidly, without any other signs. His eosinophil count decreased to  $1.38 \times 10^9$  cells/L 4 days after treatment, and reached a normal level 2 weeks later. A follow-up computed tomography scan of his chest indicated that the lesions had mostly diminished. The patient was discharged and remained neurologically normal during a follow-up period of 3 months, during which time he refused serial brain magnetic resonance imaging.

## Discussion

Among *Paragonimus* species, *Paragonimus westermani*, followed by *P. skrjabini* complex, are the major pathogens for human paragonimiasis in Asia [1]. Our patient came from Sichuan Province, where the main identified worms were *P. skrjabini*, according to the literature [9,10]. Therefore, we presumed that his infection was probably attributable to *P. skrjabini*, though no definite eggs or adult parasites were demonstrated.

Cerebral signs rarely occur without evidence of chest disease. In the majority of cases (70%), pulmonary signs occur first [11]. Various nonspecific neurologic manifestations may develop in patients with cerebral paragonimiasis, including epilepsy, headache, nausea, vomiting, hemiplegia, and aphasia [5,11]. The radiologic findings of cerebral paragonimiasis are variable, depending on the evolutionary stage of the cerebral infection. In the acute stage, the most common and characteristic computed tomography or magnetic resonance imaging findings are conglomerate, multiple, ring-shaped enhancements with surrounding edema of variable degree, resembling "grape clusters." Nonspecific features of computed tomography and magnetic resonance imaging include nonenhancing, edema-like lesions, parenchymal hemorrhage, and irregularly enhancing solid lesions [2,11-13]. Pure or massive hemorrhagic lesions are rarely reported [2,7,11-13]. The enzyme-linked immunosorbent assay has proven to be efficiently sensitive and specific for detecting pulmonary and extrapulmonary paragonimiasis [3,11].

Cerebral paragonimiasis presenting as an intracranial hemorrhage is rarely reported, especially without pulmo-

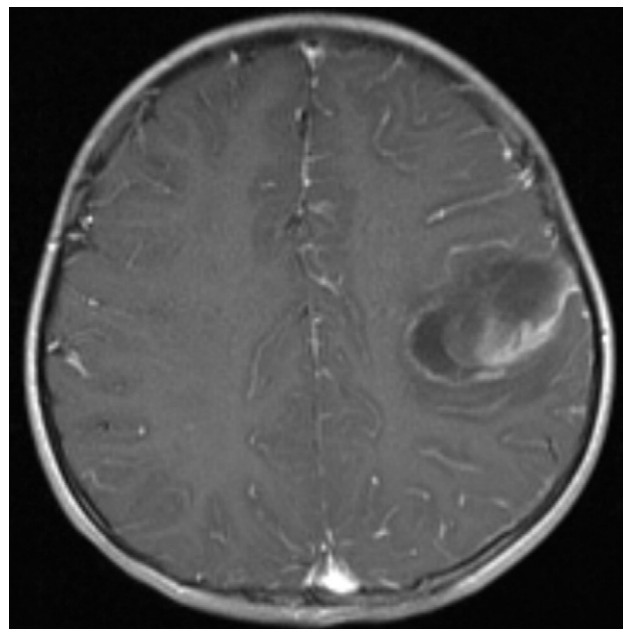
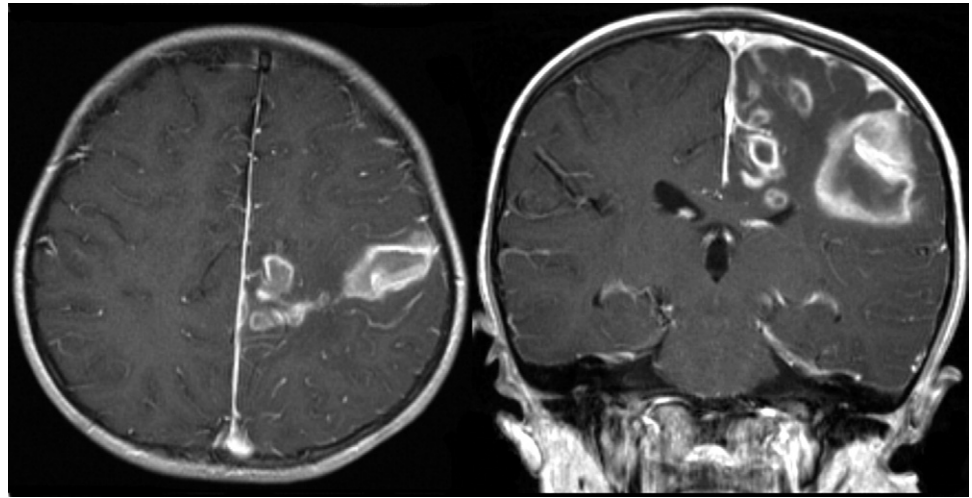


Figure 2. Initial magnetic resonance findings. Postcontrast axial T<sub>1</sub>-weighted image (TR/TE = 500/7 ms) indicates the acute hematoma, without other abnormalities.

Figure 3. Follow-up magnetic resonance imaging 1 month later. A postcontrast coronal and axial T<sub>1</sub>-weighted image (TR/TE = 500/7 ms) reveals multiple, coalesced, ring-enhancing lesions with an obvious enhancement of meninges beside the lesions and the hematoma.



nary signs. In this circumstance, the diagnosis may be mistaken or delayed. Hara et al. [7] reported on a 38-year-old man with sudden-onset headache and visual disturbance, who was diagnosed with intracerebral hemorrhage during his first admission. A diagnosis of cerebral paragonimiasis was not considered until 3 months later, when respiratory signs developed. In the present case, the intracerebral hemorrhage was also the initial finding. More unusual, characteristic radiologic findings of coalesced, ring-enhancing lesions developed near the follow-up magnetic resonance imaging. To the best of our knowledge, a childhood case of cerebral paragonimiasis with an intracerebral hemorrhage as the initial finding has not been reported.

In the reported cases of cerebral paragonimiasis combined with intracranial hemorrhage, the types of intracranial hemorrhage included intracerebral hemorrhage, subdural hematoma, and subarachnoid hemorrhage [2,7,8,13,14]. Though the hemorrhage in most reported cases was attributed to cerebral paragonimiasis, the causality between cerebral paragonimiasis and intracranial hemorrhage should be considered. Choo et al [8] reported on a 38-year-old man with chronic cerebral paragonimiasis combined with a diffuse subarachnoid hemorrhage, whose subarachnoid hemorrhage was thought to be secondary to a carotid posterior communicating-artery aneurysm. In childhood, an intracerebral hemorrhage is most often the result of an arteriovenous malformation, hematologic abnormality, or brain tumor; among these causes, arteriovenous malformations account for nearly 50% of intraparenchymal hemorrhages [15]. Other etiologies include cavernous hemangioma, vasculopathy, vasculitis, and rarely, infections and illicit drug use [15]. Our patient had no history of illicit drug use, and no signs of vascular abnormalities, brain tumor, or hematologic abnormalities according to repeated magnetic resonance imaging, magnetic resonance angiography, and laboratory examinations. Taken together with the lesions of cerebral paragonimiasis that developed closely around the hema-

toma, we think that the intracerebral hemorrhage was attributable to paragonimiasis infection. Surgical treatment is not always necessary for the management of cerebral paragonimiasis, whereas praziquantel is the drug of choice for the treatment of paragonimiasis, and is virtually 100% effective against all species of *Paragonimus* [3,11]. Therefore, diagnosis at an early stage is regarded as important in such cases.

In conclusion, our patient serves as a rare pediatric case of cerebral paragonimiasis presenting clinically and radiologically as an intracerebral hemorrhage, which made the early diagnosis difficult. Our case suggests that cerebral paragonimiasis should be considered in the differential diagnosis of hemorrhagic stroke in children in areas where paragonimiasis is epidemic.

#### References

- [1] Blair D, Xu ZB, Agatsuma T. Paragonimiasis and the genus *Paragonimus*. *Adv Parasitol* 1999;42:113-22.
- [2] Cha SH, Chang KH, Cho SY, et al. Cerebral paragonimiasis in early active stage: CT and MR features. *AJR* 1994;162:141-5.
- [3] Kagawa FT. Pulmonary paragonimiasis. *Semin Respir Infect* 1997;12:149-58.
- [4] Mukerjee CM, Simpson SE, Bell RJ, Walker JC. Pleuropulmonary paragonimiasis in a Laotian immigrant to Australia. *Chest* 1992;101:849-51.
- [5] Kusner DJ, King CH. Cerebral paragonimiasis. *Semin Neurol* 1993;13:201-8.
- [6] Oh SJ. The rate of cerebral involvement in paragonimiasis: An epidemiologic study. *Jpn J Parasitol* 1969;18:211-4.
- [7] Hara K, Yamasaki M, Okuda B, Maya K, Imai T. A case of cerebral paragonimiasis with intracerebral hemorrhage as initial finding. *Rinsho Shinkeigaku* 1985;25:808-11.
- [8] Choo JD, Suh BS, Lee HS, et al. Chronic cerebral paragonimiasis combined with aneurysmal subarachnoid hemorrhage. *Am J Trop Med Hyg* 2003;69:466-9.
- [9] Blair D, Chang Z, Chen M, et al. *Paragonimus skrjabini* Chen, 1959 (Digenea: Paragonimidae) and related species in eastern Asia: A combined molecular and morphological approach to identification and taxonomy. *Syst Parasitol* 2005;60:1-21.

[10] **Chen** MG, Chang ZS, Cui AL, et al. DNA sequences of *Paragonimus skrjabini* populations from five provinces in China. *Chin Med J [Engl]* 2004;117:219-24.

[11] **Im** JG, Chang KH, Reeder MM. Current diagnostic imaging of pulmonary and cerebral paragonimiasis, with pathological correlation. *Semin Roentgenol* 1997;32:301-24.

[12] **Hourani** RG, Tamraz JC. Imaging of parasitic diseases of the central nervous system. In: Haddad MC, Tamraz JC, Abd El, Bagi ME, eds. *Imaging of parasitic diseases*, 1st ed. Berlin: Springer, 2007:7-31.

[13] **Zhang** JS, Huan Y, Sun LJ, Zhang GY, Ge YL, Zhao HT. MRI features of pediatric cerebral paragonimiasis in the active stage. *J Magn Reson Imag* 2006;23:569-73.

[14] **Brenes Madrigal** R, Rodriguez-Ortiz B, Vargas Solano G, Ocamp Obando EM, Ruiz Sotela PJ. Cerebral hemorrhagic lesions produced by *Paragonimus mexicanus*. Report of three cases in Costa Rica. *Am J Trop Med Hyg* 1982;31:522-6.

[15] **Jordan** LC, Hillis AE. Hemorrhagic stroke in children. *Pediatr Neurol* 2007;36:73-80.