

SHORT REPORT

Vein of Galen malformation presenting in adulthood

S. MUQUIT, M. SHAH & S. BASSI

Department of Neurosurgery, King's College Hospital, London, UK

Abstract

Vein of Galen malformations are rare vascular abnormalities, which develop during gestation and usually present in the neonatal period or early childhood. Symptoms are due to high output cardiac failure, hydrocephalus, seizures or haemorrhage. We report a case where a patient remained symptom free until presentation following a haemorrhage at the age of 47 years.

Case details

A 47-year-old man was found collapsed in the driver's seat of a car that was parked on the side of the road. He had not been involved in a road traffic accident and there were no signs of physical injury. There was no significant past medical history and there had been no previous symptoms attributable to an intracranial lesion.

Glasgow Coma Score on arrival to hospital was 14/15 (E4 V4 M6). Cardiovascular examination was normal and neurological examination revealed a mild right hemiparesis.

ECG showed normal sinus rhythm and axis, and chest radiograph showed normal cardiothoracic ratio and lungs.

Non-contrast CT head scan revealed a well circumscribed calcified lesion in the region of the splenium of the corpus callosum, suggestive of an aneurysm in this region (Fig. 1). There was dilatation of the third and lateral ventricles with a normal-sized fourth ventricle. Increased density was seen in the region of the Sylvian fissures and in the left temporal region, consistent with the presence of subarachnoid blood.

MR angiogram confirmed an aneurysm of the vein of Galen (Fig. 2), measuring approximately 4 cm in diameter. The feeding vessel seemed to be the posterior cerebral artery. The veins draining the malformation were not clearly identified. However, the superior middle cerebral vein, the vein of Labbe, as well as the basal vein of Rosenthal were prominent and dilated, as were the superficial cortical veins on both sides.

A ventriculoperitoneal shunt was inserted before proceeding to endovascular embolization of the arteriovenous malformation (AVM). This was tolerated well and the patient was subsequently discharged from hospital to a regional rehabilitation centre. At the time of discharge, GCS was 15/15 and power on the right was still 3/5. He is due for follow-up in neurosurgical outpatient clinic with a repeat angiogram.

Discussion

The vein of Galen, which is located under the cerebral hemispheres, drains the anterior and central regions of the brain into the sinuses of the posterior cranial fossa. Vein of Galen malformations (VGAM) result from an aneurysmal malformation, with an arteriovenous shunting of blood. Development of this aneurysm occurs between the 6th and 11th weeks of gestation as a persistent embryonic prosencephalic vein of Markowski, which drains into the vein of Galen.¹

The classification by Lasjaunias *et al.*¹ differentiates VGAM from vein of Galen aneurysmal dilatation (VGAD); the latter has a parenchymal arteriovenous malformation that drains through the vein of Galen. VGAD more often presents with cerebral haemorrhage. Further separation of VGAM into choroidal and mural types is based on the vasculature. Choroidal VGAMs, which usually present in the neonatal period with cardiac failure have abundant, usually bilateral blood supply from choroidal arteries and pericallosal arteries. There is commonly additional supply from transiencephalic

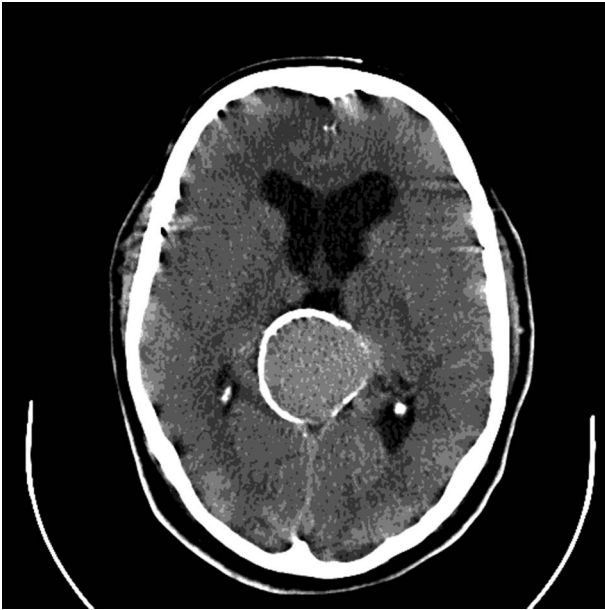


FIG. 1. Axial CT brain scan showing aneurysmal malformation.

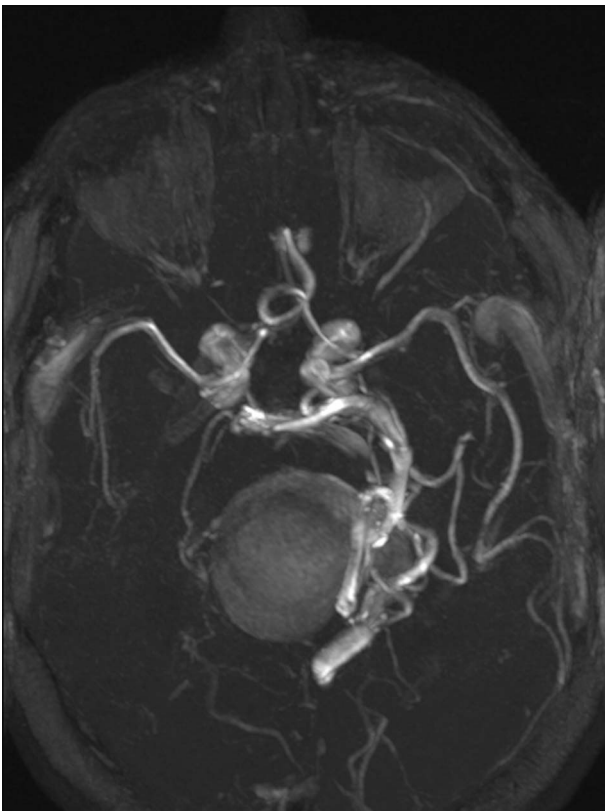


FIG. 2. MR angiogram—3D reconstruction.

or transmesencephalic perforating vessels (usually thalamoperforating vessels).

Vein of Galen malformations are the most frequent cranial arteriovenous malformation seen in neonates. The incidence is approximately 1 per 25,000 births.² Gold *et al.*³ divided the clinical presentation of these rare congenital abnormalities into three characteristic age groups. The neonate typically presents with intractable high output heart failure. The infant presents with hydrocephalus or seizures. Older

children (and adults) present with subarachnoid haemorrhage.

The neonatal presentation is the most common (90%) and carries the poorest prognosis. With high flow through the fistula the surrounding brain tissue may be deprived of blood ('steal' phenomenon), causing parenchymal damage and possibly cortical infarction. The extent of myocardial and brain ischemia is the most important factor in the prognosis of this group.

Symptoms include seizures, hydrocephalus, neurological deficit, or cardiovascular symptoms and signs. Clinical manifestations in the neonatal period and early infancy include macrocephaly, a loud intracranial bruit and dilatation of orbital veins. Rarely do patients survive to adulthood without experiencing such symptoms.

Although Steinheil⁴ was first to describe a vein of Galen malformation from postmortem finding in a 49-year-old man, presentation in adult life is extremely rare. Our literature search revealed only one other case report of first presentation of such a vascular malformation in an adult, who had no symptoms previously.⁵

Suspicion of VGAM may be raised during routine antenatal ultrasonography with the appearance of a midline cystic lesion that may be seen after 25 weeks gestation. Doppler flowmetry can be used to identify this as an AVM and the diagnosis confirmed by antenatal MRI.

Complications from vein of Galen malformation also include mass effect and compression of surrounding structures (which may or may not also cause hydrocephalus) and ischaemia of brain parenchyma (which may lead to atrophy, dystrophic calcification and convulsions).

Management

Initial treatment of VGAM in neonates is conservative with medical management of cardiac failure. Presentation in older children and adults requires management of haemorrhage or hydrocephalus.

Treatment options for the vascular malformation include transarterial embolization with cyanoacrylate glue, venous approach embolization (transtorcular or transfemoral approach), and surgical closure of the shunt by ligation of the arterial feeders from the posterior and middle cerebral arteries and plication of the aneurysm.¹

Spontaneous thrombosis of the malformation can occur, in which case the patient may only suffer with symptoms of mass effect causing hydrocephalus. In such cases CT would show a calcified non-homogenous mass with no surrounding oedema. The treatment options for hydrocephalus include ventriculoperitoneal shunt and endoscopic third ventriculostomy. Thrombosed vein of Galen malformations can be resected to relieve compression and prevent neurological deterioration.

Left untreated, vein of Galen malformations have a poor prognosis with very high mortality rates. Death usually results from cardiac failure or cerebral decompression. Overall mortality rates can be around 15%, including those undergoing arterial embolization. 50–60% of patients undergoing embolization survive with either mild or no developmental delay, and no permanent disability.³

Conclusion

Vein of Galen malformations are the most common arteriovenous malformations seen in neonates and commonly present with heart failure. Older children and adults present with haemorrhage. Affected individuals rarely survive to adulthood without experiencing any symptoms and adult presentation is extremely rare.

Declaration of interest: The authors report no conflicts of interest. The authors alone are responsible for the content and writing of the paper.

References

- 1 Lasjaunias PM, Alvarez H, Rodesch G, *et al.* Aneurysmal malformation of the vein of galen, followup of 120 children treated between 1984 and 1994. *Intervent Neuroradiol* 1996; 2:15–26.
- 2 Horowitz MB, Jungreis CA, Quisling RG, Pollack I. Vein of Galen aneurysms: a review and current perspective. *Am J Neuroradiol* 1994;15:1486–96.
- 3 Gold AP, Ransohoff JR, Carter S. Vein of Galen malformation. *Acta Neurol. Scand* 1964;40(Suppl 11):5.
- 4 Palmer JD. *Neurosurgery. Manual of neuroscience*. London: Churchill Livingstone, 1996:632–4.
- 5 Marques RM, Lobao CA, Sasaki VS, Agular LR. Vein of Galen aneurysm in an adult: case report. *Arq Neuropsiquiatr* 2006; 64(3B):862–4.