

Brief Reports

Psychosis, Short Stature in Benign Hereditary Chorea: A Novel Thyroid Transcription Factor-1 Mutation

Amir Glik, MD,¹ Isabelle Vuillaume, MD, PhD,²
David Devos, MD, PhD,³
and Rivka Inzelberg, MD^{1,4*}

¹Department of Neurology and the Sagol Neuroscience Center, Sheba Medical Center, Tel Hashomer, Israel;

²Molecular Biology and Biochemistry Institute, Neurobiology Unit, Centre Hospitalier et Universitaire, Lille, France;

³Department of Neurology, EA2683, IFR114, IMPRT, Lille, France; ⁴Department of Neurology, Rappaport Faculty of Medicine, Technion, Haifa, Israel

Video



Abstract: Benign hereditary chorea (BHC) is a rare autosomal dominant nonprogressive movement disorder. In some cases the phenotype includes, besides choreoathetosis, thyroid dysfunction and pulmonary infections in infancy, as expressed by the name “Brain-Thyroid-Lung syndrome”. Mutations in the thyroid transcription factor-1 (*TITF-1*) gene have been identified in some BHC families. We present the phenotypic features of a family with chorea, hypothyroidism, and lung dysfunction. All affected individuals suffered from a nonprogressive chorea with infancy onset. All showed short stature and some webbed neck. One patient suffered from psychosis at the age of 27 years another from lung carcinoma. In all affected individuals, a novel mutation consisting of heterozygous C to A substitution at position 650 of the coding sequence of the *TITF-1* gene, exon 3 was detected, leading to a premature stop at codon 217 (S217X). We describe the unique phenotypic features and intrafamilial variability expressing this novel mutation. © 2008 Movement Disorder Society

Additional Supporting Information may be found in the online version of this article.

*Correspondence to: Dr. Rivka Inzelberg, The Sagol Neuroscience Center, Sheba Medical Center, Tel Hashomer 52621, Israel.
E-mail: irivka@tx.technion.ac.il or rivka.inzelberg@gmail.com

Potential conflict of interest: None reported.

Received 23 April 2008; Revised 12 June 2008; Accepted 16 June 2008

Published online 25 July 2008 in Wiley InterScience (www.interscience.wiley.com). DOI: 10.1002/mds.22215

Key words: chorea; brain-thyroid-lung; benign hereditary chorea; *TITF-1*; thyroid

Benign hereditary chorea (BHC) is a rare autosomal dominant nonprogressive movement disorder with onset in infancy or childhood (OMIM 118700). Recently, mutations in the gene encoding thyroid transcription factor-1 (*TITF-1*), a member of the NK2 gene family, have been identified in some BHC pedigrees.^{1–4} Prevalence is estimated to be about two per million,⁵ although no recent epidemiological data are available. The phenotype includes choreoathetosis, thyroid dysfunction, and recurrent pulmonary infections in infancy.⁵ We herein describe the benign and variable phenotype of a novel mutation within a family.

METHODS

The pedigree is depicted in Figure 1. Family members II-4, II:5, III:1, and III:2 (see Fig. 1) were available for detailed neurological examination. All participating individuals gave informed consent for genetic testing. Information concerning I-4, who was deceased, was obtained through her son (II-5).

DNA samples for mutational screening were available from the index patient (III-1), clinically affected family members (II:5, III:2), and the index case's unaffected mother (II-4). Genomic DNA was extracted from peripheral blood using standard procedures. Sequencing analysis of the three *TITF-1* exons and splicing junctions was performed as previously described.⁴

RESULTS

The index patient (III-1) was the younger of two brothers born to nonconsanguineous parents of Jewish Ashkenazi origin (see Fig. 1). He was born prematurely around the 30th gestational week, weighed 2,300 g, following an uneventful pregnancy. Developmental milestones were normal. He presented normal intelligence and studied for 15 years. Involuntary choreic movements were detected soon after birth. The chorea remained stable over life with mild worsening at the age of 30. At the age of 27 the patient developed psy-

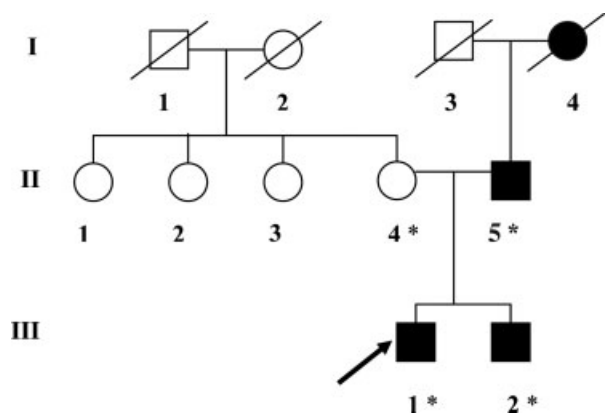


FIG. 1. Autosomal dominant inheritance of a novel *TITF-1* nonsense mutation in a pedigree with benign hereditary chorea. Dark symbols show affected individuals. Asterisks indicate genetically tested individuals. The black arrow indicates the index patient.

chosis, diagnosed as suffering from schizophrenia and was hospitalized in a psychiatric hospital. He was well controlled with Olanzapine.

In early childhood, he developed hypothyroidism, later successfully treated with L-thyroxin.

During admission, the patient was 35 years old. General physical examination revealed no pathology besides short stature and obesity. Neurological examination revealed normal high cognitive functions. Cranial nerve examination: speech was slurred and slow. Smooth pursuit and horizontal saccades showed normal speed and amplitude. Downward saccades were slow. Other cranial nerve functions, muscle tone, force, and reflexes were normal. Plantar responses were flexor. Sensory examination revealed no pathology.

He had choreoathetotic involuntary movements involving the neck, trunk, and all four limbs. They were more prominent on the left limbs and included a rotation of the neck to the left. When holding the arms up straight forward he displayed choreoathetoid movements of both hands and fingers with myoclonic jerks.

An asymmetrical intentional tremor of both upper limbs was observed, mainly in the left upper limb. The chorea worsened during eye closure and voluntary movements, but vanished while walking. An intermittent dystonic posture of the left foot, which worsened during intellectual activity, was observed. This posture disappeared during gait. Step size and pace were normal.

The patient's brother (III:2) had abnormal skeletal features including short stature and webbed neck. He suffered from hypothyroidism, asthma, and obesity. He reported disabling nonprogressive (Table 1) choreic movements, which appeared at early childhood. The index patient's father (II-5) showed a similar short stat-

TABLE 1. Clinical findings in the affected individuals

	I-4	II-5	III-1	III-2
Chorea	+	+	+	+
Psychosis		-	+	-
Hypothyroidism	Unknown	+	+	+
Short stature	-	+	-	+
Pulmonary involvement	Lung cancer	-	-	+
Normal intelligence	+	+	+	+

ure, the typical chorea, and suffered from hypothyroidism. The index patient's mother (II-4) had no neurological deficit.

Family history concerning I-4 was obtained through her son (II-5). She suffered from chorea, lung carcinoma, and died at the age of 62 (Table 1). Information regarding her thyroid functions was lacking. The index patient's paternal grandfather (I-3) was reported to be normal.

Work-up of the index patient showed normal whole blood count, sedimentation rate, liver, and renal function tests. Blood smear was negative for acanthocytes. Ophthalmological examination including slit lamp was normal.

Genetic Findings

Sequencing of the *TITF-1* gene revealed in the index patient (III-1) and in all clinically affected family members (II:5, III:2), the presence of a heterozygous C to A substitution at position 650 of the coding sequence (Ensembl Transcript ID:ENST00000354822) in exon 3. This mutation is predicted to lead to a premature stop at codon 217 (S217X), and is located within the homeobox DNA-binding domain of *TITF-1*, at position 27 (see Fig. 2). Presumably, this will result in a loss of DNA binding and thus in a loss of function of the protein. The healthy mother (II-4) did not carry the S217X mutation. Huntington's disease was

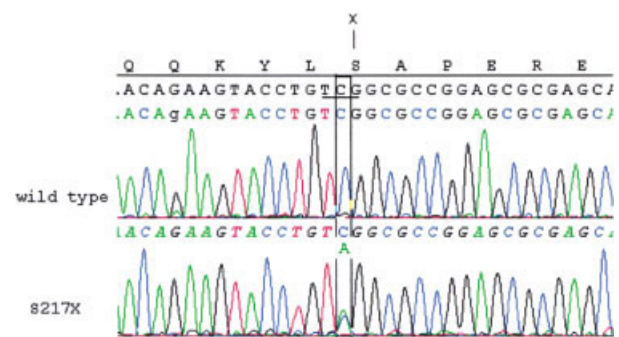


FIG. 2. A heterozygous C to A substitution at position 650 of the *TITF-1* gene introduces a stop at codon217 (S217X) in all patients.

excluded in all three patients by direct genetic analysis of the *IT15* gene.

DISCUSSION

We reported a novel heterozygous nonsense mutation in the *TITF-1* gene, with a substitution of C to A at position 650 of exon 3 with intrafamilial phenotypic variability and unique clinical features.

Our index patient suffered from psychosis at the age of 27 years. Individuals with psychosis were described in the era prior to gene identification in two families, who clinically presented with BHC.^{6,7} Therefore, we cannot be sure that these descriptions belong to carriers of a *TITF-1* gene mutations. Serious behavioral problems leading to imprisonment were described in one family with BHC. The nature of the psychiatric disorder was not described in detail.⁷ In the second described family, a patient presented with psychosis at the age of 22 years, requiring institutionalization, whereas another one died at the age of 43 years in a psychiatric hospital.⁶

Another observation in our affected individuals was the short stature and webbed neck. Sadjapour and Amato described in 1973, similar body structure in their reported pedigree.⁶ No genotyping was available at that time. Interestingly, their patients carried both the psychiatric and stature phenotype observed in our pedigree.

All individuals that carried the *TITF-1* mutation in our described pedigree presented with chorea and hypothyroidism. However, pulmonary dysfunction was observed only in one individual. Phenotypic variability is common in *TITF-1* mutations.⁵ Although chorea is the hallmark and present in the majority of mutation carriers, the triad of chorea, thyroid, and lung dysfunction is not necessarily present in all patients. Only one of our mutation carriers presented the triad.

Our index patient presented with hypothyroidism and chorea as part of the triad. An unusual feature of his chorea included the presence of rapid jerky limb movements. Although dystonia often accompanies BHC, myoclonic jerks are exceptional.⁸ The presence of continuous chorea has been proposed to discriminate BHC from myoclonic dystonia, characterized by rapid jerky movements. However, our patient's phenotypic spectrum included chorea, dystonia, and myoclonic jerks.

In our pedigree, the paternal grandmother of the proband suffered from lung cancer. Willemsen et al.⁹ described a patient with a *TITF-1* mutation who died at the age of 23 from metastatic lung carcinoma. They

raised the question of a possible relationship between the *TITF-1* mutation and lung cancer. Remarkably, leukemia was reported in two *TITF-1* mutation carriers in two different pedigrees,^{2,10} but no functional link between *TITF-1* and lymphocyte differentiation has been shown to date. A mouse model for lung carcinogenesis suggests a role for reduced *TITF-1* signaling in tumorigenesis.¹¹ Whether the *TITF-1* gene mutation predisposed to the development of lung cancer or leukemia and its relationship to tumorigenesis remains speculative.

The detected novel heterozygous nonsense mutation introduces a stop codon at position 217 (S217X). As in our case, most of the mutations reported truncate the encoded protein before or within the DNA binding homeobox functional domain, affecting the DNA binding properties of the gene, and suggesting haploinsufficiency as a presumed mutational mechanism.¹⁰

Our reported pedigree demonstrated a mild form of BHC. Studies suggest that the size of deletions may influence the severity of the phenotype although it is unclear whether such a linear relationship adequately explains the clinical heterogeneity of the disorder.⁵

Although large deletions may explain clinical severity, by occasional involvement of contiguous genes,^{3,5} phenotype-genotype correlations in point mutations as in ours are even less clear and remain to be elucidated.

LEGENDS TO THE VIDEO

The patient has short stature. He depicts choreoathetotic involuntary movements involving the neck, trunk, and all four limbs. They are more prominent on the left limbs and include a rotation of the neck to the left. When holding the arms up straight forward he displays choreoathetoid movements of both hands and fingers with myoclonic jerks.

An asymmetrical intentional tremor of both upper limbs is observed, mainly in the left upper limb. The chorea worsens during eye closure and voluntary movements, but vanishes while walking. An intermittent dystonic posture of the left foot is observed. This posture disappears during gait. Step size and pace are normal.

REFERENCES

1. Breedveld GJ, Percy AK, MacDonald ME, et al. Clinical and genetic heterogeneity in benign hereditary chorea. *Neurology* 2002; 59:579–584.
2. Kleiner-Fisman G, Rogaeva E, Halliday W, et al. Benign hereditary chorea: clinical, genetic, and pathological findings. *Ann Neurol* 2003;54:244–247.
3. Devos D, Vuillaume I, de Beedelièvre A, et al. New syndromic form of benign hereditary chorea is associated with a deletion of *TITF-1* and *PAX-9* contiguous genes. *Mov Disord* 2006;21:2237–2240.

4. Breedveld GJ, van Dongen JW, Danesino C, et al. Mutations in TITF-1 are associated with benign hereditary chorea. *Hum Mol Genet* 2002;11:971–979.
5. Kleiner-Fisman G, Lang AE. Benign hereditary chorea revisited: a journey to understanding. *Mov Disord* 2007;22:2297–2305.
6. Sadjadpour K, Amato RS. Hereditary nonprogressive chorea of early onset—a new entity? *Adv Neurol* 1973;1:79–91.
7. Bird TD, Carlson CB, Hall JG. Familial essential (“benign”) chorea. *J Med Genet* 1976;13:357–362.
8. Asmus F, Devlin A, Munz M, Zinprich A, Gasser T, Chinnery PF. Clinical differentiation of genetically proven benign hereditary chorea and myoclonic dystonia. *Mov Disord* 2007;22:2104–2109.
9. Willemsen MA, Breedveld GJ, Wouda S, et al. Brain-Thyroid-Lung syndrome: a patient with a severe multi-system disorder due to a de novo mutation in the thyroid transcription factor 1 gene. *Eur J Pediatr* 2005;164:28–30.
10. Asmus F, Horber V, Pohlenz J, et al. A novel TITF-1 mutation causes benign hereditary chorea with response to levodopa. *Neurology* 2005;64:1952–1954.
11. Kang Y, Hebron H, Ozburn L, Mariano J, Minoo P, Jakowlew SB. Nkx2.1 transcription factor in lung cells and a transforming growth factor- β 1 heterozygous mouse model of lung carcinogenesis. *Mol Carcinog* 2004;40:212–231.

Cancer and Blood Concentrations of the Comutagen Harmane in Essential Tremor

Elan D. Louis, MD, MSc,^{1,2,3,4*}
 Kathryn M. Pellegrino, BA,¹ Pam Factor-Litvak, PhD,⁴
 Eileen Rios, BS,¹ Wendy Jiang, MD, PhD,⁵
 Claire Henchcliffe, MD, DPhil,⁶
 and Wei Zheng, PhD⁵

¹*GH Sergievsky Center, College of Physicians and Surgeons, Columbia University, New York, New York, USA;*

²*Department of Neurology, College of Physicians and Surgeons, Columbia University, New York, New York, USA;*

³*Taub Institute for Research on Alzheimer's Disease and the Aging Brain, College of Physicians and Surgeons, Columbia University, New York, New York, USA;*

⁴*Department of Epidemiology, Mailman School of Public Health, Columbia University, New York, New York, USA;*

⁵*Department of Neurology and Neuroscience, Purdue University School of Health Sciences, West Lafayette, Indiana, USA;*

⁶*Weill Medical College of Cornell University, New York, New York, USA*

Abstract: Blood concentrations of harmane, a tremor-producing neurotoxin, are elevated in essential tremor (ET). Harmane is also a comutagen. Using a case-control design, we compared the prevalence of cancer in ET cases vs. controls, and determined whether blood harmane concentrations are elevated among ET cases with cancer. 66/267 (24.7%) ET cases vs. 55/331 (16.6%) controls had cancer (adjusted OR 1.52, 95% CI 1.01–2.30, $P = 0.04$). Among specific cancer types, colon cancer was more prevalent in ET cases than controls (2.6% vs. 0.6%, $P = 0.04$). Log blood harmane concentration was higher in ET cases vs. controls ($P = 0.02$) and in participants with vs. without cancer ($P = 0.02$). Log blood harmane concentration was highest in ET cases with cancer when compared with other groups ($P = 0.009$). These links between cancer and ET and between high blood harmane and cancer in ET deserve further study. © 2008 Movement Disorder Society

Key words: essential tremor; epidemiology; cancer; toxin; harmane

*Correspondence to: Dr. Elan Louis, Unit 198, Neurological Institute, 710 West 168th Street, New York, New York, 10032.

E-mail: edl2@columbia.edu

Potential conflict of interest: None reported.

Received 5 December 2007; Revised 27 February 2008; Accepted 19 March 2008

Published online 15 August 2008 in Wiley InterScience (www.interscience.wiley.com). DOI: 10.1002/mds.22084

Harmane (1-methyl-9H-pyrido[3,4-*b*]indole), a potent neurotoxin,¹ is present in many foods in the human diet.² Laboratory animals exposed to harmane and other heterocyclic amines develop an acute essential tremor (ET)-like action tremor.³ Interestingly, blood harmane concentration has been found to be elevated in ET cases compared with controls.⁴

Many heterocyclic amines are also mutagens and are linked with several types of cancer (especially colon and prostate).^{1,5,6} While harmane itself is not mutagenic, it exerts comutagenic activity in bacteria and mammalian cells.^{7,8}

Medical comorbidity has not been studied extensively in ET; indeed, there are no data on the prevalence of cancer in ET cases. By contrast, this topic has been examined extensively in Parkinson's disease (PD), which is associated with increased risk of melanoma and reduced risks of other cancer types.⁹

Harmane is a comutagen and a high blood concentration could conceivably predispose an individual to cancer. Blood harmane concentrations also seem to be elevated in ET.⁴ We therefore tested the hypothesis that we would find particularly high blood harmane concentrations among ET cases with cancer.

The aims of this study were to: (1) compare the prevalence of cancer in ET cases vs. controls, and (2) determine whether blood harmane concentrations are elevated among ET cases with cancer.

SUBJECTS AND METHODS

All participants were enrolled (2000–present) in an ongoing study of the environmental epidemiology of ET.⁴ ET cases were patients at the Neurological Institute of New York, Columbia University Medical Center (CUMC) or the Weill Medical College of Cornell University (WMC). Their ascertainment, including identification from a computerized database, has been described previously.⁴ Controls were identified from the New York Tri-state area using random digit telephone dialing and, as described in detail,⁴ came from the same source population as the cases. Controls were frequency-matched to cases based on gender, race, and age and were screened so as to be free of tremor. The CUMC and WMC Internal Review Boards approved all study procedures and written informed consent was obtained upon enrollment. To date, 352 cases and 331 controls have enrolled, although 85 cases were excluded because their ET diagnosis could not be confirmed (see criteria below); their diagnoses were as follows: PD (11), dystonia (13), psychogenic tremor (1), myoclonus (1), enhanced physiological, drug-induced,

and other tremors (59). Sixteen (18.8%) of 85 had cancer. Data on the remaining 267 cases and 331 controls were used to estimate cancer prevalence. Blood harmane data were available on 147 cases and 187 controls (data were unavailable in the remainder for several reasons: patient refused, laboratory moved locations, failed phlebotomy, quantity not sufficient). Participants with vs. without blood harmane data were similar (Table 1).

Participants were evaluated in person by a trained tester using structured questionnaires to collect demographic and medical data. Cancer was reported by the participants and was confirmed by a review of medical records and pathology reports. In a substudy of 75 ET cases and 75 controls who reported no malignancy, we determined based on medical record review that the proportion of false negative reports was low [1/75 or 1.3% (cases) and 1/75 or 1.3% (controls)]. Severity of illness in 14 disease systems was rated using the Cumulative Illness Rating Scale.¹⁰

The tester videotaped a tremor examination¹¹ and each of 12 videotaped action tremor items was rated by Dr. Louis (0–3), who was blinded to cancer status, and who confirmed the ET diagnosis using published diagnostic criteria (moderate or greater amplitude action tremor during ≥ 3 activities or head tremor in the absence of PD or dystonia).¹¹

Phlebotomy was performed and blood harmane concentration was quantified using a high-performance liquid chromatography method as described previously.¹²

Analyses were performed in SPSS Version 15.0. Chi-square (χ^2), *t* tests, analysis of variance (ANOVA) with Tukey's post test comparisons, and Pearson's correlation coefficients were used to test for associations. Blood harmane concentrations were log transformed (\log_{10}) because they were not normally distributed. In regression analyses, covariates were included in adjusted models when they were associated with the dependent or independent variables in univariate analyses or when prior analyses⁴ indicated such an association.

RESULTS

Cancer Odds in ET

The 267 ET cases and 331 controls were similar in terms of demographic characteristics, years since last hospitalization and Cumulative Illness Rating Scale scores (Table 1). 66/267 (24.7%) ET cases vs. 55/331 (16.6%) controls had cancer (Table 1). In a logistic regression analysis in which cancer was the depend-

TABLE 1. Demographic and clinical characteristics of ET cases and controls

	All ET cases (N = 267)	All controls (N = 331)	ET cases with harmane data (N = 147)	Controls with harmane data (N = 187)
Demographic and clinical characteristics				
Age in years	68.5 ± 14.4	66.6 ± 13.1	67.7 ± 14.6*	64.0 ± 13.8
Female gender	145 (54.3%)	194 (58.6%)	81 (55.1%)	107 (57.2%)
Years of education	14.8 ± 4.1	15.1 ± 3.5	15.0 ± 4.0	15.2 ± 3.6
Current cigarette smoker	16 (6.0%)	30 (9.1%)	10 (6.8%)	18 (9.6%)
Ever cigarette smoker	131 (49.1%)	169 (51.1%)	75 (51.0%)	98 (52.4%)
Cigarette pack-years	9.4 ± 19.6	11.0 ± 21.8	8.0 ± 17.9	9.6 ± 20.3
Years since last hospitalization	13.9 ± 20.5	14.6 ± 19.9	13.8 ± 18.9	14.5 ± 18.9
Cumulative Illness Rating Scale Score	5.6 ± 3.7	5.3 ± 3.7	5.4 ± 3.7	5.0 ± 3.8
Cancer				
Cancer	66 (24.7%)	55 (16.6%)		
Colon*	7 (2.6%)	2 (0.6%)		
Skin	22 (8.2%)	17 (5.1%)		
Melanoma	8 (3.0%)	9 (2.7%)		
Basal cell carcinoma	9 (3.4%)	4 (1.2%)		
Squamous cell carcinoma	4 (1.5%)	3 (0.9%)		
Basal and Squamous	1 (0.4%)	1 (0.3%)		
Prostate	8 (3.0%)	7 (2.1%)		
Breast	18 (6.7%)	22 (6.6%)		
Uterine/ovarian	4 (1.5%)	4 (1.2%)		
Lung	1 (1.4%)	0 (0.0%)		
Other ^a	6 (2.2%)	3 (0.9%)		

* $P < 0.05$ compared with controls (χ^2 and t tests).

^aIncludes bladder, brain, kidney, thyroid, and lymphoma/leukemia.

ent variable and ET vs. control was the independent variable, unadjusted odds ratio (OR) = 1.65, 95% confidence interval (CI) = 1.10–2.46, $P = 0.01$; OR adjusted for age in years, gender, ever cigarette smoker = 1.52, 95% CI = 1.01–2.30, $P = 0.04$. Further inclusion of cigarette pack-years as a covariate in the same adjusted regression model did not change the results (OR = 1.52, 95% CI = 1.01–2.29, $P = 0.047$). The prevalence of colon cancer, in particular, was higher in ET cases than controls (2.6% vs. 1.6%, $P = 0.04$) and the prevalence of skin cancer was marginally elevated (8.2% vs. 5.1%, $P = 0.13$). The prevalence of melanoma was similar in cases and controls (Table 1). After stratifying by gender, 33/122 (27.0%) male cases vs. 18/137 (13.1%) male controls had cancer [unadjusted $OR_{men} = 2.45$, 95% CI = 1.30–4.63, $P = 0.006$; adjusted (age, ever cigarette smoker) $OR_{men} = 2.23$, 95% CI = 1.16–4.29, $P = 0.016$], and 33/145 (22.8%) female cases vs. 37/194 (19.1%) female controls had cancer (unadjusted $OR_{women} = 1.25$, 95% CI = 0.74–2.12, $P = 0.41$; adjusted $OR_{women} = 1.17$, 95% CI = 0.68–2.01, $P = 0.57$). In 34 ET cases, there were precise data both on age of tremor onset and age at cancer diagnosis; in 30 (88.2%), tremor preceded the cancer diagnosis (mean latency = 15.6 ± 2.7 years, median = 10.0).

Blood Harmane, Cancer, and ET

One hundred forty-seven ET cases and 187 controls with blood harmane results were similar, except for a 3.7 year age difference (Table 1). Among controls, log blood harmane concentration was not associated with age, gender, education, cigarette smoking (current, ever, or pack-years), years since last hospitalization, or Cumulative Illness Rating Scale score (all P values > 0.3).

Log blood harmane concentration was higher in ET cases vs. controls (0.61 ± 0.63 g⁻¹⁰/mL vs. 0.44 ± 0.68 g⁻¹⁰/mL, $P = 0.02$) and in participants with vs. without cancer (0.70 ± 0.68 g⁻¹⁰/mL vs. 0.48 ± 0.65 g⁻¹⁰/mL, $P = 0.02$). Log blood harmane concentration was highest in ET cases with cancer (0.87 ± 0.68 g⁻¹⁰/mL, Table 2, $P = 0.009$). In a linear regression analysis, ET cases with cancer had higher log blood harmane concentrations than controls without cancer ($b = 0.15$, $P = 0.002$), even after adjusting for age in years, gender, ever cigarette smoker, and cigarette pack-years ($b = 0.14$, $P = 0.003$). Stratifying by gender did not change the results (unadjusted $b = 0.16$ and $P = 0.01$ [men], and unadjusted $b = 0.13$ and $P = 0.048$ [women]).

Log blood harmane concentration was stratified into quartiles. ET cases with cancer were nearly twice as likely as controls without cancer to be in the highest

TABLE 2. Log blood harmane concentrations (g^{-10}/mL) by ET diagnosis and cancer

	ET cases (N = 147)	Controls (N = 187)
Participant with cancer (N = 58)	0.87 ± 0.68 (N = 30)	0.51 ± 0.64 (N = 28)
Participant without cancer (N = 276)	0.54 ± 0.60 (N = 117)	0.43 ± 0.69 (N = 159)

For comparison of all four groups, ANOVA $F = 3.90$, $P = 0.009$.

In Tukey post hoc comparisons:

ET cases with cancer vs. controls without cancer, $P = 0.005$.

ET cases with cancer vs. controls with cancer, $P = 0.16$.

ET cases with cancer vs. ET cases without cancer, $P = 0.07$.

Controls with cancer vs. controls without cancer, $P = 0.56$.

Log blood harmane concentration was higher in ET cases vs. controls ($0.61 \pm 0.63 \text{ g}^{-10}/\text{mL}$ vs. $0.44 \pm 0.68 \text{ g}^{-10}/\text{mL}$, $P = 0.02$) and in participants with vs. without cancer ($0.70 \pm 0.68 \text{ g}^{-10}/\text{mL}$ vs. $0.48 \pm 0.65 \text{ g}^{-10}/\text{mL}$, $P = 0.02$).

vs. lowest log blood harmane concentration quartile [unadjusted OR = 1.72, 95% CI = 1.10–2.68, $P = 0.017$, and adjusted (age, gender, ever cigarettes smoker, and cigarette pack-years) OR = 1.62, 95% CI = 1.02–2.60, $P = 0.04$].

DISCUSSION

Odds of cancer have been studied extensively in PD⁹ but they have never been studied in ET. In general, there are very few data on medical comorbidities in ET. With the current analyses, we begin to examine the epidemiologic evidence that patients with ET have increased odds of cancer. In this sample, the odds of cancer were increased by ~50% in ET cases compared with matched controls from the same source population. Colon cancer, in particular, was more prevalent in ET cases than controls. This is of interest because of established links between dietary heterocyclic amines and colon cancer.⁶ Melanoma, which is more prevalent in PD,⁹ was present in a similar proportion of ET cases and controls. In another study,¹³ cancer was marginally more common in ET families (23.3%) than in control families (17.2%), but this area has not otherwise been studied.

As previously demonstrated,⁴ blood harmane concentrations were elevated in ET cases. Furthermore, they were most elevated in ET cases with cancer, among whom levels were double those of controls without cancer. Harmane is both tremorogenic and comutagenic, so that it is possible that elevated blood harmane concentration is a common determinant for both diseases (i.e., ET and cancer). One possibility is that differences in dietary harmane intake predispose to these diseases. Another possibility is that genetic differences lead to differences in the ability to metabolize dietary harmane, leading to the accumulation of blood concentrations in individuals who then develop both ET and cancer. Each of these models requires further exploration. An alternative model is that treatment for

cancer could precipitate ET and lead to increased blood harmane concentrations. However, this is less biologically plausible and, furthermore, in the large majority of our cases, tremor preceded the cancer diagnosis by many years.

The molecular mechanisms that underlie the tremorogenic toxicity of harmane are unknown. One possibility is that harmane has acidifying properties that change neural membrane potentials.¹⁴

One issue is whether our controls were systematically selected for their overall-health, thereby leading us to underestimate the prevalence of cancer in our comparison group. Controls were selected to be tremor-free but were not selected with regards to overall health. Indeed, their overall morbidity, as assessed through Cumulative Illness Rating Scale scores and years since last hospitalization, was similar to that of our ET cases. In addition, using published estimates of cancer rates in New York State,¹⁵ we calculated that the cumulative incidence of all cancers among persons living up to age 70 years is ~8.0% and, among persons living up to age 85 years, ~16.0%. These expected proportions are lower than or similar to those we observed in our controls (mean age = 66.6 ± 13.1 years), indicating that our comparison group was not selected to be cancer-free.

This study was cross sectional rather than longitudinal; we were not able to assess whether high harmane concentrations preceded either ET or cancer. Yet the study also has considerable strengths. It is the only study to examine the association between cancer and ET and the only study to look at the relationships between ET, cancer, and blood harmane concentrations. We used a large sample of ET cases and matched controls from the same source population.

In summary, the links between cancer in ET and especially between high blood concentrations of the tremorogenic comutagen harmane and cancer in ET deserve additional investigation.

Acknowledgments: This work is supported by R01 NS039422, R01 NS042859, P30 ES09089, and RR00645 (General Clinical Research Center) (NIH, Bethesda, MD). The statistical analyses were conducted by Dr. Louis.

REFERENCES

1. De Meester C. Genotoxic potential of beta-carbolines: a review. *Mutat Res* 1995;339:139–153.
2. Anderson NJ, Tyacke RJ, Husbands SM, Nutt DJ, Hudson AL, Robinson ESJ. In vitro and ex vivo distribution of [³H]harmaline, an endogenous β -carboline, in rat brain. *Neuropharmacology* 2006; 50:269–276.
3. Martin FC, Thu Le A, Handforth A. Harmaline-induced tremor as a potential preclinical screening method for essential tremor medications. *Mov Disord* 2005;20:298–305.
4. Louis ED, Zheng W, Applegate L, Shi L, Factor-Litvak P. Blood harmaline concentrations and dietary protein consumption in essential tremor. *Neurology* 2005;65:391–396.
5. Bogen KT, Keating GA, Chan JM, et al. Highly elevated PSA and dietary PhIP intake in a prospective clinic-based study among African Americans. *Prostate Cancer Prostatic Dis* 2007; 10:261–269.
6. Armbrecht HJ, Lakshmi VM, Wickstra J, Hsu FF, Zenser TV. Metabolism of a heterocyclic amine colon carcinogen in young and old rats. *Drug Metab Dispos* 2007;35:633–639.
7. Totsuka Y, Ushiyama H, Ishihara J, et al. Quantification of the co-mutagenic β -carbolines, norharman and harman, in cigarette smoke condensates and cooked foods. *Cancer Lett* 1999;143: 139–143.
8. Boisset M, Billaud C, Desjeux J-F. Studies on the mechanism of intestinal passage of the food comutagen harman, in the rabbit. *Food Chem Toxicol* 1994;32:349–356.
9. Zanetti R, Rosso S, Loria DI. Parkinson's disease and cancer. *Cancer Epidemiol Biomarkers Prev* 2007;16:1081.
10. Linn BS, Linn MW, Gurel L. Cumulative illness rating scale. *J Am Geriatr Soc* 1968;16:622–626.
11. Louis ED, Ford B, Lee H, Andrews H. Does a screening questionnaire for essential tremor agree with the physician's examination? *Neurology* 1998;50:1351–1357.
12. Zheng W, Wang S, Guan Y, Louis E. Determination of harmaline and harmine in human blood using reversed-phased high-performance liquid chromatography and fluorescence detection. *Anal Biochem* 2000;279:125–129.
13. Roy M, Boyer L, Barbeau A. A prospective study of 50 cases of familial Parkinson's disease. *Can J Neurol Sci* 1983;10:37–42.
14. Bonnet U, Scherbaum N, Wiemann M. The endogenous alkaloid harmaline: acidifying and activity-reducing effects on hippocampal neurons in vitro. *Prog Neuropsychopharmacol Biol Psychiatry* 2008;32:362–367.
15. Cancer incidence and mortality by age group and region, 2000–2004, New York State. Available at: www.health.state.ny.us/statistics/cancer/registry.

Subthalamotomy in Cervical Dystonia: A Case Study of Lesion Location and Clinical Outcome

Christian K.E. Moll, MD,^{1*} Wolfgang Hamel, MD,² Christoph B. Ostertag, MD,³ Dieter Müller, MD,² Jürgen Finsterbusch, PhD,^{4,5} Andreas K. Engel, MD, PhD,¹ and Alexander Münchau, MD⁶

¹Department of Neurophysiology and Pathophysiology, Center of Experimental Medicine, University Medical Center Hamburg-Eppendorf, Hamburg, Germany; ²Department of Neurosurgery, University Medical Center Hamburg-Eppendorf, Hamburg, Germany; ³Department of Stereotactic and Functional Neurosurgery, University-Hospital Freiburg, Freiburg, Germany; ⁴Department of Systems Neuroscience, University Medical Center Hamburg-Eppendorf, Hamburg, Germany; ⁵Neuroimage Nord, University Medical Centers Hamburg-Kiel-Lübeck, Germany; ⁶Department of Neurology, University Medical Center Hamburg-Eppendorf, Hamburg, Germany

Abstract: Here we report a 63-year-old woman with primary cervical dystonia (CD) whose symptoms subsided for more than 30 years following a unilateral stereotactic subthalamotomy contralateral to the overactive left sternocleidomastoid muscle but then gradually recurred over a period of several months. The aim of the present study was to correlate the topography of the stereotactic lesion with the long lasting therapeutic effect. High-resolution magnetic resonance imaging and subsequent stereotactic analysis were performed to determine the anatomical localization of the lesion. The primary coagulation focus comprised the posterior subthalamic white matter in the prelemniscal radiation and field H of Forel. Neighboring structures were implicated to various extents. It is suggested that the posterior subthalamic area, with its abundance of interconnecting fibers and related nuclei, represents an effective target for the neurosurgical treatment of CD that may be explored further with deep brain stimulation. © 2008 Movement Disorder Society

Key words: cervical dystonia; subthalamotomy; subthalamic nucleus; stereotaxy; magnetic resonance imaging

*Correspondence to: Christian K. E. Moll, Department of Neurophysiology and Pathophysiology, Basal Ganglia Physiology Group, Center of Experimental Medicine, University Medical Center Hamburg-Eppendorf, Martinistraße 52, 20246 Hamburg, Germany. E-mail: c.moll@uke.uni-hamburg.de

Potential conflict of interest: None reported.

Received 2 April 2007; Revised 4 February 2008; Accepted 23 March 2008

Published online 15 August 2008 in Wiley InterScience (www.interscience.wiley.com). DOI: 10.1002/mds.22088

Cervical dystonia (CD) (or spasmodic torticollis) is an adult-onset, focal dystonia clinically defined as involuntary activation of neck muscles causing abnor-

mal movements and postures of the head and neck.¹ CD-patients refractory to pharmacotherapy have successfully been treated by ablative neurosurgical inter-

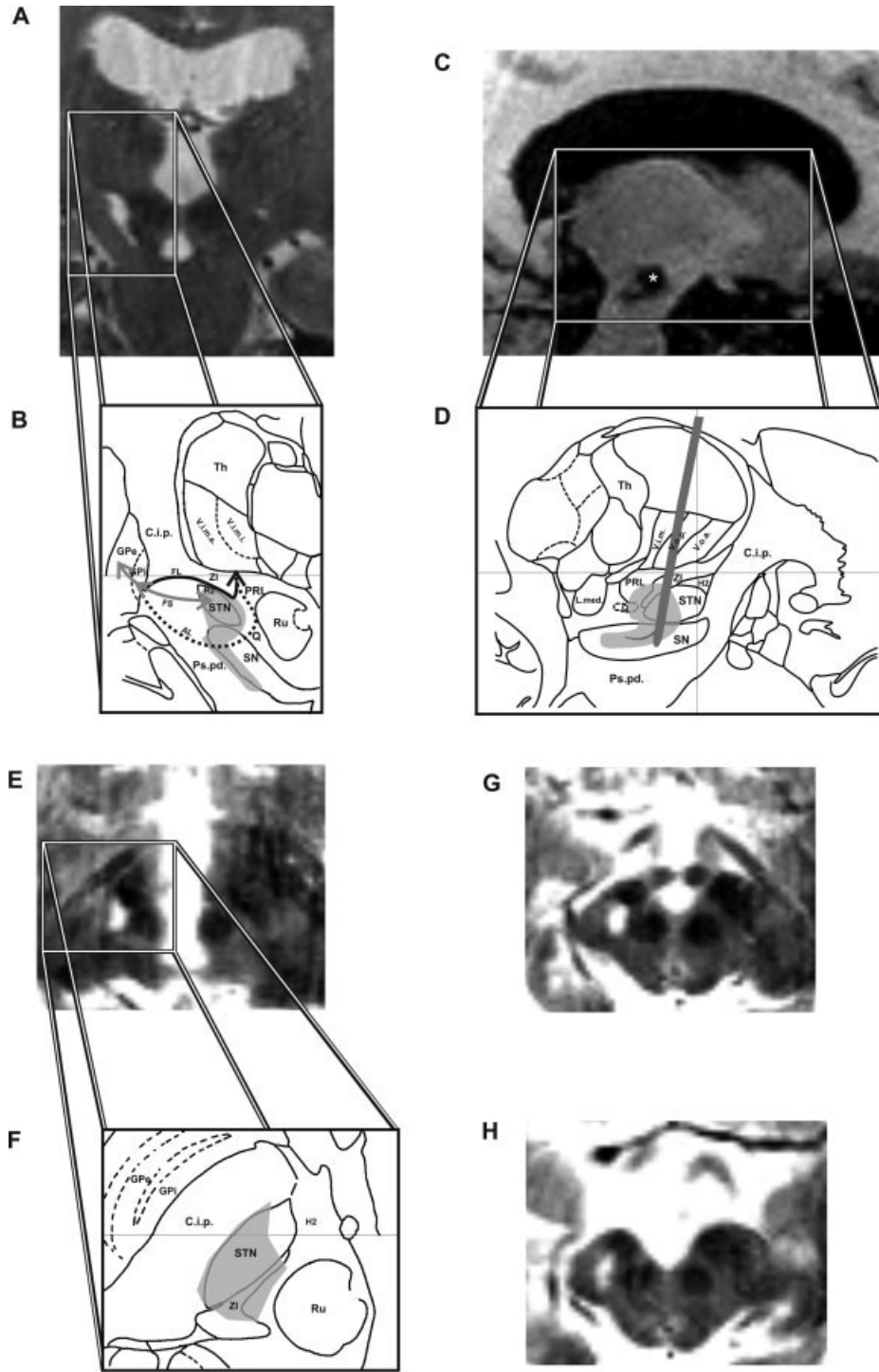


FIGURE 1.

ventions since the 1950s.² Pallidotomy was the initial procedure for treatment of CD in the 1950s,² and, today again, Leksell's target in the posteroventrolateral internal pallidum is approached in most deep brain stimulation (DBS) procedures performed for segmental and general dystonia.^{3,4} Nonetheless, in the late 1950s and early 1960s the stereotactic targets in torticollis surgery had changed and paralleled the preferred targets for Parkinson's disease with a delay of a few years. The internal pallidum was widely abandoned in favor of thalamic surgery,^{5,6} including interventions with deliberate targeting of the posterior subthalamic region.^{2,7-10} In the early 1970s, Mundinger stressed the long-term efficacy of interventions in the posterior subthalamic region in CD surgery and their superiority to pallidal and thalamic coagulations.¹¹ Consequently, he explored the use of therapeutic electrical stimulation of deep brain structures as early as 1977 and showed that unilateral subthalamic DBS suppressed abnormal head movements in CD patients.¹² Unfortunately, the impact of this hardly recognized work was rather limited and fell into oblivion together with a general decline of functional brain surgery in the 1970s. The subthalamic region has only rarely been tested in modern surgery for CD despite favorable results from the first era of stereotactic surgery.¹³

Here, we report on a long lasting (>30 years) therapeutic effect of a unilateral stereotactic subthalamotomy in a patient with CD. We aimed to identify the neural substrates the destruction of which is responsible for the long-term beneficial effect. Therefore, we applied the stereotactic method on high-resolution magnetic resonance images of the patient's brain.

CASE HISTORY

At the age of 29, this patient with an inconspicuous family history recognized a pulling sensation in the neck, months before abnormal head posture became apparent for the first time in the autumn of 1972. At the onset, she developed intermittent horizontal head turning towards the right side. No other body parts were affected. Initially, the patient was capable to suppress abnormal movements by supporting the chin with both hands. Symptoms progressed rapidly within weeks, leading to a constant rotation of the head to the right. Medical treatment was not beneficial but caused sleepiness and apathy. The patient became unable to work as a secretary. Because of a relative nihilism in the medical treatment of CD and a general therapeutic optimism concerning functional stereotactic surgery at that time, precedence was given to a stereotactic operation over the intradural rhizotomy of Foerster and Dandy or a peripheral surgical procedure.

SURGICAL PROCEDURE IN 1973

A right stereotactic subthalamotomy, ipsilateral to the direction of the abnormal head movement, was carried out by one of the authors (CBO) in February 1973. The surgical procedure comprised the use of a targeting device developed by Riechert and Mundinger.² Mundinger's approach for coagulations in the zona incerta (ZI), which intended to spare the subthalamic nucleus (STN), was chosen for this operation.^{9,11} To place the lesion as much as possible in the axial part of the subthalamic region, the use of a curved electrode was proposed, which could be protruded perpendicularly to the central shaft (Fig. 1D). The target

FIG. 1. Neuroimaging of the subthalamic lesion. **A:** 3 Tesla T2-weighted MRI. Coronal section at the level of the stereotactic lesion. The lesioned area is hyperintense with respect to the surrounding brain and extends in a streak-like fashion along the border of the SN to the internal capsule and cerebral peduncle. **B:** Magnified area of interest with a schematic representation of the subthalamic lesion coordinates (gray shaded area) superimposed on a modified section taken from the atlas of Schaltenbrand and Bailey.¹⁶ Coronal section, 5 mm posterior to the mid-commissural point. The three main output pathways of the pallidum have been indicated to illustrate that the lesion interrupts pallidofugal fibers at various levels. Note that the ansa lenticularis (AL) runs rostral to the present section, and is therefore displayed as a dashed line. Abbreviations: Th, Thalamus; V.o.a., Nc. ventralis oralis anterior thalami; V.o.p., Nc. ventralis oralis posterior thalami; V.i.m., Nc. ventralis intermedius thalami; ZI, Zona incerta; PRL, Prelemniscal radiation; H2, Forel's Field H2; STN, Subthalamic nucleus; L.med., Lemniscus medialis; SN, Substantia nigra; Ru, Red nucleus; C.i.p., Posterior internal capsule; Ps.pd., Pedunculus cerebri; Q, Fasciculus subthalamo-hypothalamicus (Sano); GPi, internal segment of globus pallidus; GPe, external segment of globus pallidus; AL, Ansa lenticularis; FL, lenticular fasciculus; FS, subthalamic fasciculus. **C:** 3 Tesla T1-weighted MRI (Flash 3D), sagittal section. The lesion area is hypointense with respect to the surrounding brain. The primary lesion cavity, which has its maximum diameter in this plane, is marked by an asterisk. Note the finger-like extension of the main lesion caused by a second coagulation using the curved electrode. **D:** Lesion extent superimposed on the corresponding sagittal slice (11 mm lateral to the midline) of the atlas of Schaltenbrand and Bailey.¹⁶ Schematic drawing of the putative position of the coagulation electrode including the curved lead pushed posteriorly (~8 mm) out of the trunk of the electrode. Abbreviations as above. **E:** 3 Tesla T2-weighted MRI. Horizontal section at the level of the posterior commissure. Note the encroachment of the hyperintense lesion onto the STN, which is in one plane with the posterior commissure and is clearly identifiable on the intact side. **F:** Lesion extent superimposed on a horizontal slice of the atlas of Schaltenbrand and Bailey¹⁶ (3.5 mm below AC-PC). Abbreviations as above. **G:** 3 Tesla T2-weighted MRI. Horizontal section at the level of the mammillary bodies, 3 mm inferior to the section in E. Note that the lesion mainly involves the STN-SN complex, neighboring structures to an extent (C.i.p., ZI), but spares the red nucleus. **H:** 3 Tesla T2-weighted MRI. Horizontal section 2-mm inferior to the section in G. Note the affection of nigral volume and of the neighboring cerebral peduncle, which appears slimmer compared to the intact side.

site was determined in relation to a baseline connecting the lower border of Monro's foramen and the posterior commissure, which were visualized by means of a stereotactic ventriculography. The target coordinates as derived from the stereotactic atlas of Andrew and Watkins¹⁴ were: 12 mm behind Monro's foramen, 8 mm lateral to the middle plane, and 5 mm below the baseline. After drilling of a trephine opening, the electrode with a tip diameter of 2 mm was inserted to the target level with approach angles of 10° in the frontal and 28° in the sagittal plane (rostral inclination), respectively. A temperature-controlled high-frequency coagulator (F.L. Fischer, Freiburg, Germany) was used to produce the lesion. The parameters used for monopolar electrocoagulation were 120 mA and ~20 V for a period of 20 to 30 seconds, resulting in an approximate temperature of 70°C for the tissue inactivation.

POSTOPERATIVE COURSE

The effect of the stereotactic operation was not immediately apparent. Initially, the malposition of the head persisted and the patient suffered from transient side-effects, such as nonrhythmic rapid low amplitude twitches of the left hand and slight clumsiness of the left arm. With a delay of 3 to 4 months, however, involuntary head turning gradually subsided, and after 6 months both dystonic symptoms and side-effects had disappeared completely. The patient resumed her work in a business company. For 30 years, she remained healthy and showed no signs of cervical dystonia. In 2002, she experienced a 2-day period of generalized, involuntary muscle-twitching. Around the same time, she noticed difficulties with writing. In 2005, she noticed involuntary head turning towards the right side, which progressed relatively slowly over several months. Symptoms deteriorated when she walked or during stress. Medical treatment with trihexyphenidyl (2 mg/d) was ineffective. She was referred to our hospital for further assessment and local botulinum toxin injections.

CLINICAL ASSESSMENT AND CURRENT TREATMENT

The neurological examination was inconspicuous, apart from abnormal movements and postures. The patient had intermittent right-sided torticollis up to 80° and a slight right laterocollis with elevation and forward displacement of the right shoulder. Writing was slow, stiff and scrawly. During writing there was dorsal extension of the wrist and abduction of the forearm

and overflow dystonia affecting the right upper arm and shoulder. When stretching out the arms in front the patient showed a moderate dystonic posturing of the left arm, superimposed with mild irregular myoclonic jerks and continuous mild chorea. Currently, overactive neck muscles are treated with local botulinum-toxin injections with an improvement of ~50%.

HIGH-RESOLUTION MRI

To determine the localization relative to stereotactic and anatomical landmarks on the one hand and to estimate the precise extent of the stereotactic lesion on the other, we obtained high-resolution images using 3 Tesla MRI (Trio 3T, Siemens Medical Solutions, Erlangen, Germany). After acquisition of a rapid 3D image localizer, we carried out partial volume scans of T2-weighted, fast spin-echo images (spatial resolution: 1 × 1 × 1 mm³; TR: 5180 ms; TE: 96 ms) in the frontal (Fig. 1A) and horizontal plane (Fig. 1E,G,D), centering upon the visualization of the meso-diencephalic junction. The subsequently acquired sequence of T1-weighted FLASH 3D images (spatial resolution: 1 × 1 × 1 mm³; TR: 15 ms; TE: 4.9 ms) covered the whole brain and allowed for a detailed visualization of the anterior and posterior commissure (AC, PC), and of the 3rd ventricle structures that were used as reference points in the stereotactic intervention (Fig. 1C). We determined the position and boundaries of the coagulation foci, relative to these landmarks (iPlan 1.1, BrainLAB Inc., Westchester, IL). The lesion area was hyperintense on T2-weighted images and hypointense on T1-weighted images with respect to the surrounding brain. To estimate the lesion volume, we used an open-source image navigation and display software.¹⁵ For a definition of the anatomical structures, we used the Schaltenbrand and Bailey atlas with Hassler's delimitation and nomenclature of thalamic structures as a visual guide.¹⁶

STEREOTACTIC RECONSTRUCTION OF THE LESION

A primary lesion was placed beneath the ventral base of the rostral ventral tier thalamic nuclei. This spherical lesion comprised a volume of ca. 90 mm³. The dorsal margin of this lesion was: 13 mm lateral, 2.5 mm posterior, and 2 mm below AC-PC. It had its center 5 mm below the AC-PC plane, 12 mm lateral, and 5 mm posterior to the midcommissural point. The coagulation focus covered a good portion of the caudal ZI, the prelemniscal radiation, and invaded the posterior edge of the STN (Fig. 1A–F). Running antero-

laterally to the red nucleus and posteromedial to the STN, it extended into the prerubral field and covered parts of both the thalamic and mesencephalic part of Forel's field H (Fig. 1G). An arcuated enlargement of the primary coagulation focus was produced by protruding the curved electrode (Fig. 1A–D). This finger-like lesion extended over a distance of ~8 mm along the lateral border of the SN to the cerebral peduncle. It continued lateral to the red nucleus and encroached upon the midbrain tegmentum (coordinates of the lesion center: 10 mm lateral, 10 mm posterior, and 11 mm below AC-PC). On frontal T2-weighted MR images, this lesion appeared as a streak-like extension of the main lesion. It included a volume of ~60 mm³ and covered ~50% of nigral volume (Fig. 1A,G). The most inferior extension of this lesion was 8 mm lateral, 11 mm posterior, and 12.5 mm below AC-PC. In horizontal sections, the right cerebral peduncle appeared slimmer in comparison to the opposite side, indicating fiber degeneration due to affection of descending corticofugal and/or traversing pallidofugal fibers (Fig. 1H).

DISCUSSION

This report demonstrates that unilateral lesioning of the posterior subthalamic region may suffice to completely abolish CD over several decades. We feel it is plausible to relate the clinical course of the present case to the surgical procedure rather than to the natural history of CD. Although spontaneous remissions can occur in primary CD they are quite uncommon and usually patients relapse within 5 years.¹⁷ In our patient, symptoms subsided for 30 years. Also, improvement following surgery was delayed which is the typical scenario following functional surgery in dystonia patients.^{3,11}

In addition to a well documented follow up period of three decades after surgery, this case is remarkable because it offers the opportunity to determine the exact lesion location and to discuss pathophysiological concepts of early stereotactic surgery in the light of modern imaging techniques. The discussion will therefore focus on the potential significance of the structures that were implicated in the described lesion, for CD surgery.

The lesion area comprises Forel's field which resembles campotomies as propagated by Spiegel and Wycis.¹⁰ Because of its close anatomical association with fibers from the dentate nucleus, a lesion in Forel's field will likely have implicated also the cerebellothalamic system.¹⁸

The ZI was involved in the lesion area, particularly its caudal aspect posteromedial to the STN. In addition to

pallidothalamic fiber bundles, ascending fibers originating in the interstitial nucleus of Cajal that pass through or terminate in the region of the ZI are of potential relevance in the context of neurosurgery for CD.^{19,20} The interstitial nucleus has long been implicated in the pathophysiology of CD,^{21,22} since stimulation of both the interstitial nucleus²³ or intersitiothalamic fibers in the ZI region produces rotatory movements in laboratory animals.²⁴

The primary coagulation focus clearly invaded the posterior moiety of the STN. This is of particular interest, since in contrast to contemporary subthalamic surgery, which focuses on the STN proper, earlier subthalamotomies attempted to avoid injury of this nucleus because of concerns to produce hemiballism.

The transient weakness of the left arm occurring postoperatively indicated the affection of corticospinal fibers. However, the impairment of capsular fibers was not sufficient to interfere with the patient's postoperative activity as a secretary. In view of the extensive distribution of pallidofugal fibers in the internal capsule,¹⁸ it appears likely that the present lesion also involved a considerable number of them.

In summary, the present case report demonstrates that isolated lesions of the ZI were hardly possible, since the lesion inevitably affected neighboring structures. It is impossible to determine a single anatomical structure, the destruction of which might be responsible for the long-term beneficial effect on involuntary head movements seen in this patient. However, the common and most prominent anatomical denominator of subthalamic structures implicated in the lesion described here is their close anatomical association to the pallidofugal complex. The lesion has interrupted the bulk of pallidofugal fiber tracts where they pass through the internal capsule at the level of the ZI.

Electrical stimulation of the posterior subthalamic region has recently been shown to alleviate parkinsonian symptoms.^{25,26} The potential efficacy of subthalamic stimulation also for CD surgery is indicated by a recent report of a patient with medically refractory CD, who showed marked improvement of dystonian symptoms following bilateral STN-DBS.¹³

In agreement with previous researchers^{7,9,10,25,27} we hypothesize, that the posterior subthalamic region may be considered a promising target for stereotactic procedures in various movement disorders, including CD.

Acknowledgments: The authors wish to thank K. Mueller for help with acquisition of the MR images and G. Engler and A. Sharott for helpful suggestions concerning the manuscript. The authors thank P. Vogel for referring the patient to our Department.

REFERENCES

1. Fahn S, Bressman SB, Marsden CD. Classification of dystonia. *Adv Neurol* 1998;78:1–10.
2. Riechert T. Stereotactic brain operations. Methods, clinical aspects, indications. Bern, Stuttgart, Vienna: Huber; 1980.
3. Bittar RG, Yianni J, Wang S, et al. Deep brain stimulation for generalised dystonia and spasmodic torticollis. *J Clin Neurosci* 2005;12:12–16.
4. Krauss JK, Pohle T, Weber S, Ozdoba C, Burgunder JM. Bilateral stimulation of globus pallidus internus for treatment of cervical dystonia. *Lancet* 1999;354:837–838.
5. Cooper IS. Effect of thalamic lesions upon torticollis. *N Engl J Med* 1964;270:967–972.
6. Lohr TJ, Pohle T, Krauss JK. Functional stereotactic surgery for treatment of cervical dystonia: review of the experience from the lesional era. *Stereotact Funct Neurosurg* 2004;82:1–13.
7. Andy OJ, Jurko MF, Sias FR, Jr. Subthalamotomy in treatment of Parkinsonian tremor. *J Neurosurg* 1963;20:860–870.
8. Bertrand C, Siegfried J. Extrapyramidal disorders—Session II. Proc 6th Symp Int Soc Res Stereoecephalotomy, Tokyo 1973. *Confin Neurol* 1975;37:9.
9. Mundinger F. Stereotaxic interventions on the zona incerta area for treatment of extrapyramidal motor disturbances and their results. *Confin Neurol* 1965;26:222–230.
10. Spiegel EA, Wycis HT, Szekely EG, Adams DJ, Flanagan M, Baird HW, III. Campotomy in various extrapyramidal disorders. *J Neurosurg* 1963;20:871–884.
11. Mundinger F, Riechert T, Disselhoff J. Long-term results of stereotactic treatment of spasmodic torticollis. *Confin Neurol* 1972;34:41–50.
12. Mundinger F. [New stereotactic treatment of spasmodic torticollis with a brain stimulation system (author's transl)]. *Med Klin* 1977;72:1982–1986.
13. Chou KL, Hurtig HI, Jaggi JL, Baltuch GH. Bilateral subthalamic nucleus deep brain stimulation in a patient with cervical dystonia and essential tremor. *Mov Disord* 2005;20:377–380.
14. Andrew J, Watkins ES. A stereotaxic atlas of the human thalamus and adjacent structures. A variability study. Baltimore: Williams & Wilkins; 1969.
15. Rosset A, Spadola L, Ratib O. OsiriX: an open-source software for navigating in multidimensional DICOM images. *J Digit Imag* 2004;17:205–216.
16. Schaltenbrand G, Bailey P. Introduction to stereotaxis with an atlas of the human brain. Stuttgart: Georg Thieme Verlag; 1959.
17. Dauer WT, Burke RE, Greene P, Fahn S. Current concepts on the clinical features, aetiology and management of idiopathic cervical dystonia. *Brain* 1998;121(Part 4):547–560.
18. Smith MC. Stereotactic operations for Parkinson's disease—anatomical observations. In: Williams D, editor. *Modern trends in neurology*. London: Butterworths; 1967. p 21–52.
19. Hassler R. Über die afferenten Bahnen und Thalamuskern des motorischen Systems des Großhirns. II. Mitteilung *Arch Psychiat Nervenkr* 1949;182:786–818.
20. Kokkoroyannis T, Scudder CA, Balaban CD, Highstein SM, Moschovakis AK. Anatomy and physiology of the primate interstitial nucleus of Cajal I. efferent projections. *J Neurophysiol* 1996;75:725–739.
21. Munchau A, Coma S, Gresty MA, et al. Abnormal interaction between vestibular and voluntary head control in patients with spasmodic torticollis. *Brain* 2001;124(Part 1):47–59.
22. Hassler R, Hess WR. Experimentelle und anatomische Befunde über die Drehbewegungen und ihre nervösen Apparate. *Arch Psychiat Nervenkr* 1954;192:488–526.
23. Klier EM, Wang H, Constantin AG, Crawford JD. Midbrain control of three-dimensional head orientation. *Science* 2002;295:1314–1316.
24. Hyde JE, Toczek S. Functional relation of interstitial nucleus to rotatory movements evoked from zona incerta stimulation. *J Neurophysiol* 1962;25:455–466.
25. Plaha P, Ben-Shlomo Y, Patel NK, Gill SS. Stimulation of the caudal zona incerta is superior to stimulation of the subthalamic nucleus in improving contralateral parkinsonism. *Brain* 2006;129(Part 7):1732–1747.
26. Kitagawa M, Murata J, Uesugi H, et al. Two-year follow-up of chronic stimulation of the posterior subthalamic white matter for tremor-dominant Parkinson's disease. *Neurosurgery* 2005;56:281–289; discussion 281–289.
27. Struppeler A, Lucking CH, Erbel F. Neurophysiological findings during stereotactic operation in thalamus and subthalamus. *Confin Neurol* 1972;34:70–73.

Intact Presupplementary Motor Area Function in Early, Untreated Parkinson's Disease

W. R. Wayne Martin, MD,^{1*} Marguerite Wieler, MSc,¹ Myrlene Gee, PhD,² Christopher C. Hanstock, PhD,² and Richard M. Camicioli, MD¹

¹Division of Neurology, University of Alberta, Edmonton, Alberta, Canada; ²Department of Biomedical Engineering, University of Alberta, Edmonton, Alberta, Canada

Abstract: Although motor symptoms of Parkinson's disease (PD) are initially responsive to dopamine replacement therapy, nonresponsive features develop over time, suggesting that impaired dopaminergic function alone may not be wholly responsible for all the motor features of the disease. Previous studies suggest impaired function in the presupplementary motor area (pre-SMA) in PD. Our objective was to determine whether pre-SMA abnormalities are present in untreated patients with early disease. We measured *N*-acetyl aspartate (NAA)/creatinine (Cr) and choline (Cho)/Cr ratios in pre-SMA in 26 untreated patients with early PD (disease duration 3.0 ± 2.0 yr) and 15 control subjects with single voxel magnetic resonance spectroscopy. Neither NAA/Cr nor Cho/Cr ratios differed significantly between groups. These observations suggest that, although pre-SMA function is impaired in moderately advanced PD, it is relatively spared in early disease. We suggest that pre-SMA dysfunction is in part responsible for the dopamine nonresponsive features associated with disease progression. © 2008 Movement Disorder Society

Key words: Parkinson's disease; supplementary motor area; magnetic resonance spectroscopy

Additional Supporting Information may be found in the online version of this article.

*Correspondence to: Dr. W. R. Wayne Martin, Movement Disorders Clinic, Glenrose Rehabilitation Hospital, 10230-111 Avenue, Edmonton, AB, Canada T5G 0B7. E-mail: wayne.martin@ualberta.ca

Potential conflict of interest: None reported.

Received 17 September 2007; Revised 21 February 2008; Accepted 31 March 2008

Published online 15 August 2008 in Wiley InterScience (www.interscience.wiley.com). DOI: 10.1002/mds.22101

The major pathophysiological substrate underlying the motor dysfunction of Parkinson's disease (PD) is loss of dopaminergic neurons projecting from substantia nigra compacta to striatum and the resulting striatal dopamine depletion. Although many motor symptoms of early PD are responsive to dopamine replacement, over time dopamine nonresponsive features including freezing of gait and impaired balance develop. This suggests that abnormal dopaminergic function alone is not completely responsible for all motor features of the disease.

Cortical motor areas are closely involved in control of normal movement and there is evidence of cortical dysfunction in PD. The presupplementary motor area (pre-SMA) is underactive on functional imaging,¹⁻⁴ and significant loss of pre-SMA neurons has been reported in PD.⁵ We have reported magnetic resonance spectroscopy (MRS) findings from pre-SMA consistent with this neuronal loss in patients with moderately severe disease.⁶ Our objective in the present study was to determine whether pre-SMA changes are present in patients with early, untreated PD.

PATIENTS AND METHODS

Twenty-six patients with early PD were recruited and matched for age and gender with 15 healthy control subjects. All patients fulfilled standard criteria for clinical diagnosis of PD.⁷ None were treated with levodopa, dopamine agonists or other PD medications prior to the completion of the studies described in this article. Clinical signs and symptoms were rated with the Unified Parkinson's Disease Rating Scale (UPDRS)⁸ by one of two raters (MW and WM) with a high inter-rater reliability (intraclass correlation coefficient for motor UPDRS = 0.99, determined in a separate group of PD patients). The study was approved by the Human Research Ethics Board of the University of Alberta; all subjects gave written informed consent.

MRS data were acquired using a Siemens Sonata 1.5T system. Imaging included a sagittal gradient-echo sequence (repetition time (TR) 199 ms, echo time (TE) 4.6 ms, slice thickness 5 mm), a coronal T2-weighted sequence (TR 6330 ms, TE 83 ms, slice thickness 3 mm), and a T1-weighted axial 3D magnetization prepared rapid acquisition gradient echo (MPRAGE) sequence (TR 2120 ms, TE 3.9 ms, TI (inversion time) 1100 ms with 176 slices, each 1 mm thick). After locating the anterior commissure (AC)–posterior commissure (PC) line on a sagittal image, a line perpendicular to the AC–PC line was placed through the AC and a $2 \times 2 \times 2$ cm³ voxel positioned such that its posterior edge abutted the perpendicular with the voxel

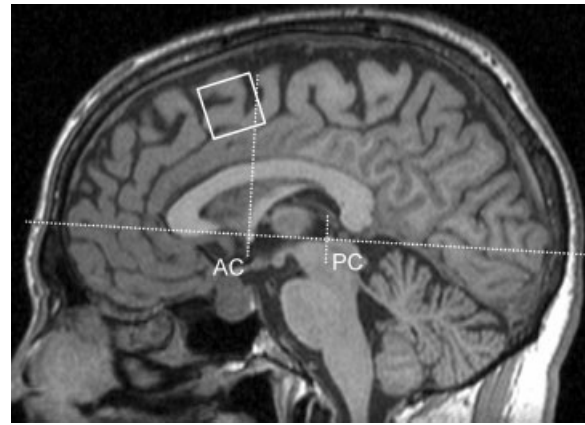


FIG. 1. Sagittal image showing pre-SMA voxel placement. AC, anterior commissure; PC, posterior commissure.

rotated counter clockwise to place its superior border parallel to the cortical surface (see Fig. 1). Coronal and axial images were used to ensure that the voxel was positioned in the midline. Water suppressed spectra were obtained using a PRESS sequence (TR = 1600 ms, TE = 80 ms, 64 averages, 1024 data size) and peak areas calculated with LC model,⁹ a program that accepts the raw MRS data and provides a “black-box” analysis with little user input. The metabolite basis set spectra used for the analysis were generated by numerical simulation. From the peak areas for *N*-acetyl aspartate (NAA), choline (Cho), and creatine/phosphocreatine (Cr), the metabolite ratios NAA/Cr and Cho/Cr were calculated. A typical spectrum from a control subject is illustrated in Figure 2.

The MRS voxel was segmented into its gray matter (GM), white matter (WM), and cerebrospinal fluid (CSF) components using MPRAGE images with SPM2 (<http://www.fil.ion.ucl.ac.uk/spm/>) in Matlab 7.0 (The Mathworks, Natick, MA). The spectroscopy voxel was placed on each segment using an in-house program to transform the coordinates of the voxel into the frame of reference of the segmented images.

Statistical analyses were performed using SPSS version 14.0 for Windows (SPSS, Chicago, IL). Comparisons of controls and patients were made using a two-tailed *t*-test. Relationships between metabolite ratios and UPDRS scores were determined using linear regression; the Pearson correlation coefficient, *r*, is reported. A value of *P* < 0.05 was required for statistical significance.

RESULTS

There was no significant difference with respect to age or gender distribution between patients and con-

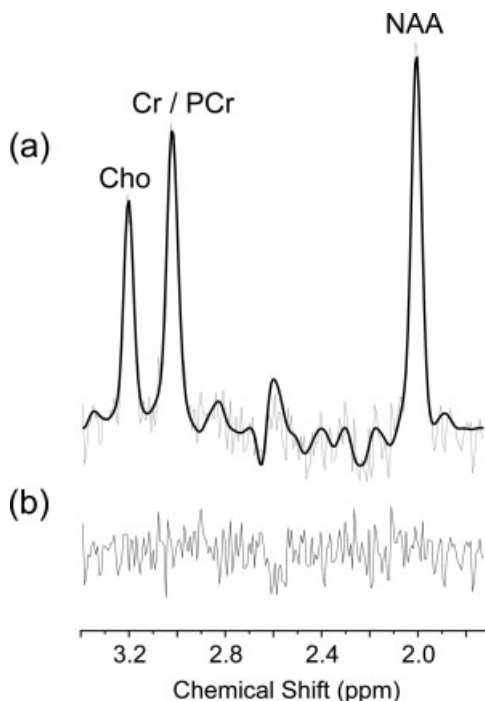


FIG. 2. Proton spectrum from a $2 \times 2 \times 2$ cm³ voxel located on the midline in the region of the supplementary motor area of a control subject. The data shown in (a) highlight the metabolite peaks from *N*-acetylaspartate (NAA), Creatine plus phosphocreatine (Cr/PCr), and choline-containing compounds (Cho) and illustrate both the experimental data (gray) and the LCModel fit (black). The data shown in (b) represent the residual noise following subtraction of the fit from the experimental data.

controls. Disease duration was 3.0 ± 2.0 yr (since symptom onset) and motor UPDRS score 15.1 ± 7.0 . Clinical features are summarized in Table 1.

There was no significant difference in either NAA/Cr (1.50 ± 0.15 vs. 1.48 ± 0.16) or the Cho/Cr (0.70 ± 0.07 vs. 0.68 ± 0.11) ratio between patients and controls. Similarly, segmentation of voxels into GM, WM, and CSF fractions showed no significant difference (GM vol: 4314 ± 811 mm³ vs. 4199 ± 719 mm³; WM vol: 1472 ± 261 mm³ vs. 1423 ± 422 mm³; CSF vol: 2297 ± 803 mm³ vs. 2402 ± 904 mm³). NAA/Cr did not correlate significantly with total, motor, or axial UPDRS scores ($P = 0.235, 0.208, 0.191$, respectively). There was no correlation between NAA/Cr and Hoehn/Yahr score ($P = 0.266$; see Supporting Information Fig. 1). There was a trend toward a correlation between Cho/Cr and clinical features (total UPDRS: $r = 0.36, P = 0.085$; motor UPDRS: $r = 0.39, P = 0.072$; axial UPDRS: $r = 0.36, P = 0.086$). A typical patient spectrum, similar in quality to the normal spectrum in Figure 2, is illustrated in Supporting Information Figure 2.

TABLE 1. Demographics and clinical status

	Controls	Patients
n (female, male)	15 (4, 7)	26 (8, 14)
Age (yrs)	56.8 ± 7.6	60.7 ± 8.5
Years since symptom onset	–	3.0 ± 2.0
UPDRS motor score	–	15.1 ± 7.0
Tremor subscore ^a	–	2.7 ± 2.0
Bradykinesia subscore ^b	–	6.3 ± 3.5
Rigidity subscore ^c	–	3.2 ± 2.2
Axial subscore ^d	–	3.3 ± 1.7
Hoehn and Yahr score	–	1.6 ± 0.5

Figures represent mean \pm SD.

^aUPDRS items 20–21.

^bUPDRS items 23–26, 31.

^cUPDRS item 22.

^dUPDRS items 18, 19, 27–30.

DISCUSSION

This group of patients with untreated PD showed no significant abnormalities in pre-SMA metabolite ratios in comparison to age-matched controls. This is in contrast to our previous study showing reduced NAA/Cr in pre-SMA⁶ in a patient population with longer disease duration. The critical difference in this study was the disease duration of 3.0 ± 2.0 yr (measured from symptom onset) when compared with 8.4 ± 4.4 yr in the previous publication. The second difference is patient age with those in this study having a mean age of 60.7 ± 8.5 yr vs. 71.2 ± 4.4 yr in the previous study. Age difference is unlikely to explain the findings, however, since control group ages (56.8 ± 7.6 yr in this study vs. 71.5 ± 4.9 yr in the previous study) were closely matched to the ages of the patient groups. A third difference is that patients in this study were untreated in contrast to those in the previous study. Lucetti et al. have reported that dopamine agonist treatment can modify motor cortex spectra, normalizing the reduced Cho/Cr ratio that they observed in early PD.¹⁰ We are unaware, however, of any reports of dopaminergic treatment producing the reduction in metabolite ratios that we reported previously.

The trend toward significance in the correlation between Cho/Cr and UPDRS score raises the possibility that membrane turnover increases as PD progresses, perhaps as an early indicator of a neurodegenerative process in pre-SMA. Most brain Cho is bound in membrane phospholipids such as phosphatidylcholine. Bound Cho, however, is not mobile and therefore largely invisible in proton MRS. The Cho peak in proton spectra of the brain is thought to consist largely of cytosolic glycerophosphocholine and phosphocholine, products of membrane breakdown.¹¹ Previous studies in neurodegenerative dementias have also reported

increased Cho/Cr, suggested as being due to increased turnover of membrane constituents.¹²

The nonprimary motor area in area 6 on the postero-medial frontal cortex is divided into SMA proper and pre- or rostral SMA.¹³ Although SMA proper is active in the initiation and execution of movement, pre-SMA is thought to play a role in motor planning and organization of complex movements.^{5,13} Pre-SMA is active prior to movement onset and is likely the source of the early component of the Bereitschaftspotential, which precedes voluntary movement by a second or more.¹⁴ Brain imaging studies have implicated the pre-SMA in motor task learning with a correlation between pre-SMA activity and the complexity of a learned motor sequence.¹⁵

Abnormal pre-SMA function has been reported in PD. Changes in the Bereitschaftspotential are present, with a pattern suggesting a failure of pre-SMA activation.¹⁴ Decreased pre-SMA activation,² reversible by levodopa administration in patients with early disease,^{16,17} is evident with functional imaging. Although a significant loss of cortico-cortical projecting pyramidal neurons from the pre-SMA has been reported in PD, this observation was based on pathology from patients with a long duration of disease.⁵

Our data are consistent with the notion that although pre-SMA activity is preserved in early PD, abnormalities develop with disease progression. We suggest that pre-SMA dysfunction may be in part responsible for the development of dopamine nonresponsive motor features associated with disease progression.

Acknowledgments: This work was supported by the Canadian Institutes for Health Research. We gratefully acknowledge the willing cooperation of our subjects.

REFERENCES

1. Fukuda M, Mentis M, Ma Y, et al. Networks mediating the clinical effects of pallidal brain stimulation for Parkinson's disease: a PET study of resting-state glucose metabolism. *Brain* 2001; 124:1601–1609.
2. Sabatini U, Boulanouar K, Martin F, et al. Cortical motor reorganization in akinetic patients with Parkinson's disease: a functional MRI study. *Brain* 2000;123:394–403.
3. Thobois S, Dominey P, Decety J, et al. Motor imagery in normal subjects and in asymmetrical Parkinson's disease: a PET study. *Neurology* 2000;55:996–1002.
4. Cunnington R, Egan G, O'Sullivan J, Hughes A, Bradshaw J, Colebatch J. Motor imagery in Parkinson's disease: a PET study. *Mov Disord* 2001;16:849–857.
5. Macdonald V, Halliday GM. Selective loss of pyramidal neurons in the presupplementary motor cortex in Parkinson's disease. *Mov Disord* 2002;17:1166–1173.
6. Camicioli RM, Hanstock CC, Bouchard TP, Gee M, Fisher NJ, Martin WRW. Magnetic resonance spectroscopic evidence for presupplementary motor area neuronal dysfunction in Parkinson's disease. *Mov Disorders* 2007;22:382–386.
7. Calne DB, Snow BJ, Lee C. Criteria for diagnosing Parkinson's disease. *Ann Neurol* 1992;32(Suppl):S125–S127.
8. Fahn S, Elton RL. Unified Parkinson's Disease Rating Scale. In: Fahn S, Marsden CD, Goldstein M, Calne DB, editors. *Recent developments in Parkinson's disease*, Vol. 2. Florham Park, NJ: Macmillan Healthcare; 1987. p 153–163.
9. Provencher SW. Estimation of metabolite concentrations from localized in vivo proton NMR spectra. *Magn Reson Med* 1993; 30:672–679.
10. Lucetti C, Del Dott P, Gambaccini G, et al. Influences of dopaminergic treatment on motor cortex in Parkinson disease: a MRI/MRS study. *Mov Disord* 2007;22:2170–2175.
11. Klein J. Membrane breakdown in acute and chronic neurodegeneration: focus on choline-containing phospholipids. *J Neural Transm* 2000;107:1027–1063.
12. Kantarci K, Petersen RC, Boeve BF, et al. ¹HMR spectroscopy in common dementias. *Neurology* 2004;63:1393–1398.
13. Picard N, Strick PL. Imaging the premotor areas. *Curr Opin Neurobiol* 2001;11:663–672.
14. Colebatch JG. Bereitschaftspotential and movement-related potentials: origin, significance, and application in disorders of human movement. *Mov Disord* 2007;22:601–610.
15. Boecker H, Dagher A, Ceballos-Baumann AO, et al. Role of the human rostral supplementary motor area and the basal ganglia in motor sequence control: investigations with H215O PET. *J Neurophysiol* 1998;79:1070–1080.
16. Haslinger B, Erhard P, Kampfe N, et al. Event-related functional magnetic resonance imaging in Parkinson's disease before and after levodopa. *Brain* 2001;124:558–570.
17. Buhmann C, Glauche V, Stürenburg HJ, Oechsner M, Weiller C, Büchel C. Pharmacologically modulated fMRI–cortical responsiveness to levodopa in drug-naive hemiparkinsonian patients. *Brain* 2003;126:451–461.

Reversal of Head Drop After Discontinuation of Olanzapine in a DLB Patient

Marcel J.H. Aries, MD,¹ Hans Debruyne, MD,¹
 Sebastiaan Engelborghs, MD, PhD,^{1,2,3,4}
 Nathalie Le Bastard, MSc,² Nore Somers, MSc,¹
 Dagmar Gorissen, MD,⁵ Barbara A. Pickut, MD,^{1,4}
 and Peter Paul De Deyn, MD, PhD^{1,2,4*}

¹Department of Neurology and Memory Clinic, ZNA-Middelheim and ZNA-Hoge Beuken, Antwerp, Belgium;

²Laboratory of Neurochemistry and Behaviour, Department of Biomedical Sciences, Institute Born-Bunge, University of Antwerp, Antwerp, Belgium; ³Department of Nursing Sciences, Faculty of Medicine, University of Antwerp, Antwerp, Belgium; ⁴Department of Health Care Sciences, University College, Antwerp, Belgium;

⁵Department of Physical Medicine and Rehabilitation, ZNA-Middelheim and ZNA-Hoge Beuken, Antwerp, Belgium

Video



Abstract: We present a 72-year-old patient with probable diffuse Lewy body disease and visual hallucinations, who developed subacute reversible “dropped head syndrome” and parkinsonian signs after the introduction of olanzapine at a total daily dose of 10 mg. One week after olanzapine was withdrawn, the patient’s posture started to improve. Further improvement was achieved after dopaminergic substitution. Clinical and electrophysiological observations might indicate neck extensor myopathy due to axial rigidity or focal neck dystonia, induced by dopamine receptor blockade.

© 2008 Movement Disorder Society

Key words: diffuse Lewy body disease; olanzapine; dropped head syndrome; axial rigidity; dystonia

The term “dropped head syndrome” refers to a condition characterized by severe weakness of the neck extensors, resulting in neck flexion. Dropped head is often part of a generalized neuromuscular disorder such as myasthenia gravis, polymyositis, or amyotro-

phic lateral sclerosis. Antecollis has also been described in multiple system atrophy and Parkinson’s disease. The term “isolated neck extensor myopathy” is used when no underlying etiology is identified.^{1–3} The pathogenesis of dropped head syndrome among extrapyramidal disorders is still under debate. Present case series are not conclusive with regard to suggested mechanisms like noninflammatory myopathy, rigidity, traction injury, and axial dystonia.^{1,4–6}

CASE REPORT

A 72-year-old woman was admitted to a geriatric ward of a general hospital due to severe confusion, delusions, and visual hallucinations, which had been seen for 3 weeks. As a psychotic depression was suspected, the patient’s general practitioner started the atypical antipsychotic agent olanzapine that was uptitrated to a total daily dose of 10 mg. Noticeable head flexion started after 2 days of olanzapine treatment. Her medical history revealed depression and anxiety disorder, treated with various antidepressants. The family reported a progressive fluctuating cognitive decline, which had progressed over the period of 1 year with prominent delusions. Two years earlier, the patient had experienced well-formed visual hallucinations that disappeared spontaneously after less than 1 week. Bradykinesia had been observed for about 1 year. At our memory clinic, the atypical antipsychotic was withdrawn in 9 days after its start. At that time, the patient was still in a severe confusional state and could lift her head maximally 20° from her chest. The MMSE score at admission was 6 of 30. Her neck rigidity was severe and painful, particularly in case of passive backward extension. The head was slightly rotated to the right side (see video, Segment 1). The sternocleidomastoid (SCM), trapezius, and splenius muscles did not reveal apparent muscle contractions on palpation. In addition, the clinical neurological examination showed bradykinesia, shuffling gait with festination, bilateral cogwheel rigidity, and postural instability. Laboratory results revealed the increased serum creatine kinase (CK) levels of 3.500 U/L (normal range: 50–150 U/L), which completely normalized during the next 2 days. Our patient was diagnosed as suffering from probable diffuse Lewy body disease (DLB), according to the consensus guidelines for the clinical diagnosis of DLB.⁷ In addition, a cervical collar was given, and rivastigmine was uptitrated to a total daily dose of 12 mg, with a beneficiary effect on the visual hallucinations.

Additional Supporting Information may be found in the online version of this article.

*Correspondence to: Dr. Peter Paul De Deyn, Laboratory of Neurochemistry and Behaviour, Institute Born-Bunge, University of Antwerp, Universiteitsplein 1, BE-2610 Antwerp, Belgium.
 E-mail: peter.dedejn@ua.ac.be

Potential conflict of interest: None reported.

Received 5 December 2007; Revised 27 February 2008; Accepted 19 March 2008

Published online 25 July 2008 in Wiley InterScience (www.interscience.wiley.com). DOI: 10.1002/mds.22182

Twenty-two days after the onset of the dropped head syndrome, electromyography showed spontaneous muscle activity consisting of positive sharp waves, fibrillation potentials, and complex repetitive discharges in cervical paraspinal muscles. One week after olanzapine was withdrawn, the patient's posture started to improve slightly (see video, Segment 2). Close observation revealed that the patient was able to drink with nearly full neck extension, which might be interpreted as being a sensory trigger (see video, Segment 3). Two weeks after olanzapine was withdrawn, we prescribed a total daily dose of 375-mg benserazide-levodopa because of disabling painful axial rigidity. After 5 weeks of treatment, the improvement of head flexed posture and motor symptoms was remarkable, though fluctuating during the day. Rigidity of dorsal cervical muscles with head ptosis was noticed when lying in a supine position (see video, Segment 4). Repeated needle electromyography disclosed marked myopathic changes in cervical paraspinal muscles and sustained contraction of right splenius capitis muscle.

Entacapone was added at a total daily dose of 600 mg because of peak dose dyskinesias, following the dose increment of L-dopa. After 10 weeks, the patient's posture continued to improve to the point of an approximation of a classical parkinsonian slightly flexed stance (see video, Segment 5). Aripiprazole 10 mg was deemed necessary to treat persistent delusions with good clinical results and no subsequent increase in extrapyramidal symptoms or dropped head in the subsequent 7 months.

DISCUSSION

Different factors may contribute to the pathophysiology of the disabling anterior curvature of the cervical spine in Parkinsonism. In this case, we considered a malignant neuroleptic syndrome (MNS) or an acute myopathy of dorsal neck muscles to explain muscle weakness, elevated CK levels, and persistent rigidity.⁸ The CK levels values, however, normalized within 2 days, and hyperthermia and autonomic dysregulations were lacking, making the diagnosis of MNS, unlikely. In our patient, repeatedly, electromyography showed myopathic changes in paravertebral extensor muscles, suggesting a plausible explanation for head ptosis. A monophasic noninflammatory process restricted to the paraspinal musculature has been suggested by several authors.^{3,5,6} However, these changes may be nonspecific or secondary, resulting from mechanical strain rather than a specific myopathic disorder.^{3,4}

Psychotic symptoms in DLB patients are particularly difficult to treat due to their extreme sensitivity to anticholinergic and antidopaminergic medications. This increased sensitivity could be due to the relative loss of dopaminergic neurons, particularly in the substantia nigra, and the failure of postsynaptic striatal neurons to upregulate D2 receptors in response to a dopaminergic deficit or D2-blocking drugs.⁹ The dropped head syndrome was probably induced by the atypical antipsychotic olanzapine, as symptoms improved after withdrawal of the antipsychotic. The coexistence with extrapyramidal signs and the effects of dopaminergic replacing medication suggest another provoking and sustaining factor than the myopathy. An unbalanced muscle rigidity between the anterior and the posterior neck muscles is suspected, which was supported by surface EMG of the neck showing that reflex muscle activity of SCM muscles was elicited during the act of neck extension.¹⁰ Neck examination in our patient indeed revealed the fluctuating painful axial rigidity, and video segment 3 shows that the patient was not able to extend the neck in supine position. Also, the theory of a focal dystonia has been proposed.¹¹ Although convincing dystonic spasms of the anterior neck muscles, as in our patient, are often lacking, clinically undetectable contractions in deep neck flexor musculature might be relevant. Improvement of dropped head by drinking suggests the presence of sensory trigger mechanisms as described in cervical dystonia.¹² In our patient, sustained contraction of the right neck rotator splenius capitis might have been indicative for cervical dystonia in deeper anterior neck muscles. Another possible explanation is suggested in a recent publication showing that in 23 of 38 treatment-naive patients with torticollis, the SCM to be activated failed to work adequately during an effort to achieve maximum rotation to the contralateral direction of torticollis (so-called negative dystonia).¹³ This can explain why a subset of Parkinson patients, with a well-preserved strength of paraspinal muscles, show prominent dropped head.¹

To the best of our knowledge, this is the first case report of reversible dropped head syndrome in DLB. In 2006, an analog case report described a depressive patient who developed mild parkinsonian signs and camptocormia after the introduction of olanzapine.¹¹ Similarities between dropped head and camptocormia, which are characterized by anterior curvature of the thoracolumbar spine, suggest similar pathophysiological processes affecting the paraspinal muscles of different parts of the spine.⁴

LEGENDS TO VIDEO

Segment 1. Seven days after treatment with olanzapine, severe head ptosis is present. The patient can lift her head maximally 20°. The head is slightly rotated to the right side. Backward extension of the neck is limited and painful.

Segment 2. One week after olanzapine was withdrawn, the patient's posture started to improve slightly. Backward extension is still limited.

Segment 3. Ten days after olanzapine withdrawal, further spontaneous improvement was noticed, with the patient being able to drink with nearly full neck extension, indicating a sensory trigger.

Segment 4. Painful rigidity of dorsal cervical muscles is noticed when lying in a supine position.

Segment 5. Ten weeks after the olanzapine was withdrawn, the patient's posture continued to improve to a classical parkinsonian slightly flexed stance.

Acknowledgments: This research was supported by the Special Research Fund of the University of Antwerp, Stichting Alzheimer Onderzoek, the Thomas Riellaerts Research Fund, the Institute Born-Bunge, the agreement between the Institute Born-Bunge and the University of Antwerp, the central Biobank facility of the Institute Born-Bunge, University of Antwerp, Medical Research Foundation Antwerp, Neurosearch Antwerp, the Fund for Scientific Research, Flanders (FWO-F) (grant no G.0127.07), and the Institute for Promotion of Innovation through Science and Technology in Flanders (IWT-Vlaanderen). NLB is a PhD fellow of the FWO-F/L'Oréal-UNESCO, and SE is a postdoctoral fellow of the FWO-F. We are grateful to Mr. F. van Coppenolle (University of Antwerp) for the photographic work.

REFERENCES

1. Kashira K, Ohno M, Tomito S. Dropped head syndrome in Parkinson's disease. *Mov Disord* 2006;21:1213–1216.
2. Fujimoto K. Dropped head in Parkinson's disease. *J Neurol* 2006;253:21–26.
3. Katz JS, Wolfe GI, Burns DK, Bryan WW, Fleckenstein JL, Barohn RJ. Isolated neck extensor myopathy: a common cause of dropped head syndrome. *Neurology* 1996;46:917–921.
4. Umaphathi T, Chaudhry V, Cornblath D, Drachman D, Griffin J, Kuncic R. Head drop and camptocormia. *J Neurol Neurosurg Psychiatry* 2002;73:1–7.
5. Ashmark H, Eeg Olafsson KE, Johansson A, et al. Parkinson and neck extensor myopathy: a new syndrome or coincidental findings? *Arch Neurol* 2001;58:232–237.
6. Oerlemans WGH, Visser de M. Dropped head syndrome and bent spine syndrome: two separate clinical entities or different manifestations of axial myopathy. *J Neurol Neurosurg Psychiatry* 1998;65:258–259.
7. McKeith IG, Galasko D, Kosaka K, Perry EK, Dickson DW, Hansen LA. Consensus guidelines for the clinical and pathologic diagnosis of dementia with Lewy bodies (DLB): report of the consortium on DLB international workshop. *Neurology* 1996;47:1113–1124.
8. Adityanjee, Sajatovic M, Munshi KR. Neuropsychiatric sequelae of neuroleptic malignant syndrome. *Clin Neuropharmacol* 2005;28:197–204.
9. Baskys A. Lewy body dementia: the litmus test for neuroleptic sensitivity and extrapyramidal symptoms. *J Clin Psychiatry* 2004;65:16–22.
10. Vela L, Moron DJ, Sanchez C, Pareja JA, Baron M. Camptocormia induced by atypical antipsychotics and resolved by electroconvulsive therapy. *Mov Disord* 2006;21:1977–1979.
11. Yoshiyama Y, Takama J, Hattori T. The dropped head sign in Parkinsonism. *J Neurol Sci* 1999;167:22–25.
12. Schramm A, Reiners K, Naumann M. Complex mechanisms of sensory tricks in cervical dystonia. *Mov Disord* 2004;19:452–458.
13. Mezaki T. Dystonia redefined as central non-paretic loss of control of muscle action: a concept including inability to activate muscles required for a specific movement, or 'negative dystonia'. *Med Hypotheses* 2007, doi:10.1016/j.mehy.2007.03.014.

Hemidystonia Secondary to Thalamic Hemorrhage Treated with GPi Stimulation

Tadashi Hamasaki, MD, PhD,* Kazumichi Yamada, MD, PhD, and Jun-ichi Kuratsu, MD, PhD

Department of Neurosurgery, Kumamoto University Medical School, Honjo, Kumamoto, Japan

Abstract: There have been few reports on the surgical treatment of secondary hemidystonias, most of which are due to basal ganglia stroke or trauma. We present 2 patients with hemidystonia secondary to thalamic hemorrhage whom we successfully treated with unilateral globus pallidus internus (GPi) stimulation. Case 1 is a 56-year-old man with abnormal posturing and intolerable muscle contraction pain in the left arm. Case 2 is a 73-year-old woman who developed severe abnormal posturing in the right arm and gait disturbance due to hyperextension of the right leg. The dystonic symptoms of both patients were refractory to medication. Three months after the inception of high frequency GPi stimulation, the motor scores on the Burke-Fahn-Marsden Dystonia Rating Scale were improved by 49.2% and 34.3% in Cases 1 and 2, respectively. We suggest GPi stimulation as a possible alternative to treat secondary hemidystonia. © 2008 Movement Disorder Society

Key words: GPi-DBS; thalamus; secondary hemidystonia

Additional Supporting Information may be found in the online version of this article.

*Correspondence to: Dr. Tadashi Hamasaki, Department of Neurosurgery, Kumamoto University Medical School, 1-1-1 Honjo, Kumamoto 860-8556, Japan. E-mail: thamasaki-nsu@umin.ac.jp

Received 8 February 2008; Revised 8 April 2008; Accepted 22 May 2008

Published online 25 July 2008 in Wiley InterScience (www.interscience.wiley.com). DOI: 10.1002/mds.22183

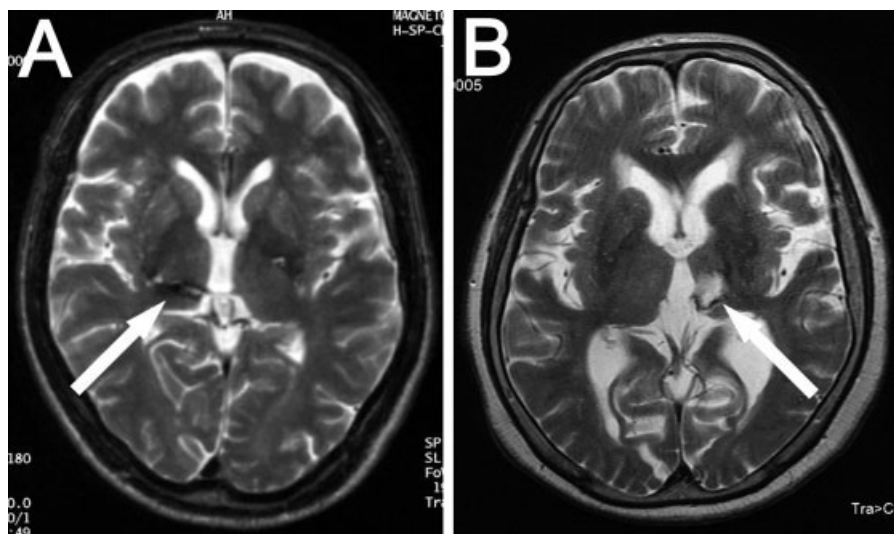


FIG. 1. Magnetic resonance images obtained at admission. (A) Case 1. (B) Case 2. Arrows indicate scar lesions in the medial to posterior portion of the thalamus. Thalamic atrophy is apparent in both cases.

Most hemidystonias develop after a latency period as a result of insults affecting the contralateral brain^{1,2} and abnormal postures and movements have a deleterious effect on the activities of daily life. Reported etiologies include stroke, trauma, perinatal injury, infection, brain tumor, and arterio-venous malformation, located in the basal ganglia, thalamus, cerebral cortex, or internal capsule.² Medical treatment is ineffective in most cases although benzodiazepines and anti-cholinergic agents may produce some effect.²⁻⁵ Few patients benefit from the injection of botulinum toxin A because the affected muscles are distributed widely in the body.

Deep brain stimulation (DBS) of the globus pallidus internus (GPi) represents a powerful alternative for the treatment of medically refractory dystonia such as generalized⁶ and segmental dystonia.⁷ However, controversy continues to surround the effectiveness of GPi-DBS in other dystonia subtypes. We present 2 patients with hemidystonia secondary to thalamic hemorrhage who were effectively treated with GPi-DBS.

PATIENTS AND METHODS

Case Presentation

Case 1: This 56-year-old man who suffered a right thalamic hemorrhage at the age of 52 (Fig. 1A) noticed abnormal posturing of the left arm and leg 3 months after the hemorrhage. He subsequently developed excessive muscle contraction and associated muscle pain in the left shoulder and arm. Medication including clonazepam and carbamazepine was minimally effective.

On our initial examination, he was alert and well-oriented. Cranial nerve study returned unremarkable results. His left arm and leg were mildly weak with spastic tone and hyperreflexia. The dystonic posture primarily affected his left hand with hyperextension of all fingers (videotape segment 1). Forced abduction of the left upper arm, flexion of the forearm, and hyperextension of the leg were observed especially during walking. There was mild sensory loss on the left side. He reported severe muscle pain distributed over the face, neck, shoulder, and proximal part of the arm. His preoperative motor score on the Burke-Fahn-Marsden Dystonia Rating Scale (BFMDRS) was 29.5 (Fig. 2A).

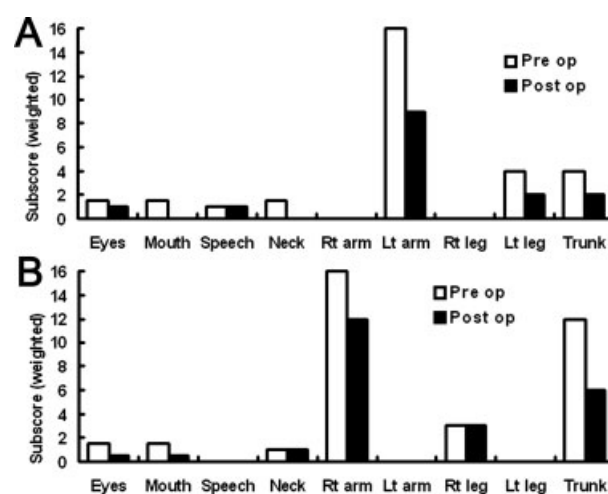


FIG. 2. Preoperative and postoperative motor scores on the Burke-Fahn-Marsden Dystonia Rating Scale. (A) Case 1. (B) Case 2.

Case 2: This 73-year-old woman developed a left thalamic hemorrhage (Fig. 1B) when she was 63 years old. Several months later, she noticed abnormal posturing of the right arm; it was initially intermittent but progressed over the course of several years despite medical therapy including clonazepam. On admission, her mental status was normal. She had difficulty in opening her eyes due to tonic and phasic contraction of the face muscles. Her right arm and leg were mildly weak. There was a strong tendency for adduction with internal rotation of the upper right arm and flexion of the forearm. This forced her arm behind her back even at rest (videotape segment 3). She had no sensory disturbances. Her gait was severely disturbed primarily due to hyperextension of the right leg. Her preoperative BFMDRS motor score was 35 (Fig. 2B).

Both patients provided prior written informed consent for the acquisition and offline and/or online distribution of preoperative and postoperative videotape.

Surgery

Case 1: Magnetic resonance imaging (MRI)-guided stereotactic surgery was performed under local anesthesia with selective 3rd ventriculography and microelectrode recording.⁸ The target was the right GPi, which we assumed to be at a point 20 mm lateral to the midline, 2 mm anterior to the mid-commissure point, and 1 mm dorsal to the floor of the 3rd ventricle. The most ventral contact of a quadripolar DBS electrode (Model 3387, Medtronic) was placed in the most ventral part of the GPi with the aid of microelectrode recording.

Case 2: Left GPi-DBS was performed; except for the use of Framelink (Medtronic) to calculate the coordinates, the procedure was as in Case 1. Test stimulation at the tentative target (2 mA, 100 μ sec, 100 Hz) elicited immediate effect and she could open her hand more easily.

RESULTS

Test stimulation via the implanted electrodes alleviated the excessive muscle contractions and associated muscle pain in the left arm in Case 1 and improved somewhat the forced abnormal posturing of the right arm in Case 2. After a few days of test stimulation, a pulse generator (SOLETRA Model 7426, Medtronic) was implanted subcutaneously in the subclavian region. There were no adverse effects or deterioration of neurological symptoms attributable to the surgical procedures.

In Case 1, the stimulation parameters at discharge were: bipolar stimulation with contact 1(-) 2(+), 130 Hz, pulse duration 210 μ sec, and amplitude 0.3V. The active contacts were subsequently moved to a more ventral position and the voltage was increased [contact 0(-) 1(+), 210 μ sec, 130 Hz, and 1.5–1.8 V] because these settings most effectively alleviated the dystonic posture. With respect to his muscle contraction pain, the visual analogue scale was improved by 80%. The abnormal posturing of his left arm was improved significantly during movement and even at rest (videotape segment 2). Three months after the inception of GPi-DBS, his BFMDRS motor score was 15, representing a 49.2% improvement over his preoperative score of 29.5 (Fig. 2A). At the latest visit 22 months postoperatively, his dystonic symptoms in the left extremities and associated muscle pain were similar to those three months after surgery.

In Case 2, the initial stimulation parameters were as follows: unipolar stimulation with Case (+), contact 0(-) 1(-), 130 Hz, pulse duration 450 μ sec, and amplitude 2.4 V. A subsequent decrease in the voltage to 2.0 V elicited no deterioration of her dystonic symptoms. Her facial dystonia was improved. The abnormal posturing of her right arm was improved moderately and she was able to move her arm unassisted from the back to the side of the trunk (videotape segment 4). She continued to exhibit severe gait disturbance although it was slightly improved with some improvement of the hyperextension of her right leg. Three months after the start of unilateral GPi-DBS, her BFMDRS motor score was 23, constituting a 34.3% improvement over her preoperative score of 35 (Fig. 2B). At the latest visit 10 months postoperatively, the patient's condition was unchanged compared with that observed 3 months postoperatively, except for the arm dystonia slightly worsened.

DISCUSSION

We used the BFMDRS to evaluate the effectiveness of unilateral GPi-DBS in patients with hemidystonia secondary to thalamic hemorrhage. The improvement rates were inferior to that we achieved in other dystonia subtypes where the average rate of improvement was 98% for DYT1 generalized dystonia,⁹ 87% for tardive dystonia,¹⁰ 80% for segmental axial dystonia,¹¹ and 69% for primary cervical dystonia (unpublished observation). It is worth noting that the effectiveness of GPi-DBS was more modest in Case 2 where the dis-

ease duration was longer than that of Case 1. This supports the observation of Ochiai et al.¹² that the better improvement can be achieved in the patients with shorter (less than 5 years) disease duration. As was true in our case, a pulse duration exceeding 200 μ sec was more effective than shorter durations.^{11,13,14}

Of 29 patients treated by stereotactic surgery in the literature, only 5 patients with secondary hemidystonia underwent GPI stimulation.^{2,15} Fernandez et al.¹⁶ reported a patient with Benedikt's syndrome who developed hemidystonia as a complication of microvascular decompression for trigeminal neuralgia. They performed GPI-DBS because the adverse effects were greater than the beneficial effects of benzodiazepine. However, dystonia was improved significantly for only 1–3 hour after the start of stimulation. Loher et al.¹⁷ reported a patient with hemidystonia due to severe closed head injury. On the basis of clinical symptoms they postulated that the lesion responsible for dystonia was in the upper brain stem, however, MRI demonstrated no focal lesion. GPI-DBS was performed 9 years after the injury because neither medication nor thalamotomy was effective. They reported marked improvement of their patient's hemidystonia and associated pain 2 months after the inception of GPI-DBS with sustained improvement 4 years after surgery. Their report is unique in that GPI stimulation was effective despite the prolonged disease duration. However, these early surgical cases were not informative in terms of fine adjustments of the stimulation parameters and they did not report postoperative quantitative evaluation of the dystonia symptoms. In their series of 10 cases with generalized dystonia, Diamond et al.¹⁸ encountered a patient with hemidystonia secondary to a basal ganglia hemorrhage. GPI-DBS produced a 22.2% improvement on the Unified Dystonia Rating Scale (UDRS). The mean rate of improvement in our 2 cases was 42%, indicating that GPI stimulation can be used to address secondary hemidystonia although compared to other dystonia subtypes, the results may be inferior.

A number of clinical and experimental studies support the concept that dystonia is a disorder of sensorimotor integration.¹⁹ According to Murase et al.,²⁰ electrophysiological studies suggested that patients with dystonia encounter problems in interpreting proprioceptive sensory inputs before or during movement. Indeed, in 22 patients with thalamic stroke, analysis of three-dimensional MRI showed that the Vc was one of the thalamic nuclei more frequently lesioned in patients with dystonia than patients without involuntary movement.²¹ In our cases, insult to the thalamic sensory

nuclei (Fig. 1) and possibly subsequent aberrant reorganization of the somatosensory pathway³ may have resulted in abnormal sensory inputs to the somatosensory area, producing a fixed input–output mismatch in the “motor subroutine”²² dedicated to movement on the contralateral side of the body.

In conclusion, our surgical results suggest that GPI-DBS is a possible alternative to treat secondary hemidystonia although reports of surgical cases are still scarce. Studies on more patients are underway in our laboratory to identify optimum parameter settings and long-term outcomes, and to compare the course of treated patients with the natural course of secondary hemidystonia.

LEGENDS TO THE VIDEOTAPE

Segment 1. Case 1: Preoperatively, this 56-year-old man with a history of right thalamic hemorrhage (Case 1) exhibits dystonic posturing of the left hand and arm at rest and during movement. Hyperextension of the left leg is also observed during walking.

Segment 2. Fourteen days after the inception of right GPI-DBS, there was alleviation of his dystonic postures and movements, and he is able to open his left hand and to stand straight. His dystonic pain on the left side of the face and left shoulder has almost disappeared. His BFMDRS motor score is improved by 49.2%.

Segment 3. Case 2: Preoperatively, this 73-year-old woman with a history of left thalamic hemorrhage exhibits severe dystonic posture of the right arm. It is forced behind her back even at rest. Her right face and leg are moderately affected.

Segment 4. After two weeks of continuous stimulation of the left GPI, her dystonic symptoms are significantly alleviated. Her BFMDRS motor score is improved by 34.3%.

Acknowledgments: We thank Drs. T. Takezaki and R. Kojima for their assistance with the surgery, and the preoperative and postoperative evaluation of the patients. K. Yamada and T. Hamasaki did the research project, surgery, and the data analysis. T. Hamasaki prepared the first draft of this manuscript. Review and critique were done by K. Yamada and J. Kuratsu.

REFERENCES

1. Pettigrew LC, Jankovic J. Hemidystonia: A report of 22 patients and review of the literature. *J Neurol Neurosurg Psychiatry* 1985;48:650–657.
2. Chuang C, Fahn S, Frucht SJ. The natural history and treatment of acquired hemidystonia: report of 33 cases and review of the literature. *J Neurol Neurosurg Psychiatry* 2002;72:59–67.

3. Burke RE, Fahn S, Gold AP. Delayed-onset dystonia in patients with "static" encephalopathy. *J Neurol Neurosurg Psychiatry* 1980; 43:789–797.
4. Factor SA, Sanchez-Ramos J, Weiner WJ. Delayed-onset dystonia associated with corticospinal tract dysfunction. *Mov Disord* 1988;3:201–210.
5. Nardocci N, Zorzi G, Grisoli M, Rumi V, Broggi G, Angelini L. Acquired hemidystonia in childhood: a clinical and neuroradiological study of 13 patients. *Pediatric Neurol* 1996;15:108–113.
6. Vidailhet M, Vercueil L, Houeto JL, et al. French Stimulation du Pallidum Interne dans la Dystonie (SPIDY) Study Group. Bilateral deep-brain stimulation of globus pallidus in primary generalized dystonia. *N Eng J Med* 2005;352:459–467.
7. Wöhrle JC, Weigel R, Grips E, Blahak C, Capelle HH, Krauss JK. Risperidone-responsive segmental dystonia and pallidal deep brain stimulation. *Neurology* 2003;61:546–548.
8. Goto S, Yamada K. Long term continuous bilateral pallidal stimulation produces stimulation independent relief of cervical dystonia. *J Neurol Neurosurg Psychiatry* 2004;75:1506–1507.
9. Goto S, Yamada K, Shimazu H, et al. Impact of bilateral pallidal stimulation on DYT1-generalized dystonia in Japanese patients. *Mov Disord* 2006;21:1785–1787.
10. Yamada K, Goto S, Yoshida S, et al. Bilateral pallidal stimulation for tardive dystonia. *Funct Neurosurg* 2005;44:115–119.
11. Muta D, Goto S, Nishikawa S, et al. Bilateral pallidal stimulation for idiopathic segmental dystonia advanced from Meige syndrome refractory to bilateral thalamotomy. *Mov Disord* 2001;16:774–777.
12. Ochiai T, Taira T, Goto S, Hayashi M, Hori T. An effect and indication of GPI-DBS for dystonia—from experience of 41 GPI-DBS cases. *Funct Neurosurg* 2007;46:166–170.
13. Kumar R, Dagher A, Hutchison WD, Lang AE, Lozano AM. Globus pallidus deep brain stimulation for generalized dystonia: clinical and PET study. *Neurology* 1999;53:871–874.
14. Coubes P, Roubertie A, Vayssiere N, Hemm S, Echenne B. Treatment of DYT1-generalized dystonia by stimulation of the internal globus pallidus. *Lancet* 2000;355:2220–2221.
15. Hutchison WD, Lang AE, Dostrovsky JO, Lozano AM. Pallidal neuronal activity: implications for models of dystonia. *Ann Neurol* 2003;53:480–488.
16. Fernandez HH, Friedman JH, Centofanti JV. Benedikt's syndrome with delayed-onset rubral tremor and hemidystonia: a complication of Douloureux surgery. *Mov Disord* 1999;14:695–697.
17. Lohr TJ, Hasdemir MG, Burgunder JM, Krauss JK. Long-term follow-up study of chronic globus pallidus internus stimulation for posttraumatic hemidystonia. *J Neurosurg* 2000;92:547–460.
18. Diamond A, Shahed J, Azher S, Dat-Vuong K, Jankovic J. Globus pallidus deep brain stimulation in dystonia. *Mov Disord* 2006;21:692–694.
19. Abbruzzese G, Berardelli A. Sensorimotor integration in movement disorders. *Mov Disord* 2003;18:231–240.
20. Murase N, Kaji R, Shimizu H, et al. Abnormal premovement gating of somatosensory input in writer's cramp. *Brain* 2000; 123:1813–1829.
21. Lehericy S, Grand S, Pollak P, et al. Clinical characteristics and topography of lesions in movement disorders due to thalamic lesions. *Neurology* 2001;57:1055–1066.
22. Kaji R, Shibasaki H, Kimura J. Writer's cramp: a disorder of motor subroutine? *Ann Neurol* 1995;38:837–838.

Autonomic Dysfunction in Different Subtypes of Multiple System Atrophy

Claudia Schmidt, MD,¹ Birgit Herting, MD,²
 Silke Prieur,¹ Susann Junghanns, MD,²
 Katherine Schweitzer, MD,³ Christoph Globas, MD,³
 Ludger Schöls, MD,³ Heinz Reichmann, MD,²
 Daniela Berg, MD,³ and Tjalf Ziemssen, MD,^{1*}

¹Autonomic and neuroendocrinological laboratory, University of Dresden, Germany; ²Parkinson Research group, Department of Neurology, University of Dresden, Germany; ³Department of Neurodegenerative Disorders, Hertie Institute of Clinical Brain Research, University of Tübingen, Germany

Abstract: Multiple system atrophy (MSA) can clinically be divided into the cerebellar (MSA-C) and the parkinsonian (MSA-P) variant. However, till now, it is unknown whether autonomic dysfunction in these two entities differs regarding severity and profile. We compared the pattern of autonomic dysfunction in 12 patients with MSA-C and 26 with MSA-P in comparison with 27 age- and sex-matched healthy controls using a standard battery of autonomic function tests and a structured anamnesis of the autonomic nervous system. MSA-P patients complained significantly more often about the symptoms of autonomic dysfunctions than MSA-C patients, especially regarding vasomotor, secretomotor, and gastrointestinal subsystems. However, regarding cardiovascular, sudomotor pupil, urogenital, and sleep subsystems, there were no significant quantitative or qualitative differences as analyzed by autonomic anamnesis and testing. Our results suggest that there are only minor differences in the pattern of autonomic dysfunction between the two clinical MSA phenotypes. © 2008 Movement Disorder Society

Key words: autonomic nervous system; multiple system atrophy; autonomic dysfunction; MSA subtypes

Multiple system atrophy (MSA) is a sporadic neurodegenerative disorder that usually manifests in the early sixth decade of life and progresses relentlessly with a mean survival of 9 years.¹ Clinically, MSA is dominated by autonomic failure, which may be associated with either levodopa (L-dopa)-unresponsive

Additional Supporting Information may be found in the online version of this article.

*Correspondence to: Dr. Tjalf Ziemssen, Autonomic and Neuroendocrinological Laboratory, Department of Neurology, University of Technology Dresden, Fetscherstraße 74, D-01307 Dresden, Germany. E-mail: Ziemssen@web.de

Received 31 January 2008; Revised 19 May 2008; Accepted 22 May 2008

Published online 25 July 2008 in Wiley InterScience (www.interscience.wiley.com). DOI: 10.1002/mds.22187

TABLE 1. Clinical characteristics of the patients with multiple system atrophy (MSA) subtype P and C as well as healthy controls (Con) (mean \pm SD; NA, not applicable)

	MSA-P	MSA-C	Control
Number of patients	26	12	27
Sex			
Female/male	18/8	7/5	14/13
Age at autonomic testing (years)	62 \pm 8	64 \pm 8	60 \pm 5
Age at onset of disease (years)	57 \pm 8	59 \pm 8	NA
Duration of disease (years)	4.0 (2.6; 5.0)	5.0 (3.8; 7.0)	NA
Hoehn & Yahr staging	4.0 (3.0; 4.4)	3.5 (3.0; 4.3)	NA
Patients with medication	96% (25/26)	42% (5/12)	NA
Levodopa	21	4	
Mean daily dose in milligram	581 \pm 245	288 \pm 131	
Dopamine agonist	14	1	
Pramipexole (mean daily dose in milligram)	8 (1.9 \pm 0.6)	1	
Pergolide	3	0	
Cabergoline	2	0	
Ropinirole	1	0	
Bromocriptine	0	0	
α -Dihydroergocryptine	0	0	
MAO inhibitor	1	0	
COMT inhibitor	3	0	
Amantadine	13	0	
Mean daily dose in milligram	348 \pm 128		

The differences between MSA-P and -C patients regarding dopaminergic medications were significant at $P < 0.02$ (L-dopa) resp. $P < 0.012$ (dopamine agonists).

Parkinsonism in 80% of cases (MSA-P subtype) or with cerebellar ataxia in 20% of cases (MSA-C subtype).² Although the MSA-P subtype is associated with the pathological phenotype of striatonigral degeneration, MSA-C subtype is characterized by olivopontocerebellar atrophy.³ To differentiate MSA-C and -P, besides clinical presentation, magnetic resonance and functional imaging can be used. Still, a certain diagnosis can only be established postmortem.⁴⁻⁶

Until now, it is still unclear whether the key clinical feature of MSA, autonomic failure, differs quantitatively and/or qualitatively between MSA-C and -P. For this reason, we performed for the first time quantitative measurements of autonomic function in patients with the MSA-C and -P subtype in comparison with an age- and sex-matched control group. As in our routine clinical setting, symptoms of autonomic failure are assessed in the clinical anamnesis, we used our semiquantitative autonomic questionnaire to identify symptoms of autonomic failure in a standardized way (Schmidt et al., manuscript in submission). In addition, testing by an autonomic standard test battery on the cardiovascular, pupil and sudomotor system was performed to compare clinical symptoms with the results of autonomic testing.

PATIENTS AND METHODS

We prospectively studied 26 patients with probable parkinsonism-dominant MSA, based on the published

criteria of Gilman et al.⁷ and 12 patients with cerebellar-dominant MSA, and compared them with 27 age- and sex-matched healthy controls (Table 1). The study was approved by the local ethical committee. After giving informed consent, all patients underwent a thorough neurological examination. Only patients fulfilling the criteria of either probable MSA-P or MSA-C were included. With respect to treatment, there were significant differences regarding the dopaminergic medication between MSA-C and MSA-P patients (see Table 1).

We used a structured detailed questionnaire with more than 50 items to evaluate the symptoms of autonomic dysfunction addressing cardiovascular, vasomotor, sudomotor, secretomotor, pupil, gastrointestinal, urogenital, and sleep function. Cardiovascular autonomic testing was performed in a supine position using the SUEMPATHY device (Suess Medizin-Technik, Aue, Germany) including the noninvasive blood pressure (BP) monitoring CBM3000 device (Nihon Colin, Komaki, Japan). At first, resting BP and heart rate (HR) were recorded for 15 minutes, followed by metronomic breathing with six cycles/min for 3 minutes to calculate expiration/inspiration (E/I) ratio as parameter of HR variability. Thereafter, at least three recordings of Valsalva maneuver were done by having the subjects exhaling into a mouthpiece at an expiratory pressure of 40 mm Hg for 15 seconds. For head-up tilt-table testing, patients were tilted up to a 60° upright position within 15 seconds for 10 minutes after staying

TABLE 2. *Semiquantitative autonomic anamnesis in MSA-P, -C patients, and healthy controls, which were performed by a standardized clinical interview using our own autonomic questionnaire*

	MSA-P patients	MSA-C patients	Controls	<i>P</i> value MSA-P versus control	<i>P</i> value MSA-C versus control	<i>P</i> value MSA-P versus MSA-C
Cardiovascular function						
Most frequent symptom	78% (18/23) Presyncope 65% (15/23) Postural (8/23) Heat intolerance (8/23)	55% (6/11) Presyncope 36% (4/11) Postural (4/11)	33% (9/27) Presyncope 30% (8/27) Postural (4/27) Postexercise (3/27)	0.002 NS	NS NS	NS NS
Vasomotor function	96% (22/23) Cold hands 65% (15/23)	64% (7/11) Cold hands 45% (5/11)	37% (10/27) Dry skin 30% (8/27) Localized hyperhidrosis 4% (1/27)	<0.0001 0.01	NS NS	0.029 NS
Sudomotor function	57% (13/23) Dry skin 35% (8/23) Localized hyperhidrosis 26% (6/23)	45% (5/11) Dry skin 27% (3/11) Localized hyperhidrosis 18% (2/11)	37% (10/27) Dry skin 30% (8/27) Localized hyperhidrosis 4% (1/27)	NS NS 0.039	NS NS NS	NS NS NS
Secretomotor function	96% (22/23) Hypersalivation 70% (16/23)	64% (7/11) Hypersalivation 45% (5/11)	37% (10/27) Hypersalivation (0/27) Dry eyes 26% (7/27)	<0.0001 <0.0001	NS 0.001	0.029 NS
Pupil function	78% (18/23) Impaired vision during night 52% (12/23)	82% (9/11) Impaired vision during night 36% (4/11)	22% (6/27) Impaired vision during night 19% (5/27)	<0.0001 0.017	0.001 NS	NS NS
Gastrointestinal function	96% (22/23) Constipation 78% (18/23)	64% (7/11) Constipation 55% (6/11)	19% (5/27) Constipation 11% (3/27) Bloating sensations 15% (4/27)	<0.0001 <0.0001	0.017 0.009	0.029 NS
Urogenital function	100% (23/23) Incontinence 70% (mixed) (16/23)	100% (11/11) Incontinence 73% (mixed) (8/11)	37% (10/27) Stress incontinence 22% (6/27)	<0.0001 0.001	<0.0001 0.008	NS NS
Sleep function	83% (19/23) Snoring 70% (16/23)	64% (7/11) Snoring 73% (8/11)	41% (11/27) Snoring 22% (6/27)	0.004 0.001	NS 0.008	NS NS

Overall frequency of complaints regarding individual autonomic function systems (Cardiovascular, vasomotor, sudomotor, secretomotor, pupil, gastrointestinal, urogenital, sleep function) as well as most frequent symptoms in the individual function systems is presented. *P* values are provided for comparison of the different groups.

at least for 10 minutes in resting supine position. Sympathetic skin response (SSR) evoked by acoustic stimulation was recorded from both palms at least three times using the SUEMPATHY device (Suess Medizin-Technik, Aue, Germany). Recording of the pupil diameter in darkness by near-infrared TV (television) pupillography was performed 20 minutes after dark adaptation using the compact integrated pupillograph (AMTech GmbH, Weinheim) in a standardized way.⁸ Devices for automatic 24-hour recording of ambulatory BP (Boso GmbH, Jüdingen, Germany) were used at various measurement intervals (every 15 minutes during the day and every 30 minutes at night).

The statistical analysis of the data was performed by SPSS. For the descriptive part, mean \pm standard deviation was calculated. Considering the small number of patients, mean and median (first quartile; third quartile) were compared. If both differed more than 10%, median was used; in other cases, mean \pm standard deviation was used. For the explorative analysis (interindividual comparison), we used the Mann-Whitney-Wilcoxon test using medians. For the crosstab analysis (binary data), Fisher's test was applied. Significance was defined $P < 0.05$.

RESULTS

Regarding standardized semiquantitative anamnesis of the autonomic nervous system, the most frequent symptom of autonomic failure was urogenital dysfunction (both MSA groups 100% vs. 37% in the age-matched control group, $P < 0.0001$) (Table 2). In addition, control persons described a totally different pattern of urogenital symptoms (stress incontinence). Sudomotor dysfunction (e.g., dry skin and localized hyperhidrosis) was the least specific symptom of autonomic dysfunction as it was reported to be pathological by many healthy controls as well. Interestingly, MSA-P patients complained significantly more often about symptoms of autonomic dysfunction than MSA-C patients in vasomotor, secretomotor, and gastrointestinal systems ($P < 0.029$). In addition, MSA-P patients complained about the impairment of significantly higher numbers of pathologically involved autonomic subsystems than MSA-C patients when the numbers of pathologically changed autonomic subsystems were counted (7 of 8 vs. 6 of 8 involved autonomic systems, $P < 0.008$).

Concerning the results of autonomic testing, resting supine HR and BP were significantly different between the MSA patients and controls, but not between MSA-P and -C patients (Table 3). Parameters of parasympathetic function as E/I ratio during metronomic breathing

and Valsalva ratio were pathological in all MSA patients with a nonsignificant tendency toward more severe parasympathetic involvement of MSA-P patients. Sympathetic dysfunction in the Valsalva maneuver (missing phase IIb and overshoot of phase IV) was also similar between MSA-C and -P patients. Orthostatic testing revealed orthostatic hypotension in nearly 60% of both MSA subgroup patients with a nonsignificant tendency for a higher proportion of symptomatic orthostatic hypotension in MSA-C patients (15 vs. 25%). For both, MSA-C and -P patients, increase of HR during orthostasis was significantly lower than in the control group. In both patient groups, 24-hour ambulatory BP recording revealed similar pathological BP behavior with nondipping and even an increase in BP during night. SSR testing was the only method demonstrating small significant differences between MSA-P and -C patients: 48% MSA-P patients presented with missing SSR at both sides in comparison with 22% MSA-C patients ($P < 0.049$) and 4% healthy controls ($P < 0.001$). In addition, significantly more MSA-P (91%) than MSA-C (43%) patients showed pathological P0 latencies ($P < 0.047$). Although nearly all SSR parameters besides amplitude differed significantly between MSA-P patients and healthy controls, there were no significant differences between MSA-C patients and controls. In contrast, pupillography demonstrated no difference regarding pupil diameter in darkness between MSA-P and -C patients with a tendency of lower pupil diameter in darkness in MSA-C patients, which was significant when compared with the healthy controls ($P < 0.018$). Pupil light reflex testing revealed no significant differences between the MSA-P and -C patients (data not shown).

DISCUSSION

Autonomic anamnesis and function tests are mandatory in the diagnosis and clinical follow-up of patients with MSA. Findings of significant autonomic failure early in the course of the disease make the diagnosis of MSA more likely. Autonomic failure is the key symptom in both MSA subtypes, corresponding to histopathological supraspinal and spinal findings.¹⁰ Cell loss is reported in the dorsal motor nucleus of vagus and involves catecholaminergic neurons of the ventrolateral medulla. All cases of MSA with predominant pathology in either the striatonigral or olivopontocerebellar system show significant loss of intermediolateral cells in the spinal cord.¹¹

Till now, only clinical anamnesis of autonomic failure has been assessed comparative studies between

TABLE 3. Autonomic testing of the cardiovascular, pupil and sudomotor system in MSA-P, -C patients, and healthy controls, as described in materials and methods

	MSA-P patients	MSA-C patients	Controls	P value MSA-P versus control	P value MSA-C versus control	P value MSA-P versus MSA-C
Resting heart rate (Bpm)	76 ± 10	76 ± 13	66 ± 9	0.001	0.019	NS
Resting systolic/diastolic blood pressure (mmHg)	144 ± 22/77 ± 16	145 ± 17/80 ± 11	127 ± 13/70 ± 10	0.002/0.037	0.003/0.005	NS
P. with hypertension at supine rest	35% (9/26)	58% (7/12)	15% (4/27)	NS	0.017	NS
E/I-ratio during metronomic breathing	1.05 ± 0.03	1.08 ± 0.07	1.18 ± 0.09	0.000	0.003	NS
P. with pathological E/I-ratio	87% (13/15)	56% (5/9)	4% (1/27)	0.005	0.002	NS
Valsalva ratio	1.18 (1.11;1.27)	1.26 (1.07;1.42)	1.36 (1.27;1.43)	0.003	NS	NS
P. with pathological Valsalva phase II (missing phase IIb)	53% (9/17)	44% (4/9)	4% (1/25)	0.000	0.012	NS
P. with pathological Valsalva phase IV (missing blood pressure overshoot)	88% (15/17)	88% (8/9)	28% (7/25)	0.000	0.004	NS
Fall of systolic BP during HUT [absolute (mm Hg)/relative]	-30 (-40, -20)	-35 (-46; -13)	-10 (-15; -5)	0.000	0.012	NS
Fall of diastolic BP during HUT [absolute (mm Hg)/relative]	-20% (-28%, -14%)	-21% (-29%; -8%)	-7% (-12%; -4%)	0.000	0.027	NS
Fall of median BP during HUT [absolute (mm Hg)/relative]	-15 (-15; -10)	-15 (-20; 0)	0 (-5; -5)	0.000	0.022	NS
P. with orthostatic hypotension	-17% (-21%; -10%)	-17% (-22%; 0)	0% (-8%; 6%)	0.000	0.022	NS
P. with symptomatic orthostatic hypotension	-20 (-27; -15)	-23 (-28; -4)	-3 (-8; -2)	0.000	0.000	NS
Relative increase of heart rate during HUT	-18% (-25%; -13%)	-20% (-24%; -4%)	-3 % (-9%; 2%)	0.000	0.021	NS
24-h BP: Missing nocturnal blood pressure dipping	58% (15/26)	58% (7/12)	0%	0.051	0.020	NS
24-h BP: Reversed circadian blood pressure	15% (9%; 20%)	10% (7%; 15%)	23% (15%; 29%)	0.040	0.005	NS
P. with missing SSR at one side	70% (14/20)	60% (3/5)	8% (2/26)	0.000	0.020	NS
P. with missing SSR at both sides	45% (9/20)	60% (3/5)	4% (1/26)	0.001	0.008	NS
Mean SSR P0 latency (ms)	17% (4/23)	0%	0%	0.024	NS	NS
P. with pathological SSR P0 latency	48% (11/23)	22% (2/9)	4% (1/27)	0.000	NS	0.049
Mean SSR N1 latency (ms)	1.94 (1.89; 2.05)	1.61 (1.52; 2.03)	1.45 (1.25; 1.68)	0.000	NS	NS
P. with pathological SSR amplitude (µm)	92% (11/12)	43% (3/7)	31% (8/26)	0.001	NS	0.047
P. with pathological SSR in darkness (mm)	3.06 (3.01; 3.20)	2.43 (2.21; 2.88)	2.22 (1.91; 2.75)	0.002	NS	NS
P. with pathological pupil diameter in darkness	3.15 (1.65; 4.62)	2.39 (1.66; 3.97)	4.43 (2.33; 6.94)	NS	NS	NS
	50% (6/12)	57% (4/7)	19% (5/26)	NS	NS	NS
	4.87 ± 0.93	4.33 ± 1.12	5.22 ± 0.72	NS	0.018	NS
	31% (5/16)	38% (3/8)	7% (2/27)	NS	NS	NS

Values are given as median (1. quartile; 3. quartile)

P values are provided for comparison of the different groups. HUT, head-up tilt; significant orthostatic hypotension was defined by the actual guidelines.⁹ SSR, sympathetic skin response.

MSA-P and -C patients. Although one histopathological study with 42 postmortem-confirmed cases showed no differences regarding symptoms of autonomic and urinary failure,³ another study with 100 MSA cases reported significantly more abundant clinical signs of autonomic dysfunction in the olivopontocerebellar (MSA-C) than in the striatonigral (MSA-P) phenotype.¹² Both studies only relied on retrospective chart reviews. Another imaging study with 45 MSA patients described in 74% (MSA-P) and 85% (MSA-C) symptoms suggestive of autonomic dysfunction (mostly orthostatic hypotension and urinary symptoms).¹³ Another small study regarding SSR in MSA-P and -C demonstrated preservation of SSR in up to 30% in MSA patients, more in the MSA-C than in the MSA-P group.¹⁴

As autonomic failure can be diagnosed by symptom-focused anamnesis, which is routinely used method in the clinical setting, and autonomic testing, which is only available in specialized centers, we used both approaches to compare autonomic failure between MSA-C and -P patients.

In our study, we were able to demonstrate that it is possible to differentiate both MSA-P and -C patients from healthy age- and sex-matched controls by both approaches. Interestingly, using our semiquantitative autonomic questionnaire, we were able to demonstrate significant differences between MSA-P and -C patients. MSA-P patients reported symptoms of autonomic failure in more autonomic subsystems and more frequently in the vasomotor, secretomotor, and gastrointestinal subsystem, which cannot be assessed by standard autonomic testing. In contrast, cardiovascular, sudomotor, and pupil subsystem were not significantly different between MSA-P and -C patients as assessed by both approaches used in this study, semiquantitative anamnesis, and autonomic testing. Even regarding SSR, only minor differences could be shown. So, if both approaches could be compared, autonomic testing and semiquantitative anamnesis demonstrated similar results.

Comparing MSA-C and -P patients, we can report for the first time a quantitative comparison, which demonstrates differences in some autonomic subsystems (by standardized anamnesis), whereas other subsystems (evaluated by anamnesis and autonomic test battery) are similarly involved in MSA-P and -C patients.

As restriction of this study, the number of patients investigated in each group was small. Moreover, we used clinical criteria for diagnosis and did not have pathologic confirmation. Further prospective studies on MSA patients with larger groups of patients and with neuropathological correlation are needed to determine

accurate diagnostic values. There maybe an influence of dopaminergic medication, which was significant different between MSA-P and -C patients (Table 1). But, we regard this effect only minor from the literature and our unpublished data.^{15,16} So, Mesec et al.¹⁷ could not find any significant influence of dopaminergic medication in 50 PD patients as well as Bouhaddi et al.¹⁸ in de novo versus long-term-treated PD patients. In addition, Senard et al. only reported minor changes by dopaminergic stimulation.¹⁹ In some MSA-P patients, it was possible to stop dopaminergic medication the day before testing, whereas in some patients it was not possible because of quite-pronounced OFF symptoms. The patients we investigated were at least half a year on stable dopaminergic medication. In this situation, we decided to analyze in OFF whereas possible and where not to perform testing under dopaminergic medication. In addition, we could not demonstrate differences in a subgroup analysis comparing patients with and without dopaminergic medication (data not shown).

Still, frequency and severity of autonomic symptoms show that not only standard autonomic testing, but also autonomic anamnesis, which could be performed in nearly any clinical setting should be a mandatory part of the diagnostic procedure of MSA patients.

REFERENCES

1. Geser F, Wenning GK. The diagnosis of multiple system atrophy. *J Neurol* 2006;253 (Suppl 3):iii2–iii15.
2. Wenning GK, Geser F. Multiple system atrophy. *Rev Neurol* 2003;159(5, Part 2):3S31–3S38.
3. Jellinger KA, Seppi K, Wenning GK. Grading of neuropathology in multiple system atrophy: proposal for a novel scale. *Mov Disord* 2005;20 (Suppl 12):S29–S36.
4. da Rocha AJ, Maia AC, Jr, da Silva CJ, et al. Pyramidal tract degeneration in multiple system atrophy: the relevance of magnetization transfer imaging. *Mov Disord* 2007;22:238–244.
5. Schulz JB, Klockgether T, Petersen D, et al. Multiple system atrophy: natural history, MRI morphology, and dopamine receptor imaging with 123IBZM-SPECT. *J Neurol Neurosurg Psychiatr* 1994;57:1047–1056.
6. Taniwaki T, Nakagawa M, Yamada T, et al. Cerebral metabolic changes in early multiple system atrophy: a PET study. *J Neurol Sci* 2002;200:79–84.
7. Gilman S, Low PA, Quinn N, et al. Consensus statement on the diagnosis of multiple system atrophy. *J Auton Nerv Syst* 1998;74:189–192.
8. Schmidt C, Herting B, Prieur S, et al. Pupil diameter in darkness differentiates progressive supranuclear palsy (PSP) from other extrapyramidal syndromes. *Mov Disord* 2007;22:2123–2126.
9. Consensus statement on the definition of orthostatic hypotension, pure autonomic failure, and multiple system atrophy. The Consensus Committee of the American Autonomic Society and the American Academy of Neurology. *Neurology* 1996;46:1470.
10. Ozawa T. Morphological substrate of autonomic failure and neurohormonal dysfunction in multiple system atrophy: impact on determining phenotype spectrum. *Acta Neuropathol (Berl)* 2007;114:201–211.

11. Oppenheimer DR. Lateral horn cells in progressive autonomic failure. *J Neurol Sci* 1980;46:393–404.
12. Ozawa T, Paviour D, Quinn NP, et al. The spectrum of pathological involvement of the striatonigral and olivopontocerebellar systems in multiple system atrophy: clinicopathological correlations. *Brain* 2004;127(Part 12):2657–2671.
13. Abdo WF, van de Warrenburg BP, Kremer HP, Bloem BR, Verbeek MM. CSF biomarker profiles do not differentiate between the cerebellar and parkinsonian phenotypes of multiple system atrophy. *Parkinsonism Relat Disord* 2007;13:480–482.
14. Magnifico F, Misra VP, Murray NMF, Mathias CJ. The laboratory detection of autonomic dysfunction in multiple system atrophy—the role of the sympathetic skin response. *Neurology* 1997;48 (Suppl):A190.
15. Goldstein DS. Dysautonomia in Parkinson's disease: neurocardiological abnormalities. *Lancet Neurol* 2003;2:669–676.
16. Jost WH. [Autonomic dysregulations in Parkinson's syndrome]. *Schweizerische Rundschau Medizin Praxis = Rev Suisse Med PRAXIS* 2005;94:1639–1646.
17. Mesec A, Segal S, Kiauta T. The influence of the type, duration, severity and levodopa treatment of Parkinson's disease on cardiovascular autonomic responses. *Clin Auton Res* 1993;3:339–344.
18. Bouhaddi M, Vuillier F, Fortrat JO, et al. Impaired cardiovascular autonomic control in newly and long-term-treated patients with Parkinson's disease: involvement of L-dopa therapy. *Auton Neurosci* 2004;116:30–38.
19. Senard JM, Verwaerde P, Rascol O, Montastruc JL. Effects of acute levodopa administration on blood pressure and heart variability in never treated parkinsonians. *Hypertens Res* 1995;18 (Suppl 1):S175–S177.

Ultrasonographic Findings of Shoulder Disorders in Patients with Parkinson's Disease

Seong-Beom Koh, MD, PhD,¹ Jee-Hoon Roh, MD,¹
 Ji Hyun Kim, MD, PhD,¹ Kyungmi Oh, MD, PhD,¹
 Byung-Jo Kim, MD, PhD,¹ Gui-Sang Kim, MD,²
 Byung-Kyu Park, MD, PhD,² Se-Ju Kim, MD, PhD²,
 and Joon-Shik Yoon, MD, PhD^{2*}

¹*Department of Neurology Korea University College of Medicine Guro-Ku, Seoul, Republic of Korea;*

²*Department of Physical Medicine and Rehabilitation Korea University College of Medicine, Guro-Ku, Seoul, Republic of Korea*

Abstract: The prevalence of a history of shoulder complaints is higher in patients with Parkinson's disease (PD) than in healthy individuals. The aims of this study were to evaluate shoulder disease in PD patients with ultrasonography (US) and to identify the relationship between the US findings of shoulder disease and the motor signs in patients with PD. Thirty-three PD patients completed a shoulder disability questionnaire, a musculoskeletal examination, and US of the shoulder. Twenty-two patients had abnormal US findings. Tendon tearing was the most common abnormal US finding (22/22), and the supraspinatus tendon was the most common site involved (15/22). Patients with tendon tearing had a significantly longer duration of disease than patients without tendon tearing ($P = 0.027$). Patients with adhesive capsulitis had a significantly higher rigidity score than patients without adhesive capsulitis ($P = 0.035$). Disease duration and rigidity were the contributing factors for the development of tendon tearing and adhesive capsulitis, respectively. © 2008 Movement Disorder Society

Key words: shoulder disorders; Parkinson's disease; ultrasonography

Shoulder pain is an important medical and socio-economic problem. Pain and stiffness in the shoulder may lead to an inability to work and/or to carry out activities of daily living. The self-reported prevalence of shoulder pain is estimated to be 16 to 26%; shoulder pain is the third most common cause of consultations for musculoskeletal conditions in primary care.^{1,2}

Ultrasonography (US) has been shown to be a useful diagnostic tool in patients with shoulder pain and/or a

*Correspondence to: Dr. Joon-Shik Yoon, Department of Physical Medicine and Rehabilitation, Korea University College of Medicine at Guro Hospital, 80 Guro-Dong, Guro-Ku, Seoul, Republic of Korea. E-mail: rehab46@korea.ac.kr

Received 28 January 2008; Revised 27 May 2008; Accepted 31 May 2008

Published online 25 July 2008 in Wiley InterScience (www.interscience.wiley.com). DOI: 10.1002/mds.22191

limited range of shoulder motion. It allows for the careful assessment of a wide range of changes involving different anatomic structures of the shoulder girdle, such as the rotator cuff tendons, the long head of the biceps tendon, and the soft tissues.^{3,4}

Parkinson's disease (PD) is a common neurodegenerative disorder, affecting 1.47% of the population over 60 years of age in Korea.⁵ In one previous report, the PD population, as compared with healthy individuals, showed a higher prevalence of both a history of shoulder complaints and frozen shoulder.⁶

The primary aim of this study was to identify the US findings associated with shoulder disease in patients with PD. The second aim was to identify the relationship between the US findings of shoulder disease and the cardinal motor signs of PD.

PATIENTS AND METHODS

Patient Selection

Thirty-three patients with PD were enrolled in our study. The patients were selected from the Neurology Department of the Korea University Guro Hospital. All patients met the clinical diagnostic criteria for PD, as described by the United Kingdom Parkinson's Disease Society Brain Bank.⁷ The patients were on levodopa therapy with a definite and lasting good response. We excluded patients who reported previous shoulder joint trauma or shoulder surgery. Patients who could not complete a questionnaire and an US study because of cognitive impairment (Mini-Mental Status Examination <24) or who had severe medical comorbidities were also excluded. Written informed consent was obtained from each patient for participation in the study. This study was approved by the Institutional Review Board of the Korea University Guro Hospital.

Between April 1, 2006 and May 1, 2006, 62 patients were prospectively enrolled in this study, and 33 patients were ultimately examined. Twenty-nine patients were excluded due to cognitive impairment (n = 12), previous shoulder trauma or surgery (n = 4), rheumatoid arthritis [n = 8 (2 patients also had cognitive impairment)], and an incomplete study (n = 7).

METHODS

Neurologic Evaluation

Patients underwent a neurologic examination and a clinical assessment. The Hoehn and Yahr (H&Y) stage was determined⁸ and the degree of disease severity was quantified by the Unified Parkinson's Disease Rat-

ing Scale (UPDRS)⁹ in the *on* state by one movement disorder specialist.

Self-Questionnaire

All enrolled patients were asked to complete a questionnaire with information pertaining to their shoulder disability.¹⁰

Musculoskeletal Examination and US

Patients underwent a musculoskeletal examination and an US. The examiner was blinded to the patient's history and the findings of the neurologic examination. Real-time sonography was performed with a HDI 5000 (Philips, Holland) equipped with a 7 to 12 MHz linear-array transducer. The patient was seated on an examination chair, behind which the examiner stood. According to the description of a previous report, five standard US views were selected (anterior transverse, anterior longitudinal, lateral transverse, lateral longitudinal, and posterior transverse).¹¹ The US criteria for complete tendon tears (TT) were as follows: tendon nonvisualization, anechoic or hypoechoic discontinuity, and deltoid herniation (Fig. 1). The criteria of partial tendon tears were as follows: focal heterogenous hypoechoic and an incomplete hypoechoic defect (Fig. 2). We made note of secondary signs of tears, such as subdeltoid bursitis, cortical irregularity of the greater tuberosity, and the cartilage sign. By using dynamic US, adhesive capsulitis (AC) was defined as a difficulty in obtaining adequate images of the subscapularis tendon due to a reduced region of external rotation of the subscapularis tendon and increased fluid in the dependent portion of the bicipital tendon sheath.¹² We also defined

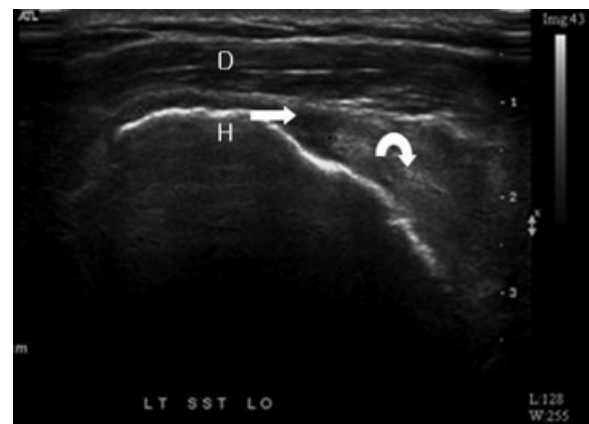


FIG. 1. Longitudinal ultrasonography shows tendon nonvisualization, indicating a full thickness tear of the supraspinatus tendon (arrow). The retracted tendon end is detected (curved arrow). The overlying deltoid muscle (D) is seen on the underlying humerus (H).

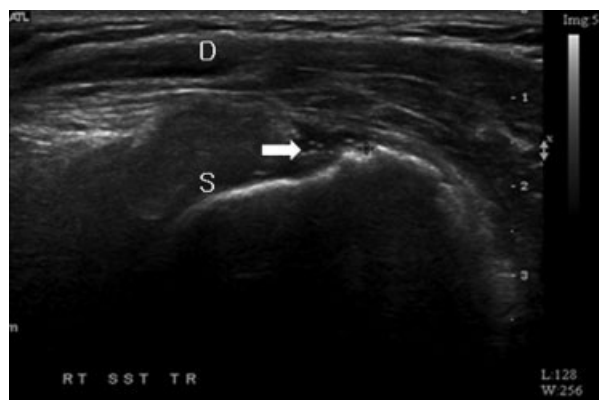


FIG. 2. Transverse ultrasonography of the supraspinatus tendon shows a partial thickness tear (arrow) in the supraspinatus tendon (S). The overlying deltoid muscle (D) is seen.

myofascial pain syndrome (MPS) as a tender point within a taut band of the shoulder girdle muscle, a characteristic referred pain, pain on sustained compression over the tender point, or a local twitch response within the band. We classified shoulder disease according to the anatomic structures of the shoulder girdle and a pathologic process by US, such as the TT, AC, and a nonpathologic process, such as MPS.

Statistical Analysis

Data were tabulated and analyzed using SPSS, version 10.0 for Windows (SPSS, Chicago, IL). An independent *t*-test was used to compare disease duration, H&Y stage, UPDRS part 3 (total, tremor, rigidity, and bradykinesia scores) and the shoulder pain questionnaire score according to the classification of shoulder diseases. The correlation between the shoulder pain questionnaire score and each cardinal motor sign score of UPDRS part 3 was evaluated using Spearman's rho test.

RESULTS

Clinical Characteristics

The study participants included 19 males and 23 females with a mean age of 67.27 ± 6.72 years (range, 54–80 years). The median age of disease onset was 64.0 years, and the mean duration of disease was 3.2 ± 2.6 years (range, 1–12 years; Table 1). Among the 33 patients, 3 patients did not have shoulder pain.

Ultrasonographic Findings

Among the 33 patients, 22 patients had abnormal US findings on the dominant side. Among the 22 patients, 10 patients also had abnormal US findings on the nondominant side.

TABLE 1. Demographic and clinical characteristics of the 33 patients with Parkinson's disease

	Mean \pm SD or number
Age (yr)	67.27 ± 6.72
Male/female	10/23
Disease duration (yr)	3.23 ± 2.59
Hoehn & Yahr Stage	2.11 ± 0.68

All 22 patients with abnormal US findings had a TT (22/22) and 9 patients had AC (9/22). All nine patients with AC also had a TT. The anatomic locations of the TT were the supraspinatus tendon (15/22), a combination of the supraspinatus and subscapular tendons (6/22), and a combination of the supraspinatus and biceps tendons (1/22). Eleven patients had MPS. Among three patients without shoulder pain, one patient had a TT of the supraspinatus tendon and two patients had AC. Among the 10 patients with abnormal US findings on the nondominant side, 8 patients had a TT (8/10), 3 patients had AC (3/10), and 1 patient had a combined TT and AC. On the dominant side, the majority of patients (18/22) with a TT had complete tendon tearing and 4 patients had partial tendon tearing. On the nondominant side, only one patient had complete tendon tearing and other seven patients had partial tendon tearing.

Clinical Features and Cardinal Motor Signs of PD According to Shoulder Diseases

Tendon Tear

The mean duration of disease was 3.82 ± 2.82 years for the group with a TT and 2.05 ± 1.56 years for the group without a TT. In the group with a TT, the mean duration of disease was significantly longer than the group without a TT ($P = 0.027$). There was no significant difference between the two groups with respect to other clinical profiles (Table 2).

Adhesive Capsulitis

The mean rigidity score of UPDRS 3 was 15.11 ± 8.43 for the group with AC and 3.46 ± 2.23 for the group without AC. In the group with AC, the mean UPDRS 3 rigidity score was significantly higher than in the group without AC ($P = 0.035$). There was no significant difference between the two groups with respect to other clinical profiles (Table 2).

Myofascial Pain Syndrome

There was no significant difference between patients with MPS and patients without MPS in terms of the

TABLE 2. Clinical features in PD patients with shoulder diseases

	Tendon tearing		Adhesive capsulitis	
	Yes	No	Yes	No
Number of Patients	22	11	9	24
Age	67.36 ± 6.19	67.09 ± 8.01	66.90 ± 7.36	67.43 ± 6.60
SDQ scores	31.86 ± 26.50*	13.91 ± 20.12*	31.89 ± 23.15	23.63 ± 26.73
Disease duration (yr)	3.82 ± 2.82*	2.05 ± 1.56*	4.00 ± 1.87	2.94 ± 2.79
UPDRS 3, total	13.73 ± 8.32	13.18 ± 8.53	15.11 ± 8.43	12.96 ± 8.30
UPDRS 3, tremor	1.95 ± 1.53	1.82 ± 1.25	1.67 ± 1.12	2.00 ± 1.53
UPDRS 3, rigidity	4.27 ± 2.76	3.55 ± 2.21	5.56 ± 2.96*	3.46 ± 2.23*
UPDRS 3, bradykinesia	3.82 ± 4.52	4.36 ± 4.57	5.00 ± 5.77	3.63 ± 3.97

* $P < 0.05$.

shoulder disability questionnaire score, H&Y stage, or UPDRS 3 tremor and bradykinesia scores.

Shoulder Disability Questionnaire and Cardinal Motor Signs of Parkinsonism

There was no significant correlation between the shoulder disability questionnaire score and the UPDRS 3 total score, and there was no significant correlation between the shoulder disability questionnaire and each UPDRS 3 cardinal sign score.

DISCUSSION

In this study of PD patients, abnormal US findings were common and a TT was the most common finding; MPS and AC were also common findings. A TT was also observed in patients without shoulder pain (33%). The epidemiology of symptomatic and asymptomatic rotator cuff tears has been poorly characterized. Previous studies involving cadavers have demonstrated a high prevalence of rotator cuff tears, ranging from 9.4% (18 of 192) to 39% (39 of 100).¹³ Indeed, rotator cuff tears are a very common pathologic finding and may be part of the natural ageing process.¹⁴ Reilly et al. also reported that in an unselected cadaver population, the prevalence of full-thickness and partial thickness tears was 11.75 and 18.49%, respectively (total tears, 30.24%).¹⁵ In a previous study with US, the prevalence of rotator cuff tears was 65% (15 of 23) in patients who were more than 70 years of age.¹⁶ In another study with US, Yamaguchi et al.¹⁷ reported that there was a strong correlation between the onset of rotator cuff tears and increasing age. In our study, the prevalence of TT in the PD patients group was 66.7% (22 of 33) and there was no significant age difference between the TT and non-TT groups. The prevalence and degree of TT on the dominant side were common and severe, compared to the nondominant side. With these findings, we suggest that shoulder dis-

ease in PD patients is common compared to the general population. However, in our study there was no age-matched healthy control group. This was a main limitation in our study.

In the present study, the most frequent location of a TT was the supraspinatus tendon; a TT involving the supraspinatus and subscapularis tendons was also common in patients with PD. In the general population, the supraspinatus tendon is the most frequent tendon that is torn.¹⁸ The supraspinatus tendon is located on the acromiohumeral joint and is covered by the deltoid muscle. When the shoulder joint is immobilized for an extended period of time, the joint capsule of the acromiohumeral joint undergoes atrophy. Therefore, in PD patients the adducted posture of the shoulder, rigidity, and poverty of movement might contribute to the tearing of the supraspinatus tendon. PD of long duration might be a risk factor for a TT of the rotator cuff.

AC was also a common finding in patients with PD. AC is characterized by pain and loss of stiffness in the shoulder and affects approximately 2% of the general population.¹⁹ In the present study, AC affected 9 (26.4%) of 34 patients with PD. The UPDRS 3 rigidity score was higher in patients with AC than in patients without AC. Rigidity and the associated immobilization might contribute to the development of AC, and AC may also be an aggravating factor for rigidity.

However, in the present study, there was no significant correlation between the shoulder disability questionnaire score and the UPDRS motor scores. The small sample size and predominance of early stage PD (approximately 76% for H-Y stage ≤ 2.5 ; median H&Y stage = 2) could limit an accurate assessment of the relationship between the shoulder disability score and the cardinal motor signs of PD.

In conclusion, US abnormalities of the shoulder joint are common in patients with PD, and a supraspinatus TT was the most common finding in our study. The

duration of disease was the main contributing factor for the development of a TT, whereas rigidity was a more important factor in the development of AC.

REFERENCES

1. Urwin M, Symmons D, Allison T, et al. Estimating the burden of musculoskeletal disorders in the community: the comparative prevalence of symptoms at different anatomical sites, and the relation to social deprivation. *Ann Rheum Dis* 1998;57:649–655.
2. Winters JC, Sobel JS, Groenier KH, Arendzen JH, Meyboom-de Jong B. The long-term course of shoulder complaints: a prospective study in general practice. *Rheumatology (Oxford)* 1999;38:160–163.
3. Ozcakar L, Vanderstraeten G, Parlevliet T. Sonography and visualizing rotator cuff injuries in older people. *J Am Geriatr Soc* 2005;53:1840–1841.
4. Iagnocco A, Filippucci E, Meenagh G, et al. Ultrasound imaging for the rheumatologist. I. Ultrasonography of the shoulder *Clin Exp Rheumatol* 2006;24:6–11.
5. Seo WK, Koh SB, Kim BJ, et al. Prevalence of Parkinson's disease in Korea. *J Clin Neurosci* 2007;14:1155–1157.
6. Cleaves L, Findley L. Frozen shoulder and other shoulder disturbances in Parkinson's disease. *J Neurol Neurosurg Psychiatry* 1989;52:813–814.
7. Yughes AJ, Daniel SE, Lees AJ. The clinical features of Parkinson's disease in 100 histologically proven cases. *Adv Neurol* 1993;60:595–599.
8. Hoehn MM, Yahr MD. Parkinsonism: onset, progression and mortality. *Neurology* 1967;17:427–442.
9. The Unified Parkinson's Disease Rating Scale (UPDRS): status and recommendations. *Mov Disord* 2003;18(7):738–750.
10. van der Windt DA, van der Heijden GJ, de Winter AF, Koes BW, Deville W, Bouter LM. The responsiveness of the shoulder disability questionnaire. *Ann Rheum Dis* 1998;57:82–87.
11. Moosmayer S, Smith HJ. Diagnostic ultrasound of the shoulder—a method for experts only? Results from an orthopedic surgeon with relative inexpensive compared to operative findings. *Acta Orthop* 2005;76:503–508.
12. McNally EG. *Practical musculoskeletal ultrasound*. Philadelphia: Elsevier; 2005.
13. Fukuda H, Hamada K, Yamanaka K. Pathology and pathogenesis of bursal-side rotator cuff tears viewed from en bloc histologic sections. *Clin Orthop Relat Res* 1990(254):75–80.
14. Worland RL, Lee D, Orozco CG, SozaRex F, Keenan J. Correlation of age, acromial morphology, and rotator cuff tear pathology diagnosed by ultrasound in asymptomatic patients. *J South Orthop Assoc* 2003;12:23–26.
15. Reilly P, Macleod I, Macfarlane R, Windley J, Emery RJ. Dead men and radiologists don't lie: a review of cadaveric and radiological studies of rotator cuff tear prevalence. *Ann R Coll Surg Engl* 2006;88:116–121.
16. Milgrom C, Schaffler M, Gilbert S, van Holsbeeck M. Rotator-cuff changes in asymptomatic adults. The effect of age, hand dominance and gender. *J Bone Joint Surg Br* 1995;77:296–298.
17. Yamaguchi K, Ditosios K, Middleton WD, et al. The diagnosis and morphologic features of rotator cuff disease. A comparison of asymptomatic and symptomatic shoulders. *J Bone Joint Surg Am* 2006;88:1699–1704.
18. Kim HA, Kim SH, Seo YI. Ultrasonographic findings of painful shoulders and correlation between physical examination and ultrasonographic rotator cuff tear. *Mod Rheumatol* 2007;17:213–219.
19. Hunt SA, Kwon YW, Zuckerman JD. The rotator interval: anatomy, pathology, and strategies for treatment. *J Am Acad Orthop Surg* 2007;15:218–227.

Elevated Serotonin Transporter Binding in Depressed Patients with Parkinson's Disease: A Preliminary PET Study with [¹¹C]DASB

Isabelle Boileau, PhD,^{1*} Jerry J. Warsh, MD,²
Mark Guttman, MD,^{1,3} Jean A. Saint-Cyr, PhD,^{1,4}
Tina McCluskey, MSc,¹ Pablo Rusjan, PhD,⁵
Sylvain Houle, MD,⁵ Alan A. Wilson, PhD,⁵
Jeffrey H. Meyer, MD, PhD,⁵
and Stephen J. Kish, PhD¹

¹Human Neurochemical Pathology Laboratory, Centre for Addiction and Mental Health, University of Toronto, Toronto, Ontario, Canada; ²Laboratory of Cellular and Molecular Pathophysiology and Mood Disorders Program, Centre for Addiction and Mental Health, University of Toronto, Toronto, Ontario, Canada; ³Centre for Movement Disorders, Markham, Ontario, Canada; ⁴Division of Brain Imaging & Behaviour Systems, Toronto Western Research Institute, University of Toronto, Toronto, Ontario, Canada; ⁵Vivian M. Rakoff PET Imaging Centre, Centre for Addiction and Mental Health, University of Toronto, Toronto, Ontario, Canada

Abstract: This study investigated whether abnormalities in serotonin transporter binding occur in Parkinson's disease (PD) patients with concurrent depression. We estimated serotonin transporter levels in seven clinically depressed early-stage PD patients and in seven healthy matched-control subjects during a single positron emission tomography (PET) scan with the serotonin transporter radioligand, [¹¹C]DASB. Depressed PD patients displayed a wide-spread increase (8–68%) in [¹¹C]DASB specific binding outside of the striatum, which was significant in dorsolateral (37%) and prefrontal (68%) cortices. Elevated [¹¹C]DASB binding was positively correlated with depressive symptoms but not with disease severity or duration. Compatible with recent PET/[¹¹C]DASB findings in major depression, the present preliminary data suggest that increased [¹¹C]DASB binding, possibly reflecting greater serotonin transporter density (up-regulation), might be a pathological feature of depression in Parkinson's disease—and possibly a characteristic of depressive illness in general. © 2008 Movement Disorder Society

Key words: Parkinson's disease; depression; serotonin transporter; positron emission tomography; [¹¹C]DASB

*Correspondence to: Dr. Isabelle Boileau, Centre for Addiction and Mental Health, 250 College Street, Toronto, Ontario, CANADA M5T 1R8. E-mail: isabelle_boileau@CAMH.net

Potential conflict of interest: None reported.

Received 17 March 2008; Revised 15 May 2008; Accepted 11 June 2008

Published online 25 July 2008 in Wiley InterScience (www.interscience.wiley.com). DOI: 10.1002/mds.22212

TABLE 1. Mean (and SD) of [¹¹C]DASB BP_{ND} in 10 brain ROIs of normal control subjects (n = 7) and patients with PD and concurrent depression (n = 7)

Regions of interest	Control (n = 7)		PD (n = 7)		%Difference	P uncorrected
	Mean	SD	Mean	SD		
DLPFC	0.32	0.07	0.42	0.04	37	†0.001
PFC	0.29	0.11	0.48	0.07	68	†0.002
OFC	0.42	0.08	0.49	0.11	16	0.21
Anterior cingulate	0.35	0.07	0.46	0.14	31	0.08
Insular cortex	0.36	0.16	0.50	0.13	39	0.09
Cuneus	0.38	0.15	0.51	0.13	37	0.08
Caudate nucleus	1.18	0.34	1.16	0.09	-1	0.89
Putamen	1.11	0.39	1.05	0.09	-5	0.72
Thalamus	1.71	0.66	2.18	0.52	21	0.28
Midbrain	3.33	1.46	3.61	0.89	8	0.67

†Significant difference after adjustment using Bonferroni correction criterion ($P < 0.005$).

Parkinson's disease (PD) is a neurodegenerative disorder characterized by motor and nonmotor features including cognitive and neuropsychiatric disturbances. Depression, assumed to be present in ~40% of PD patients,¹ is not only the most common nonmotor symptom of (early) PD but also among the most taxing

on quality of life.² Postmortem studies³ and in vivo neurochemical imaging investigations studies⁴⁻⁶ suggest a brain serotonergic deficiency in PD which could in part explain mood and cognitive disturbances (including depression) in some PD patients. However, to date, only one post-mortem neuropathological study has provided evidence that depression in PD might be related to a loss of (raphé) serotonergic neurons.⁷ To our knowledge, no imaging study of serotonin transporter (5-HTT) levels, a key serotonin neuron marker, has been conducted in PD with diagnosed concurrent depression using a highly specific and selective radioligand. The goal of the present positron emission tomography (PET) study was to assess 5-HTT binding in clinically depressed, nondemented patients with PD using [¹¹C]DASB ([¹¹C]-3-amino-4-(2-dimethylamino-methyl-phenylsulfanyl)-benzonitrile) a highly specific radioactive probe.⁸

PATIENTS AND METHODS

Seven patients (4M, 3F) meeting UK Brain-Bank Criteria for idiopathic PD (mean \pm SD age of 61.1 ± 9.8 years) and seven gender-matched controls (mean \pm SD age of 59.5 ± 6.7 years) participated in the research ethic's board approved study. PD patients were mostly in early clinical stages of the disease (mean \pm SD disease duration: 4 ± 2.9 years; Hoehn and Yahr scale (H&Y): 2 H&Y stage I, 4 H&Y stage II, 1 H&Y stage III; mean \pm SD Unified Parkinson's Disease Rating Scale on medication: 21.1 ± 0.34) and responded well to the treatment. All PD subjects (and no control subjects) met criteria for current depressive disorders (4 major, 2 minor, and 1 sub-syndromal depression) during a structured clinical interview for DSM-IV Axis I Disorders (SCID) with a psychiatrist.

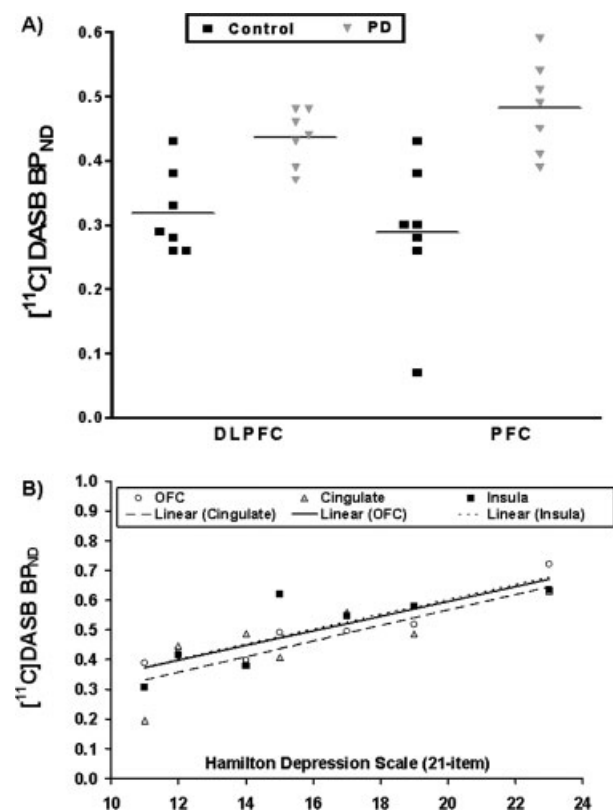


FIG. 1. (A) Increased [¹¹C]DASB BP_{ND} in DLPFC and PFC in depressed PD relative to healthy matched controls. (B) Positive correlation (Pearson) between [¹¹C]DASB BP_{ND} and depressive symptoms (HAM-21).

None of the subjects, PD or controls, had ever received antidepressant medication and none showed evidence of dementia based on a nonsignificant difference ($P = 0.4$) between pre-morbid intelligence, as estimated by the National Adult Reading Test (controls mean \pm SD: 119.59 ± 5.6 ; PD mean \pm SD: 116.81 ± 4.2), and IQ as estimated with the Wechsler Adult Intelligence Scale (controls mean \pm SD: 121.29 ± 7.6 ; PD mean \pm SD: 112.29 ± 9.3). PET measurements were conducted when the patients were in a normal medicated state (3 Levodopa/carbidopa therapy, 1 L-dopa/carbidopa and dopamine agonist therapy, 1 dopamine agonist therapy, 1 L-dopa/carbidopa and anticholinergic therapy, and 1 amantadine therapy). All subjects completed rater-administered mood questionnaires including the Hamilton Depression Scale (HAM-21) and the Inventory of Depressive Symptomatology (IDS) and a battery of standardized cognitive tests (data not shown).

[^{11}C]DASB synthesis and image acquisition protocol have been described in detail elsewhere.^{9,10} All subjects participated in a 90-min PET scan (using GEMS 2048-15B PET camera, Scanditronix Medical, General electric, Uppsala, Sweden) after a bolus injection of 362.23 MBq of [^{11}C]DASB (purity >95%; specific activity 29.82 ± 8.9 GBq/umol at the time of injection). Images were corrected for attenuation using a ^{68}Ge transmission scan and were reconstructed by the filtered back projection (Hanning filter).

PET data were analyzed using a region of interest (ROI)-based method, which uses proton density weighted magnetic resonance imaging (Signa 1.5 T scanner, GE Medical Systems, Milwaukee, WI) and an in-house software¹¹ (ROMI) to delineate ROIs. Briefly, automatically defined ROIs were aligned and re-sliced to match the dimensions of the PET images, and [^{11}C]DASB ROI time activity curves were extracted. To address the potential issues of bias from the volume loss in the patient sample, time activity data was corrected for the effect of partial volume (PVC) using the Mueller-Gartner algorithm.¹² [^{11}C]DASB nondisplaceable binding potential (BP_{ND} : distribution volume ratio of a receptor containing region to a nonreceptor region minus 1) was estimated in each ROI using the noninvasive Logan method¹³ implemented under Pmod (Version 2.8). The cerebellar cortex, a tissue devoid of significant 5-HTT binding, served as the reference tissue. The rationale for this method has been described in detail, and reliability data have been previously published.¹⁴ Differences in [^{11}C]DASB BP_{ND} values between control and PD were analyzed using Bonferroni-corrected independent-sample Student *t*-test (alpha level corrected for 10 ROI comparisons; $P = 0.005$).

RESULTS

When compared to the controls, mean total scores on the two depression rating scales were significantly higher for the PD group (HAM-21 mean \pm SD: controls, 1.4 ± 1.3 ; PD, 15.8 ± 4.1 , $P = 0.00$; IDS mean \pm SD: controls, 4.1 ± 3.5 ; PD, 29.5 ± 5.5 , $P = 0.00$).

As shown in Table 1, [^{11}C]DASB BP_{ND} was higher in PD relative to controls (range 8–68%; mean \pm SD $33 \pm 17\%$) in all the regions investigated except the striatum. Increased [^{11}C]DASB BP_{ND} in PD was statistically significant in the dorsolateral prefrontal (DLPFC; P corrected = 0.01) and prefrontal (PFC; P corrected = 0.02) cortices. Before PVC, the increases were smaller (and more variable) corresponding to 24.7% in DLPFC and 39.6% in PFC (N.S.). PVC appeared to result in a greater relative gain in regional (cortical) activity in patients compared to controls; possibly because of inter-group differences in cortical ROI volume (gray matter volume was slightly, by less than 10%, reduced in frontal cortex of patients, hence theoretically prone to greater contamination from partial volume effect). Inspection of the individual data revealed only a slight overlap between the patients and controls [^{11}C]DASB BP_{ND} values in the DLPFC and PFC (Fig. 1A). Statistically significant correlations (Spearman's ρ ; Fig. 1Bs) between depressive symptom rating and [^{11}C]DASB BP_{ND} were observed in the orbitofrontal cortex (OFC; $\rho = 0.96$, $P < 0.001$), the cingulate cortex ($\rho = 0.81$, $P = 0.027$), the insula ($\rho = 0.85$, $P = 0.014$), and also the putamen ($\rho = 0.85$, $P = 0.014$); such that BP_{ND} increased with depression symptom severity (HAM-21). Only the OFC correlation survived correction for the multiple comparisons (P corrected < 0.001). [^{11}C]DASB BP_{ND} before PVC also correlated with the depression severity (OFC: $\rho = 0.89$, $P = 0.007$; insula $\rho = 0.71$, $P = 0.07$).

DISCUSSION

This is the first study to directly investigate 5-HTT binding using a highly specific 5-HTT radioligand in clinically depressed PD. Notwithstanding the many limitations of our study, for example, small sample size, possible influence of anti-parkinsonian medication on [^{11}C]DASB BP_{ND} ,¹⁵ heterogeneity of depression severity in the PD sample, noise added by the PVC algorithm, between-group brain morphological differences and high [^{11}C]DASB BP_{ND} variability in low 5-HTT binding regions, our data indicate that [^{11}C]DASB BP_{ND} at the 5-HTT is increased and positively correlated with an index of depressive symptomatology in PD.

These findings appear to “deviate” from the results of postmortem³ and imaging^{4–6} studies which typically find a moderate, though variable, decrease in serotonin markers in PD. Although, this difference can tentatively be accounted for in part by the inclusion of more-advanced PD in previous studies^{3,5–6} (note that the patients in the present study were generally early stage); it can also be suggested that the apparent increase (up-regulation) of 5-HTT might have masked the transporter loss and conversely, increased 5-HTT levels might have been underestimated due to a parallel loss of serotonin neuropil (or 5-HTT down-regulation). In this context, it could be argued that a substantial up-regulation in 5-HTT in the cerebral cortex (the region showing statistically significant changes) would have to occur in order to counter the PD-related loss of the transporter. However, the status of brain 5-HTT in early (nondepressed) PD is uncertain as it is limited to a study of only five subjects⁴ and did not include measurement of the transporter in the PFC brain areas.

Our findings (specifically in the cingulate, insula, thalamus, and PFC but not in the striatum) are compatible with some recent PET reports that current episodes of depression¹⁶ and pessimism in major depression¹⁷ are associated with the elevated 5-HTT binding. However, they are at odds with other findings of either decreased or no change in 5-HTT levels in major depression¹⁸ (for review see Ref. 19). Possible discrepancies among these studies could be explained by differences in extent of withdrawal from antidepressant medication (note that the subjects of our investigation had no previous exposure to antidepressant medication) or presence of comorbid psychiatric pathology.

The *in vivo* evidence that physiological fluctuations in endogenous serotonin concentrations in humans do not affect the interaction between [¹¹C]DASB and 5-HTT,^{20,21} suggest that the observed between-group effect more likely reflects a change in 5-HTT density (up-regulation) and/or affinity for [¹¹C]DASB. This argues in favor of the hypothesis that the mechanism contributing to reduced extracellular concentrations of serotonin—and presumably to symptoms of depression—could be excessive serotonin clearance capacity resulting from the increased 5-HTT density. Whether increased 5-HTT is an inherited vulnerability or a compensatory response to PD or to other secondary (environmental or biological) factors is unknown; the etiology of elevated 5-HTT levels in PD with comorbid depression and in depression, whether common or independent, is still an open-ended question.

In conclusion, our imaging data suggest that the depression in PD might be associated with the above-normal brain 5-HTT concentration. In this context, our finding adds to the emerging literature that increased the brain 5-HTT availability might be a common feature of the depressive episodes.

Acknowledgments: This study was supported by Michael J Fox Foundation, Canada CIHR. Dr. Guttman is supported by the National Parkinson Foundation (Miami) Inc. Dr. Meyer acknowledges the Ontario Mental Health Foundation Intermediate Research Fellowship.

REFERENCES

- Poewe W, Luginger E. Depression in Parkinson's disease: impediments to recognition and treatment options. *Neurology* 1999; 52(7 Suppl 3):S2–S6.
- Schrag A, Jahanshahi M, Quinn N. How does Parkinson's disease affect quality of life? A comparison with quality of life in the general population. *Mov Disord* 200;15:1112–1118.
- Kish SJ. Biochemistry of Parkinson's disease: is a brain serotonergic deficiency a characteristic of idiopathic Parkinson's disease? *Adv Neurol* 2003;91:39–49.
- Albin RL, Koeppe RA, Bohnen NI, Wernette K, Kilbourn MA, Frey KA. Sparing caudal brainstem SERT binding in early Parkinson's disease. *J Cereb Blood Flow Metab* 2008;28:441–444.
- Guttman M, Boileau I, Warsh J, et al. Brain serotonin transporter binding in non-depressed patients with Parkinson's disease. *Eur J Neurol* 2007;14:523–528.
- Kerenyi L, Ricaurte GA, Schretlen DJ, et al. Positron emission tomography of striatal serotonin transporters in Parkinson disease. *Arch Neurol* 2003;60:1223–1229.
- Paulus W, Jellinger K. The neuropathologic basis of different clinical subgroups of Parkinson's disease. *J Neuropathol Exp Neurol* 1991;50:743–755.
- Houle S, Ginovart N, Hussey D, Meyer JH, Wilson AA. Imaging the serotonin transporter with positron emission tomography: initial human studies with [¹¹C]DAPP and [¹¹C]DASB. *Eur J Nucl Med* 2001;27:1719–1722.
- Wilson AA, Ginovart N, Schmidt M, Meyer JH, Threkleid PG, Houle S. Novel radiotracers for imaging the serotonin transporter by positron emission tomography: synthesis, radiosynthesis, and *in vitro* and *ex vivo* evaluation of (11)C-labeled 2-(phenylthio) aralkylamines. *J Med Chem* 2000;43:3103–3110.
- Ginovart N, Wilson AA, Meyer JH, Hussey D, Houle S. Positron emission tomography quantification of [¹¹C]-DASB binding to the human serotonin transporter: modeling strategies. *J Cereb Blood Flow Metab* 2001;21:1342–1353.
- Rusjan PM, Mamo D, Ginovart N, et al. An automated method for the extraction of regional data from PET images. *Psychiatry Res* 2006;147:79–89.
- Muller-Gartner HW, Links JM, Prince JL, et al. Measurement of radiotracer concentration in brain gray matter using positron emission tomography: MRI-based correction for partial volume effects. *J Cereb Blood Flow Metab* 2000;12:571–583.
- Logan J, Fowler JS, Volkow ND, Wang G-J, Ding Y-S, Alexoff DL. Distribution volume ratios without blood sampling from graphical analysis of PET data. *J Cereb Blood Flow Metab* 1996;16:834–840.
- Meyer JH. Imaging the serotonin transporter during major depressive disorder and antidepressant treatment. *J Psychiatry Neurosci* 2007;32:86–102.
- Kvernmo T, Hartter S, Burger E. A review of the receptor-binding and pharmacokinetic properties of dopamine agonists. *Clin Ther* 2006;28:1065–1078.

16. Cannon DM, Ichise M, Rollis D, et al. Elevated serotonin transporter binding in major depressive disorder assessed using positron emission tomography and [¹¹C]DASB; comparison with bipolar disorder. *Biol Psychiatry* 2007;62:870–877.
17. Meyer JH, Houle S, Sagrati S, et al. Brain serotonin transporter binding potential measured with carbon 11-labeled DASB positron emission tomography: effects of major depressive episodes and severity of dysfunctional attitudes. *Arch Gen Psychiatry* 2004; 61:1271–1279.
18. Parsey RV, Hastings RS, Oquendo MA, et al. Lower serotonin transporter binding potential in the human brain during major depressive episodes. *Am J Psychiatry* 2006;163:52–58.
19. Meyer JH. Applying neuroimaging ligands to study major depressive disorders. *Semin Nucl Med* 2008;38:287–304.
20. Talbot PS, Frankle WG, Hwang DR, et al. Effects of reduced endogenous 5-HT on the in vivo binding of the serotonin transporter radioligand 11C-DASB in healthy humans. *Synapse* 2005; 55:164–175.
21. Praschak-Rieder N, Wilson AA, Hussey D, et al. Effects of tryptophan depletion on the serotonin transporter in healthy humans. *Biol Psychiatry* 2005;58:825–830.

What Relation Is There Between Deep Brain Stimulation and Coping Strategies in Parkinson's Disease?

Sébastien Montel, PhD*
and Catherine Bungener, PhD

*Laboratory of Clinical Psychopathology and
Neuropsychology, University of Paris Descartes,
Paris, France*

Abstract: We investigated the effect of the deep brain stimulation (DBS) on coping strategies while taking depression into account. Patients with Parkinson's disease (PD) were divided into three groups matched for sex, age, and disease severity: one, just before DBS, another at 12 months post DBS, and a group of patients not being considered for DBS. Each patient was asked to complete two self-reports about their coping styles: The ways of coping check list and the coping with health, injuries, and problems scale. The Montgomery and Asberg depression rating scale was assessed by a psychologist. After control for depression, significant differences were noticed concerning two coping strategies: instrumental ($P < 0.01$) and emotional ($P < 0.05$) ones, with higher instrumental coping strategies (seeking more information) for patients prior DBS and higher emotional strategies (avoidance, emotional preoccupation) for patients not being considered for surgery. These results confirmed our clinical impression that coping strategies differ as a function of the surgical status of PD patients. © 2008 Movement Disorder Society

Key words: coping strategies; deep brain stimulation; Parkinson's disease

Although deep brain stimulation (DBS) of the subthalamic nucleus (STN) effectively improves some unpleasant, distressing symptoms of Parkinson's disease (PD) like dyskinesia, tremor or rigidity,¹ the effect of such an intervention on nonmotor symptoms (e.g. mood) are more debatable.²

When patients encounter difficulties related to their medical condition, they resort to specific coping strategies. Coping strategies have been defined as “*the overall cognitive and behavioral efforts to master,*

*Correspondence to: Sébastien Montel, 258 rue Marcadet Bat K, 75018 Paris, France. E-mail: montel.sebastien@wanadoo.fr

Potential conflict of interest: None reported.

Received 15 February 2008; Revised 9 June 2008; Accepted 16 June 2008

Published online 25 July 2008 in Wiley InterScience (www.interscience.wiley.com). DOI: 10.1002/mds.22217

*reduce or tolerate inside or outside demands which threaten or surpass personal resources.”*³

To our knowledge, few papers have studied coping strategies in PD and none have done in relation to DBS. From the studies on PD under medication, no specific style of coping emerged but it seemed that some strategies like avoidance or emotional strategies were linked to poor adjustment.⁴⁻⁶

Therefore, we examined the coping strategies used by three different groups of PD patients: those who had undergone STN DBS, those awaiting DBS, and patients not being considered for surgery. Because of the frequency of depression in PD and its relationship with coping strategies,^{5,7} we also controlled for depression.

PATIENTS AND METHODS

Between September 2004 and December 2006, 135 PD patients, distributed into three different groups were selected: 6 months before DBS ($N = 45$), 12 months after DBS ($N = 45$), and patients not being considered for surgery ($N = 45$). All were matched for sex, age, and disease severity. All participants were treated in the Department of Neurology of the Salpêtrière Hospital and were present at the hospital in the context of their treatment follow-up. All subjects (men and women) aged from 18 to 85, were invited to participate in this study. The exclusion criteria consisted of having a cognitive impairment ($MMSE < 24$)⁸ or a mental disease⁹ except for depression. All patients gave their written, informed consent.

All the neurological data was collected by a neurologist. Disease severity and motor signs were measured using the Hoehn and Yahr stages¹⁰ and the Unified Parkinson's Disease Rating Scale (UPDRS).¹¹ Their cognitive state was assessed using the Mini Mental State Examination.⁸

Then, patients were interviewed by a psychologist in order to collect their sociodemographic data. Over the course of the interview, the psychologist checked for mental disorders: current and past depression, anxiety, psychotic disorders and substance abuse (mini international neuropsychiatric interview (M.I.N.I)^{9,12}), severity of depression (Montgomery and Asberg depression rating scale, MADRS¹³). Finally, each subject was asked to complete two self-report coping questionnaires: the French version of the ways of coping checklist (WCC)^{14,15} and the coping with health, injuries and problems scale (CHIP).¹⁶ The WCC is a 29-item self-questionnaire which assesses five types of coping strategies: solving problem, avoidance, seeks social support,

positive re-evaluation, and self-blamed. All of them are summarized by two broad strategies: problem-focused coping which implies the efforts made by the subject to overcome his difficulty, and emotion-focused coping which are associated with emotional regulation. Respondents were asked to report on the coping behaviors they typically used when encountering “a stressful situation.”

The CHIP is specific to subjects suffering from somatic diseases. This 32-item questionnaire identifies four strategies: diversion (e.g. thinking about agreeable things), palliative (e.g. taking a rest to feel better), instrumental (e.g. looking for more information), and emotional preoccupation (e.g. feeling angry because of the disease). Respondents rate the extent to which they engage in various types of coping activities in order to deal with a disease using a 5-point Likert-type scale. The higher the score, the more that type of strategy is used.

These two instruments have been used for the assessment of coping strategies in PD.⁶ Avoidance, self-blamed, and emotion-focused coping (WCC) are strongly associated to emotional preoccupation (CHIP) ($P < 0.05$), while solving problem, seeks social support and problem-focused coping (WCC) are associated to instrumental strategies (CHIP) ($P < 0.05$).

We used a multiple analysis of variance model (MANOVA) for the comparison of coping strategies between groups. An analysis of covariance (MANCOVA) was carried out in order to control for depression. We also carried out a post-hoc analysis (Tukey test) to specify each effect which was found. The 1997 version of Statistica software Release 5.1 was used to perform the analysis.

RESULTS

The clinical characteristics of each group are displayed in Table 1.

Sixty percent of all the subjects were men. The mean age was 58.7 (± 9.3). The mean for H&Y stages was 1.5 (± 0.7) (on stage) and 2.3 (± 0.9) (off stage). The UPDRS scores differed significantly according to the groups. The lowest scores were observed for patients who benefited from DBS.

The MANOVA showed that daily treatment dosage and dyskinesia were substantially lower 12 months after DBS ($P < 0.01$ and $P < 0.05$). The disease duration did not vary as a function of the group ($P = 0.22$).

Twelve percent of the stimulated patients had a history of major depression disorders, while such was the

TABLE 1. *Clinical characteristics of the population as a function of the groups*

	Awaiting for DBS N = 45	12 M after DBS N = 45	Not being considered for DBS N = 45
UPDRS on state Means (SD)	10.6 (4.7)	6.7 (5.7)	18.2 (10.3)*
UPDRS off state Means (SD)	32.6 (7.3)*	13.6 (10.8)	23.7 (15.6)**
Disease duration Means (SD)	10.1 (6.5)	11.9 (5.1)	9.9 (4.5)
Treatment dosage mg Means (SD)	1160 (669.1)*	447 (322.6)	1002 (554.6)*
Dyskinesia %	82**	50	76**

* $P < 0.05$.** $P < 0.01$.

case for 13% of the patients waiting to undergo DBS and 28% of the patients not being considered for DBS ($P < 0.05$). The depression scores on the MADRS varied significantly from group to group ($P < 0.01$). Indeed, higher scores were noted for patients under medication (Mean \pm SD 9.2 ± 4.4), while patients stimulated and those awaiting DBS had lower scores (respectively Mean \pm SD 5.7 ± 4.4 and 5.6 ± 3.6).

A MANOVA enabled us to compare the coping styles of the different groups (Table 2). Given the impact of depression on the variables studied, we considered it to be covariate (MANCOVA). After controlling for depression, substantial differences were observed concerning two coping strategies: instrumental ($P < 0.01$) and emotional ($P < 0.05$) ones. The post-hoc analysis allowed us to specify each effect. Indeed, patients awaiting stimulation used significantly more instrumental coping strategies (e.g. seeking more information) than did patients not being considered for surgery ($P < 0.05$) and those who had been stimulated ($P < 0.01$), while patients not being considered for surgery used significantly more emotional coping strategies

(e.g. avoidance, emotional preoccupation) than did the two others groups ($P < 0.05$). Patients not being considered for surgery used significantly more instrumental strategies than those who had been stimulated ($P < 0.05$).

Higher score in instrumental coping strategies (CHIP) than in emotional coping strategies were observed for all groups.

As for all the other strategies, (CHIP or WCC) differences observed between the different groups did not hold up after controlling for depression.

DISCUSSION

We confirmed previous data^{1,17,18} concerning the improvement of motor signs and consequently the decrease of daily dosage treatments thanks to DBS. It seems that the effectiveness of DBS on motor signs is now clearly established, even undisputable.

We observed that score of depression remained moderate. Indeed, patients who benefited from DBS could see their motor improvement and those who

TABLE 2. *Coping strategies as a function of the groups*

	Awaiting for DBS N = 45	12 M after DBS N = 45	Not being considered for DBS N = 45
PFC (WCC) Means (SD)	38.3 (8.2)	36.6 (7.9)	36.1 (8.1)
EFC (WCC) Means (SD)	47 (10.8)	44.6 (10.2)	49.2 (9.3)*
PS (WCC) Means (SD)	23.8 (5.9)	21.8 (5.7)	22.2 (6.5)
AWT (WCC) Means (SD)	14.4 (5.5)	14.3 (5.2)	16.5 (5.1)*
SSS (WCC) Means (SD)	14.5 (4)	14.8 (3.5)	13.9 (3.5)
PR (WCC) Means (SD)	23.8 (4.5)	21.8 (3.4)	22.2 (4)
SB (WCC) Means (SD)	8.8 (4.6)	8.5 (4)	10.5 (4)
D (CHIP) Means (SD)	27.5 (6)	27 (5.3)	26 (6.1)
P (CHIP) Means (SD)	24 (5.3)	23 (4.1)	24 (5.4)
I (CHIP) Means (SD)	31 (5.8)**	27 (4.8)	29 (4.7)*
E (CHIP) Means (SD)	21 (7.6)	20 (7.5)	24 (7.1)*

PFC, problem focused coping strategies; EFC, emotional focused coping strategies; PS, problem solving; AWT, avoidance with wishful thinking; SSS, seeks social support; PR, positive re-evaluation; SB, self-blamed; D, distraction; P, palliative; I, instrumental; E, emotional preoccupation.

* $P < 0.05$.** $P < 0.01$.

were awaiting stimulation put all their hope in this surgery. We can imagine that these two situations would have a positive effect on mood. Concerning patients not being considered for DBS, their scores on MADRS were higher than the two others groups, but remained moderate.

Even when matched regarding disease severity, patients not considered for DBS presented more frequent histories of depression. We do not have a clear explanation to propose, but we must reiterate that severe depression is one of the exclusion criteria for DBS.

Concerning coping strategies, we noticed substantial differences in instrumental and emotional strategies according to the groups. In fact, patients awaiting DBS used significantly more instrumental coping strategies than did the other patients. This might be due to the fact that just before DBS, patients are always looking for more information about their disease or the latest information about the surgical procedure. However, once they have benefited from the best treatment currently available, it seems that their coping style changes. Indeed, as observed clinically, after surgery, patients are not free from all problems but their preoccupations change. They seek other means to attain their well-being or they consider their well-being differently. However, data showed higher score in instrumental coping strategies (CHIP) than in emotional coping strategies for all groups. Two explanations can be proposed. First, these results can be associated with lower scores of depression for all groups. Second, whatever the patients' surgical status, they need information and look for the improvement of their QoL.

Patients not being considered for DBS used significantly more emotional coping strategies than did patients awaiting DBS and patients who had already been stimulated. This result matched with the clinical data which showed that patients under treatment suffered from more motor signs than did patients who were stimulated and then tended to use more emotional strategies which are generally used more often in such circumstances.⁶ We can hypothesize that emotional strategies which include avoidance and self-blame do not correspond to the mood of patients who are confident in a successful outcome to their surgery and who are impatiently awaiting symptom improvement. Indeed, since they are confident, they prefer to be active in order to be ready for change. As most of the studies⁴⁻⁶ emphasized, patients with higher scores of depression used more emotional coping strategies.

However, we think that all groups of PD patients, whether they have already been stimulated, are await-

ing stimulation or not, would benefit from a psychological intervention focused on coping strategies in order to help them adapt their coping style as a function of their medical situation. It would be useful for patients not being considered for DBS who have to cope with their motor disabilities every day, for those impatiently awaiting DBS in order to help them maintain realistic expectations about the procedure, and for patients already stimulated in order to help them adapt to their new life and sometimes to the disappointment of what were over-optimistic expectations of DBS.

Acknowledgments: We thank Drs. Anne-Marie Bonnet, Marie-Laure Welter, and Sadek Yaici as well as the nurses of the "Fédération des maladies du système nerveux" of the Pitié-Salpêtrière hospital for their assistance during this research.

REFERENCES

- Houeto JL, Mallet L, Mesnage V, et al. Subthalamic stimulation in Parkinson disease: behavior and social adaptation. *Arch Neurol* 2006;63:1090-1095.
- Drapier S, Raoul S, Drapier D, et al. Only physical aspects of quality of life are significantly improved by bilateral subthalamic stimulation in Parkinson's disease. *J Neurol* 2005;252:583-588.
- Lazarus R, Folkman S. *Stress, appraisal and coping*. New York: Springer; 1984.
- Moore KA, Seeney F. Biopsychosocial predictors of depressive mood in people with Parkinson's disease. *Behav Med* 2007;33:29-37.
- Ehmann TS, Beninger RJ, Gawel MJ, et al. Coping, social support, and depressive symptoms in Parkinson's disease. *J Geriatr Psychiatry Neurol* 1990;3:85-90.
- Montel S, Bonnet AM, Bungener C. Quality of life in relation to coping, mood and dyskinesia in Parkinson's Disease. *J Geriatr Psychiatry Neurol* (in press).
- Ravina B, Camicioli R, Como PG, et al. The impact of depressive symptoms in early Parkinson disease. *Neurology* 2007;69:342-347.
- Folstein MF, Folstein SE, Mc Hugh PR. Mini mental scale: a practical method for grading the cognitive state of patients for the clinician. *J Psychiatr Res* 1975;12:189-198.
- American Psychiatric Association. *Diagnostic and statistical manual of mental disorders*, 4th ed. Revised (DSM IV-TR). Washington, DC: American Psychiatric Association; 2000.
- Hoehn M, Yarh M. Parkinsonism: onset, progression and mortality. *Neurology* 1967;17:427-442.
- Fahn S, Elton R, Members of the UPDRS Development Committee. In: Fahn S, Marsden CD, Calne DB, Goldstein M, editors. *Recent developments in Parkinson's disease*, Vol 2. Florham Park, NJ: Macmillan Health Care Information; 1987. p 153-163, 293-304.
- Leclercq Y, Weiller E, Hergueta T, et al. M.I.N.I. 5.0.0, French Version, DSM-IV, 1999.
- Montgomery SA, Asberg M. A new depression scale designed to be sensitive to change. *Br J Psychiatry* 1979;34:382-389.
- Vitaliano PP, Russo J, Carr JE, et al. The ways of coping checklist: revision and psychometric properties. *Multivariate Behav Res* 1985;20:3-26.
- Paulhan I, Nuissier J, Quintard B, et al. La mesure du coping. Traduction et validation de la version Française de l'échelle Vitaliano. *Ann Med Psychol* 1994;152:292-299.

16. Endler NS, Parker JDA, Summerfelt LJ. Coping with health problems: developing a reliable and valid multidimensional measure. *Psychol Assess* 1998;10:195–205.
17. Krack P, Batir A, Van Blercom N, et al. Five-year follow-up of bilateral stimulation of the subthalamic nucleus in advanced Parkinson's disease. *N Engl J Med* 2003;349:1925–1934.
18. Tir M, Devos D, Blond S, et al. Exhaustive, one-year follow-up of subthalamic nucleus deep brain stimulation in a large, single-center cohort of Parkinsonian patients. *Neurosurgery* 2007;61:297–304.

Arm Swing Is Reduced in Idiopathic Cervical Dystonia

Georg Kägi, MD, Petra Schwingenschuh, MD,
and Kailash P. Bhatia, MD*

Sobell Department of Motor Neuroscience and Movement Disorders, Institute of Neurology, University College London, National Hospital for Neurology and Neurosurgery, Queen Square, London, United Kingdom

Video 

Abstract: Arm swing is typically reduced in people with Parkinsonism, and also in those with pyramidal dysfunction. We have previously observed that patients with focal arm dystonia can also have reduced arm swing. However, arm swing has not been formally studied in adult-onset primary cervical dystonia (AOPCD). We assessed arm swing in 100 consecutive patients diagnosed with AOPCD and 50 healthy controls. Reduced arm swing was more common in patients with AOPCD compared with healthy controls (55% vs. 6%, $P < 0.001$) and was more often abnormal on the same side as the direction of head turning ($P < 0.05$). Women with AOPCD had more often reduced arm swing compared with men ($P = 0.002$). Reduced arm swing is common in AOPCD. It may indicate segmental spread of subtle motor dysfunction or it may be a feature of dystonia per se. © 2008 Movement Disorder Society

Key words: adult-onset primary cervical dystonia; arm swing; Parkinson's disease

Additional Supporting Information may be found in the online version of this article.

*Correspondence to: Dr. Kailash P. Bhatia, Sobell Department of Motor Neuroscience and Movement Disorders, Institute of Neurology, University College of London, Queen Square, London WC1N 3BG, UK. E-mail: k.bhatia@ion.ucl.ac.uk

Potential conflict of interest: None reported.

Received 3 April 2008; Revised 21 May 2008; Accepted 16 June 2008

Published online 25 July 2008 in Wiley InterScience (www.interscience.wiley.com). DOI: 10.1002/mds.22216

Adult-onset primary cervical dystonia (AOPCD) is the most common form of adult-onset focal dystonia¹ and is characterized by sustained, involuntary contractions of the neck muscles resulting in abnormal postures and sometimes tremor of the head.² The incidence is sex- and age-dependent. Women are affected 1.5 to 1.9 times more often than men, and in both men and women, the peak incidence is in the fifth decade. In 70 to 90% of cases, disease onset is between the fourth and sixth decade of life.^{2–5} Extracervical dystonia (oromandibular, blepharospasm, focal hand dystonia, or axial dystonia) is found in ~20%^{2,4,6} and a postural or kinetic hand tremor in ~25% of patients with AOPCD.

Asymmetry of arm swing is recognized in a number of neurological disorders such as hemiparesis or Parkinson's disease. Indeed, the diagnosis of Parkinson's disease is often supported clinically by the finding of unilateral loss of arm swing. From our clinical experience, we have observed that arm swing may be reduced in patients with focal arm dystonia, for example, writer's cramp. Furthermore, we have recently reported the presence of reduced arm swing in patients with adult-onset dystonic arm tremor, many of whom were misdiagnosed with Parkinson's disease.⁷ We wondered how common reduced arm swing might be in other dystonic conditions, and therefore, we formally investigated arm swing in 100 consecutive patients with AOPCD.

PATIENTS AND METHODS

We recruited 100 consecutive patients with AOPCD, who were attending a botulinum toxin clinic at the National Hospital for Neurology and Neurosurgery. We also recruited 50 healthy controls matched for age, gender, and handedness. In the patients, we specifically recorded the direction of head turn and any abnormality of arm swing. Torticollis was defined as head deviation in the horizontal, laterocollis as deviation in the coronal, and ante-/retrocollis as deviation in the sagittal plane. The side of head deviation was defined as the side of torticollis or, if absent, the side of laterocollis. For the assessment of arm swing, patients were asked to walk a standardized distance of 6 m back and forth twice, with a gait velocity judged by them to be "normal walking speed." Arm swing was observed by an experienced movement disorders neurologist (GK), and patients were also videotaped. Arm swing was classified as either "normal" when there was a good amplitude on both sides without asymmetry (see video, segment 1), as "mildly" reduced when there was some

TABLE 1. Patient characteristics and results

	Adult-onset primary cervical dystonia			Controls		
	Total	Normal arm swing	Abnormal arm swing	Total	Normal arm swing	Abnormal arm swing
Number	100	45	55 ^a	50	47	3 ^a
Sex M:F	1:3 ^b	1:1.05	1:6.9	1:2.75 ^b	1:2.57	2:1
Age, mean \pm SD (yr)	58.3 \pm 11.2 ^c	56.8 \pm 11.1	59.5 \pm 11.3	61.0 \pm 11 ^c	60.5 \pm 11.1	69.3 \pm 3.5
Disease duration, mean \pm SD (yr)	14.6 \pm 8.8	16 \pm 10	13.5 \pm 7.6	–	–	–
Right handed, n (%)	90 (90) ^b	40 (89)	50 (91)	47 (94) ^b	44 (94)	3 (100)
Results of patients with abnormal arm swing						
Side (right/left/both)	–	–	33/14/8			3/0/0
Degree of reduced arm swing n (%)						
Mild	21 (21)	–	21 (38.2)	1 (2)	–	1 (33.3)
Moderate	32 (32)	–	32 (58.2)	2 (4)	–	2 (66.6)
Severe	2 (2)	–	2 (3.6)	0	–	0

^aChi-square test; $P < 0.001$.

^bChi-square test; no significant difference between patients with AOPCD and healthy controls.

^c t test; no significant difference between patients with AOPCD and healthy controls.

reduction of the amplitude on one or both sides (see video, segment 2), as “moderately” reduced when arm swing was still present but with low amplitude (see video, segment 3), and as “severely” reduced when there was no clear arm swing (see video, segment 4).

Statistical Analysis

Results were analyzed using the SPSS statistical package for *Windows v. 14.0*. After finding a normal distribution, age (patients/controls) was compared using the Student's t test, and age and disease duration between the subgroups with different degrees of reduced arm-swing using ANOVA. Binominal data (arm swing, side of reduced arm swing, side of cervical dystonia, gender, handedness) were compared using chi-square tests. Spearman's ratio was calculated to correlate age and disease duration with the degree of reduced arm swing and to correlate handedness with the side of reduced arm swing. A P value of < 0.05 was considered significant.

RESULTS

The gender, mean ages, disease duration, handedness, and arm swing of patients and healthy controls are summarized in Table 1. Ninety-five percent of patients had torticollis or a combination of torticollis, laterocollis, and ante-/retrocollis. The remaining 5% had laterocollis (3%) or dystonic head tremor (2%) only. The frequency of reduced arm swing was significantly more common in patients with cervical dystonia compared with controls (55% vs. 6%, $P < 0.001$). In patients with cervical dystonia, 47 (85.5%) had reduced arm swing on one side and 8 (14.5%) had

reduced arm swing on both sides. Where present, reduced arm swing was more common on the right side in both patients (60%) and controls (100%), but bilaterally reduced arm swing occurred only in patients with cervical dystonia and not controls. In 54.7% of patients with reduced arm swing, it was reduced on the same side of head deviation, 30.4% on the opposite side, and in 14.5% on both sides. Overall, reduced arm swing was twice as common on the right side.

The degree of reduced arm swing in patients with abnormal arm swing was mild in 38.2%, moderate in 58.2%, and severe in 3.6%. In the three controls with abnormal arm swing, it was mild in one (33.3%) and moderate in two (66.6%). There was no significant difference in age, disease duration, or handedness between those subgroups with normal, mildly, or moderately reduced arm swing (the group with severely reduced arm swing was not statistically evaluated because of the low numbers). Age and disease duration did not correlate with the degree of reduced arm swing and handedness did not correlate with the side of reduced arm swing. The distribution of gender was significantly different in the group of patients with normal arm swing (M/F = 1:1.05) compared with the group of patients with abnormal arm swing (M/F = 1:6.9), $P = 0.002$. None of the patients or controls had any parkinsonian features or pyramidal dysfunction, and the rest of their neurological examination was normal apart from dystonia.

DISCUSSION

To our knowledge, this is the first study to describe reduced arm swing in patients with cervical dystonia. Arm swing was reduced in the majority (55%) of

patients with AOPCD compared with 6% of healthy controls. Reduced arm swing was particularly common in women with AOPCD (even after correcting for the sex bias that cervical dystonia itself is more common in women) and more commonly affected the right side.

Loss of the associated synergistic arm movements when walking is seen in akinetic-rigid syndromes, pyramidal tract lesions affecting the arm, and acute cerebellar lesions. Unilateral loss of associated arm swing when walking may be the first clinical sign in early Parkinson's disease.^{8,9} However, none of our patients with AOPCD had features of Parkinsonism or pyramidal dysfunction even after a median disease duration of 14.6 years. This leads us to conclude that the decreased arm swing we observed can be part and parcel of dystonia itself.

We have previously reported that patients with adult-onset dystonic tremor affecting the arms (which was often associated with dystonic postures of the arms) frequently have reduced arm swing.⁷ We and others have also previously noted anecdotally that reduced arm swing can occur in patients with pure focal arm dystonia without associated tremor. However, we did not observe signs of dystonia or tremor in the arms of any of our patients with AOPCD, even those with reduced arm swing. It is possible that the reduced arm swing in these patients represents a segmental spread of subtle motor system dysfunction to the arm, which is sufficient to cause reduced arm swing, but is not sufficient to cause overt dystonic postures or tremor.

It is well recognized that a degree of asymmetry in arm swing is physiological and therefore present in healthy subjects. A recent study in normal subjects using quantitative gait analysis has shown that the right arm tends to swing less than the left regardless of handedness.¹⁰ Nevertheless, it is interesting that in our patients with AOPCD as well as in our controls we have reproduced this pattern with reduced arm swing seen predominantly on the right side. However, there was no correlation with handedness.

Why reduced arm swing should occur much more in women with AOPCD than in men is not clear. One could speculate that focal dystonia may have a higher tendency to spread from the focal (cervical) dystonia toward a segmental distribution in women.

In summary, we have shown that reduced arm swing is common in patients with AOPCD, and we propose that it is part and parcel of primary focal/segmental dystonia affecting the neck. The importance of this observation, in combination with our previously published data in adult-onset dystonic tremor, is that

reduced arm swing appears to be a frequent occurrence in patients with dystonia.⁷ It can therefore present a chance for clinical confusion, given the historical link between reduced arm swing and Parkinson's disease. Although it is unlikely that clinicians would misdiagnose a patient with clear cervical dystonia and reduced arm swing as Parkinson's disease (in contrast to the clear risk of doing so in a patient with dystonic tremor of the arm), there are other situations where awareness of the presence of reduced arm swing in patients with AOPCD are more important. One of the most important clinical decisions to make when assessing a patient with dystonia is to decide whether they have primary dystonia (defined as dystonia +/- tremor as the only clinical signs) or whether they have a secondary/degenerative dystonia. In this context, the misattribution of reduced arm swing as a sign of possible secondary/degenerative dystonia becomes important, as it could lead to unnecessary investigation and diagnostic confusion. Clinicians should therefore be aware that, in patients with movement disorders, reduced arm swing is not just a sign associated with Parkinsonism, and can occur in the context of uncomplicated primary dystonia.

LEGENDS TO THE VIDEO

- Segment 1.** This woman has mild torticollis to the right side and normal arm swing when walking.
- Segment 2.** This man has torticollis to the right and laterocollis to the left side and mildly reduced arm swing on the right side when walking.
- Segment 3.** This woman has torticollis to the right side and moderately reduced arm swing on the right side when walking.
- Segment 4.** This woman has torticollis to the right side and severely reduced arm swing on the right side when walking.
- Segment 5.** This woman has torticollis to the right side and bilaterally reduced arm swing slightly more pronounced on the right side.

Acknowledgments: GK was supported by a grant from the Swiss Parkinson's Disease Association.

REFERENCES

1. Nutt JG, Muenter MD, Aronson A, Kurland LT, Melton LJ, III. Epidemiology of focal and generalized dystonia in Rochester, Minnesota. *Mov Disord* 1988;3:188-194.
2. Jankovic J, Leder S, Warner D, Schwartz K. Cervical dystonia: clinical findings and associated movement disorders. *Neurology* 1991;41:1088-1091.
3. Duane DD. Spasmodic torticollis. *Adv Neurol* 1988;49:135-150.

4. Chan J, Brin MF, Fahn S. Idiopathic cervical dystonia: clinical characteristics. *Mov Disord* 1991;6:119–126.
5. Rondot P, Marchand MP, Dellatolas G. Spasmodic torticollis—review of 220 patients. *Can J Neurol Sci* 1991;18:143–151.
6. Dauer WT, Burke RE, Greene P, Fahn S. Current concepts on the clinical features, aetiology and management of idiopathic cervical dystonia. *Brain* 1998;121:547–560.
7. Schneider SA, Edwards MJ, Mir P, et al. Patients with adult-onset dystonic tremor resembling parkinsonian tremor have scans without evidence of dopaminergic deficit (SWEDDs). *Mov Disord* 2007;22:2210–2215.
8. Thomson PD. Clinical neurological assessment of balance and gait disorders. In: Bronstein AM, Brandt T, Nutt J, Woollacot MH, editors. *Clinical disorders of balance, posture and gait*. London: Arnold; 2004. p 93–98.
9. Rubino FA. Gait disorders. *Neurologist* 2002;8:254–262.
10. Kutz-Buschbeck JP, Brockmann K, Gilster R, Koch A, Stolze H. Asymmetry of arm-swing not related to handedness. *Gait Posture* 2008;27:447–454.