

Infectious Collet-Sicard syndrome in the differential diagnosis of cerebrovascular accident: a case of head-to-neck dissociation with skull-based osteomyelitis

Tarek A. Sibai, MD^a, Peleg J. Ben-Galim, MD^{a,*}, Susan A. Eicher, MD^b, Charles A. Reitman, MD^b

^aDepartment of Orthopedic Surgery, Baylor College of Medicine, 1709 Dryden St., 12th floor, Houston, TX 77030, USA

^bDepartment of Otolaryngology-Head & Neck Surgery, Baylor College of Medicine, Houston, 1709 Dryden St., 12th floor, Houston, TX 77030, USA

Received 21 January 2008; accepted 19 May 2008

Abstract

BACKGROUND CONTEXT: Collet-Sicard syndrome (CSS) is a rare condition that includes palsies of cranial nerves IX, X, XI, and XII. There are multiple reported causes in the literature, although infection is particularly unusual.

PURPOSE: To report an unusual case of CSS as a result of infection causing head-to-neck dissociation with involvement of the upper cervical spine.

STUDY DESIGN: Case report.

METHODS: A 56-year-old male with medical comorbidities developed a cranial-based infection secondary to initial incomplete treatment of otitis media. The mass effect of the infection resulted in multiple cranial nerve palsies and extremity symptoms initially confused with a cerebrovascular accident. Clinical course of the patient and a review of CSS are presented.

RESULTS: With progression of the disease, further evaluation revealed a disseminated upper cervical and skull-based infection causing destructive head-to-neck infectious instability. This was treated with posterior occipitocervical debridement, fixation, and fusion and appropriate long-term antibiotics. Over the course of several months, the infection resolved and there was a significant improvement in his dysphagia, dysarthria, and hearing.

CONCLUSIONS: Delay in diagnosis of CSS is common, and this syndrome should be considered in patients who present with a constellation of lower cranial nerve palsies. Early recognition and treatment should result in successful recovery, but even in cases of delayed detection, suitable intervention can result in substantial clinical improvement. © 2009 Elsevier Inc. All rights reserved.

Keywords:

Collet-Sicard syndrome; Skull-based osteomyelitis; Cerebrovascular accident; Occipitocervical dissociation; Posterior occipitocervical fixation

Introduction

Collet-Sicard syndrome (CSS) is a collective term comprising disorders associated with cranial nerve palsy involving the ninth, tenth, eleventh, and twelfth cranial nerves. This produces paralysis of the vocal cords, the palate and the trapezius muscle, sternocleidomastoid muscle; secondary loss of the sense of taste in the back of the tongue, and anesthesia of the larynx, pharynx, and soft palate. Collet [1] in 1915

described the syndrome as glossolaryngoscapulopharyngeal hemiplegia and Sicard [2] in 1917 as the syndrome of the condyloposterior lacerated foramen. It is a variant of the Villaret syndrome, unaccompanied by the Horner syndrome. More reports associate this syndrome with symptoms related to mass effect (tumor or metastasis), trauma, or vascular problems. We present a case of CSS related to infection, the onset of which is the result of otitis media with propagation of the infection to the skull base.

Case study

A 56-year-old African-American man with Type 2 diabetes mellitus and a history of a cerebrovascular accident

FDA device/drug status: not applicable.

* Corresponding author. Department of Orthopedic Surgery, Baylor College of Medicine, 1709 Dryden St., 12th floor, Houston, TX 77030, USA. Tel.: (713) 986-6010; fax: (713) 986-7391.

E-mail address: galim@bcm.tmc.edu (P.J. Ben-Galim)

in 1998 was admitted for complicated left otitis media in February, 2006. Cultures from his ear discharge grew coagulase negative staphylococcus, which was treated with a 5-day hospital course of intravenous (IV) Clindamycin. He was discharged in stable condition to complete home IV antibiotics. Two months later, he presented to our community hospital with dysphagia to solids and liquids, decreased auditory acuity more prominent on the left, hoarseness, left facial palsy and left neck pain without fever, chills or otalgia. Physical examination revealed an apprehensive, afebrile, dysarthric patient with left-sided facial palsy, left-sided tongue deviation along with right-sided upper extremity weakness and parasthesia in the ulnar aspect of the right hand. He was diagnosed as having a recurrent cerebrovascular accident and was transferred to a stroke rehabilitation program at the local city hospital.

Two months into his rehabilitation, he presented again to our community hospital when his neck pain significantly increased and after developing severe torticollis with a peculiar rotatory head tilt. X-rays of the neck (Fig. 1) showed acute tilting of the head over the upper neck with resorption of the occipito-atlantal articulation and part of the C1 vertebra on the left. Computed tomography scan of the head and neck (Fig. 2) revealed no acute infarct with chronic small vessel ischemic changes, destruction of C1 anterior arch, odontoid tip and clivus, and severe degenerative changes extending to the level of C7. Magnetic resonance imaging (MRI) of the head and neck (Fig. 3) revealed the extent of the infectious process, which encompassed the skull base foramen for these cranial nerves on the left side,

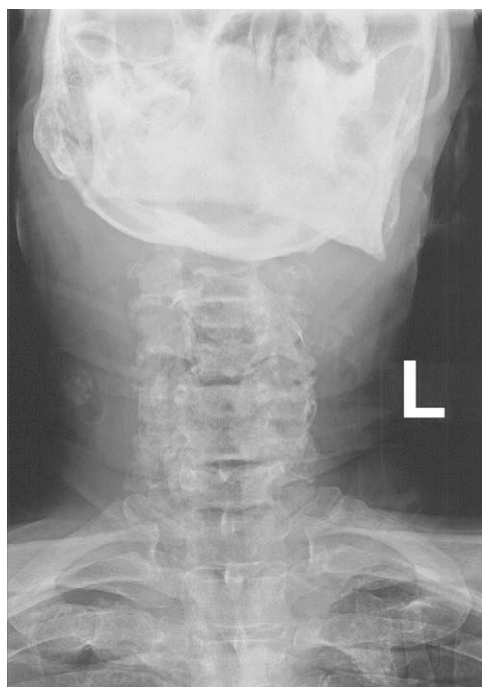

Fig. 1. Anteroposterior radiograph of the neck showing acute tilting of the head over the upper neck with resorption of the occipito-atlantal articulation and part of the C1 vertebra on the left.

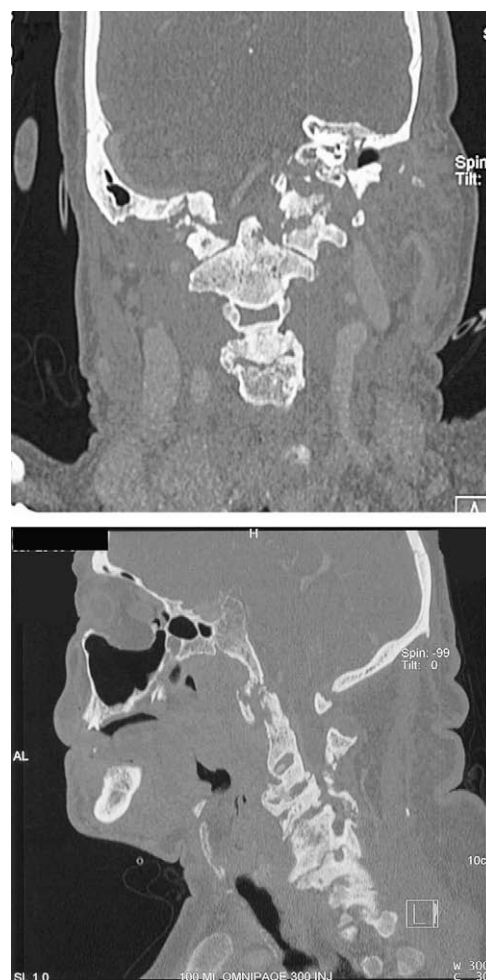


Fig. 2. (Top) Preoperative coronal computed tomography (CT) reconstruction showing the extensive osteomyelitic destruction extending from the mastoid process into the occipitocervical condyle joint on the left with some of the odontoid process as well. (Bottom) Preoperative sagittal midline CT scan showing destruction of C1 anterior arch, odontoid tip and clivus, and severe degenerative changes extending to the level of C7.

left mastoid, anterior occipital bone, and temporomandibular joint with destructive resorption of the bone and joints at the occipital-cervical junction (occipital condyle, lateral mass of C1, and part of the dens) consistent with an infectious soft-tissue phlegmon and skull-based osteomyelitis. The MRI also confirmed the chronic degenerative cervical disease causing spinal canal stenosis from C4 to C7. Examination by an Ear, Nose and Throat (ENT) consultant revealed palsy of cranial nerves VII, IX, X, XI, and XII as accounting for this “stroke-like” presentation.

The apparent head-to-neck dissociation and associated instability prompted orthopedic spine surgery consultation. In addition to the cranial nerve findings, further examination revealed signs and symptoms consistent with myeloradiculopathy with numbness in bilateral upper extremities, a L’hermites sign, hyperreflexia, and clonus. As a result of the neurological deficits as well as imaging findings including upper cervical destruction and subaxial cervical

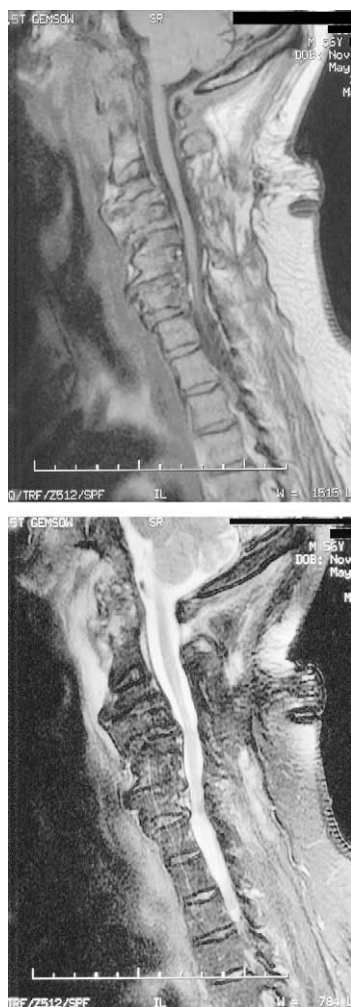


Fig. 3. Sagittal midline T1 magnetic resonance imaging with (Top) enhancement and (Bottom) fast spin echo sequence showing destruction of C1 anterior arch, odontoid tip, and clivus all engulfed within an infectious enhancing phlegmon.

stenosis, it was decided that his condition would be optimally managed by culture-specific antibiotics as well as subaxial decompression and stabilization from the occiput to C7. He was started initially on empiric Moxifloxacin and Ceftazidime to cover for suspected pseudomonas infection (malignant otitis externa with previous treatment failure with IV Clindamycin) and to cover for the risk of meningitis. He underwent abscess decompression by insertion of a pressure equalizing tube by ENT before fixation of the spine. His ear fluid cultures eventually grew methicillin-resistant *Staphylococcus epidermidis* and *Corynebacterium*. At that point, Vancomycin was added to his antibiotic regimen. Depending on the response of the neurological exam to this initial stabilization and antibiotic treatment, staged anterior upper cervical decompression was also considered. Thus, the patient underwent posterior occiput to C7 fusion and instrumentation with iliac crest autograft. The fusion spanned from the occiput to C2 and then segmentally down to C7.

His neurological condition showed initial signs of improvement 5 days after surgery and antibiotic therapy. He proceeded to complete a 6-week hospital course of IV triple antibiotic therapy (ceftazidime, moxifloxacin, and vancomycin). Because of persistent deficits, he also received a percutaneous endoscopic gastrostomy tube for his dysphagia and high aspiration risk as well as a hearing aid device for left sensory-neural hearing deficit. Serial in hospital examination, labs with serial normal white blood cell (WBC) counts and a down trending erythrocyte sedimentation rate (ESR) and C-reactive protein (CRP) levels, and MRI demonstrated improvement in his infectious process, thus further anterior upper cervical decompression did not appear to be necessary. He was discharged from the hospital in good medical condition with the percutaneous endoscopic gastrostomy feeding tube.

Follow-up in the months thereafter showed resolution of the infectious process with good spinal alignment (Fig. 4) and continuous slow improvement in cranial nerve function. On his 1-year follow-up, the patient's facial droop

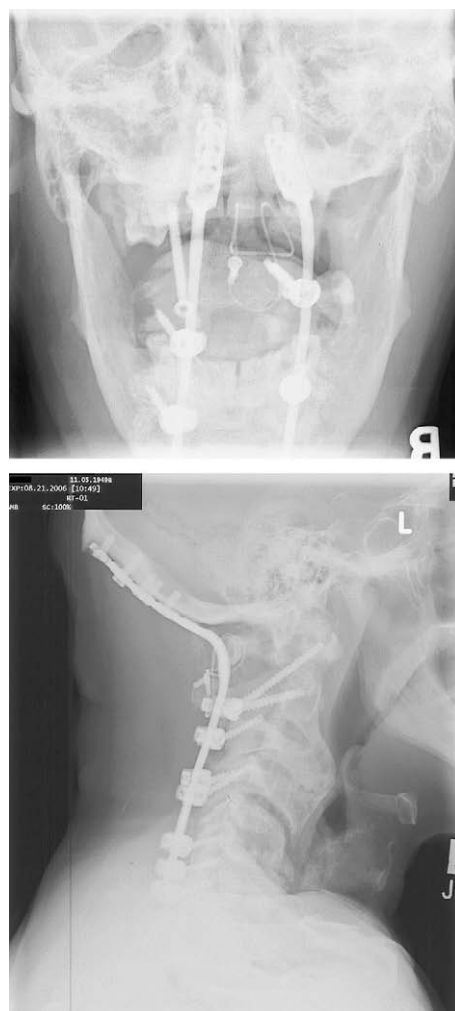

Fig. 4. Anteroposterior (Top) open mouth and (Bottom) lateral half-year postoperative plain films showing good alignment with maintenance of all hardware placements.

completely resolved, he was able to speak fluently and coherently and was swallowing liquids and small quantities of solids.

Discussion

Osteomyelitis of the cervical spine is estimated to represent only 5.9% of all osteomyelitis cases [3]. Involvement of the occipitocervical joint is more unusual, and often poses a diagnostic challenge [4,5]. If the infectious process advances enough, ultimately mass effect on the upper cervical spinal cord and skull base cranial nerves can result in a variety of neurological complaints. Our patient presented with a constellation of symptoms involving palsy of cranial nerves IX, X, XI, XII, or CSS. Earlier reports in the literature describe CSS as being caused by trauma [6–8], tumors, and metastatic cancers of the skull base [9–13]. More recent reports have attributed internal carotid artery dissection [14] and coiling [15], polyarteritis nodosa [16], and jugular vein thrombosis [17] to this rare syndrome. Review of the Medline database from 1950 till 2007 did not reveal prior reports of an infectious process, osteomyelitis of the skull base as in our case, as a causative factor. Furthermore, involvement of the seventh cranial nerve is extremely rare with only two previous reported cases [12,18]. In skull-based osteomyelitis, prompt diagnosis before the onset of neurologic symptoms usually allows for nonsurgical, medical treatment [19]. However, if neurological symptoms are present, surgical therapy with decompression of neural structures may be required depending on the severity of the deficit and the response to medical therapy. Additional stabilization procedures may be necessary if there is advancement of the destructive process to include those structures necessary for maintenance of upper cervical stability as occurred in this case. Other than temporary cervical bracing, no other initial correction was performed before surgery. Traction was contraindicated because of the potential susceptibility to overdistraction and further neurological injury in the presence of occipitocervical dissociation. Although there was concern for placing instrumentation in the presence of infection, there is evidence that this can be done safely and effectively [20–22]. We did avoid placing a screw in the lateral mass of C1 on the left, which was the location of primary infectious mass. In addition, the primary infection was anterior, while the instrumentation was placed more posterior. Furthermore, the patient was treated with culture-specific antibiotics and underwent abscess decompression by insertion of a pressure equalizing tube by ENT before fixation of the spine.

The patient's presentation including the facial palsy, dysarthria, dysphagia along with arm weakness (that was later found to be the result of chronic degenerative cervical myeloradiculopathy), and the previous history of stroke led to the initial misdiagnosis of stroke and to the delay in appropriate management. Delay in diagnosis of this syndrome is common because of its rare presentation, and is

often initially confused with a primary intracranial event. Awareness of CSS as part of the differential diagnosis for this constellation of cranial nerve palsies is necessary to help minimize diagnostic delay. In this report, we also aimed to highlight the importance of early and aggressive treatment of infections around the skull base and upper cervical spine. These can lead to severe brainstem cranial nerve palsies as in CSS and possible residual neurological deficits, if not promptly addressed and treated. Early intervention can in turn minimize potential complications associated with this syndrome.

Acknowledgments

We are greatly indebted to John Hipp, PhD, for his expertise and to Merle Husband's valuable assistance. This work could not have been completed without their valued contribution.

References

- [1] Collet FJ. Sur un nouveau syndrome paralytique pharyngo-larynge par blessure de guerre (hemiplegie glosso-laryngo-scapulo-pharyngee). *Lyon Med* 1915;124:121–9.
- [2] Sicard JA. Syndrome du carrefour condylodechire posterieur (type pur de paralysie des quatre derniers nerfs craniens). *Mars Med* 1917;53:385–97.
- [3] Malawski SK, Lukawski S. Pyogenic infection of the spine. *Clin Orthop* 1991;272:58–66.
- [4] Forsythe M, Rothman RH. New concepts in the diagnosis and treatment of infections of the cervical spine. *Orthop Clin North Am* 1978;9:1039–51.
- [5] Frederickson B, Hansen Y, Olans R. Management and outcome of pyogenic vertebral osteomyelitis. *Clin Orthop* 1978;131:160–7.
- [6] Sharma BS, Mahajan RK, Bhatia S, Khosla UK. Collet-Sicard syndrome after closed head injury. *Clin Neurol Neurosurg* 1994;96:197–8.
- [7] Connolly B, Turner C, Devine J, Gerlinger T. Jefferson fracture resulting in Collet-Sicard syndrome. *Spine* 2000;25:395–8.
- [8] Hsu HP, Chen ST, Chen CJ, Ro LSA. Case of Collet-Sicard syndrome associated with traumatic atlas fractures and congenital basilar invagination. *J Neurol Neurosurg Psychiatry* 2004;75:782–4.
- [9] Satoh H, Nishiyama T, Horiguchi A, et al. Case of Collet-Sicard syndrome caused by skull base metastasis of prostate carcinoma. *Nippon Hinyokika Gakkai Zasshi [Japanese J Urol]* 2000;91:562–4.
- [10] Nagata H, Sato S, Tanaka K, et al. Skull base metastasis of the breast cancer causing the Collet Sicard syndrome—a case report. *No To Shinkei [Brain Nerve]* 1980;32:695–700.
- [11] Tappin JA, Satchi G, Corless JA, Ashworth F. Multiple myeloma presenting as the Collet-Sicard syndrome. *J Neurol Neurosurg Psychiatry* 1996;60:14.
- [12] Prashant R, Franks A. Collet-Sicard syndrome—a report and review. *Lancet Oncol* 2003;4:376–7.
- [13] Garcia-Escriba A, Pampliega Perez A, Martin-Estefania C, Botella C. Schwannoma of the hypoglossal nerve presenting as a syndrome of Collet Sicard. [Spanish]. *Neurologia* 2005;20:311–3.
- [14] Heckmann JG, Tomandl B, Duhm C, et al. Collet-Sicard syndrome due to coiling and dissection of the internal carotid artery. *Cerebrovasc Dis* 2000;10:487–8.
- [15] Silverstrini M, Floris R, Tagliati M, et al. Collet-Sicard syndrome caused by a coiling of the internal carotid artery. *Rev Neurol* 1991;61:135–6.

- [16] Krystkowiak P, Vermersch P, Maurrage CA, Petit H. Collet-Sicard syndrome disclosing periarteritis nodosa. *Rev Neurol (Paris)* 1998;154:777–9.
- [17] Otto M, Otto V, Göttinger R, Cordes P, Wessel K. Collet-Sicard's syndrome as a result of jugular vein thrombosis. *J Neurol* 2001;248:143–4.
- [18] Comacchio F, D'Eredita R, Poletto E, et al. Hemangiopericytoma of the skull base and Collet-Sicard syndrome, a case report. *Ear Nose Throat J* 1995;74:845–7.
- [19] Spies E, Stücker R, Reichelt A. Conservative management of pyogenic osteomyelitis of the occipitocervical junction. *Spine* 1999;24: 818–22.
- [20] Michael R, Stoltze D, Harry M, Ames M, Harms J. Treatment of vertebral osteomyelitis by radical debridement and stabilization using titanium mesh cages. *Spine* 2007;32:E275–80.
- [21] Korovessis P, Petsinis G, Koureas G, Iliopoulos P, Zacharatos S. Anterior surgery with insertion of titanium mesh cage and posterior instrumented fusion performed sequentially on the same day under one anesthesia for septic spondylitis of thoracolumbar spine: is the use of titanium mesh cages safe? *Spine* 2006;31:1014–9.
- [22] Aryan H, Lu D, Acosta F, Ames C. Corpectomy followed by the placement of instrumentation with titanium cages and recombinant human bone morphogenetic protein-2 for vertebral osteomyelitis. *J Neurosurg Spine* 2007;6:23–30.