

# Effect of Ibudilast on Non-specific Symptoms in Patients with Chronic Cerebral Ischemia

## Analysis of cerebral blood flow

Nobuhiro Inoue, Mikio Harada

Department of Neurosurgery, Kumamoto Neurosurgical Hospital, Kumamoto (Japan)

**Corresponding author:** Nobuhiro Inoue, M.D. Ph.D., 6-1-21 Honjo Kumamoto, 860-0811 Kumamoto (Japan);  
e-mail: kenshin-info@iris.ocn.ne.jp

## Abstract

**Background and purpose:** Many patients with chronic cerebrovascular disease complain that dizziness and depression negatively affect their daily lives. In these patients, ibudilast (CAS 50847-11-5) reportedly ameliorated dizziness. The efficacy of ibudilast was investigated and its effect on the cerebral blood flow (CBF) was recorded.

**Methods:** The study population consisted of 11 patients (male and female) with chronic cerebrovascular disease complaining of dizziness or depression. They received 30 mg of ibudilast orally per day. The grade of vertigo and depression at entry into this study and 2 and 6 months after the start of therapy was recorded. Their depressive state was scored with the Japan Stroke Scale-Depression Scale (JSS-D) and their cerebral blood flow (CBF) was measured before and approximately 3 months after the start of ibudilast therapy.

**Results:** At 6 months after the start of ibudilast therapy, all patients reported the resolution of dizziness; of the 6 patients with depression at entry, all experienced significant improvement. At 3 months, the CBF was significantly increased in the right frontal ( $p = 0.019$ ) and occipital cortex ( $p = 0.004$ ) with no significant changes in the cerebellar folia,

subcortical gray matter (striatum and thalamus), and other cerebral cortices in the right cerebral hemisphere. There were no significant CBF changes in any areas of the left cerebral hemisphere.

**Conclusion:** In patients treated with ibudilast, the amelioration of dizziness and depression was accompanied by a CBF increase in the right frontal and occipital cortices. These findings suggest that the right frontal and occipital cortices may be related to their dizziness and depression.

## Key words

- CAS 50847-11-5
- Depression, post-stroke
- Ibudilast, cerebral ischemia, clinical study
- Ketas<sup>®</sup>
- Phosphodiesterase inhibitors
- Vertigo

Arzneimittel-Forschung  
(Drug Research)  
2008;58(6):277-282

## 1. Introduction

Vertigo, dizziness and unsteadiness are symptoms frequently reported by patients in the chronic stage after stroke. The term “dizziness” has been applied to vertigo, lightheadedness, presyncope, anxiety, and general malaise [1–4]. Although the percentage of patients whose dizziness symptoms are unequivocally attributable to stroke is low, considering the large number of stroke patients who report dizziness symptoms at evaluation [5], the true number of patients whose dizziness symptoms are due to a stroke etiology may be high [6]. Dizziness as a non-specific complaint may also be related to depression [7]. The association between cerebrovascular disease and depression has been recognized [8, 9] and a 20-40% incidence of post-stroke depression (PSD) has been reported [10].

Ibudilast (CAS 50847-11-5) acts as a phosphodiesterase (PDE)-4 inhibitor via modulation of the cyclic adenosine monophosphate (cAMP) second messenger system [11, 12]. It is widely used for the treatment of central nervous system disorders (such as depression) and asthma.

It has been shown to elevate the cerebral blood flow (CBF) in patients with chronic ischemic cerebrovascular lesions [13, 14] and to ameliorate dizziness in the chronic stage of cerebral infarction [15]. However, the pathophysiological mechanism(s) underlying its effects remain to be elucidated.

In this study, we investigated whether the ibudilast-induced amelioration of non-specific clinical symptoms in patients in the chronic stage of cerebral ischemia is attributable to an increase in the CBF.

## 2. Patients and methods

### 2.1. Patients

This study was approved by the Ethics Committee of our institution; prior oral informed consent to participate in this study was obtained from all patients. The study population consisted

of 11 patients, 7 men and 4 women (mean age  $72 \pm 7.9$  years) who complained of dizziness, vertigo, unsteadiness, or feeling faint. Of these, 8 (mean age  $71.4 \pm 8.8$  years) had suffered a cerebral infarct more than 1 month earlier. The other 3 (mean age  $73.7 \pm 6.1$  years) had experienced no obvious ischemic episodes although MRI (magnetic resonance imaging) demonstrated hyperintense ischemic areas in the deep white matter. All 11 patients were treated with ibudilast (30 mg daily) orally and followed up for 6 months.

Patient profiles are presented in Table 1. Case 1 was a 75-year-old woman with a 5-year history of vertigo who was being treated for hypertension. She reported for a check-up at our hospital. Attacks of vertigo rendered her unable to walk. MRI demonstrated hyperintense areas in the bilateral deep white matter; there were no new lesions attributable to stroke. Case 2 was a 71-year-old man with dysarthria. His right hand was clumsy and he noticed hypoesthesia of the right hand and foot. One month after onset he also suffered episodes of dizziness and he reported to our hospital for a check-up. MRI demonstrated a relatively fresh infarct (subacute to chronic stage) in the left putamen; there were multiple old lacunar infarcts in the deep white matter. Case 3 was a 77-year-old man who reported forgetfulness, decreased motivation and concentration ability, and episodes of dizziness that had started several months earlier. MRI demonstrated multiple lacunar infarcts in the deep white matter; there were relatively fresh (subacute stage) lacunar infarcts in the right corona radiata. MRA (magnetic resonance angiography) demonstrated severe stenosis of the right middle cerebral artery. Case 4 was a 78-year-old woman with a long history of diabetes mellitus and hypertension. She suddenly experienced the onset of vertigo, lateral left gaze palsy, and gait disturbance. Her episodes of vertigo continued for 2 months and she suffered persistent depression. MRI demonstrated a small lacunar infarct in the left pons. Case 5 was a 75-year-old man with a long history of hypertension who noticed unsteadiness and gait disturbance. He also complained of right homonymous hemianopsia. MRI demonstrated a subcortical infarct in the left occipital lobe accompanied by multiple old lacunar infarcts in the deep white matter. Case 6 was a 67-year-old man who experienced dizziness episodes for several months. At check-up at our hospital he reported forgetfulness and decreased motivation and concentration ability. MRI

**Table 1: Case profile.**

Case No.	Age/Sex	Type of infarction	Site of lesion	Past history	Dizziness	JSS-D score at entry	Handedness
Case 1	75/F	multiple lacunar	deep white matter	HT	vertigo	7.31	right
Case 2	71/M	lacunar	left putamen	rt MCA severe stenosis	dizziness	3.35	right
Case 3	77/M	ATBI	right corona radiata	DM, HT	dizziness	6.20	right
Case 4	78/F	ATBI	left pons	HT	vertigo	20.11	right
Case 5	75/M	ATBI	left occipital lobe	HT	unsteadiness	1.00	right
Case 6	67/M	multiple lacunar	deep white matter	severe stenosis of lt ICA	dizziness	1.44	right
Case 7	79/F	multiple lacunar	deep white matter	HT, HL	unfitness	6.60	right
Case 8	80/F	BAD	right pons	HT, lt MCA severe stenosis	unsteadiness	1.17	right
Case 9	74/M	ATBI	left occipital lobe	HT	dizziness	0.73	right
Case 10	55/M	ATBI	left corona radiata	rt MCA severe stenosis	faintness	1.43	right
Case 11	61/M	ATBI	left MCA watershed zone	DM, HT	faintness	9.49	right

ATBI: atherothrombotic brain infarction; HT: hypertension; MCA: middle cerebral artery; DM: diabetes mellitus; BAD: branch atheromatous disease; ICA: internal carotid artery.

demonstrated multiple lacunar infarcts in the deep white matter. Case 7 was a 79-year-old woman with general malaise. She complained of vertigo and severe depression. MRI demonstrated multiple lacunar infarcts in the deep white matter. Case 8 was an 80-year-old woman with a long history of hypertension. She reported the sudden onset of unsteadiness and gait disturbance. MRI demonstrated infarction in the right pons and a diagnosis of branch-atheromatous disease was made. Case 9 was a 74-year-old man with sudden onset of amaurosis fugax in the left visual field and weakness of the right hand accompanied by dizziness. MRI demonstrated cerebral embolism in the left occipital subcortical area. Cervical echography disclosed severe stenosis of the left internal carotid artery. Case 10 was a 55-year-old man with a long history of untreated hypertension and hyperlipidemia. He suddenly experienced dysarthria, right facial palsy, and faintness. MRI demonstrated a new stroke in the left corona radiata; there were old lacunar infarcts in the right corona radiata and right cerebellar folia. MRA revealed severe stenosis from the carotid artery to the middle cerebral artery bilaterally. Case 11 was a 61-year-old man with a 5-year history of untreated hypertension who experienced recurrent transient ischemic attacks during several months, right-arm dysesthesia, and episodes of faintness. MRI demonstrated left parietal cortical and subcortical hyperintense spots, including the left corona radiata on diffusion-weighted images. There was severe left middle cerebral artery stenosis.

## 2.2. Drugs

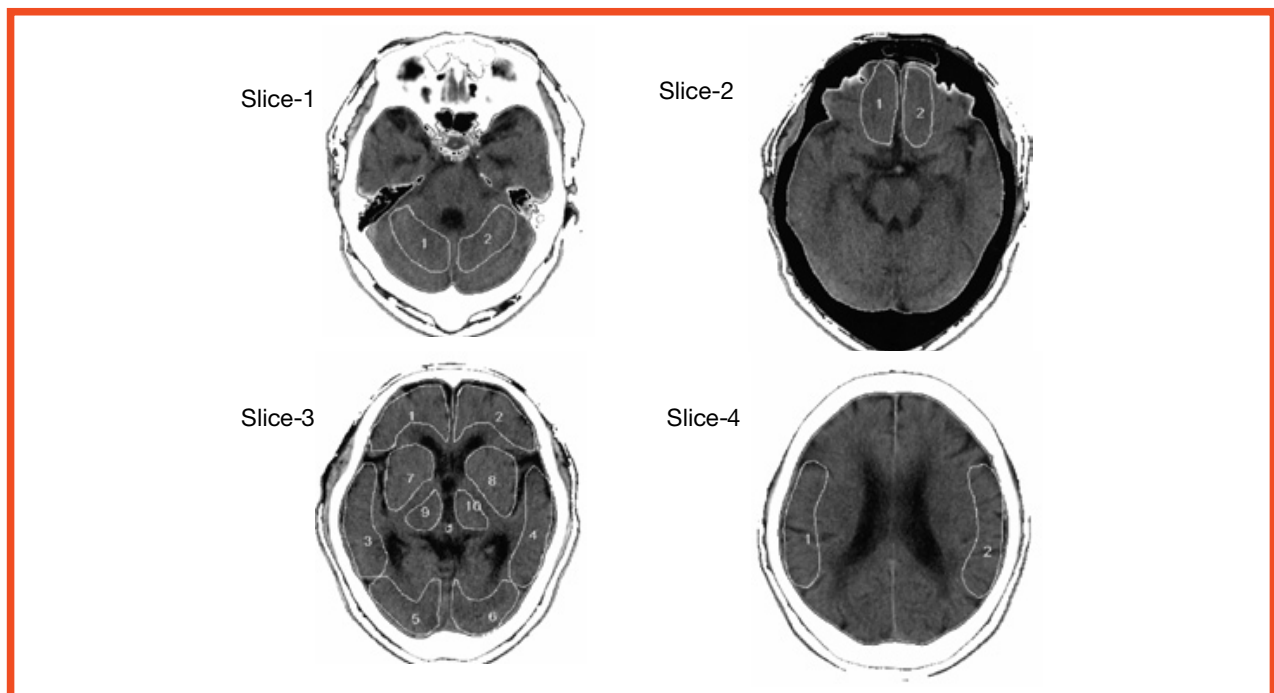
Ibudilast (CAS 50847-11-5, 3-isobutyl-2-isopropylpyrazolo [1,5-a] pyridine, KC-404, Ketas<sup>®</sup>) capsules was obtained from Kyorin Pharmaceutical Co., Ltd., Tokyo (Japan).

## 2.3. Recording of dizziness grade and scoring of depression

Dizziness grade of all 11 patients were recorded at 2 and 6 months after the start of ibudilast therapy. Using the Japan Stroke Scale-Depression Scale (JSS-D), the changes in their depressive state and dizziness grade were recorded before and 2 and 6 months after the start of ibudilast therapy. In 2003, the Japan Stroke Society established the JSS-D to evaluate mood disorders after stroke, especially post-stroke depression (PSD) [16]. There is a strong correlation between the JSS-D and the Hamilton Depression Scale (HAM-D<sub>17</sub>) [17]; the threshold for PSD on the JSS-D is more than 2.48 [18].

## 2.4. CBF measurement

The patients' CBF was measured at the start of therapy and 3 months later. For the CBF study the standard Xe-CT CBF system adapted to the Siemens scanner (120 kV, 195 mA, Siemens Somatom Plus4, München, Germany) was used [19, 20]. Prior to scanning, the patient's head was immobilized and secured with a vacuum-activated cranial mold. The head was aligned along the orbitomeatal plane with a laser light. A scout film was used to select the CT slices; two 10 mm-thick slices, separated by 15 mm, were selected for the CBF study. After selection of the scan levels, the patient was connected to the xenon gas inhalation system (AZ-726, Anzai Medical Corp., Tokyo Japan); the inhaled xenon concentration was 30%. The patients inhaled stable xenon for 3 min (wash-in); this was followed by 4-min desaturation (wash-out). An AZ-7000 instrument (Anzai Medical Corp.) was used to evaluate CBF values. The airway was tightly sealed with a facemask that covered the mouth and nose.



**Fig. 1:** Analyzed sections of CT images. Slices 1, 2, 3, and 4 are axial images that include the cerebellar hemisphere, frontal base, basal ganglia, and temporo-parietal cortex, respectively. ROIs were placed on each image. In slice 1, 1 and 2 indicate the cerebellar folia. In slice 2, 1 and 2 indicate the frontal base. In slice 3, the level of the analyzed slice passed through the basal ganglia and included the midsection of the anterior horns of the lateral ventricles, the caudate putamen, thalamus, and pineal body posteriorly. For cortical areas, three pairs of cortices were determined corresponding to the frontal cortex. 1, 2, Temporal cortex; 3, 4, occipital cortex; 5, 6, indicate subcortical gray matter areas; two pairs of regions were determined corresponding to the striatum (7, 8) and thalamus (9, 10). In slice 4, 1, 2 indicate the temporo-parietal cortex.

Regions of interest (ROIs) were placed on cortical and sub-cortical areas on 4 slices. The analyzed sections on the CT slices are shown in Fig. 1. The CBF (ml/100 g/min) was calculated in the corresponding ROI on the CT slices using Kety's autoradiographic equation [20, 21].

### 2.5. Statistical analysis

Statistical analysis was carried out using the paired t-test. In addition, a paired t-test with a Bonferroni correction was also carried out.

### 3. Results

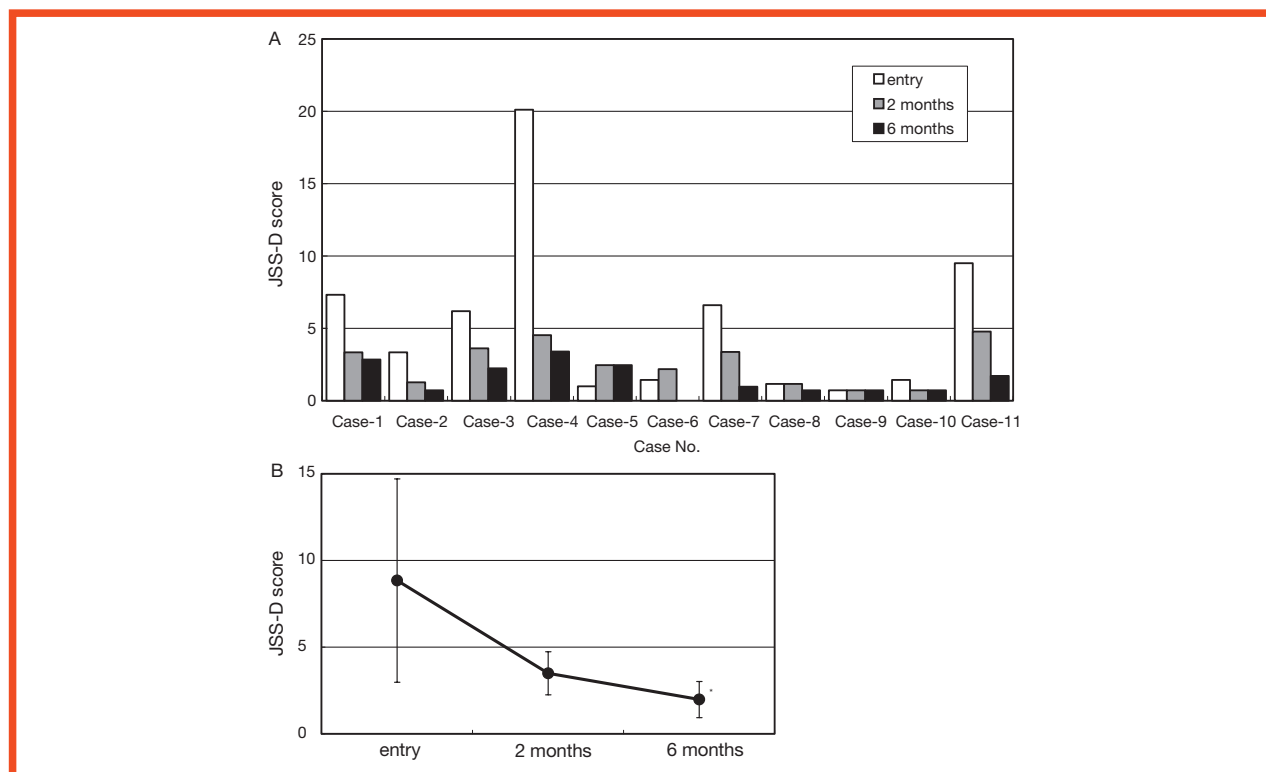
In Fig. 1 the analyzed sections of CT images are shown. Slices 1, 2, 3, and 4 are axial images that include the cerebellar hemisphere, frontal base, basal ganglia, and temporo-parietal cortex, respectively. ROIs were placed on each image. In slice 1, 1 and 2 indicate the cerebellar folia. In slice 2, 1 and 2 indicate the frontal base. In slice 3, the level of the analyzed slice passed through the basal ganglia and included the midsection of the anterior horns of the lateral ventricles, the caudate putamen, thalamus, and pineal body posteriorly. For cortical areas, 3 pairs of cortices were determined corresponding to the frontal cortex. 1, 2 indicate the temporal cortex; 3, 4 indicate the occipital cortex; 5, 6 indicate subcortical gray matter areas; 2 pairs of regions were determined corresponding to the striatum (7, 8) and thalamus (9, 10). In slice 4, 1, 2 indicate the temporo-parietal cortex.

**Table 2: Improvement of dizziness.**

Case No.	Dizziness grade		
	At entry	After 2 months	After 6 months
Case 1	severe	moderate	none
Case 2	mild	none	none
Case 3	moderate	mild	none
Case 4	moderate	none	none
Case 5	moderate	none	none
Case 6	moderate	none	none
Case 7	moderate	none	none
Case 8	mild	none	none
Case 9	mild	none	none
Case 10	mild	none	none
Case 11	mild	none	none

As shown in Table 2, at 6 months after the start of ibudilast therapy, dizziness was resolved in all patients. At the start of treatment, 6 patients (cases 1-3, 4, 7, 11) manifested depression (Fig. 2A) according to JSS-D parameters. Their depression was significantly ameliorated at 6 months after the start of therapy (Fig. 2B).

Table 3 shows that 3-month treatment resulted in CBF changes analyzed in each ROI demonstrated in Fig 1. In the right cerebral hemisphere there was a significant CBF increase in the frontal ( $p = 0.019$ ) and occipital ( $p=0.004$ ) cortices. There was no significant change in the subcortical gray matter, the striatum, thalamus, cerebellar folia, or other cerebral cortices. In the left cerebral hemisphere there was no significant CBF change. Comparison of the CBF in the right and left hemisphere disclosed no significant differences (data not shown).



**Fig. 2: Change in the JSS-D scores after administration of ibudilast in the patients with chronic cerebral ischemia. (A) Bar graph showing changes in the depression score (JSS-D) of all 11 patients at study inception (open columns) and 2 (gray columns), and 6 months (solid columns) after the start of ibudilast treatment. (B) Line graph of the mean JSS-D score and standard deviation of six patients (score at entry > 2.48, Case 1, 2, 3, 4, 7, 11). \*Significant change in value obtained at 6 months after the start of ibudilast treatment. Paired t-test with a Bonn-Ferroni correction,  $p < 0.025$ .**



**Table 3: Change of CBF.**

ROI	Right region			Left region		
	Baseline CBF	Loading CBF	p value	Baseline CBF	Loading CBF	p value
Cerebellar folia	43.26 ± 11.63	35.54 ± 13.10	0.184	44.01 ± 14.31	41.86 ± 15.19	0.697
Frontal base	31.60 ± 12.00	38.62 ± 9.49	0.101	36.64 ± 20.09	42.90 ± 24.89	0.201
Frontal cortex	35.16 ± 9.10	40.65 ± 7.99*	0.019	33.30 ± 12.45	37.56 ± 10.09	0.253
Temporal cortex	37.64 ± 11.35	39.75 ± 10.49	0.474	35.76 ± 11.99	36.22 ± 11.21	0.863
Occipital cortex	29.79 ± 9.64	36.78 ± 10.76*	0.004	32.91 ± 7.45	33.62 ± 9.72	0.723
Striatum	42.17 ± 12.26	42.01 ± 10.45	0.939	39.60 ± 14.27	40.17 ± 10.40	0.846
Thalamus	54.03 ± 23.94	50.22 ± 15.35	0.608	52.05 ± 23.36	48.84 ± 15.92	0.658
Temporo-parietal cortex	40.65 ± 11.73	42.72 ± 8.80	0.467	37.44 ± 11.01	39.44 ± 11.71	0.408

CBF (mL/100 g/min): mean ± S.D.; p value: paired t-test, \*p < 0.05.

#### 4. Discussion

In the present study, administration of 30 mg/day of ibudilast resulted in amelioration of non-specific clinical symptoms such as dizziness and depression and produced a significant increase in the CBF of the right frontal and occipital cortices. If this phenomenon reflects the natural course of PSD patients treated with ibudilast, not only the right, but also the left cortical areas should show an increase in CBF. However, there was no significant change in the CBF in any areas of the left cerebral hemisphere. As shown in Table 1, none of the patients presented with lesions in the right frontal or occipital cortices. Therefore, we focused on the relationship between their clinical symptoms and the ibudilast-induced CBF changes in the right frontal and occipital cortices.

All 11 patients complained of dizziness, vertigo, unsteadiness, or feeling faint, symptoms attributable to secondary chronic cerebral circulation impairment as sequelae of brain infarction. Others who studied the relationship between dizziness and the regional CBF demonstrated hypoperfusion in both occipital lobes and posited that insufficient flow in the territory of the vertebrobasilar system is a factor resulting in hypoperfusion of both occipital lobes [22, 23]. At 2 and 6 months after the start of ibudilast therapy, all of the 11 patients reported resolution of their dizziness episodes. As infarcts were present in the brainstem and occipital lobes of 2 patients and another patient manifested infarction in the cerebellar folia, we posit that these patients suffered from vertebrobasilar insufficiency.

In 6 patients who reported depression at the inception of our study, this symptom was significantly ameliorated at 6 months. Studies on the relationship between depression and the CBF demonstrated a significant reduction in the CBF in the left frontal lobe among patients with PSD [24–27]. The most consistent regional deficits were a decrease in the CBF and the metabolism affecting the left dorso-lateral prefrontal cortex; low CBF and glucose hypometabolism in the left prefrontal cortex have been reported to be inversely correlated with depression severity [28, 29]. However, there is no

consensus whether the right or left side is the dominant one involved in depression. Based on our findings, we posit that our patients' dizziness and depression reflect involvement of the right frontal and occipital cortices.

Ibudilast therapy produced no significant CBF changes in subcortical structures such as the striatum and thalamus. Interruption of the cortical blood flow by subcortical lesions reportedly produced neuropsychiatric symptoms [26, 30, 31]. Major PSD may occur secondary to disruption of subcortico-cortical biogenic amine pathways and patients with PSD manifested cortical serotonergic deficits [32, 33]. Our results demonstrate that damage to subcortical regions may affect the right frontal and occipital cortices and result in dizziness and depression.

Ibudilast has received attention for its role as a PDE4 inhibitor via modulation of the cyclic adenosine monophosphate (cAMP) second messenger system and has been used to treat CNS disorders [11, 12]. The PDE4D gene has been identified as a risk factor for ischemic stroke through regulation of cAMP signal transduction [34]. PDE4D enzyme activity may play an important role in stroke through its effects on inflammation, plaque stability, response to injury, angiogenesis, and the susceptibility and response to low-grade infections [35]. Ibudilast may exert beneficial effects on the brain, especially in chronically hypoperfused right frontal and occipital lobes, by increasing the CBF and via a prostaglandin I<sub>2</sub>-related mechanism and PDE4I-related modulation of the cAMP second messenger system.

In conclusion, our results demonstrated that in patients with cerebral ischemia, the administration of ibudilast produced a significant increase in the CBF to the right frontal and occipital cortices and amelioration of non-specific symptoms such as dizziness and depression. Our findings suggest that the right frontal and occipital cortices are related to the symptoms experienced by these patients. Studies are underway in our laboratory to identify the relevant hypoperfused location(s), and the neurotransmission underlying the non-specific post-stroke clinical symptoms.

## References

- [1] Leigh RJ, Zee DS. *The Neurology of Eye Movements*. New York: Oxford University Press; 1999.
- [2] Baloh RW. The dizzy patient. *Postgrad Med*. 1999;105:161–164
- [3] Tusa RJ. Dizziness. *Med Clin North Am*. 2003;87:609–641, vii.
- [4] Brandt T, Strupp M. General vestibular testing. *Clin Neurophysiol*. 2005;116:406–426.
- [5] Burt CW, Schapper SM. Ambulatory care visits to physician offices, hospital out-patient departments, and emergency departments: United States, 1999–2000. *Vital Health Stat*. 2004;13:1–70.
- [6] Kerber KA, Brown DL, Lisabeth LD, Smith MA, Morgenstern LB. Stroke among patients with dizziness, vertigo, and imbalance in the emergency department. A population-based study. *Stroke* 2006;37:2484–2487
- [7] Fujishima M, Yao H, Terashi A, Tagawa K, Matsumoto M, Hara H, *et al*. Deep white matter lesions on MRI, and not silent brain infarcts are related to headache and dizziness of non-specific cause in non-stroke Japanese subjects. *Intern Med*. 2000;39:727–731
- [8] Robinson RG, Szetela B. Mood change following left hemisphere brain injury. *Ann Neurol* 1981;9:447–453
- [9] Robinson RG, Kubos KL, Starr LB, Rao K, Price TR. Mood disorders in stroke patients: Importance of location. *Brain* 1984;107:81–93
- [10] Robinson RG. *The clinical neuropsychiatry of stroke*. Cambridge: Cambridge University Press; 1988.
- [11] Kishi Y, Ohta S, Sakita S, Ashikaga T, Isobe M. Ibutilast: A nonselective PDE inhibitor with multiple actions on blood cells and the vascular wall. *Cardiovasc Drug Rev*. 2001;19:215–225
- [12] Renau TE. The potential of phosphodiesterase 4 inhibitors for the treatment of depression: Opportunities and challenges. *Curr Opin Invest Drugs*. 2004;5:34–39
- [13] Fukuyama H, Kimura J, Yamaguchi S, Ymauchi H, Ogawa M, Doi T, *et al*. Pharmacological effects of ibutilast on cerebral circulation: A PET study. *Neurol Res*. 1993;15:169–173.
- [14] Yamashita T, Urakawa M, Hayashi M, Nakano S, Kashiwagi S, Ishihara H, *et al*. The effect of ibutilast on local cerebral blood flow in patients with chronic ischemic cerebrovascular lesions. *Prog Med*. 1993;13:59–66. (In Japanese with English abstract)
- [15] Shinohara Y, Kusunoki T, Nakashima M. Clinical efficacy of Ibutilast on vertigo and dizziness observed in patients with cerebral infarction in the chronic stage—a double-blind, randomized, placebo-controlled trial with a run-in period. *Neurol Ther*. 2002;19:177–187. (In Japanese with English abstract)
- [16] Japan Stroke Society. Japan Stroke Scale (Emotional Disturbance Scale) <JSS-D · JSS-E>. *Jpn J Stroke* 2003;25:206–214. (In Japanese)
- [17] Kaji Y, Hirata K, Ebata A. Post-stroke depression (PSD) at the subacute stage after stroke: A study on an appropriate and easy evaluation strategy for its diagnosis. *Jpn J Stroke*. 2004;26:441–448. (In Japanese with English abstract)
- [18] Kaji Y, Hirata K. Depression after stroke. *Nippon Rinsho*. 2006;64:445–450. (In Japanese)
- [19] Yonas H, Darby JM, Marks EC, Durham SR, Maxwell C. CBF measured by Xe/CT-approach to analysis and normal values. *J Cereb Blood Flow Metab*. 1991;11:716–725.
- [20] Dean BL, Hodak JA, Drayer BP, Lee C, Graham TW, Conrad GR. *Cerebral Blood Flow Measurement with Stable Xenon-Enhanced Computed Tomography*. H. Yonas, editor. New York: Raven Press; 1992. p. 156–161.
- [21] Kety SS. The theory and applications of the exchange of inert gas at the lungs and tissue. *Pharmacol Rev*. 1951;3:1–41.
- [22] Arai M, Higuchi A, Itoh T, Mochimatu Y, Hayashi H, Itoh K. A comparison between peripheral and central origin in elderly patients with vestibular vertigo by using magnetic resonance angiography and single photon emission computed tomography using I-123 iodoamphetamine. *Equilibrium Res*. 2001;60:169–176. (In Japanese with English abstract)
- [23] Koyuncu M, Elhami AR, Akan H, Sahin M, Basoglu T, Simsek M. Investigation of the vertebrobasilar arterial system in vertigo by vestibulocochlear test, SPECT and angiography. *Auris Nasus Larynx*. 2001;28:23–28.
- [24] Bench CJ, Friston KJ, Brown RG, Frackowiak RSJ, Dolan RJ. Regional cerebral blood flow in depression measured by positron emission tomography: The relationship with clinical dimensions. *Psychol Med*. 1993;23:579–590.
- [25] Rubin E, Sackeim HA, Prohovnik I, Moeller JR, Schnur DB, Mukherjee S. Regional cerebral blood flow in mood disorders: IV. Comparison of mania and depression. *Psychiat Res Neuroimaging*. 1995;61:1–10.
- [26] Okada K, Kobayashi S, Yamagata S, Takahashi K, Yamaguchi S. Post-stroke apathy and regional cerebral blood flow. *Stroke* 1997;28:2437–2441.
- [27] Kimura M, Shimoda K, Mizumura S, Tateno A, Tatsuma F, Mori T, *et al*. Regional cerebral blood flow in vascular depression assessed by 123 I-IMP SPECT. *J Nippon Med Sch*. 2003; 70:321–326
- [28] Baxter LR, Schwartz JM, Phelps ME, Mazziotta JC, Guze BH, Selin CE, *et al*. Reduction of prefrontal cortex metabolism common to three types of depression. *Arch Gen Psychiatry*. 1990;46:243–250.
- [29] Martinot JL, Hardy P, Feline A, Huret JD, Mazoyer B, Attal-Levy D, *et al*. Left prefrontal glucose hypometabolism in the depressed state: A confirmation. *Am J Psychiatry*. 1990;147:1313–1317.
- [30] Takano T, Kimura K, Nakamura M, Fukunaga R, Kusunoki M, Etani H, *et al*. Effect of small deep hemispheric infarction on the ipsilateral cortical blood flow in man. *Stroke*. 1985;16:64–69.
- [31] Yamaguchi S, Kobayashi S, Koide H, Tsunematsu T. Longitudinal study of regional cerebral blood flow changes in depression after stroke. *Stroke*. 1992;23:1716–1722.
- [32] Mayberg HS, Robinson RG, Wong DF, Parikh RM, Bolduc PL, Starkstein SE, *et al*. PET imaging of cortical S2 serotonin receptors after stroke: Lateralized changes and relationship to depression. *Am J Psychiatry*. 1988;145:937–943.
- [33] Starkstein SE, Robinson RG. Affective disorders and cerebral vascular disease. *Br J Psychiatry*. 1989;154:170–182.
- [34] Brophy VH, Ro SK, Rhees BK, Lui LY, Lee JM, Umblas N, *et al*. Association of phosphodiesterase 4D polymorphisms with ischemic stroke in a US population stratified by hypertension status. *Stroke*. 2006;37:1385–1390.
- [35] Worrall B, Mychalekcyj JC. PDE4D and stroke. A real advance or a case of the emperor's new clothes? *Stroke*. 2006;37:1955–1957.