

## Short communication

Serum vitamin B<sub>12</sub> deficiency and hyperhomocystinemia: A reversible cause of acute chorea, cerebellar ataxia in an adult with cerebral ischemiaC. Shyambabu<sup>a</sup>, S. Sinha<sup>a,\*</sup>, A.B. Taly<sup>a</sup>, J. Vijayan<sup>a</sup>, J.M.E. Kovoov<sup>b</sup><sup>a</sup> Department of Neurology, NIMHANS, Hosur Road, Bangalore, 560029, India<sup>b</sup> Department of Neuroimaging and Interventional Neuroradiology, NIMHANS, Hosur Road, Bangalore, 560029, India

## ARTICLE INFO

## Article history:

Received 23 April 2008

Received in revised form 20 June 2008

Accepted 25 June 2008

Available online 3 August 2008

## Keywords:

Cerebellar ataxia

Chorea

Hyperhomocystinemia

Vitamin B<sub>12</sub> deficiency

Wernicke's aphasia

## ABSTRACT

Patients with vitamin B<sub>12</sub> deficiency have protean neurological manifestations that are often insidious. Acute onset of cerebellar dysfunction and extrapyramidal manifestations like dystonia and chorea are rather uncommon in adults. We describe a patient who manifested with acute onset of language dysfunction, chorea and ataxia. There was no history of hypertension, diabetes or ischemic heart disease. He had low serum vitamin B<sub>12</sub> and elevated serum homocystine levels. He improved dramatically following B<sub>12</sub> replacement therapy. Our patient provides insight into the pathophysiological mechanism of this rare manifestation. Further the importance of considering vitamin B<sub>12</sub> deficiency, in country like India, where vegetarian food practice is quite common, is being emphasized.

© 2008 Elsevier B.V. All rights reserved.

## 1. Introduction

Subacute combined degeneration of the spinal cord (SCD) is the most frequent neurological syndrome of vitamin B<sub>12</sub> deficiency [1]. It affects the dorsal and lateral columns of the spinal cord [2]. The neurological manifestations are paraesthesia, sensory ataxia, weakness of limbs, dementia, optic atrophy, and mood disorders and commonly occur in the 5th to 7th decade. Cerebellar ataxia and extrapyramidal manifestations like dystonia and chorea have been documented infrequently in adults [2,3].

The present report highlights an unusual and acute presentation of vitamin B<sub>12</sub> deficiency in the form of ischemic stroke, chorea, and cerebellar ataxia which had improved dramatically following treatment with B<sub>12</sub> injections.

## 2. Case report

A 40-year-old gentleman manifested with 5 weeks history of acute onset of "irrelevant" speech and inability to comprehend. A week before, he developed involuntary movements of upper extremities and unsteadiness of gait. He was noted to have hyperpigmentation of hands and feet for the last few months, which was confirmed during evaluation (Fig. 1A, D). There was no history of psychiatric disturbances, paraesthesia or weakness of limbs or systemic diseases like hyperten-

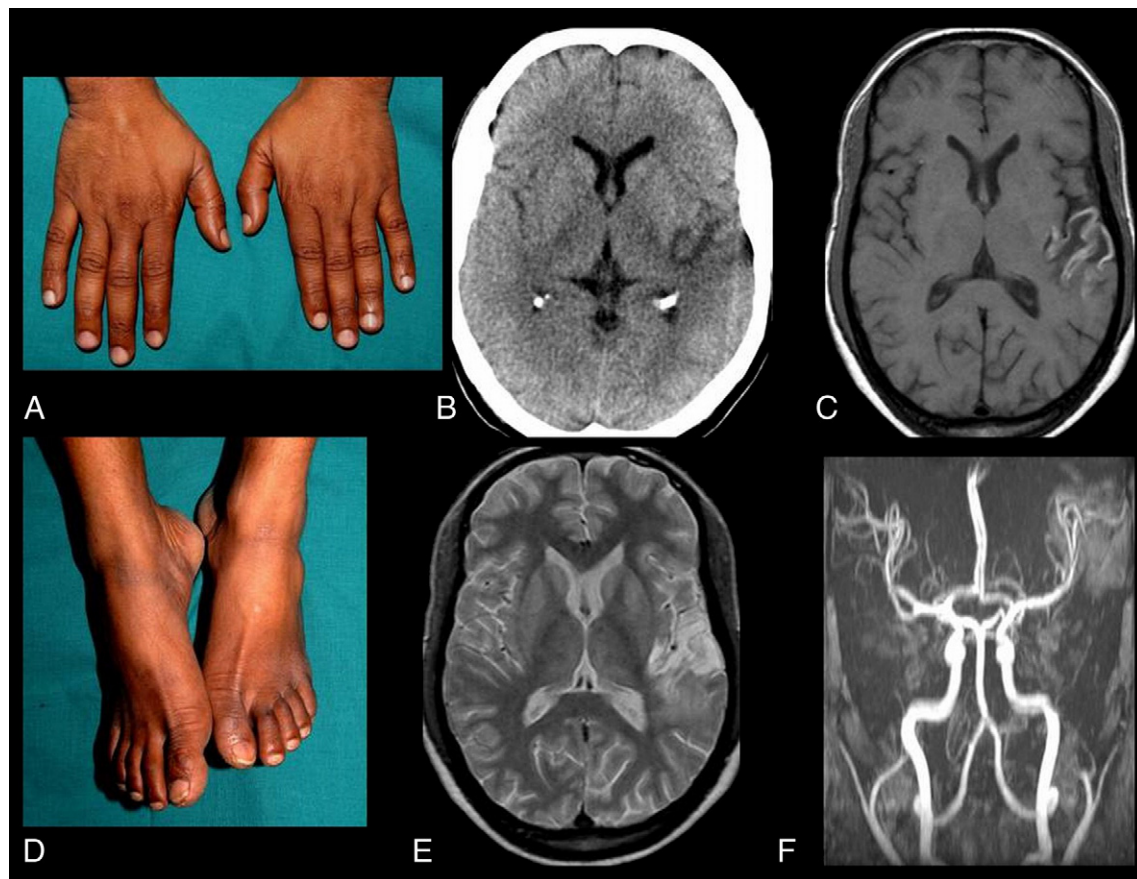
sion, diabetes or ischemic heart disease. He was a pure vegetarian and didn't have any habits like drinking or substance abuse. He had features of Wernicke's aphasia by western aphasia battery, choreiform movement in upper extremities, wide based gait and truncal and limb ataxia, requiring support by one person for all activities of daily living. Muscle strength was normal (MRC: 5/5), the stretch reflexes were normal and there was no kinesthetic impairment. Romberg's sign was absent.

The investigations revealed hemoglobin of 12.6 g%, TLC—7600 mm<sup>3</sup>, PCV—38%, ESR—30 mm/h, MCV—103.8 fl, Platelets—2.9 lakhs/mm<sup>3</sup>. Peripheral smear showed hypersegmented neutrophils. The routine biochemical parameters were in the normal range. Serum and CSF VDRL, ANA, RA factor, LE cell phenomena, antiphospholipid antibody, anti-cardiolipin antibody, and lupus anticoagulant were normal. Thyroid function was normal. Serum homocysteine was elevated—50 μmol/l (normal: 5–15 μmol/l) while serum vitamin B<sub>12</sub> was low—62.96 pg/ml (normal: 243–894 pg/ml). Serum folate level estimation was not carried out. Upper GI endoscopy showed normal mucosa. The cranial MRI and MRA showed infarct in the left MCA territory involving inferior part of parietal lobe and anterior part of temporal lobe (Fig. 1B, C, E, F). There was no lesion in the basal ganglia, brainstem or cerebellum. Carotid and vertebral Doppler and 2D echo of heart were normal. The motor and sensory nerve conduction study revealed values within normal limits. Visual evoked potential study showed mildly increased P100 latency of 113.4 ms in both eyes and somatosensory and brainstem auditory evoked responses were normal. A diagnosis of vitamin B<sub>12</sub> deficiency related neurological syndrome manifesting as chorea, cerebellar ataxia and ischemic stroke was considered.

He received parenteral cyanocobalamin 3000 μg daily for a month followed by 1000 μg/week for a month. After 2 months, he improved

\* Corresponding author. NIMHANS, Hosur Road, Bangalore, 560029, India. Tel.: +91 8026995150; fax: +91 8026564830.

E-mail addresses: [sanjib\\_sinha2004@yahoo.co.in](mailto:sanjib_sinha2004@yahoo.co.in), [sanjib\\_sinha@nimhans.kar.nic.in](mailto:sanjib_sinha@nimhans.kar.nic.in) (S. Sinha).



**Fig. 1.** A,D: Hyperpigmentation of dorsum of hand and knuckles and dorsum of feet and toes. B: axial CT brain showing infarct in the left MCA territory. C: Axial T1W image showing subacute infarct (with gadolinium enhancement) in the left MCA territory. E: Axial T2W sequence showing infarct in the left MCA territory. F: MR angiography showing left MCA occlusion.

remarkably in his gait, involuntary movements and language. He was able to walk independently, the choreoathetotic movements had reduced markedly in severity and extent, and it was only limited to fingers. Serial speech and language assessment revealed improvement in overall comprehension, however writing was still impaired. The repeat hemoglobin at 2 months was 13 g%, TLC–4800 mm<sup>3</sup>, ESR–12 mm/h and MCV–88.3 fl. Following 3 months of treatment, the serum homocysteine level (7.73 μmol/l) and vitamin B<sub>12</sub> (2000 pg/ml) were normal. Repeat peripheral smear also did not reveal any hypersegmented neutrophil.

### 3. Discussion

Our patient, a vegetarian had low serum concentration of vitamin B<sub>12</sub>, increased serum level of homocysteine and improved with treatment. The neurological symptoms of chorea and cerebellar ataxia improved markedly after 2 months of vitamin B<sub>12</sub> replacement and it could be attributed to the deficiency of vitamin B<sub>12</sub>. Involuntary movements like tremors, twitches, chorea, myoclonus or combination have been reported in about 50% of the infants with infantile cobalamin deficiency [4–6]. In adults with vitamin B<sub>12</sub> deficiency, focal dystonia, chorea, parkinsonism, myoclonus and even ataxia have been documented as single case reports [3,8–11].

The left middle cerebral artery territory infarction might be due to hyperhomocysteinemia related thrombo-embolism, secondary to B<sub>12</sub> deficiency or mutations in MTHFR gene, which was not carried out in our patient. Caldera et al. (2003) had reported a 60-year-old woman with ataxia and pulmonary emboli due to pernicious anemia, hyperhomo-

cysteinemia, and a G20210A prothrombin gene mutation [12]. Leemann et al. [13] had discussed possible association of high plasma level of homocysteine in the context of pernicious anemia in 44-year-old women of frontal ischemic stroke [13]. Moderate hyperhomocysteinemia is a risk factor for cardiovascular and neurodegenerative diseases, osteoporotic fractures and complications during pregnancy. Vitamin deficiency is by far the most common cause of hyperhomocysteinemia. Retrospective and prospective studies emphasize a causal relationship between hyperhomocysteinemia and the vascular risk factor [14].

Vitamin B<sub>12</sub> induces an increased homocysteine, which is required for the methylation of methionine. The neurotoxic *N*-methyl-D-aspartate (NMDA) agonist action of homocysteine produces excitatory activity in the basal ganglia by its action on the thalamocortical pathway and there by causing dystonia and chorea [7,8]. The excess methyl levels in B<sub>12</sub> deficiency increase the levels of methyl tetra hydrofolate, which acts as agonist of kainic acid. In experimental animals, this kainate produces damage similar to that in Huntington's disease [15,16]. Also, the methylmalonic acidemia (MMA), an inborn error of metabolism, usually presents with acute extrapyramidal syndrome in infants, and some cases respond to vitamin B<sub>12</sub> therapy. Brain imaging and autopsy studies in MMA have shown symmetrical involvement of basal ganglia [17].

Our patient is unique in view of the presence of a combination of involuntary movements, ataxia and ischemic stroke. In country like India, where vegetarianism is common, one needs to consider it as a possibility. Even though the pathophysiological mechanisms are speculative, the reversibility of the clinical symptoms with cyanocobalamin therapy is striking.

## References

- [1] Heaton EB, Savage DG, Brust JC, Garrett TJ, Lindenbaum J. Neurologic aspects of cobalamin deficiency. *Medicine (Baltimore)* 1991;70:229–45.
- [2] Katsaros VK, Glocker FX, Hemmer B, Schumacher M. MRI of spinal cord and brain lesions in subacute combined degeneration. *Neuroradiology* 1988;40:716–9.
- [3] Ahn TB, Cho JW, Jeon BS. Unusual neurologic presentations of vitamin B<sub>12</sub> deficiency. *Eur J Neurol* 2004;11:339–41.
- [4] Jadhav M, Webb JKG, Vaishnav S, Baker SJ. Vitamin-B<sub>12</sub> deficiency in Indian infants. *Lancet* 1962;2:903–7.
- [5] Ozer EA, Turker M, Bakiler AR, Yaprak I, Ozturk C. Involuntary movements in infantile cobalamin deficiency appearing after treatment. *Pediatr Neurol* 2001;25:81–3.
- [6] Emery ES, Homans AC. Vitamin B<sub>12</sub> deficiency: a cause of abnormal movements in infants. *Pediatrics* 1997;99:255–6.
- [7] Vitek JL, Chokkan V, Zhang JY, et al. Neuronal activity in basal ganglia with generalized dystonia and hemiballismus. *Ann Neurol* 1999;46:22–35.
- [8] Muller T, Woitalla D, Hunsdieck A, Kuhn W. Elevated plasma levels of homocysteine in dystonia. *Acta Neurol Scand* 2000;101:388–90.
- [9] Kumar S. Vitamin B<sub>12</sub> deficiency presenting with an acute reversible extrapyramidal syndrome. *Neurol India* 2004;52:507–9.
- [10] Pacchetti C, Cristina S, Nappi G. Reversible chorea and focal dystonia in Vitamin B<sub>12</sub> deficiency. *N Engl J Med* 2002;347:295.
- [11] Celik M, Barkut IK, Oncel C, Forta H. Involuntary movements associated with vitamin B<sub>12</sub> deficiency. *Parkinsonism Relat Disord* 2003;10:55–7.
- [12] Caldera A, Mora J, Kotler M, Eiger G. Pulmonary embolism in a patient with pernicious anemia and hyperhomocysteinemia. *Chest* 2002;122(4):1487–8.
- [13] Leemann B, Boughanem N, Schnider A. Ischemia, an uncommon complication of Biermer disease (pernicious anemia). *Rev Neurol (Paris)* 2006;162(10):1007–10.
- [14] Herrmann W. Significance of hyperhomocysteinemia. *Clin Lab* 2006;52(7–8):367–74.
- [15] Brennan MJ, van der Westhuyzen J, Kramer S, Metz J. Neurotoxicity of folates: Implications for vitamin B<sub>12</sub> deficiency and Huntington's chorea. *Med Hypotheses* 1981;7:919–29.
- [16] Ruck A, Kramer S, Metz J, Brennan MJ. Methyltetra hydrofolate is a potent and selective agonist for kainic acid receptors. *Nature* 1980;287:852–3.
- [17] Larnaout A, Mongalgi MA, Kaabachi N, Khiari D, Debbabi A, Mebazza A, et al. Methylmalonic acidemia with bilateral globus pallidus involvement: a neuro-pathological study. *J Inher Metab Dis* 1998;21:639–44.