

Inherited protein C deficiency with acute ischemic stroke in a young adult: a case report

Fu-Chi Yang^a, Chang-Hung Hsu^a, Jiann-Chyun Lin^a, Cheng-Yu Chen^b and Jiunn-Tay Lee^a

Hereditary protein C deficiency is inherited primarily as an autosomal dominant trait with incomplete penetrance. Arterial thrombosis, especially of the intracranial arteries, due to this deficiency is relatively rare. A 31-year-old man was admitted to our department because of sudden onset of neurological symptoms. Magnetic resonance imaging of the brain disclosed an acute ischemic infarction of the area supplied by the left middle cerebral artery. Protein C antigen was 40.7% (77–129%) and protein C activity was 46.3% (70–140%). No other possible associated causes of stroke were present. A survey of his relatives for protein C deficiency showed this deficiency in his mother, brother, sister and nephews. Protein C concentrations should be determined in cases of ischemic stroke in all young patients with no other major risk factors. Once protein C deficiency is detected, a search for protein C deficiency in the patient's

relatives should be performed to prevent the occurrence of ischemic strokes. *Blood Coagul Fibrinolysis* 19:601–604 © 2008 Wolters Kluwer Health | Lippincott Williams & Wilkins.

Blood Coagulation and Fibrinolysis 2008, 19:601–604

Keywords: cerebral ischemia, coagulation disorder, protein C

^aDepartment of Neurology and ^bDepartment of Radiology, Tri-Service General Hospital, National Defense Medical Center, Taipei, Taiwan

Correspondence to Jiunn-Tay Lee, MD, Department of Neurology, Tri-Service General Hospital, National Defense Medical Center, No. 325, Section 2, Cheng-Kung Road, Neihu 114, Taipei, Taiwan, ROC
Tel: +886 2 87923311 ext 12858; fax: +886 2 87927174;
e-mail: jiunntay@ms26.hinet.net

Received 27 November 2007 Revised 10 March 2008

Accepted 11 March 2008

Introduction

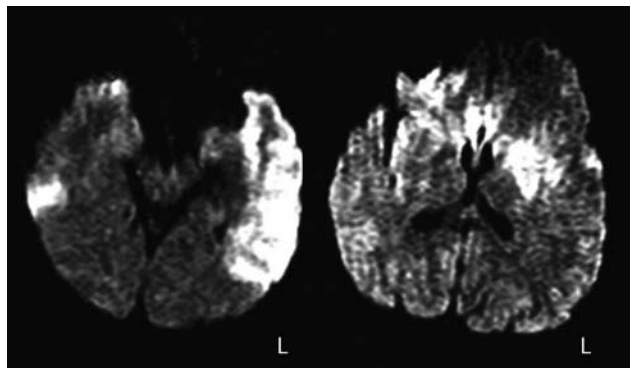
In approximately 4% of all young adults (less than 45-years of age) with stroke, a hematological disorder or coagulopathy is a contributing factor [1]. One such coagulopathy is protein C (PC) deficiency. PC is a plasma glycoprotein, produced through vitamin K-dependent synthesis in the liver, which is known to play an important role in regulating coagulation [2–4]. When activated by thrombin and the endothelial cofactor thrombomodulin, and in conjunction with protein S, PC inactivates the active forms of two mediators (factors Va and VIIIa) of the intrinsic pathway for coagulation [2–4]. The deficiency of this coagulation inhibitor leads to hypercoagulability. PC deficiency is inherited as an autosomal dominant trait with incomplete penetrance. Homozygous PC deficiency is rare and usually lethal through massive venous thrombosis during the neonatal period [5]. Heterozygous individuals have a fivefold increased risk for venous thrombosis [3]. The most common clinical manifestations of PC deficiency are the occurrence of superficial thrombophlebitis, deep venous thrombosis or pulmonary embolism at a young age. Arterial thrombosis, especially thrombosis of the intracranial arteries, associated with this deficiency has rarely been reported [6–9]. We recently encountered a young adult heterozygous for PC deficiency who experienced an occlusion of the left middle cerebral artery that led to ischemic stroke.

Case report

A 31-year-old, right-handed man came to our emergency room because of the sudden onset of neurological symptoms, including right hemiplegia, sensory disturbance, and motor aphasia. On admission, his blood pressure (BP) was 166/88 mmHg, and his heart rate was 65 beats per minute, with no arrhythmia. The results of the general physical examination were normal. The patient was mildly drowsy with disorientation as to time and place. Neurological examination revealed deviation of the eyes to the left, right central facial palsy, deviation of the tongue to the right and hypoesthesia over the limbs and trunk on the right side. He had Medical Research Council grade 1/5 muscle power in the right upper extremity, 3/5 in the right lower extremity, and 4/5 in the left extremities. Deep tendon reflexes were brisk in the right extremities. The plantar response was extensor on the right. Cell counts and blood biochemistry tests were within normal limits.

The patient had been healthy until this event, and there were no obvious precipitants of thrombosis (i.e., no dehydration, trauma or intoxication.). The patient had neither hypertension nor diabetes. He also denied the habits of smoking or drinking. The family history of the patient was also unremarkable, except for his maternal grandmother, who died at the age of 61 because of a cerebrovascular event of unclear cause.

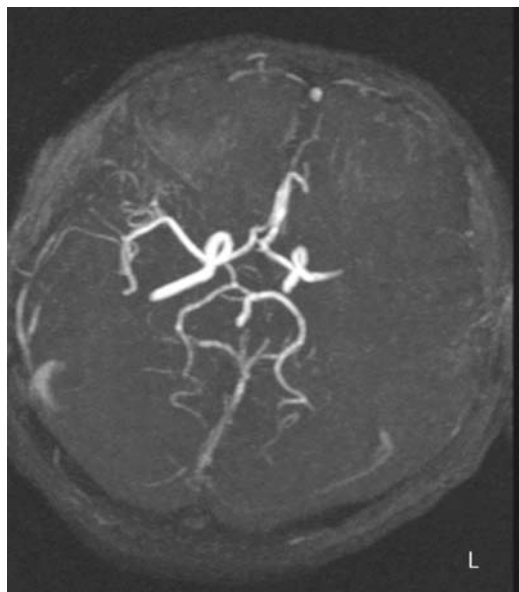
Fig. 1



Diffusion-weighted magnetic resonance images showing an acute infarction of the left middle cerebral arterial territory, including the caudate nucleus, basal ganglia, corona radiata and temporal lobe.

Magnetic resonance (MR) scans of the brain were performed and showed an acute infarction of the area supplied by the left middle cerebral artery, including the caudate nucleus, basal ganglia, corona radiata, and temporal lobe (Fig. 1). The lateral frontal and parietal lobes were spared. MR angiography of the circle of Willis showed occlusion of the left middle cerebral artery at the horizontal M1 segment. The distal branches of the left middle cerebral artery were not visualized (Fig. 2). However, the cervical arteries showed normal lumens in the

Fig. 2

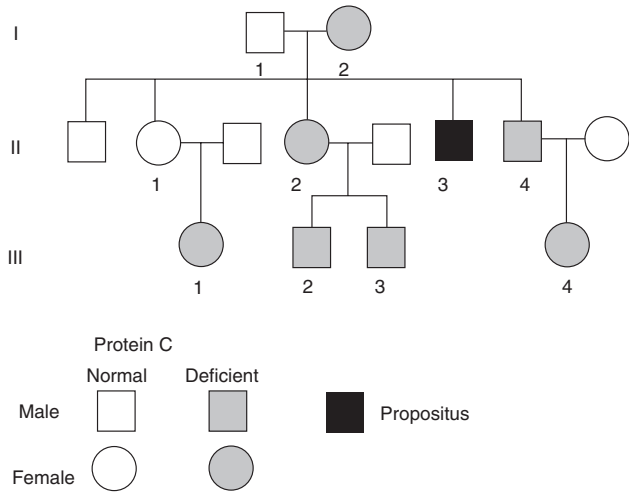


MR angiography of the circle of Willis shows an occlusion of the left middle cerebral artery at the horizontal M1 segment. All the distal branches of left middle cerebral artery are not visualized. MR, magnetic resonance.

bilateral carotid and vertebral systems. The extracranial carotid, vertebral, and subclavian arteries, when evaluated by cervical echography, did not show any abnormalities such as plaque formation. Two-dimensional and color Doppler echocardiography did not reveal valvular disease, thrombus formation, or an intracardiac shunt pathway. Routine blood parameters and measurements for factors involved in clotting [prothrombin time (PT) 10.9 s (control time 14.0 s), partial thromboplastin time 27.8 s (control time 35.5 s), albumin 4.5 g/dl (3.5–5.3 mg/dl), fibrinogen 332 mg/dl (200–400 mg/dl), factor VIII level 92% (50–150%), antithrombin III activity 95% (70–120%), platelet count $225 \times 10^3/\mu\text{l}$, bleeding time 4 min (3–8 min), protein S activity level 101.3% (60–150%), lupus anticoagulant level 0.95 (<1.2), homocysteine level $9.42 \mu\text{mol/l}$ (4.45–12.42 $\mu\text{mol/l}$) and platelet aggregation test] were normal. The reagents used for these tests were as follows: PT and fibrinogen, ILTest PT-Fibrinogen; partial thromboplastin time, IL test APTT-SP (liquid); factor VIII, IL test deficient plasma; antithrombin III, IL test liquid antithrombin; anticoagulant, IL test LAC; protein S, IL test protein S (Clotting-functional); lupus anticoagulant, IL test LAC. The homocysteine level was measured by competitive immunoassay using direct chemiluminescent technology. Platelet aggregation was measured by optical aggregometers, which measure platelet aggregation in platelet-rich plasma, using the turbidometric method developed by Born [10]. A search was performed for other possible causes of stroke in the young; however, serum electrolytes, renal and liver function tests, and erythrocyte sedimentation rate were normal and the patient was negative for syphilis and human immunodeficiency virus. But, as mentioned above, PC antigen levels in the patient's serum were low, only 40.7% (normal range, 77–129%) and PC activity was similarly depressed, 46.3% (normal range, 70–140%). This result was reproducible upon repeat testing 5 months later. Blood samples were collected in siliconized glass containers, containing one part sodium citrate solution (0.11 mol/l) with nine parts venous blood, and avoiding foam formation during collection [11]. Platelet-poor plasma was prepared from citrated blood by centrifugation at 1500 g for 10 min. The supernatant plasma was frozen rapidly in a well-closed plastic container at -20°C . Assays were performed within 2 weeks of storage. Samples were frozen/thawed once and abandoned after analysis. The PC antigen level was measured by the enzyme-linked immunosorbent assay (ELISA) method [12], and PC activity was measured by the chromogenic method [13]. Because of the low PC levels and lack of other precipitating factors, we believed that the cerebral infarction had been caused by the PC deficiency.

After initial therapy with subcutaneous low molecular weight heparin (fraxiparin), the patient was started on long-term anticoagulation with warfarin. When adequate

Fig. 3



Pedigree of 31-year-old man with heterozygous protein C deficiency who suffered severe ischemic stroke because of infarction of the left middle cerebral artery.

anticoagulation was achieved with warfarin, as shown by PT, the low molecular weight heparin was discontinued. There were no complications, particularly no warfarin necrosis.

The patient's hemiparesis and aphasia gradually improved during the following months. The patient's family history showed no thromboembolic episodes, except for the unknown cerebrovascular event that caused his maternal grandmother's death at age 61. To determine whether the patient's PC deficiency was hereditary, we assayed the PC antigen and activity levels in plasma samples from several of his family members (Fig. 3) (Table 1). The patient's father and one of the patient's older sisters had normal PC antigen and activity, but his mother, and his other older sister and his younger brother with their children, showed PC deficiency, both antigen and activity levels (Fig. 3). None of these PC-deficient relatives had a history of thromboembolic disease. Protein S concentrations measured by the

Table 1 Pedigree of a 31-year-old man with heterozygous protein C deficiency

ID	Sex/age	Protein C activity %	Protein C antigen %
I-1	Man/56	103.0	94.1
I-2	Woman/54	46.8	44.6
II-1	Woman/34	84.4	77.5
II-2	Woman/33	68.1	67.0
II-3	Man/31	46.3	40.7
II-4	Man/30	48.3	46.4
III-1	Girl/12	59.4	68.6
III-2	Boy/11	42.8	42.8
III-3	Boy/9	42.2	42.4
III-4	Girl/4	53.2	39.5

coagulation test with inhibition of the PT [14] and were in the normal range in all relatives investigated.

Discussion

PC deficiency is an established risk factor for venous thrombosis [3]; however, associated arterial thrombosis, especially in intracranial arteries, is very rare [15]. Our patient fulfilled all the diagnostic criteria for hereditary PC deficiency [16]: a consistent fall of PC activity and antigen below the normal range, both at the moment of the acute event and after recovery; normal levels of protein S and other vitamin K-dependent clotting factors; absence of recognized causes of acquired PC deficiency, such as liver failure or inflammatory disease [17]; and presence of PC deficiency in at least one other family member. Protein antigen and activity were similar in the patient and all affected members of his family, an observation showing that the deficiency was a type 1 deficiency, and due to either decreased synthesis or increased destruction of PC, rather than to production of a protein with only partial activity [18]. The family pedigree and the measured values of PC activity and antigen suggest that the affected members are heterozygous for this deficiency. No homozygous individuals were discovered, for no cases of purpura fulminans neonatalis, multiple thrombosis, or pulmonary emboli in newborns, the typical appearances of homogenous PC deficiency, were recorded in the family history.

We performed a Medline search to retrieve all published stroke cases in the young that were associated with PC deficiency [6,8,16,19–21]. Most patients had a either personal or family history or both of vascular events and familial PC deficiency. Our patient had no such personal or family history, and his hereditary PC deficiency was discovered during a survey that was part of a study of stroke in the young. The finding of low PC in some of his relatives confirmed this diagnosis.

Once the diagnosis of hereditary PC deficiency was made, subsequent antithrombotic treatment was important. If a cerebrovascular event associated with PC deficiency is diagnosed, initial intensive heparinization accompanied by, and finally replaced by, oral anticoagulant therapy, should be given in order to prevent any further thrombosis [22]. In addition, long-term oral anti-coagulant treatment is considered to be beneficial in preventing a recurrence of arterial or venous thrombosis.

Two studies comparing ethnic groups show that ethnic groups may differ in their normal ranges for PC and other coagulation and anticoagulation factors. In one study, African blacks were found to have lower PC and protein S levels than whites [23]. In a second study, a considerably lower percentage (9.5%) of Chinese patients than Caucasian patients (24–75%) who had had the Fontan procedure were found to have low levels of PC [24]. In

the Fontan procedure, venous blood from the systemic circulation is shunted directly into the lungs, bypassing the right ventricle and increasing venous pressures. The hepatic synthesis of the various factors involved in clotting might be affected by these higher pressures, so it is not certain that the data on ethnic differences reported in the second study apply to normal populations.

Conclusion

Increasing evidence shows that deficiency of protein C can play an important role in the pathogenesis of ischemic strokes, particularly in children and young adults. Thus, we suggest evaluating the PC level in all young patients with thromboembolic disease, particularly those without major risk factors. Once the PC deficiency is confirmed, a further search for PC deficiency in the patient's family is desirable, even if the family history contains no records of thrombotic events, to prevent the occurrence of ischemic strokes.

References

- Hart RG, Miller VT. Cerebral infarction in young adults: a practical approach. *Stroke* 1983; **14**:110–114.
- Esmon CT. The role of protein C and thrombomodulin in the regulation of blood coagulation. *J Biol Chem* 1989; **264**:4743–4747.
- Dahlback B, Villoutreix BO. Regulation of blood coagulation by the protein C anticoagulant pathway: novel insights into structure-function relationships and molecular recognition. *Arterioscler Thromb Vasc Biol* 2005; **25**:1311–1320.
- Mosnier LO, Zlokovic BV, Griffin JH. The cytoprotective protein C pathway. *Blood* 2007; **109**:3161–3172.
- Seligsohn U, Berger A, Abend M, Rubin L, Attias D, Zivelin A, et al. Homozygous protein C deficiency manifested by massive venous thrombosis in the newborn. *N Engl J Med* 1984; **310**:559–562.
- Kohler J, Kasper J, Witt I, Von Reuthern GM. Ischemic stroke due to protein C deficiency. *Stroke* 1990; **21**:1077–1080.
- Camerlingo M, Finazzi G, Casto L, Laffranchi C, Barbui T, Mamoli A. Inherited protein C deficiency and nonhaemorrhagic arterial stroke in young adults. *Neurology* 1991; **41**:1371–1373.
- Matsushita K, Kuriyama Y, Sawada T, Uchida K. Cerebral infarction associated with protein C deficiency. *Stroke* 1992; **23**:108–111.
- Hart RG, Kanter MC. Hematologic disorders and ischemic stroke: a selective review. *Stroke* 1990; **21**:1111–1121.
- Born GVR. Aggregation of blood platelets by adenosine diphosphate and its reversal. *Nature* 1962; **194**:927–929.
- National Committee on Clinical Laboratory Standards. Collection, transport, and processing of blood specimens for testing plasma-based coagulation assay; Vol. 23, No. 35, 4th ed, NCCLS Document H21-A4; 2003.
- Rubenstein KE, Schneider RS, Ullman EF. 'Homogenous' enzyme immunoassay: a new immunochemical technique. *Biochem Biophys Res Commun* 1972; **47**:846–851.
- Francis RB Jr, Patch MJ. A functional assay for protein C in human plasma. *Thromb Res* 1983; **32**:605–613.
- Suzuki K, Nishioka J. Plasma protein S activity using Protac, a snake venom derived activator of protein C. *Thromb Res* 1988; **49**:214–251.
- Broekmans AW. Hereditary protein C deficiency. *Haemostasis* 1985; **15**:233–240.
- Smith DB, Ens GE. Protein C deficiency: a cause of amaurosis fugax. *J Neurol Neurosurg Psychiatry* 1987; **50**:361–362.
- Douay X, Lucas C, Caron C, Goudemand J, Leys D. Antithrombin, protein C and protein S level in 127 consecutive young adults with ischemic stroke. *Acta Neurol Scand* 1998; **98**:124–127.
- Hoshi S, Hijikata M, Togashi Y, Aoyagi T, Kono C, Yamada Y, et al. Protein C deficiency in a family with thromboembolism and identified gene mutations. *Intern Med* 2006; **45**:997–1003.
- Griffin JH, Evatt B, Zimmerman TS, Kleiss AJ, Wideman C. Deficiency of protein C in congenital thrombotic disease. *J Clin Invest* 1981; **68**:1370–1373.
- Velasco F, Andres P, Cañadillas F, Fornes G, Torres A. Transient ischemic attack (T.I.A) in a patient with nonthrombogenic hereditary protein C deficiency under oral contraceptives. *Thromb Haemost* 1985; **54**:904.
- Dusser A, Neumann CB, Wolf M. Temporary protein C deficiency associated with cerebral arterial thrombosis in childhood. *J Pediatr* 1988; **113**:849–851.
- Samama M, Horellou MH, Soria J, Conard J, Nicolas G. Successful progressive anticoagulation in a severe protein C deficiency and previous skin necrosis at the initiation of oral anticoagulant treatment. *Thromb Haemost* 1984; **51**:132–133.
- Jerrard-Dunne P, Evans A, McGovern R, Hajat C, Kaira L, Rudd AG, et al. Ethnic differences in markers of thrombophilia. Implications for the investigation of ischemic stroke in multiethnic populations: The South London Ethnicity and Stroke Study. *Stroke* 2003; **34**:1821–1827.
- Cheung Y-F, Chay CW, Ma ESK. Ethnic differences in coagulation factor abnormalities after the Fontan procedure. *Pediatr Cardiol* 2006; **27**:96–101.