

## Slow Progressive Bilateral Posterior Artery Infarction Presenting as Agitated Delirium, Complicated with Anton's Syndrome

W. Verslegers<sup>a,b</sup>, P.P. De Deyn<sup>a,b</sup>, J. Saerens<sup>a</sup>, P. Marien<sup>a</sup>, B. Appel<sup>c</sup>, B.A. Pickut<sup>b</sup>, A. Lowenthal<sup>a</sup>

<sup>a</sup>Department of Neurology, Algemeen Ziekenhuis Middelheim, <sup>b</sup>Laboratory for Neurochemistry, Born-Bunge Foundation, University of Antwerp, and <sup>c</sup>Department of Neuroradiology, Algemeen Ziekenhuis Middelheim, Antwerp, Belgium

**Key Words.** Anton's syndrome · Cerebrovascular ischemia · Anosognosia · Occipital blindness · Posterior cerebral artery infarction · Confusion · Delirium · Computed tomography

**Abstract.** Three patients presented with an acute agitated delirium as the earliest sign of bilateral posterior cerebral artery infarction. All patients showed a unique slow progressive deterioration with a remarkably long interval between the first neuropsychological and subsequent visual and neurological symptoms, ranging from 3 to 30 days. Repeated CT scans demonstrated hypodensities in the posterior artery territory only after a long interval of 9–12 days, in case 3, and between 33 and 48 days in case 2. In the latter case MRI was still negative 33 days after onset. In 2 patients the cortical blindness was complicated with anosognosia for blindness. Clinical condition worsened progressively in all patients, leading to death, probably due to brainstem infarction. In all 3, the combination of clinical and radiological findings indicated a 'top of the basilar' distribution, which could be confirmed in two by autopsy.

### Introduction

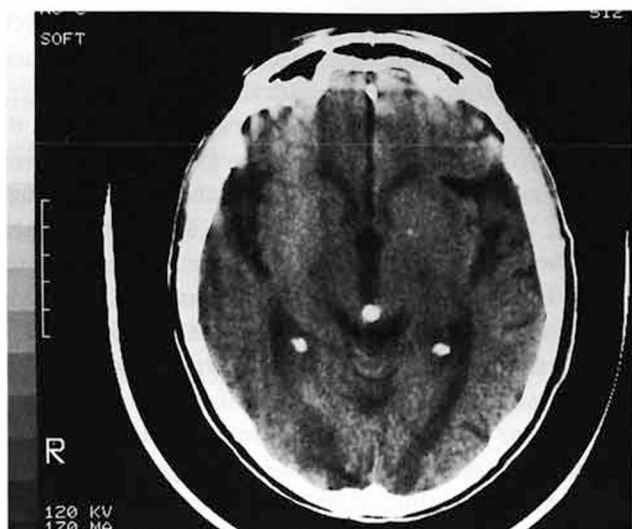
It is known that lesions in brain regions supplied by the posterior cerebral artery (PCA) can cause confusion, especially when both or the dominant PCA are involved [1]. The behavioral disturbances, characterized by agitation, crying and restlessness, are more pronounced when the onset is acute [2]. Depending on the involvement of other structures such as brainstem or diencephalon, the clinical presentation can be persistent, transient or fluctuating. Agitation and aggressivity can be present at onset of the clinical syndrome [3], it may be delayed or even dominate the clinical picture [4].

The 3 reported patients are quite unique because of the very slow progressive and long clinical course resulting in diagnostic difficulties, because of the remarkably long interval before additional neurological symptoms and abnormal CT findings appeared and because they all initially presented in an agitated confusional state.

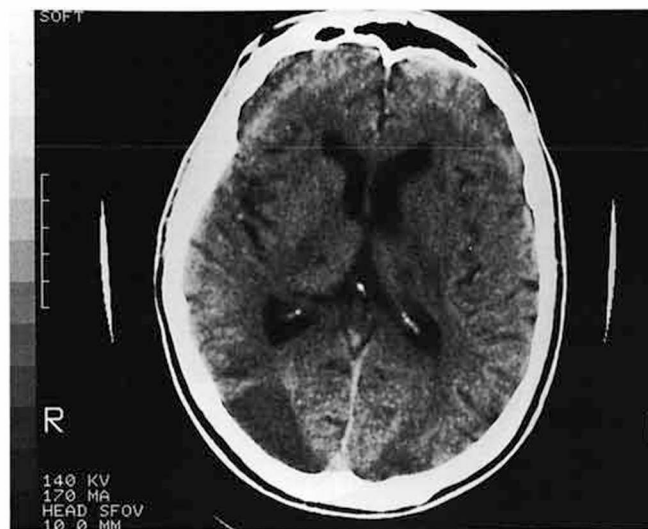### Case Histories

*Case 1.* A 75-year-old right-handed woman suffered from angina pectoris and arterial hypertension since the age of 60. She presented with an acute and severely agitated confusional state with diurnal variation, exhibited restlessness and, mostly at night, wandered about naked and disturbed her neighbors by calling on them. Neurological examination revealed complete disorientation with respect to time and place and retrograde amnesia for several months prior to her admission. She complained at that time of vision disturbances only 3 days after onset. From that time she bumped into objects in her path. After 7 days she became distractible, developed slurred speech containing neologisms and paraphasias. Examination revealed a slight hemiparesis of the right side, ocular immobility whereby she did not explore the space nor respond to visual threat and objects passing along the frontal eye fields. The pupillary reactions to light were positive.

Clinically she was undoubtedly blind but she denied having visual problems. Hematological, biochemical and serological examinations were unremarkable. EEG demonstrated a normal background activity with only slightly irritative features. CT under sedation, 9 days after onset, confirmed the clinically suspected bilateral



**Fig. 1.** CT 9 days after onset of the 'agitated delirium' showed bilateral hypodensities at the top of the occipital lobes. There was also a global cortical atrophy more pronounced at the temporal lobes.



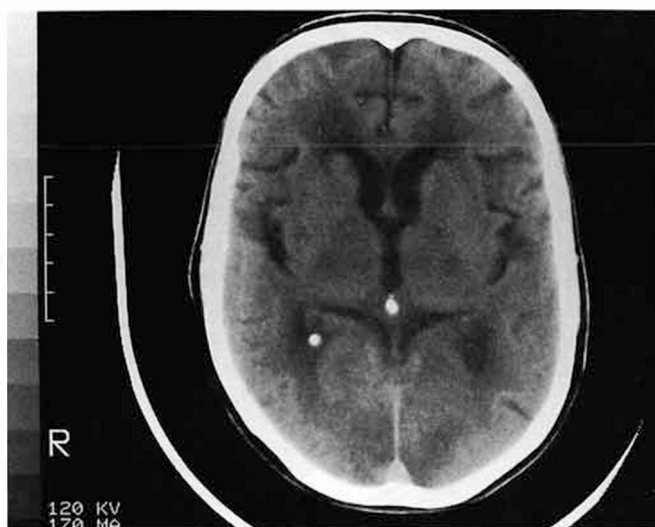
**Fig. 2.** CT 48 days after the first signs and 14 days after the first CT showed well circumscribed lesions of both occipital branches of the occipital lobes, more on the right side, with sparing of the visual cortex bilaterally and with symmetrical lacunar infarctions in the lateral parts of both thalami.

infarctions of the occipital lobes restricted to the top of the lobes (fig. 1). The patient's condition deteriorated further with disturbances of consciousness, persistent agitation with screaming and yelling and a paresis (3/5) of the right arm and leg. A control CT 11 days after onset disclosed more extensive hypodensities in both occipital (occipital and calcarinal) lobes and in the left temporal branches. She died 17 days after onset of the first neuropsychological signs. Examination of the brain demonstrated infarctions of the occipitotemporal lobes on the left side and occipitobasal infarctions on the right. There were confluent necrotic foci in the medial part of the pulvinar with infiltration of foam cells and necrotic foci near the central tegmental tract. The occipitobasal infarctions were above all subcortical and irregular, with pycnotic nuclei and cortical spongiosis. The findings were compatible with multiple embolic infarctions. Examination of the heart revealed an old posterior infarction in the lower one-third of the left ventricle, without mural thrombus.

**Case 2.** A 68-year-old right-handed man suffered since the age of 63 from unstable angina pectoris. He was presented by his family because of sudden distractibility, verbal agitation and changes in behavior and mood. The patient himself complained only of intermittent posteriorly located headache, dyssomnia and generalized tiredness. Repeated neurological examination could not reveal any abnormality. He complained for the first time of feelings of transient heaviness in the left part of the body, unsteadiness and transient visual impairment only 30 days after onset. CT and MRI performed respectively 31 and 33 days after onset were normal. Because of increased angina pectoris, treatment was started with infusion of heparin and isosorbide dinitrate. Because of repeated normal neurological examination, hysteria was considered as differential diagnosis. Forty-eight days after onset he was still emotionally agitated, confused and developed a global amnesia for several months prior to his actual state. On at least 1 day he developed a right ptosis with a paresis of one-fifth of the right leg and a complete

paralysis of the left leg. There was isocoria with normal pupillary reactions. Foveal pursuit movements could not be evoked and reflexes to visual threat were absent. He responded very anxiously to everything that happened in the room. He did not move his eyes nor explore the room visually. When confronted with his visual impairment, he reacted angrily and denied having visual problems. Some days later he developed perseverations, sporadic echolalia and a marked flexion posture of the elbow, wrist and fingers bilaterally. Reflexes were more pronounced in the left leg with ankle clonus and Babinski. Control CT performed 48 days after onset of the delirium showed bilateral hypodensities of both tops of the occipital lobes (more pronounced at the right side), two symmetrical lacunar infarctions in the lateral parts of both thalami with sparing of the splenium and the calcarine cortex bilaterally (fig. 2). The patient's condition deteriorated rapidly resulting in bilateral ptosis, tetraplegia, bilateral Babinski sign with attenuation of the decorticate rigidity of the upper limbs. He shouted especially at night without provocation. A control CT with contrast injection 59 days after onset showed more extended lesions with infarctions in the territory of the posterior temporal artery, more pronounced at the right side, bilateral necrosis of the parietal lobes with luxury perfusion of the right parietal lobe. He died 79 days after onset of the delirium. Autopsy was refused by the family.

**Case 3.** A 73-year-old right-handed woman suddenly developed confused behavior with restlessness, excitability, purposeless acting and unresponsiveness to correcting attempts of her daughter although speech and comprehension were normal. Five days after onset she complained of anorexia, dizziness and transient visual disturbances. All symptoms fluctuated during the daytime. No neurological abnormalities could be detected. Nine days later she developed a sudden loss of consciousness with apneustic breathing, responding only to pain. The cornea reflexes and pupillary reactions to light were absent on the left with the left pupil being smaller than



**Fig. 3.** Control CT 12 days after onset of the confusion showed bilateral hypodensities of both occipital lobes.

the right. Pharyngeal reflexes were absent. Hematological and biochemical screening were normal. A CT performed 9 days after onset of the delirium showed only periventricular leukomalacia. A second CT twelve days after onset demonstrated symmetrical infarctions of both occipital lobes and the visual cortex especially on the right side (fig. 3). There were also bilateral hypodensities of the parietal white matter and a triangular infarction at the pontocerebellar level of the left cerebellum. The patient's clinical condition remained unchanged until death, 3 weeks after onset of confusion. Autopsy revealed complete destruction of both cerebellar lobes, the medio-basal part of both occipital lobes and the striate cortex. There were numerous cribriform cavities in the caudate nucleus, the thalamus and the intralamellar formation at the left side. The heart was dilated without thrombus.

## Discussion

It is known that 'agitated delirium' may result from disconnection of anterior limbic structures from neocortical inputs, from destruction of posterior limbic structures or from disconnection of dominant temporal neocortex from the limbic system [5]. Bilateral PCA infarctions generally result in more severe confusional states, suggesting that disconnection from nondominant limbic structures aggravates the confusion. Unilateral infarctions of the dominant temporal lobe of the PCA can also cause confusion [6]. The degree of confusion may depend on differences in lesion size and localization, lateralization of cognitive functions and absence or presence of threatening hallucinations [7]. In the majority of the cases, the clinical picture is complicated by hom-

onymous hemianopia, cortical blindness, sensory deficit, pure alexia without agraphia, anomia and amnesia, hemiplegia, transcortical sensory aphasia, memory impairment, release hallucinations in blind parts of the visual fields [8], metamorphopsia [9], visual agnosia, color dysnomias, third nerve palsy, thalamic symptomatology, Kluver-Bucy [10], Anton's [11], Balint [12, 13] and Charco-Witbrand [14] syndrome. Because of the variability in the clinical picture, toxic or metabolic encephalopathies, psychiatric diseases or middle cerebral artery ischemia are frequently the first proposed diagnoses [1, 3].

In all our cases, confusion, agitation and disturbances in behavior and mood were the initial symptoms. While 1 patient (case 3) showed only a mild confusion, the others (cases 1 and 2) showed a severely agitated delirium that required sedation to protect them against injuries. A remarkable feature is the long interval between the first neuropsychological symptoms and the subsequent neurological and visual symptoms. The interval ranged between 3 (case 1) and 30 days (case 2). All cases showed a slowly progressive course in which new symptoms appeared, all together leading to death. The long interval accounts also for the CT abnormalities. CT was still normal 9 days (case 3) and 31 days (case 2) after onset. Also MRI was normal 33 days after onset in case 2. The first CT abnormalities appeared between 9 and 12 days (case 3) and between 33 and 48 days (case 2) after onset. In cases 2 and 3 it is undoubtedly demonstrated that CT was normal respectively 9 and 31 days after onset. The progressive course, absence of neurological signs, fluctuating symptoms and normal neuroimaging even suggested a diagnosis of hysteria in a 68-year-old man without psychiatric history. It seems possible that symptoms in the beginning were due to hemodynamic changes, rather than infarction. This may explain the fluctuating symptomatology and the early negative structural neuroimaging.

Although consciousness was not completely lost, patient 2 showed, 48 days after onset, decorticate rigidity of the upper limbs due to biparietal white matter lesions. He also presented a Weber syndrome suggesting involvement of the interpeduncular branches. Cases 1 and 2 with the most pronounced 'agitated delirium' showed signs of fear and anxiety about everything that happened in their environment.

All 3 patients showed infarctions at the 'top of the basilar' [15] with great variability in size and number of the occipital infarctions. At autopsy (cases 1, 3) destruction of the occipital and cerebellar lobes was much more

extensive than suspected by CT. Case 2 also had bilateral lacunar infarctions in the lateral parts of both thalami suggesting that the thalamogeniculate arteries arise from the same PCA. Although CT demonstrated sparing of the visual cortex, case 2 showed total cortical blindness possibly due to a disconnecting lesion between the geniculate bodies and the occipital cortex. Since heparin started 30 days after onset, did not alter deterioration in case 2, and because clinical condition in cases 1 and 3 was too bad at the moment of the CT abnormalities, further investigation as for cardiogenic embolic source were not considered as warranted because they would not have altered diagnosis or treatment.

In cases 1 and 2, denial of visual deficits and pretending they see 'things' suggest that the cortical blindness was complicated by anosognosia (Anton's syndrome) [11] and visual confabulation, despite initial complaints about visual disturbances. They wandered about in their rooms, bumping into objects in their paths. They were indeed blind since patients with an apperceptive visual agnosia, described by Benson and Greenberg [16], do not hit objects. At the time of their blindness they showed ocular immobility which can be explained by the blindness and in case 2 by the parietal lesions similar to the pathology in Balint syndrome [12, 13]. Indeed, lesions in the posterior part of the parietal lobe [17] and disruption of colliculo-pulvinar-parietal projection [18] may result in ocular immobility and impairment of visually guided eye movements.

### Acknowledgements

This investigation was supported by the Medical Research Foundation, OCMW, Antwerp, and the Born-Bunge Foundation, Laboratory of Neurochemistry, University of Antwerp, Belgium.

### References

- 1 Horenstein S, Chamberlain W, Conomy J: Infarctions of the fusiform and calcarine regions: Agitated delirium and hemianopia. *Trans Am Neurol Assoc* 1967;92:85-89.
- 2 Symonds C, MacKenzie I: Bilateral loss of vision from cerebral infarction. *Brain* 1957;80:415-455.
- 3 Mehler MF: The rostral basilar artery syndrome: Diagnosis, etiology, prognosis. *Neurology* 1989;39:9-16.
- 4 Medina JL, Rubino FA, Ross E: Agitated delirium caused by infarctions of the hippocampal formation and fusiform and lingual gyri: A case report. *J Neurol Neurosurg Psychiatry* 1974;24:1181-1183.
- 5 Efron R: Temporal perception, aphasia, and déjà vu. *Brain* 1963;86:403-424.
- 6 Fisher CM: Unusual vascular events in the territory of the posterior cerebral artery. *Can J Neurol Sci* 1986;13:1-7.
- 7 Devinsky O, Bear D, Volpe BT: Confusional states following posterior cerebral artery infarction. *Arch Neurol* 1988;45:160-163.
- 8 Cogan DG: Visual hallucinations as release phenomena. *Graefes Arch Clin Exp Ophthalmol* 1973;188:139.
- 9 Brust JCM, Behrens MM: 'Release hallucinations' as the major symptoms of posterior cerebral artery occlusion: A report of 2 cases. *Ann Neurol* 1973;2:432.
- 10 Kluver H: The temporal lobe syndrome produced by bilateral ablations; in Wolstenholme GEW, O'Connor CM (eds): *Ciba Foundation of the Neurological Basis of Behavior*. Boston, Little, Brown, 1958, pp 175-182.
- 11 Anton G: Über die Selbstwahrnehmungen der Herderkrankungen des Gehirns durch den Rindenblindheit und Rindentaubheit. *Arch Psychiat* 1899;32:86-127.
- 12 Balint R: Seelenlähmung des 'Schauens', optische Ataxie, räumliche Störung der Aufmerksamkeit. *Monatsschr Psychiatr Neurol* 1909;25:51-81.
- 13 Holmes B, Horrax G: Disturbances of spatial orientation and visual attention with loss of stereoscopic vision. *Arch Neurol Psychiatry* 1919;1:385-407.
- 14 Charcot JM: *Clinical Lectures on Diseases of the Nervous System*. Lecture XI. London, New Sydenham Society, 1889, vol 3.
- 15 Caplan LR: 'Top of the basilar' syndrome. *Neurology (NY)* 1980;30:72-79.
- 16 Benson D, Greenberg J: Visual form agnosia. *Arch Neurol* 1969;20:82-89.
- 17 Pierrot-Deseilligny Ch, Gray F, Brunet P: Infarction of both inferior parietal lobules with impairment of visually guided eye movements, peripheral visual inattention and optic ataxia. *Brain* 1986;109:81-97.
- 18 Zihl J, Von Cramon D: The contribution of the second visual system to directed visual attention in man. *Brain* 1979;102:835-856.

Received: July 24, 1990

Accepted after revision: November 5, 1990

Werner Verslegers, MD  
 Department of Neurology  
 Algemeen Ziekenhuis Middelheim  
 Lindendreef 1  
 B-2020 Antwerpen (Belgium)