

# Traumatic Retroclival Epidural Hematoma in a Child

## —Case Report—

Taek-Hyun KWON, Hoon JOY, Youn-Kwan PARK, and Hung-Seob CHUNG

Department of Neurosurgery, College of Medicine, Korea University, Seoul, R.O.K.

### Abstract

An 11-year-old girl presented with a very rare traumatic retroclival epidural hematoma manifesting as bilateral abducens nerve palsy, deviation of the uvula to the left, and weakened movement of tongue, which developed after a motor vehicle accident. The patient was treated conservatively and showed good outcome. Retroclival hematoma is a mainly pediatric entity usually associated with ligamentous injury at the craniocervical junction, and can be treated conservatively with good outcome.

Key words: clivus, epidural hematoma, hyperextension injury

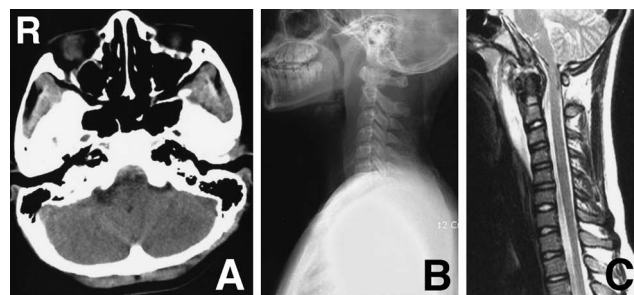
### Introduction

Retroclival epidural hematomas (EDHs) are very rare and only numbered cases have been reported.<sup>1,2,4-18,20,22,23</sup> Most reported cases have been noted in pediatric patients after motor vehicle accidents involving the cervical spine. Here we report another case of traumatic retroclival EDH in a child.

### Case Report

An 11-year-old girl was involved in a motor vehicle accident which caused cervical hyperextension after she was thrown from a passenger seat and collided with the front windshield. On admission, her Glasgow Coma Scale (GCS) score was 15. She complained of headache and neck pain. In addition, swallowing was extremely difficult and she had dysarthria. Physical examination revealed bilateral abducens nerve palsy, deviation of the uvula to the left, and weakened movement of tongue.

Brain computed tomography (CT) revealed a hyperdense lesion ventral to the medulla (Fig. 1A). Radiography of the cervical spine showed straightening of the cervical spine lordosis with a large prevertebral swelling in front of the clivus and upper cervical spine (Fig. 1B). Cervical spine CT showed a retroclival hyperdense mass lesion compatible with acute retroclival EDH, extending from the posterior aspect of dens to the upper clival region, indicating that the dura and tectorial mem-



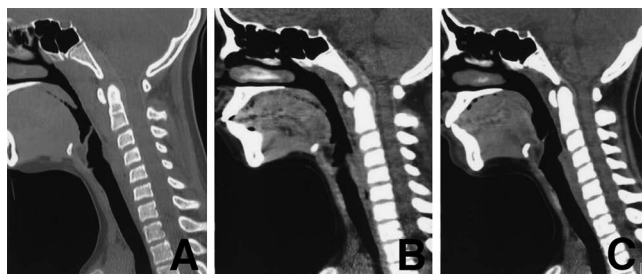
**Fig. 1** A: Initial brain computed tomography scan showing a hyperdense lesion ventral to the medulla. B: Lateral radiograph of the cervical spine revealing straightening of the cervical spine lordosis with a large prevertebral swelling in front of the clivus and upper cervical spine. C: Sagittal T<sub>2</sub>-weighted magnetic resonance image of the cervical spine revealing the better delineation of the hematoma and resultant brainstem compression.

brane had been stripped off the clivus by the hematoma (Fig. 2A). Magnetic resonance imaging provided better delineation of the hematoma and resultant brainstem compression (Fig. 1C). There was no visible fracture or dislocation in the skull base or craniocervical region. However, her cervical spine was immobilized with a Philadelphia brace, given the long segmental stripping of the tectorial membrane.

Clinical status including swallowing and speech improved with conservative treatment consisting of

Received November 7, 2007; Accepted March 26, 2008

simple immobilization. Cervical spine CT obtained 10 days after the accident revealed decreases in the hematoma size and prevertebral soft tissue swelling (Fig. 2B). Follow-up CT 6 weeks after the accident showed spontaneous resorption of the hematoma (Fig. 2C). Her neurological symptoms had also resolved.



**Fig. 2** Serial high resolution computed tomography scans of the cervical spine taken initially (A), and 10 days (B) and 6 weeks after the accident (C) showing gradual decrease of the retroclival hematoma and prevertebral soft tissue swelling.

## Discussion

Posterior fossa EDHs are relatively uncommon, often located between the occipital bone and the dura mater, and, moreover, retroclival EDHs are exceedingly rare. Spontaneous or non-traumatic retroclival are also known in adults.<sup>3,6,8,19,21</sup> However, excluding such non-traumatic cases, only 20 cases of traumatic retroclival hematoma, including our case, have been reported (Table 1),<sup>1,2,4,5,7,9-18,20,22,23</sup> and some striking clinical similarities can be found.

Firstly, most cases occurred in the pediatric population, characteristically after a motor vehicle accident resulting in cervical hyperflexion or hyperextension injuries. The cranio-cervical junction is less stable in children than in adults because the occipital condyles are relatively smaller and the articulation between the cranium and the atlas is more horizontal. In addition, the cranio-cervical junction has increased ligamentous elasticity in children, which predisposes to ligamentous injury at the cranio-cervical junction.<sup>1,7,16</sup> The mechanism of retroclival EDH is controversial. In addition to ordinary retroclival hematoma formation after clivus fracture, cervical hyperflexion or hyperextension in-

**Table 1** Clinical summary of all published cases of traumatic retroclival hematoma

Author (Year)	Age (yrs)	Cause of hematoma	GCS score	GOS score
Orrison et al. (1986) <sup>15</sup>	8	MVA, hyperflexion, lt atlanto-occipital dislocation	3	death
Kurosu et al. (1990) <sup>11</sup>	11	MVA, hyperextension, diastasis of spheno-occipital synchondrosis	7	GR
Papadopoulos et al. (1991) <sup>16</sup>	10	MVA, atlanto-occipital dislocation	4	GR
Castillo et al. (1994) <sup>4</sup>	10	MVA, hyperextension	coma	GR
Marks et al. (1997) <sup>12</sup>	8	MVA, hyperextension, C1-2 dislocation	6	GR
Mizushima et al. (1998) <sup>13</sup>	8	MVA, hyperextension, C1-2 dislocation	6	GR
Muller et al. (1998) <sup>14</sup>	7	MVA, hyperflexion	6	GR
Fuentes et al. (2000) <sup>5</sup>	47	MVA, bil occipital condyle fracture	NA	GR
Khan and Zumstein (2000) <sup>10</sup>	19	MVA, transverse clivus fracture	15	GR
Suliman et al. (2001) <sup>20</sup>	16	MVA, hyperextension, avulsion fracture of lt occipital condyle	10	GR
Yang (2003) <sup>23</sup>	5	MVA	7	GR
Paterakis et al. (2005) <sup>17</sup>	10	MVA, longitudinal clivus fracture	12	GR
Agrawal and Cochrane (2006) <sup>1</sup>	8	MVA	7	GR
Calisaneller et al. (2006) <sup>2</sup>	11	MVA	15	GR
Guillaume and Menezes (2006) <sup>7</sup>	5	MVA	7	GR
	8	ATV accident	15	GR
Itshayek et al. (2006) <sup>9</sup>	12	running fall, hyperextension	15	GR
Ratilal et al. (2006) <sup>18</sup>	26	MVA, hyperextension	13	GR
Vera et al. (2007) <sup>22</sup>	5	MVA, atlanto-occipital dislocation	3	death
Present case	11	MVA, hyperextension	15	GR

ATV: all terrain vehicle, GCS: Glasgow Coma Scale, GOS: Glasgow Outcome Scale, GR: good recovery, MVA: motor-vehicle accident, NA: not available.

jury may cause disruption of the insertion of the tectorial membrane from the clivus, resulting in venous bleeding. The dura is more easily separated from the skull in children, so children are more susceptible to this type of stripping injury.<sup>18,23)</sup> Motor vehicle accidents are more prevalent in adults than in children, but these anatomical characteristics of children contribute to the relatively high occurrence of traumatic retroclival EDH in the pediatric age group.

Secondly, the clinical course of retroclival hematoma seems to be very benign. GCS score is an effective predictor of the course and prognosis in a patient with traumatic brain injury. However, no positive correlation could be established between GCS on admission and outcome in patients with retroclival EDH. Among the 20 cases, all but two patients who died showed good recovery irrespective of GCS score on admission, and even one patient comatose on admission achieved full recovery.<sup>4)</sup>

The present patient had multiple cranial nerve pareses manifesting as bilateral abducens nerve palsy, swallowing difficulty, and tongue weakness. Many previous patients had various cranial nerve pareses: the abducens nerve was the most commonly injured (37%), followed by the hypoglossal nerve (21%) and the glossopharyngeal nerve (16%). The 6th cranial nerve seems to be the most susceptible, possibly because of the longest intracranial course. Direct contusion or stretching of the nerve by the hematoma may be the cause of the cranial nerve paresis,<sup>2)</sup> so most pareses showed good recovery.

Most patients with retroclival hematoma were treated conservatively and had good outcomes, as in our case. Four patients were treated surgically, one with transoral evacuation<sup>12)</sup> and the other three with posterior decompression.<sup>5,14,16)</sup> Regardless of the management option, all patients showed good recovery, except the patients who died due to comorbidities. In our patient, all the symptoms and signs of swallowing and speech difficulties due to multiple cranial nerve pareses resolved gradually within weeks after cervical immobilization. Conservative treatment, in the absence of progressive neurological deterioration, seems to be the treatment of choice. However, evacuation of the hematoma and stabilization procedure should be considered in patients with critical compression of the brainstem or instability of the cranio-cervical junction.

## References

1) Agrawal D, Cochrane DD: Traumatic retroclival epidural hematoma — a pediatric entity? *Childs Nerv Syst* 22: 670–673, 2006

- 2) Calisaneller T, Ozdemir O, Altinors N: Posttraumatic acute bilateral abducens nerve palsy in a child: case report. *Childs Nerv Syst* 22: 726–728, 2006
- 3) Call C, Katranci N, Guzelbag E, Alper H, Yunten N: Retroclival epidural hematoma secondary to decompressive craniectomy in cerebellar infarction: MR demonstration. *J Neuroradiol* 25: 229–232, 1998
- 4) Castillo C, Lambre H, Meli F, Boero A, Lylyk P: [Acute extra-axial hematoma post-traumatic of the clivus]. *Medicina (B Aires)* 54: 150–152, 1994 (Spa, with Eng abstract)
- 5) Fuentes S, Bouillot P, Dufour H, Grisoli F: [Occipital condyle fractures and clivus epidural hematoma: case report]. *Neurochirurgie* 46: 563–567, 2000 (Fre, with Eng abstract)
- 6) Goodman JM, Kuzma B, Britt P: Retroclival hematoma secondary to pituitary apoplexy. *Surg Neurol* 47: 79–80, 1997
- 7) Guillaume D, Menezes AH: Retroclival hematoma in the pediatric population: report of two cases and review of the literature. *J Neurosurg* 105 (4 Suppl): 321–325, 2006
- 8) Guilloton L, Godon P, Drouet A, Guerard S, Aczel F, Ribot C: [Retroclival hematoma in a patient taking oral anticoagulants]. *Rev Neurol (Paris)* 156: 392–394, 2000 (Fre, with Eng abstract)
- 9) Itshayek E, Goldman J, Rosenthal G, Chikoya L, Gomori M, Segal R: Extradural hematoma of the clivus, not limited to the severely injured patient: case report and review of the literature. *J Trauma* 60: 417–420, 2006
- 10) Khan N, Zumstein B: Transverse clivus fracture: case presentation and significance of clinico-anatomic correlations. *Surg Neurol* 54: 171–177, 2000
- 11) Kurosuo A, Amano K, Kubo O, Himuro H, Nagao T, Kobayashi N, Kakinoki Y, Kitamura K: Clivus epidural hematoma: case report. *J Neurosurg* 72: 660–662, 1990
- 12) Marks SM, Paramaraswaren RN, Johnston RA: Transoral evacuation of a clivus extradural haematoma with good recovery: a case report. *Br J Neurosurg* 11: 245–247, 1997
- 13) Mizushima H, Kobayashi N, Sawabe Y, Hanakawa K, Jinbo H, Iida M, Iwata T, Matsumoto K: Epidural hematoma of the clivus: case report. *J Neurosurg* 88: 590–593, 1998
- 14) Muller JU, Piek J, Kallwellis G, Stenger RD: [Prepontine epidural hemorrhage]. *Zentralbl Neurochir* 59: 185–188, 1998 (Ger, with Eng abstract)
- 15) Orrison WW, Rodge S, Kinard RE, Williams JE, Torvik A, Sackett JF, Amundsen P: Clivus epidural hematoma: a case report. *Neurosurgery* 18: 194–196, 1986
- 16) Papadopoulos SM, Dickman CA, Sonntag VKH, ReKate HL, Spetzler RF: Traumatic atlantooccipital dislocation with survival. *Neurosurgery* 28: 574–579, 1991
- 17) Paterakis KN, Karantanis AH, Hadjigeorgiou GM, Anagnostopoulos V, Karavelis A: Retroclival epidural hematoma secondary to a longitudinal cli-

- vus fracture: case report. *Clin Neurol Neurosurg* 108: 67-72, 2005
- 18) Ratilal B, Castanho P, Luiz CV, Antunes JO: Traumatic clivus epidural hematoma: case report and review of the literature. *Surg Neurol* 66: 200-202, 2006
- 19) Schievink WI, Thompson RC, Loh CT, Maya MM: Spontaneous retroclival hematoma presenting as a thunderclap headache: case report. *J Neurosurg* 95: 522-524, 2001
- 20) Suliman HM, Merx HL, Wesseling P, van der Sluijs B, Vos PE, Thijssen HO: Retroclival extradural hematoma is a magnetic resonance imaging diagnosis. *J Neurotrauma* 18: 1289-1293, 2001
- 21) Tomaras C, Horowitz BL, Harper RL: Spontaneous clivus hematoma: case report and literature review. *Neurosurgery* 37: 123-124, 1996
- 22) Vera M, Navarro R, Esteban E, Costa JM: Association of atlanto-occipital dislocation and retroclival haematoma in a child. *Childs Nerv Syst* 23: 913-916, 2007
- 23) Yang BP: Traumatic retroclival epidural hematoma in a child. *Pediatr Neurosurg* 39: 339-340, 2003

---

Address reprint requests to: Youn-Kwan Park, M.D.,  
Department of Neurosurgery, Korea University Guro  
Hospital, 80, Guro-dong, Guro-ku, Seoul, 152-703,  
R.O.K.  
e-mail: ykapa76@yahoo.co.kr