

Neck pain and minor trauma: normal radiographs do not always exclude serious pathology

T Ribbons,¹ S Bell²

A 37-year-old woman presented following a trampolining accident with neck pain and paraesthesia of the left arm. Cervical spine radiographs were normal and a provisional diagnosis of whiplash was made. Three hours later she developed rotational vertigo and then cerebellar signs. Magnetic resonance angiography and magnetic resonance imaging of the brain confirmed the diagnosis of vertebral artery dissection (VAD) with cerebellar embolic infarcts. She was anticoagulated and symptoms resolved over one week. VAD is a relatively common cause of posterior circulation stroke in young people. It usually presents following (often minor) trauma, with headache, neck pain, cerebellar, sensory and cranial nerve signs. However, it remains a diagnosis that is frequently missed or misdiagnosed.

A 37-year-old woman attended the A&E department presenting with left shoulder and neck pain, with pins and needles in her left arm, following a trampolining accident. She had turned a somersault, landing on the trampoline on her left shoulder, head turned to the right. There was no head

injury or loss of consciousness. There were no other injuries. She was previously fit and well and was taking the combined oral contraceptive pill. She was a non-smoker and drank no alcohol.

On arrival in the emergency department she was obviously in pain.

She was immobilised with collar and blocks, given analgesia and sent for cervical spine radiographs, which were normal. The analgesia had been effective and when reviewed she had no tenderness of the C-spine, a good range of neck movement and no neurological deficit. The collar was removed and she was allowed to sit up. A provisional diagnosis of neck sprain (whiplash) was made.

Three hours after the injury she developed rotational vertigo and vomited several times. Treatment with stemetil and the Epley manoeuvre transiently improved her symptoms, which then worsened. One hour later she had developed nystagmus on leftward gaze, truncal ataxia, past pointing with the left hand and had reduced left-sided heel-shin coordination. Cranial nerves, fundoscopy, power, tone, reflexes and sensation in all four limbs were normal.

She was admitted for a magnetic resonance imaging brain scan and a magnetic resonance angiography (MRA). This confirmed the diagnosis of a left vertebral artery dissection (VAD) with a left cerebellar embolic infarct.

She was started on a heparin infusion, before anticoagulation with warfarin. By day 3 the vertigo was persistent but all other neurological signs had resolved. The vertigo slowly resolved over the next week and she remains asymptomatic at 6 months.

DISCUSSION

VAD is an uncommon confirmed cause of stroke; however, it is a common cause of stroke in young (<60 years) people and is more common in women, causing 3–8% of ischaemic strokes in this age group. It is suspected, however, that the condition is underdiagnosed and is actually more common.^{1 2}

Dissection of the vertebral artery is described as spontaneous or, more commonly, traumatic dissection. Trauma is the only definite risk factor for VAD. Although the trauma may be an overt neck injury, more classically the trauma is a low-impact twisting movement of the neck, which turns the head away from the side on which the arterial tear occurs. The amount of force required might be little more than that applied during everyday activities. Common precipitants include chiropractic manipulations, yoga, a trip to the hairdressers or painting the ceiling. The precipitating trauma may precede the onset of symptoms of VAD by a variable time, usually several days and may be as long as a month. It is possible therefore

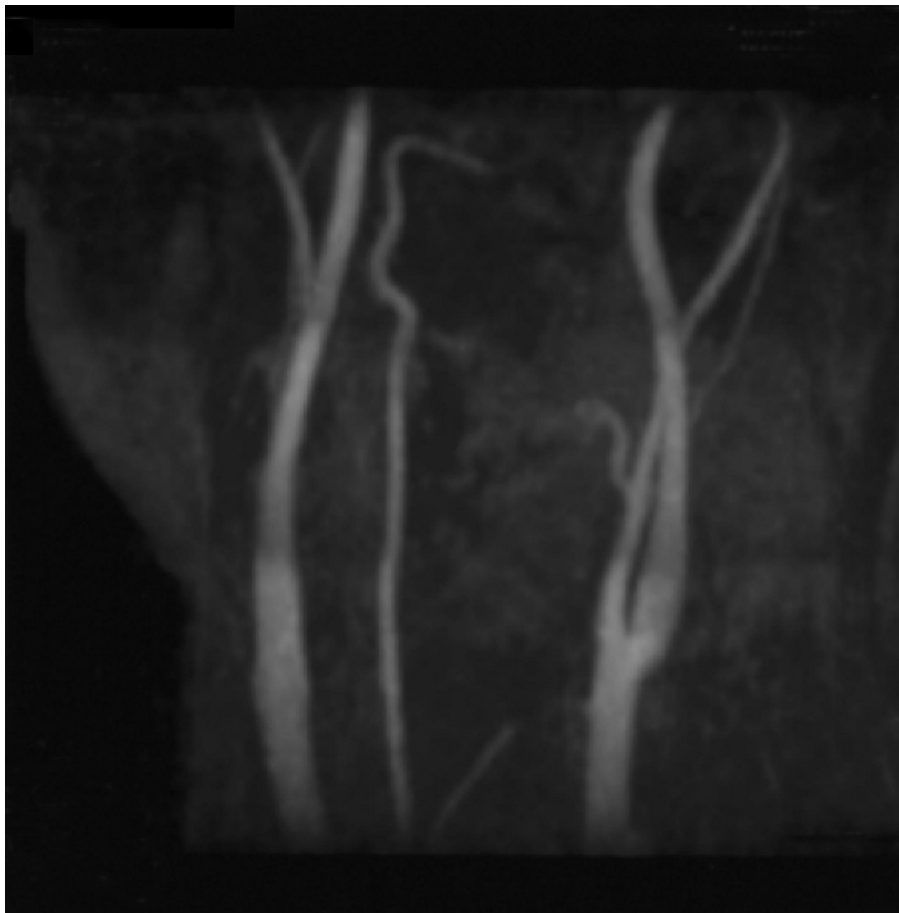


Figure 1 Magnetic resonance angiography demonstrating absence of the vertebral artery on the left.

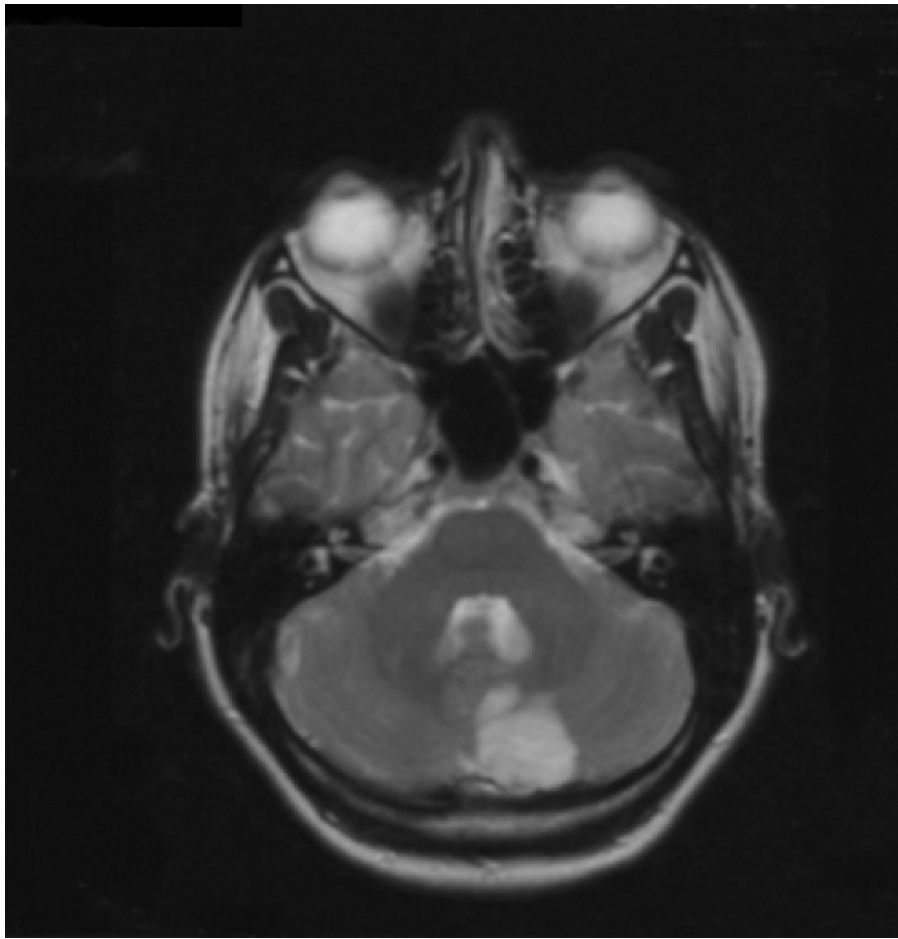


Figure 2 Magnetic resonance imaging brain scan showing a large left cerebellar infarct.

that all VAD are related to at least some minor neck trauma; however, the precipitating event is not always recalled. Spontaneous VAD is also positively associated with oral contraceptives, migraine, hypertension, fibromuscular dysplasia and connective tissue disorders.¹

Dissections in the vertebral artery result from a tear in the arterial wall. The tear may then cause stroke by both extension and rupture extra-arterially (which occurs most commonly in the intracranial portion of the vertebral artery causing a subarachnoid haemorrhage (4%)) or by acting as a site for thrombus formation with extension into the basilar artery and its branches or embolism. It is thought that the majority of strokes related to VAD are caused by thromboembolism.¹

Patients may present with headache (present in 80%, typically occipital), neck

pain and/or stroke symptoms from the territory supplied by the vertebral artery. These symptoms include: cerebellar signs – ipsilateral loss of coordination, nystagmus, ataxia, vertigo; cranial nerve palsies, affecting CN V, VIII–XII: V – ipsilateral facial dysaesthesia, VIII – vertigo, tinnitus, IX, X – dysarthria, dysphagia, XII – ipsilateral loss of taste; sensory fibres as they pass through the lateral medulla causing ipsilateral sensory loss.¹

The diagnosis of VAD begins with a suggestive history and clinical signs. It is confirmed traditionally by angiography, or more recently by MRA or Doppler ultrasound. The mainstay of treatment is anticoagulation for a minimum of 6 months. Neurosurgical referral is warranted following subarachnoid haemorrhage, or if adequate anticoagulation fails to prevent recurrent emboli. The prognosis of VAD

is good, with complete resolution of symptoms or minimal functional deficit in approximately 75% of patients at one month, although fatal cases have occurred.¹

The diagnosis has in the past been missed, at least initially, in many cases. The proposed reasons VAD is not suspected include: (1) it is relatively rare; (2) symptoms and signs (pain and neurological) may be masked or confused by and wrongly attributed to coexistent head, neck or limb injury following trauma; (3) the patient may neglect to mention neck trauma, especially if minor, as the time interval between precipitating trauma and the development of neurological signs may be days or even weeks.^{3, 4}

Rapid resolution of the symptoms, which occurs in the majority of cases, may have occurred before the availability of radiological confirmation with angiography/MRA, particularly if these facilities are not immediately available.

CONCLUSION

Neck injury is a very common presentation to emergency departments. Normal radiographs following minimal trauma to the neck do not always exclude serious pathology. VAD should be suspected in any young patient with symptoms of a posterior circulation stroke following neck trauma.

¹ Accident and Emergency Department, Queen Alexandra Hospital, Cosham, Portsmouth, UK; ² Poole Hospital, Poole, Dorset, UK

Correspondence to: Dr T Ribbons, Accident and Emergency Department, Queen Alexandra Hospital, Southwick Hill Road, Cosham, Portsmouth PO6 3LY, UK; tamsinribbons@doctors.org.uk

Accepted: 21 February 2008

Competing interests: None declared.

Patient consent: Obtained.

Emerg Med J 2008;**25**:609–610.
doi:10.1136/emj.2007.050328

REFERENCES

1. **Schievink WI.** Spontaneous dissection of the carotid and vertebral arteries. *N Engl J Med* 2001;**344**:898–906.
2. **Bin Saeed A, Shuaib A, Al-Sulaiti G, et al.** Vertebral artery dissection: warning symptoms, clinical features and prognosis in 26 patients. *Can J Neurol Sci* 2000;**27**:292–6.
3. **Hilton-Jones D, Warlow CP.** Non-penetrating arterial trauma and cerebral infarction in the young. *Lancet* 1985;**1**:1435–8.
4. **Schellinger PD, Schwab S, Krieger D, et al.** Masking of vertebral artery dissection by severe trauma to the cervical spine. *Spine* 2001;**26**:314–19.



Neck pain and minor trauma: normal radiographs do not always exclude serious pathology

T Ribbons and S Bell

Emerg Med J 2008 25: 609-610
doi: 10.1136/emj.2007.050328

Updated information and services can be found at:
<http://emj.bmj.com/content/25/9/609>

These include:

References

This article cites 4 articles, 0 of which you can access for free at:
<http://emj.bmj.com/content/25/9/609#BIBL>

Email alerting service

Receive free email alerts when new articles cite this article. Sign up in the box at the top right corner of the online article.

Topic Collections

Articles on similar topics can be found in the following collections

[Clinical diagnostic tests](#) (996)
[Radiology](#) (945)
[Radiology \(diagnostics\)](#) (852)
[Stroke](#) (225)
[Pain \(neurology\)](#) (954)
[Headache \(including migraine\)](#) (105)
[Cranial nerves](#) (40)
[Ear, nose and throat/otolaryngology](#) (106)
[Trauma](#) (996)
[Trauma CNS / PNS](#) (279)

Notes

To request permissions go to:
<http://group.bmj.com/group/rights-licensing/permissions>

To order reprints go to:
<http://journals.bmj.com/cgi/reprintform>

To subscribe to BMJ go to:
<http://group.bmj.com/subscribe/>