

Guillain-Barré Syndrome with Optic Neuritis and a Focal Lesion in the Central White Matter Following Epstein-Barr Virus Infection

Jae Young An, Bora Yoon, Joong Seok Kim, In Uk Song, Kwang Soo Lee and Yeong In Kim

Abstract

We report a case of Guillain-Barré syndrome (GBS) accompanied by optic neuritis and a central white matter lesion subsequent to Epstein-Barr virus (EBV) infection. A 49-year-old man presented with visual disturbance and hemiparesis one week after developing cold-like symptoms. T2- and diffusion-weighted brain MRI showed a high-signal intensity lesion in the left internal capsule. The patient's visual acuity improved during steroid pulse therapy, but his hemiparesis progressed to quadriparesis. Nerve conduction studies showed demyelination predominant in the distal nerve terminals, consistent with GBS. Serological testing suggested EBV reinfection. Our findings indicate that EBV-related central and peripheral demyelination can occur simultaneously and can be successfully treated with a combination of corticosteroids and immunoglobulin.

Key words: Epstein-Barr virus, Guillain-Barré syndrome, optic neuritis, central white matter

(Inter Med 47: 1539-1542, 2008)

(DOI: 10.2169/internalmedicine.47.1224)

Introduction

There have been several reports of central nervous system (CNS) involvement in Guillain-Barré syndrome (GBS), which is usually associated with cytomegalovirus or mycoplasma pneumonia (1-4). Although the neurological complications of Epstein-Barr virus (EBV) infection include a wide spectrum of clinical syndromes involving the CNS and peripheral nervous system (PNS) (5, 6), GBS accompanied by optic neuritis (ON) and a focal lesion in the central white matter subsequent to EBV infection is very rare.

Case Report

A 49-year-old man with arterial hypertension experienced a visual disturbance in his right eye accompanied by right hemiparesis upon awakening. The patient had had a cough and low-grade fever 7 days earlier. On physical examination, the patient had a body temperature of 36.7°C and a blood pressure of 135/76. Neurological examination revealed mild

right hemiparesis (Medical Research Council [MRC] grade 4). Visual acuity was light perception in the right eye. Deep tendon reflexes (DTRs) were slightly decreased in the right upper and lower extremities. All other neurological findings were normal. A complete blood count showed a hematocrit of 44.5%, a WBC count of 7.78×10^9 cells/ μ L (67.5% neutrophils, 24.6% lymphocytes, and 5.8% monocytes), and a platelet count of 274×10^9 cells/ μ L. The results of blood chemistry, including transaminase, were normal, as were the chest radiograph findings. Brain magnetic resonance imaging (MRI) revealed a focal area of high signal intensity in the left internal capsule on T2- and diffusion-weighted images, but there was no decrease in the apparent diffusion coefficient (ADC) value, and no gadolinium enhancement was observed (Fig. 1). A test for visual evoked potential showed no wave formation on the right side.

The CSF was clear, with an opening pressure of 17cmH₂O, WBC count of 3 cells/ μ L, glucose level of 72.2 mg/dL (blood glucose of 128.5 mg/dL), and protein level of 55 mg/dL. No microorganisms were observed on Gram- and acid-fast bacilli (AFB)-stained smears or an Indian ink prepara-

¹Department of Neurology, College of Medicine, The Catholic University of Korea, Seoul, Korea

Received for publication April 18, 2008; Accepted for publication May 22, 2008

Correspondence to Dr. Yeong In Kim, nuyikim@catholic.ac.kr

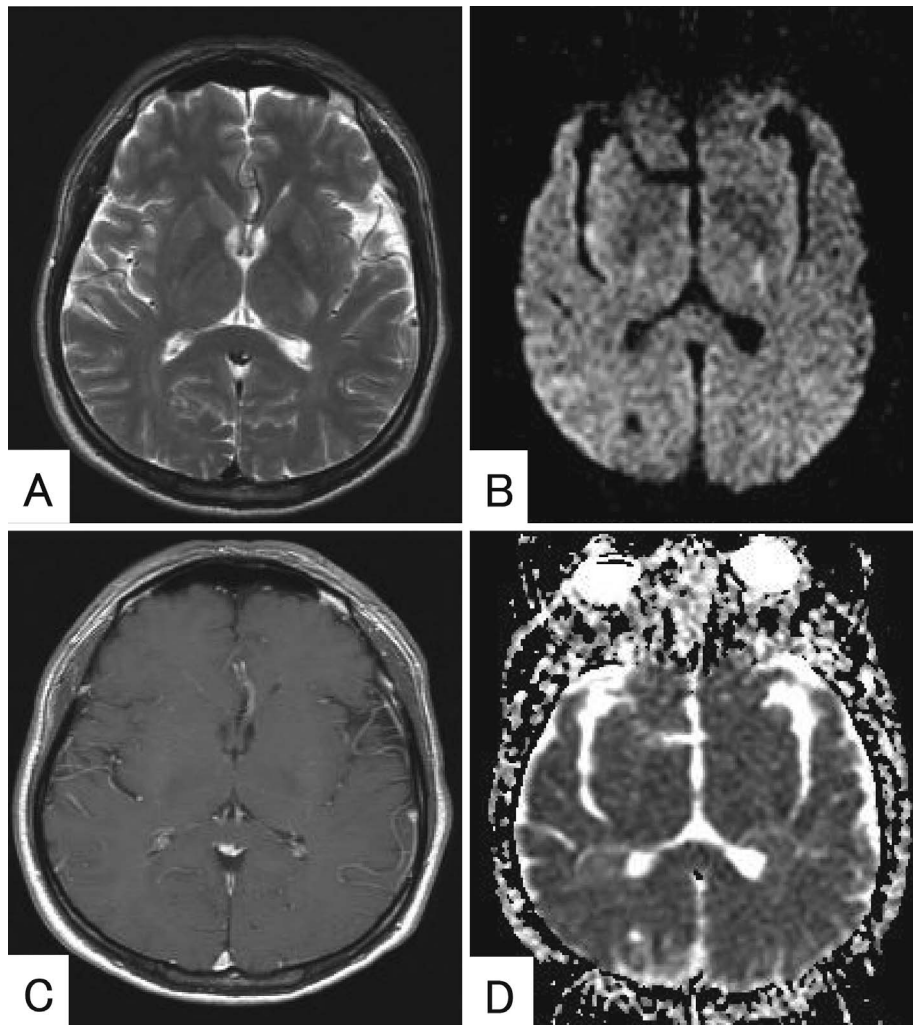


Figure 1. A focal area of high signal intensity on T2-weighted (A) and diffusion-weighted (B) MRI was noted in the posterior limb of the left internal capsule, which showed no gadolinium enhancement (C) and no decrease in the apparent diffusion coefficient (D).

tion. CSF cryptococcal antigen was negative, as was PCR for *Mycobacterium tuberculosis* and herpes simplex. The CSF concentration of myelin basic protein was not elevated, and the IgG index was normal. Oligoclonal bands were not detected. Tests for vasculitic markers, including serum anti-nuclear antibodies, extractable nuclear antigens and antineutrophil cytoplasmic antigen, were negative.

The patient was initially diagnosed with acute disseminated encephalomyelitis and treated with pulse intravenous methylprednisolone (1 g/day for 3 days). On day 2, the hemiparesis progressed to quadriparesis (MRC 2-3/5), and DTRs were absent in all limbs.

Table 1 shows results of nerve conduction studies. There was evidence of demyelination predominant in the distal nerve terminals; motor distal latencies were substantially prolonged in all the nerves tested with relative preservation of nerve conduction velocities in the forearm and leg segments. Reduced median and ulnar sensory responses with preserved sural responses were consistent with demyelination in the distal nerve segments. Figure 2 shows waveforms in median and ulnar motor studies. Abnormal temporal dis-

persion of the distally evoked compound muscle action potentials, again, supported demyelination in the motor nerve terminals. Serum anti-GM1, GD1, GQ1b and MAG antibodies were negative. Serologic tests for EBV were performed by enzyme immunoassay. The patient was positive for antibodies to viral capsid antigen (VCA) IgG and IgM and EBV nuclear antigen (EBNA) IgG and IgM, but negative for EBV-early antigen, diffuse or restricted (EADR) IgG and IgM antibodies. Serologic tests for CMV, *C. jejuni*, and *M. pneumoniae* were negative.

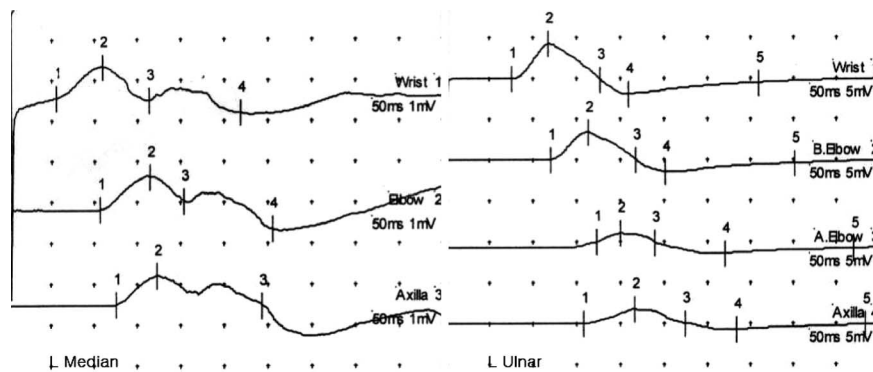
The patient was diagnosed with atypical GBS associated with EBV infection. Treatment with intravenous immunoglobulin G (IVIgG) (0.4 mg/kg/day for 5 days) was started on day 4. Bilateral peripheral facial palsy, dysphagia, and mild dyspnea were noted on day 5, but the patient's visual acuity in the right eye improved to a finger count of 30 cm. On day 35, the patient was able to walk without support, and the visual acuity in his right eye improved to 0.16.

Table 1. Motor and Sensory Nerve Conduction Studies

Motor	L Median	L Ulnar	R Peroneal	R Tibial
DL (ms)	5.6	7.65	NP	9.65
Distal amp (mV)	1.3	6.3	NP	2.0
Proximal amp (mV)	1.2	2.6	NP	1.8
CV (m/s)	47.5	50.6	NP	36.2
F wave latency (ms)	35.75	NP	NP	NP
Sensory	L Median	L Ulnar	R Sural	L Sural
Distal amp (μV)	2.8	NP	11.1	10.3
CV (m/s)	58.1	NP	46.3	42.5

Distal amplitude was obtained by stimulating at wrist or ankle and proximal amplitude by stimulating at axilla or knee.

R = right; L = left; DL = distal latency; Amp = amplitude; CV = conduction velocity; NP = no potential

**Figure 2. Motor nerve conduction studies of the left median and ulnar nerves showed conduction block and temporal dispersion.**

Discussion

The clinical spectrum of neurological complications associated with EBV infection is wide, but the exact incidences of these complications are unknown. Some studies reported an association between EBV infection and GBS in up to 10% of cases (7, 8).

In the present case, the patient initially presented with ON and a focal lesion in the central white matter after developing mild symptoms of an upper respiratory infection, and progressed to areflexic paralysis, bilateral facial nerve palsy, and autonomic dysfunction, consistent with GBS.

Brain MRI suggested that the lesion was caused by subacute infarction or demyelination. However, we thought that this lesion was more likely to have resulted from demyelination than from subacute infarction because the MRI was performed within 10 hours after the onset of weakness. However, it was uncertain whether the initial right-sided weakness was due to the left-sided focal central white matter lesion or whether it was an early symptom of GBS.

Although infection and neurological symptoms may coincide, there was a clear correlation between the clinical symptoms and serological findings in the present case. Serologic testing of early acute phase specimens for EBV suggested reinfection (9, 10). EBV-associated neurological disease was previously thought to occur exclusively in cases of acute primary infection and children. However, with the re-

cent development of improved diagnostic tools, there have been several reports of EBV-related neurological complications associated with reactivated infection in adults (11, 12).

In most of the reported cases of GBS with ON, the temporal profile of GBS differed from that of ON (1, 13). This biphasic illness profile suggests that an autoantigen was liberated from the nervous system during the first attack and subsequently sensitized the host to cause the second insult (13). However, in the present case, GBS developed at the same time as ON, which suggests that an epitope shared by the CNS and PNS was targeted. The patient's visual acuity improved, but the hemiparesis progressed to quadriparesis, and peripheral facial nerve palsy and autonomic symptoms began to develop after steroid pulse therapy. Although the exact mechanism is not fully understood, the pathogenesis of ON or central white matter lesion development may differ from that of GBS.

Given the widespread prevalence of human EBV infection throughout the world, it is likely that the burden of neurological disease associated with EBV has been underestimated. Furthermore, EBV may present atypically, and it has been associated with a wide spectrum of neurologic diseases. EBV should be considered when a patient presents with both CNS and PNS symptoms. Simultaneous treatment of high-dose steroid pulse and IVIgG therapy may be more helpful in reducing the incidence of adverse neurological outcomes than IVIgG monotherapy in these cases.

References

1. Nadkarni N, Lisak R. Guillain-Barré syndrome (GBS) with bilateral optic neuritis and central white matter disease. *Neurology* **43**: 842-843, 1993.
2. Ginestal RC, Plaza JF, Callejo JM, Rodriguez-Espinosa N, Fernández-Ruiz LC, Masjuán J. Bilateral optic neuritis and Guillain-Barré syndrome following an acute *Mycoplasma pneumoniae* infection. *J Neurol* **251**: 767-768, 2004.
3. Pfausler B, Engelhardt K, Kampfl A, Spiss H, Taferner E, Schmutzhard E. Post-infectious central and peripheral nervous system diseases complicating *Mycoplasma pneumoniae* infection. Report of three cases and review of the literature. *Eur J Neurol* **9**: 93-96, 2002.
4. Igarashi O, Fujioka T, Kishi M, Normoto N, Iwasaki Y, Kurihara T. Guillain-Barré syndrome with optic neuritis and cytomegalovirus infection. *J Peripher Nerv Syst* **10**: 340-341, 2005.
5. Portegies P, Corssmit N. Epstein-Barr virus and the nervous system. *Cur Opin Neurol* **13**: 301-304, 2000.
6. Conelly KP, DeWit LD. Neurologic complication of infectious mononucleosis. *Pediatr Neurol* **10**: 181-184, 1994.
7. Hahn AF. Guillain-Barré syndrome. *Lancet* **325**: 635-641, 1998.
8. Winer JB, Hughes RAC, Anderson MJ, Jones DM, Kangro H, Watkins RP. A prospective study of acute idiopathic neuropathy: II antecedent events. *J Neurol Neurosurg Psychiatry* **51**: 613-618, 1988.
9. Nystad TW, Myrnes H. Prevalence of primary versus reactivated Epstein-Barr virus infection in patients with VCA IgG-, VCA IgM- and EBNA-1 antibodies and suspected infectious mononucleosis. *J Clin Virol* **38**: 292-297, 2007.
10. Nalesnik MA. Epstein-Barr virus. In: Laboratory diagnosis of viral infections. Lennette EH, Smith TF, Eds. Marcel Dekker, Inc., New York, 1999: 385-419.
11. Merelli E, Bedin R, Sola P, et al. Encephalomyeloradiculopathy associated with Epstein-Barr virus: primary infection or reactivation? *Acta Neurol Scand* **96**: 416-420, 1997.
12. Weinberg A, Li S, Palmer M, Tyler KL. Quantitative CSF PCR in Epstein-Barr virus infections of the central nervous system. *Ann Neurol* **52**: 543-548, 2002.
13. Nikoskelainen E, Riekkinen P. Retrobulbar neuritis as an early symptom of Guillain-Barré syndrome. Report of a case. *Acta Ophthalmol (Copenh)* **50**: 111-115, 1972.