

Stroke Following Oral Trauma in Children

Stroke after oral trauma in children is a rare but catastrophic event. We describe two cases of stroke in children after each child fell with a writing instrument in the mouth. Both children had a latent period prior to the onset of neurologic symptoms. Ischemic infarction in the distribution of the middle cerebral artery was present in both cases. Both children were left with permanent hemiparesis. The case reports are reviewed and diagnosis and therapy are discussed. Emergency physicians should be aware of the risk of neurologic complications following apparently asymptomatic oral trauma. [Graham CJ, Schwartz JE, Stacy T: Stroke following oral trauma in children. Ann Emerg Med September 1991;20:1029-1031.]

Charles J Graham, MD*
Little Rock, Arkansas
Jane E Schwartz, MD†
Theresa Stacy, MD‡
Oklahoma City, Oklahoma

From the Department of Pediatrics, University of Arkansas for Medical Sciences, Little Rock;* and the Departments of Pediatrics† and Radiology,‡ University of Oklahoma Health Sciences Center, Oklahoma City.

INTRODUCTION

Oral trauma in children is a relatively common occurrence and is generally benign. Vascular injury following oral trauma is infrequent but can be catastrophic. We report two cases of children presenting to the emergency department after suffering a stroke after oral trauma with a writing instrument.

Received for publication February 13, 1991. Accepted for publication April 29, 1991.

Address for reprints: Charles J Graham, MD, Pediatric Emergency Medicine, Arkansas Children's Hospital, 800 Marshall Street, Little Rock, Arkansas 72202.

Case 1

One day prior to admission, a previously healthy 21-month-old boy was found by his grandmother after falling with a pencil in his mouth. The child had blood coming from his mouth and on both hands. After the bleeding stopped, he seemed normal to his parents. About 18 hours later, the child fell to the floor while playing and was unable to move his left arm or left leg. He was taken to a local ED and subsequently was referred to our facility. His medical history was remarkable only for a linear skull fracture at 7 months. There was no family history of childhood stroke or sickle cell disease.

Physical examination on admission revealed an awake and alert child. A wound was visible on the soft palate and along the right tonsillar pillar with no active bleeding. A firm mass was palpable along the right side of the neck with bluish discoloration of the overlying skin. Neurological examination revealed a left seventh cranial nerve palsy, left hemiparesis with hyperactive deep tendon reflexes in the arm and leg, and positive Babinski sign on the left.

Laboratory studies included hemoglobin of 11.8 gm/dL and hematocrit of 35.7%. The platelet count was 609,000/mm³. Sickle cell screen was negative. Prothrombin time was 9.9 seconds, and partial thromboplastin time was 34.6 seconds. A cranial computed tomography (CT) study revealed a wedge-shaped area of decreased attenuation in the right temporal parietal cortex in the distribution of the right middle cerebral artery consistent with ischemic infarction (Figure 1). A CT scan of the neck revealed considerable right-sided soft tissue swelling obliteration of muscle layers consistent with edema or hematoma formation (Figure 2). On the second hospital day, a four-vessel cerebral arteriogram demonstrated stenosis with almost complete obstruction of the right internal carotid artery.

The patient underwent internal carotid artery ligation on the third hospital day. He was discharged home on the 16th hospital day with a continuing dense left hemiparesis.

Case 2

A previously healthy 17-month-old girl had a sudden onset of refusal to walk, refusal to move the left side of her face, and irritability. Four hours prior to the onset of symptoms, she had fallen with a pencil in her mouth. She was taken to the local ED, where left facial weakness and left hemiparesis were noted. She was referred to our facility for evaluation.

Physical examination on arrival demonstrated left facial weakness and left hemiparesis. A hemorrhagic lesion was seen on the right posterior pharynx. There were no palpable neck masses. Laboratory studies included hemoglobin of 10.4 gm/dL, hematocrit of 32.2%, prothrombin time of 10.3 seconds, and partial thromboplastin time of 29.6 seconds. A magnetic resonance imaging study of the head revealed a focal area of high signal intensity in a triangular pattern in the right temporal-parietal cortex consistent with infarction. In addition, a focal area of high signal intensity in the right oropharynx was seen consistent with hematoma and soft tissue swelling. A four-vessel arteriogram demonstrated abrupt truncation of the right internal carotid artery consistent with dissection. No surgical intervention was performed.

The patient was discharged home on the fourth hospital day with continuing left facial weakness and hemiparesis and was referred for outpatient physical therapy.

DISCUSSION

This report describes two children who fell with a writing instrument in the mouth. The children appeared to be well immediately following the injury but had the abrupt onset of neurological symptoms hours later. By the time symptoms were present and the patients were evaluated, ischemic infarction in the middle cerebral artery distribution had occurred. One of the children described had a palpable mass in the neck. One child was managed conservatively; the other underwent internal carotid ligation in an attempt to prevent further embolization. Both children had a permanent hemiparesis.

Oral trauma is relatively common in children as they are prone to put objects in their mouth and fall. Caldwell first described stroke in children following oral trauma in 1936.¹ Twenty-six cases of stroke following

FIGURE 1. CT scan of the head demonstrating an area of decreased attenuation on the right consistent with ischemic infarction.

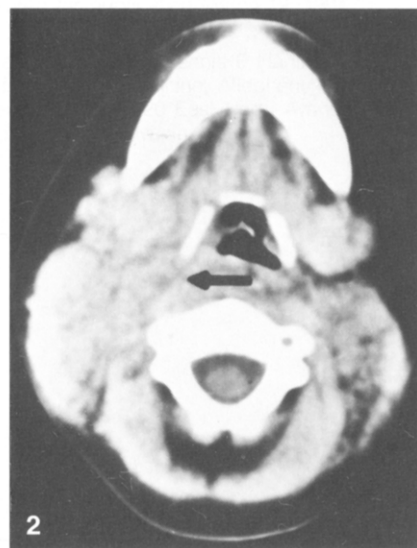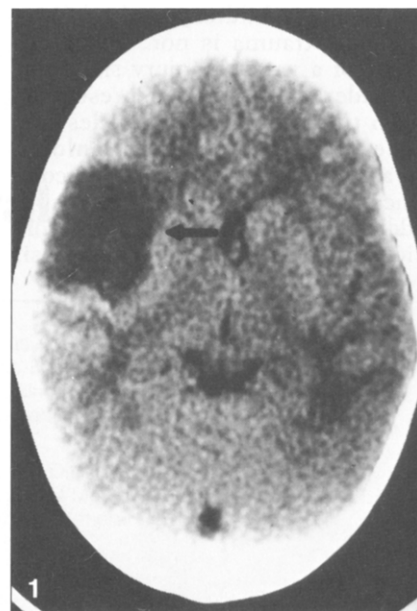
FIGURE 2. CT scan of the neck demonstrating soft tissue swelling and obliteration of muscle layers on the right.

oral trauma in children have been documented in the English literature; 16 of these involved a child falling with an object such as a pen, pencil, stick, or knitting needle in the mouth.²⁻⁵ Thus, Bickerstaff termed such trauma "pencil injuries."⁶ Reports have included both penetrating and nonpenetrating pharyngeal trauma. It is thought that the injury damages the intima of the arterial wall, predisposing to the thrombus formation. Ischemic infarction occurs after a latent period of between three and 48 hours with propagation of the thrombus or embolus formation.² Typically, the middle cerebral artery distribution is affected, resulting in contralateral hemiparesis. Carotid arteriography will demonstrate the thrombosis, and at times, propagation of the thrombus or evidence of embolism.⁴

Therapy for this condition is controversial. Some authors advocate supportive and rehabilitative care,² while others suggest possible surgical intervention depending on the site and nature of the lesion.⁴ The prognosis for these injuries is poor, with 30% mortality and 60% permanent paresis based on reported cases.³

An important unanswered question regards the management of the asymptomatic child who is evaluated for pharyngeal trauma. Almost all described cases of vascular injury have had an asymptomatic "latent" period; thus, a patient may seem normal while a thrombus is forming in the artery. In fact, many of these children are never evaluated by medical personnel. Indeed, the general public and much of the medical profession is not aware of the risk of neurologic complications. Even if the patient is seen immediately after such trauma, the risk of neurologic complications may not be identified.

A noninvasive study such as ultrasound and/or Doppler imaging might be able to demonstrate the vascular injury or thrombus formation prior to the onset of neurologic symptoms.



If the lesion were demonstrated in a child prior to infarction, stroke might be prevented through surgical intervention or anticoagulation. Hengerer, et al have advocated Doppler or angiographic studies for children with lateral soft palate or peritonsillar wounds.⁷ Mains and Nagle, however, advocate observation and further evaluation following the onset of symptoms such as headache or vomiting.²

SUMMARY

We describe two patients who suffered stroke and permanent paresis following oral trauma with a writing instrument. While oral trauma is

common in children, stroke following such trauma is not. The possibility of a vascular injury should be considered in children presenting with traumatic pharyngeal lesions. Emergency physicians should be aware of the risk of neurologic complications following oral trauma. In addition, oral trauma should be considered in the differential diagnosis

of any child who presents with cerebral infarction.

REFERENCES

1. Caldwell JA: Posttraumatic thrombosis of internal carotid artery: Report of 2 cases. *Am J Surg* 1936;32:522-523.
2. Mains B, Nagle M: Thrombosis of the internal carotid artery due to soft palate injury. *J Laryngol Otol* 1989;103:796-797.
3. Pearl PL: Childhood stroke following intraoral trauma. *J Pediatrics* 1987;110:574-575.
4. Woodhurst WB, Robertson WD, Thompson GB: Carotid injury due to intraoral trauma: Case report and review of literature. *Neurosurgery* 1980;6:559-563.
5. Pitner SE: Carotid thrombosis due to intraoral trauma. *N Engl J Med* 1966;274:764-767.
6. Bickerstaff ER: Aetiology of acute hemiplegia in childhood. *Br Med J* 1964;2:82-87.
7. Hengerer AS, DeGroot TR, Rivers RJ, et al: Internal carotid artery thrombosis following soft palate injury: A case report and review of 16 cases. *Laryngoscope* 1984;94:1571-1574.

ERRATA

In the article "Electronic Weaponry — A Question of Safety" [May 1991;20:583-587], the following reference should be cited after the last sentence under the subheading "Safety Controversy" (p 585-586): Koscove E: The Taser® Weapon: A New Emergency Medicine Problem. *Ann Emerg Med* 1985;14:1205-1208.

In the article "A Randomized Comparison of Atropine and Metaproterenol Inhalational Therapies for Refractory Status Asthmaticus" [May 1991;20:513-519], Table 2 should appear as follows:

TABLE 2. Patients with changes in FEV₁ of 15% or more

	No. of Patients	FEV ₁ ↑ by ≥ 15% N (%)	FEV ₁ ↓ by ≥ 15% N (%)
Atropine	20	8 (40)	7 (35)
Metaproterenol	20	12 (60)	2 (10)
P		> .05	< .05