

Acute Hemiplegia Associated with HIV Infection

Steven L. Kugler, MD*†,
Asher Barzilai, MD*,
David S. Hodes, MD*,
Aryeh Stollman, MD‡, Chun K. Kim, MD§,
Alexander C. Hyatt, MD*, and
Alan M. Aron, MD*†

An acute hemiplegia secondary to a large cerebral infarct is described in a 16-month-old infant with congenitally-acquired human immunodeficiency virus infection. Serial imaging studies during the next year documented improvement in his hemiplegia and a static underlying human immunodeficiency virus encephalopathy. Acquired immunodeficiency syndrome should be included in the differential diagnosis of children with acute hemiplegia.

Kugler SL, Barzilai A, Hodes DS, Stollman A, Kim CK, Hyatt AC, Aron AM. Acute hemiplegia associated with HIV infection. *Pediatr Neurol* 1991;7:207-10.

Introduction

Neurologic sequelae of human immunodeficiency virus (HIV) infection in children are the most frequently encountered complications involving nearly 90% of symptomatic patients [1]. Neurologic manifestations of HIV infection have included an encephalopathy characterized by developmental delay, cognitive deficits, acquired microcephaly, pyramidal tract dysfunction, ataxia, pseudobulbar palsy, and seizures [2,3]. Clinical presentations of stroke and/or autopsy findings of cerebral infarcts in HIV-infected adults and children have only recently been reported [4-12]. We describe the clinical course of acute hemiplegia over a 1-year period in a child infected with HIV.

Case Report

This patient was born to an 18-year-old mother after 35 weeks gestation by spontaneous vaginal delivery. Labor was complicated by hypertension which was treated with magnesium sulfate. The infant weighed

2,115 gm and Apgar scores were 9 at 1 and 5 min. The perinatal course was uncomplicated.

The infant presented at 5 months of age with failure-to-thrive and a diffuse, maculopapular rash. On physical examination he had hepatosplenomegaly, adenopathy, and oral thrush. Laboratory studies were remarkable for a total bilirubin of 5.0 mg/dl, direct bilirubin 3.9 mg/dl, aspartate aminotransferase (AST) 1,440 U/L, and alanine aminotransferase (ALT) 560 U/L. An HIV ELISA antibody with confirmatory western blot was positive in both the infant and mother and negative in the natural father. Maternal risk factor was a previous sexual contact with an intravenous drug user.

At 6 months of age, the infant presented with respiratory distress. *Pneumocystis carinii* pneumonia was confirmed by bronchio-alveolar lavage. He received a 14-day course of intravenous trimethoprim/sulfamethoxazole and was discharged on prophylactic treatment. He was readmitted for monthly intravenous infusions of gamma globulin.

At 11 months of age, developmental delay was observed. Cranial sonography revealed increased echogenicity in the periventricular white matter surrounded by areas of decreased echogenicity. Unenhanced computed tomography (CT) demonstrated areas of high attenuation bilaterally within the basal ganglia and in the subcortical white matter. These findings were consistent with calcifications (Fig 1). The third and lateral ventricles were minimally dilated.

At 14 months of age, he was begun on a study protocol consisting of oral zidovudine with monthly infusions of either gamma globulin or placebo. On neurologic evaluation he was believed to have an HIV encephalopathy characterized by pansycho-motor delay, microcephaly, and atonic diparesis.

At 15 months of age, he was readmitted with fever and severe respiratory distress which required intubation and mechanical ventila-

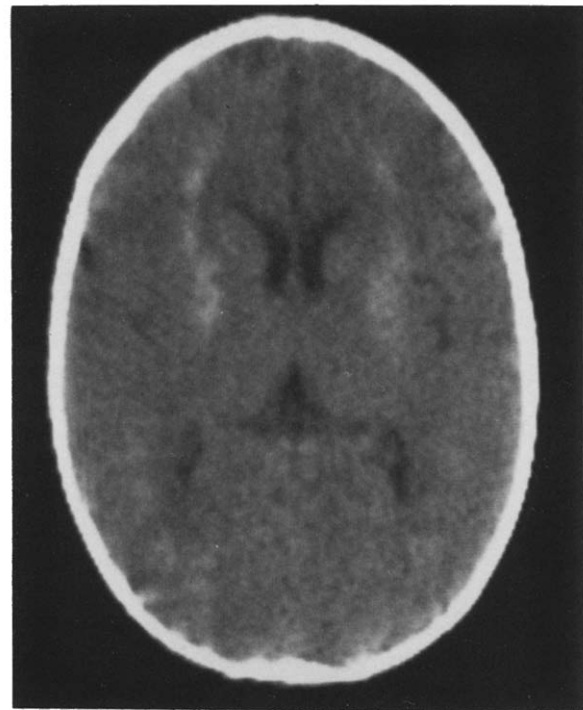


Figure 1. CT prior to stroke disclosing calcifications bilaterally within the basal ganglia and subcortical white matter.

From the Departments of *Pediatrics, †Neurology, ‡Radiology, and §Nuclear Medicine; Mount Sinai Hospital; Mount Sinai School of Medicine; New York, New York.

Communications should be addressed to:
Dr. Kugler; Neurological Institute; 710 West 168th Street, Room 2-251;
New York, NY 10032.
Received November 19, 1990; accepted January 28, 1991.

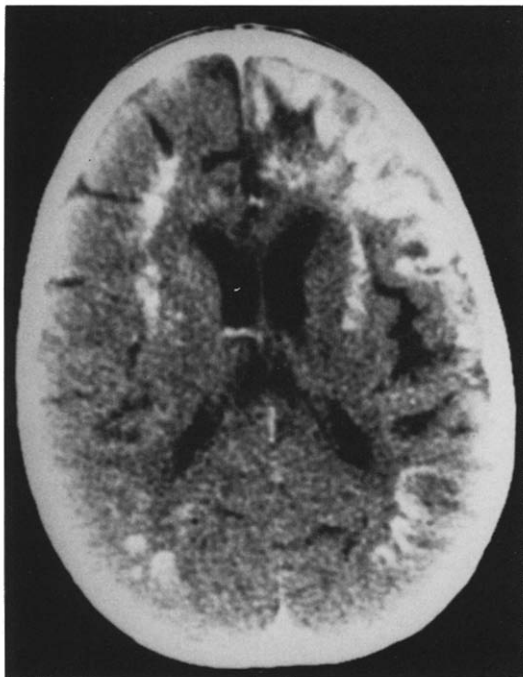


Figure 2. Enhanced CT demonstrated cortical gyral enhancement in the distribution of the left middle and anterior cerebral arteries.

tion. An open lung biopsy confirmed a second episode of *Pneumocystis carinii* pneumonia. The patient improved on therapy. One week after extubation he developed a right-sided hemiplegia which evolved over several hours. He was afebrile and his neck was supple. Head circumference was 42.0 cm (< 2 percentile) and the anterior fontanel was sunken. Funduscopic examination was normal. He had a flaccid right arm; strength in his right leg was graded as 2/5. Deep tendon reflexes were increased on the right and Babinski and Chaddock signs were elicited. A right hemisensory deficit to pinprick and a right hemianopia were present. Complete blood count included a leukocyte count of 8,700/mm³, hemoglobin 10.1 gm/dl, hematocrit 32.5%, and a platelet

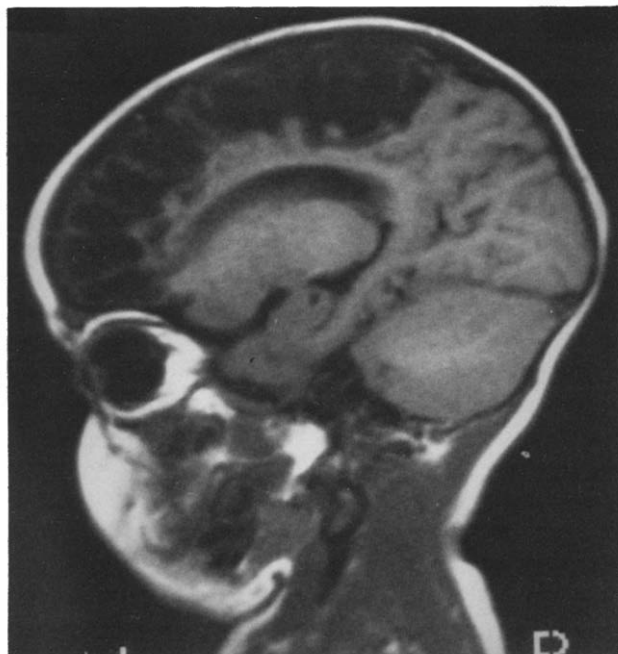


Figure 3. T₁-weighted MRI (TR 350 msec, TE 27 msec) revealed an extensive area of decreased signal in the left fronto-parietal lobes.

count of 641,000/mm³. Prothrombin time and partial thromboplastin time were normal.

After the detection of the acute hemiplegia, an unenhanced CT demonstrated a lucency in the left frontoparietal region superimposed on bilateral basal ganglia calcifications and generalized atrophy. An enhanced CT demonstrated cortical gyral enhancement in the distribution of the left middle and anterior cerebral arteries which was consistent with an infarct (Fig 2). Echocardiography and carotid Doppler studies were normal. Lumbar puncture yielded cerebrospinal fluid (CSF) containing 1 erythrocyte/mm³, 0 leukocytes, protein 14 mg/dl, and glucose 52 mg/dl. CSF HIV culture and p24 antigen determinations were negative.

Eight days after the infarct, electroencephalography (EEG) revealed slowing and decreased amplitude on the left side. A quantified EEG with topographical mapping confirmed this asymmetry.

The infant exhibited a gradual improvement in the right-sided weakness. At 8 weeks following the stroke, magnetic resonance imaging (MRI) on T₁-weighted images disclosed an extensive area of decreased signal in the left frontoparietal region (Fig 3). On T₂-weighted images this area manifested increased signal consistent with a prior infarct with marked parenchymal loss.

Three months after the acute hemiplegia a single photon emission computed tomography (SPECT) with technetium-99m-hexamethylpropylene amine oxime (^{99m}Tc-HMPAO) indicated a large region of absent uptake in the frontoparietal regions which correlated well with CT and MRI studies (Fig 4). A repeat ^{99m}Tc-HMPAO SPECT study 5 months following the infarct disclosed a large perfusion defect which was essentially unchanged from the previous study.

At 20 months of age, the child had a generalized tonic-clonic seizure. He had a fever of 38.0°C without meningeal signs. Spinal fluid contained 2 leukocytes/mm³ and protein 32 mg/dl. He had right-sided hypertonicity with strength graded at 2/5 in his arm and 4/5 in his leg. Phenytoin was administered. EEG documented no epileptiform activity. One year after the stroke, he is progressing in his developmental milestones with further acquisition of language and he ambulates with residual hemiparesis.

Discussion

In the latter part of the nineteenth century Osler, Sachs, and Freud described large series of infants afflicted with hemiplegia [13]. In 1927, Ford and Schaffer recognized that infections may produce vascular lesions which could result in acquired hemiplegia in children. With the advent of more advanced neuroradiologic techniques, acute hemiplegias in infants, once believed to be of obscure origin, are now more amenable to an etiologic diagnosis.

Recently, it has become apparent that adult-acquired immunodeficiency syndrome (AIDS) patients are at an increased risk for stroke. In a review of more than 1,600 adult patients with AIDS, Engstrom et al. identified 10 with cerebral infarction, 12 with acute onset of transient neurologic deficits (TNDs), and 2 with both [8]. Cerebral infarction or TND was the first clinical presentation of AIDS in 9 patients [8]. Mizusawa et al. reported evidence of cerebral infarcts in 24 of 83 autopsy cases of adult AIDS [7]. Most of these infarcts were small and were not clinically evident. Mural thickening of small blood vessels was observed in 12 (50%) of the infarct patients with only one patient manifesting a frank vasculitis and another with perivascular lymphocytic infiltration.

Table 1 summarizes reported patients with cerebrovascular lesions, including infarcts and hemorrhages in HIV-infected infants and children. Park et al. described clinical




Figure 4. SPECT with ^{99m}Tc-HMPAO disclosed absent uptake in the fronto-parietal regions.

and/or neurologic evidence of stroke in 4 of 65 patients followed longitudinally [12]. At autopsy, cerebrovascular disease was confirmed in 6 of 25 (25%) children. One child had an arteriopathy of the leptomeningeal arteries and in another reported patient the arteries of the circle of Willis were aneurysmally dilated. Two children had subacute necrotizing encephalomyelopathy and co-existing cardiomyopathy.

Our patient with HIV infection experienced an episode of acute hemiplegia and survived. Over the year since the acute event, his hemiplegia has progressively improved and his global HIV encephalopathy has remained static; therefore, stroke complicating HIV infection is not necessarily a terminal phase in the clinical course.

In our patient, we had no clinical or serologic evidence of an accompanying opportunistic infection, such as *Cyto-*

Table 1. Cerebrovascular lesions in pediatric AIDS

Reference	No. of Patients	Patient Age	Radiologic Findings	Pathology	Presumptive Etiology
Frank et al. [9]	1	4½ yrs	CT: hypodensities in basal ganglia and temporal lobe; angiography: segmental narrowing of anterior and middle cerebral arteries	Intimal fibrosis with thrombotic occlusion	<i>Herpes zoster</i> vasculitis, HIV
Mintz et al. [10]	2	NR	NR	NR	2 HIV
Cho et al. [11]	2	2, 7 yrs	NR	Intimal proliferation with narrowing of leptomeningeal arteries	2 HIV
Park et al. [12]	7	9 mos to 9 yrs	CT: hypodensities in 5 patients and a massive hemorrhage in 1	2 arteriopathy 2 subacute necrotizing encephalomyelopathy	4 HIV 1 <i>Herpes zoster</i> 1 lymphoma, ITP, HIV 1 ITP, HIV
Present patient	1	16 mos	Sonography, CT, MRI, SPECT abnormalities	Survived	HIV

Abbreviations:
HIV = Human immunodeficiency virus
ITP = Idiopathic thrombocytopenic purpura
NR = Not reported
SPECT = Single photon emission computed tomography

megalovirus (CMV), Herpes zoster, Aspergillus, or Toxoplasma that can induce vascular lesions. We believe that in our patient the cerebral infarct may be a direct intracranial sequela of the HIV infection. HIV has been demonstrated in vascular endothelial cells in brains of patients with AIDS [15,16] even in regions devoid of inflammatory cells. Although HIV has been directly implicated as the cause of cerebral angiitis [17], it has also been postulated that HIV-mediated toxins (e.g., cytokines) or antigen-antibody complexes may directly damage the vessel wall. In our patient, the CT even prior to acute hemiplegia, was remarkable for very extensive mineralization beyond the confines of the basal ganglia. These findings are highly suggestive of dystrophic calcifications occurring after a previous intimal injury. An HIV-associated vasculopathy could provide the substrate for an ensuing thrombosis. A cerebral embolus is unlikely because no infectious process was active during the infarct; furthermore, echocardiographic and Doppler studies were negative.

Pizzo et al. demonstrated improvement in neurodevelopmental abnormalities after 3-6 months of continuous zidovudine infusion [18]. Our patient had been on zidovudine 180 mg/m² every 6 hours for 3 months prior to the stroke and he has demonstrated a marked attenuation of the motor deficit with no further progression of the underlying encephalopathy. His clinical course was no different from that expected in stroke of other etiologies. The contribution of zidovudine to his recovery is unclear.

Our findings lead us to recommend that AIDS be included in the differential diagnosis of infants and children with acute hemiplegia; however, stroke in children with AIDS is not necessarily fatal or progressive.

This work was supported in part by grant #U01-AI-27554 from the National Institute of Allergy and Infectious Diseases.

References

[1] **Belman AL**, Diamond G, Dickson D, et al. Pediatric acquired immunodeficiency syndrome: Neurologic syndromes. *Am J Dis Child* 1988;142:29-35.

[2] **Epstein LG**, Sharer LR. Neurology of human immunodeficiency virus infection in children. In: Rosenblum ML, ed. *AIDS and the nervous system*. New York: Raven Press, 1988;79-101.

[3] **Falloon J**, Eddy J, Wiener L, Pizzo P. Human immunodeficiency virus infection in children. *J Pediatr* 1989;114:1-30.

[4] **Snider WD**, Simpson DM, Nielson S, Gold J, Metroka G, Posner J. Neurological complications of acquired immune deficiency syndrome: Analysis of 50 patients. *Ann Neurol* 1983;14:403-18.

[5] **Anders KH**, Guerra WF, Tomiyasu U, Verity MA, Vinters HV. The neuropathology of AIDS. UCLA experience and reviews. *Am J Med* 1986;124:537-58.

[6] **Budka H**, Costanzi G, Cristini S, et al. Brain pathology induced by infection with the human immunodeficiency virus (HIV). A histological, immunocytochemical and electron microscopical study of 100 autopsy cases. *Acta Neuropathol* 1987;75:185-98.

[7] **Mizusawa H**, Hirano A, Llena JF, Shintaku A. Cerebrovascular lesions in acquired immune deficiency syndrome (AIDS). *Acta Neuropathol* 1988;76:451-7.

[8] **Engstrom J**, Lowenstein DH, Bredesen D. Cerebral infarctions and transient neurological deficits associated with AIDS. *Am J Med* 1989;86:528-32.

[9] **Frank Y**, Lim W, Kahn E, Farmer P, Gorey M, Pahwa S. Multiple ischemic infarcts in a child with AIDS, varicella zoster infection, and cerebral vasculitis. *Pediatr Neurol* 1989;5:64-7.

[10] **Mintz M**, Epstein LG, Koenigsberger MR. Neurological manifestations of acquired immunodeficiency syndrome in children. *Int Pediatr* 1989;4:161-71.

[11] **Cho E-S**, Sharer LR, Peress NS, Little B. Intimal proliferation of leptomeningeal arteries and brain infarcts in subjects with AIDS. *J Neuropathol Exp Neurol* 1987;46:385.

[12] **Park YD**, Belman AL, Kim TS, et al. Stroke in pediatric acquired immune deficiency syndrome. *Ann Neurol* 1990;28:303-11.

[13] **Schoenberg BS**, Mellinger JF, Schoenberg DG. Cerebrovascular disease in infants and children: A study of incidence, clinical features and survival. *Neurology* 1978;28:763-7.

[14] **Ford FR**, Schaffer AJ. The etiology of infantile acquired hemiplegia. *AMA Arch Neurol Psychiatry* 1927;18:323-47.

[15] **Dickson D**, Belman A, Park Y, et al. Central nervous system pathology in pediatric AIDS: An autopsy study. *APMIS* 1989;(Suppl 8):40-57.

[16] **Wiley CA**, Schrier RD, Nelson JA, Lambert PW, Oldstone MB. Cellular localization of human immunodeficiency virus infection within the brains of acquired immune deficiency patients. *Proc Natl Acad Sci USA* 1986;83:7089-93.

[17] **Yanker BA**, Skolnik PR, Shoukimas GM. Cerebral granulomatous angiitis associated with isolation of human T-lymphotropic virus III from the nervous system. *Ann Neurol* 1986;20:362-4.

[18] **Pizzo PA**, Eddy J, Falloon J, et al. Effect of continuous intravenous infusion of zidovudine (AZT) in children with symptomatic HIV infection. *N Engl J Med* 1988;319:889-96.