

## Cerebral Infarction in a Patient with Macrothrombocytopenia with Leukocyte Inclusions (MTCP, May-Hegglin Anomaly/Sebastian Syndrome)

Yutaka Nishiyama<sup>1</sup>, Junko Akaishi<sup>2</sup>, Toshiya Katsumata<sup>1</sup>,  
Ken-ichiro Katsura<sup>1</sup> and Yasuo Katayama<sup>1</sup>

<sup>1</sup>Department of Neurological, Nephrological and Rheumatological Science, Graduate School of Medicine, Nippon Medical School

<sup>2</sup>Department of Biological Regulation and Regenerative Surgery, Graduate School of Medicine, Nippon Medical School

### Abstract

We report on a 78-year-old woman patient with macrothrombocytopenia with leukocyte inclusions (MTCP, May-Hegglin anomaly/Sebastian syndrome), who had no history of hemorrhagic symptoms and had a platelet count of 10,000 or less, but had a cerebral infarction. The patient was found to have idiopathic thrombocytopenic purpura, hypertension, and atrial fibrillation 16 years ago, yet received no medication. She was found to have had a cerebral infarction with aphasia as the chief complaint and was admitted to our hospital. Thrombocytopenia was found in three family members. Blood examinations revealed normal bleeding time and platelet aggregation ability. The patient was found to have the triad of giant platelets, thrombocytopenia, and inclusion bodies in leukocytes. Genetic analysis showed a mutation of the MYH-9 gene in the patient's second daughter. Consequently, this patient received a diagnosis of MTCP. There have only been a few reports of the onset of thrombosis in patients with MTCP and no reports of the onset of cerebral infarction. Our report is the first case of MTCP in a patient with cerebral infarction.

(J Nippon Med Sch 2008; 75: 228–232)

**Key words:** cerebral infarction, macrothrombocytopenia, May-Hegglin anomaly

### Introduction

Macrothrombocytopenia with leukocyte inclusions (MTCP) is a rare dominantly inherited thrombocytic abnormality that is characterized by the presence of three signs: giant platelets, thrombocytopenia, and inclusion bodies in leukocytes (Doehle-like bodies).

MTCP includes multiple syndromes, such as May-Hegglin anomaly and Sebastian syndrome. These two syndromes are differentiated by differences in the micromorphologic features of the inclusion bodies within leukocytes<sup>1</sup>. Additionally, Fetcher syndrome, which is complicated by Alport symptoms, is also present<sup>1,2</sup>. Recently, Kunishima et al. have reported that a mutation of the nonmuscle

---

Correspondence to Yutaka Nishiyama, Department of Internal Medicine (Division of Neurology, Nephrology, and Rheumatology), Nippon Medical School, 1-1-5 Sendagi Bunkyo-ku, Tokyo 113-8603, Japan

E-mail: yutakanms@yahoo.co.jp

Journal Website (<http://www.nms.ac.jp/jnms/>)

myosin chain A (NMHHCA, MYH-9) gene induces MTCP<sup>3</sup>. There have thus far been no reports of cerebral infarction in patients with MTCP. The patient we now report on had clinical features of MTCP, without symptoms or examination findings indicative of idiopathic thrombocytopenic purpura or antiphospholipid antibody syndrome. Thus, this case is, to our knowledge, the first reported case of cerebral infarction in a patient with MTCP.

**Case**

The patient was a 78-year-old Japanese woman

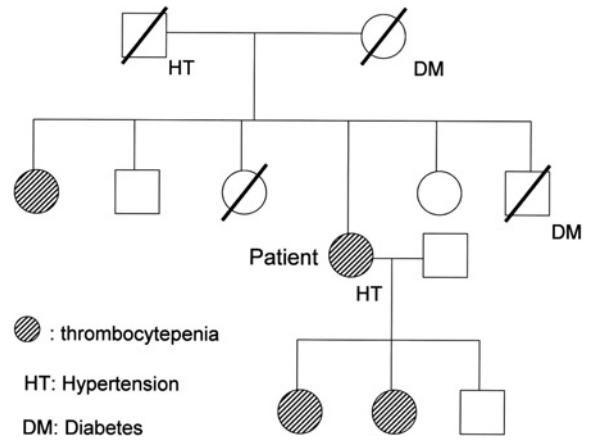


Fig. 1 Pedigree of the patient's family

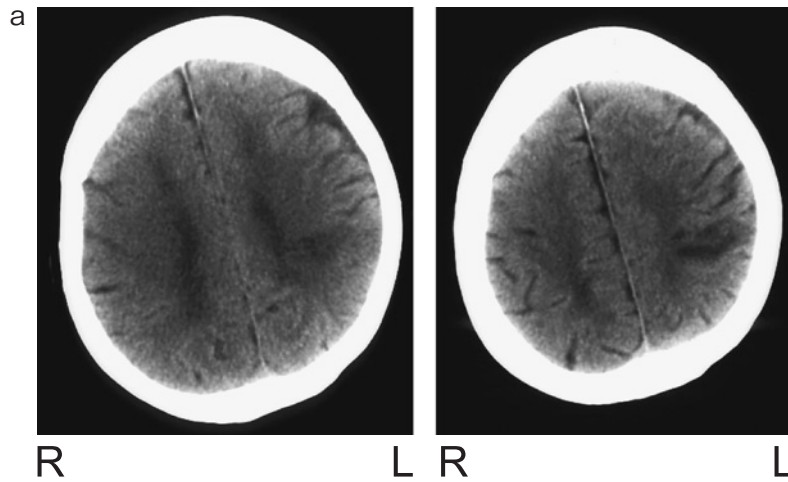


Fig. 2a Computed tomography of the brain on the first hospital day: Cerebral infarction was identified in the left angular gyrus.

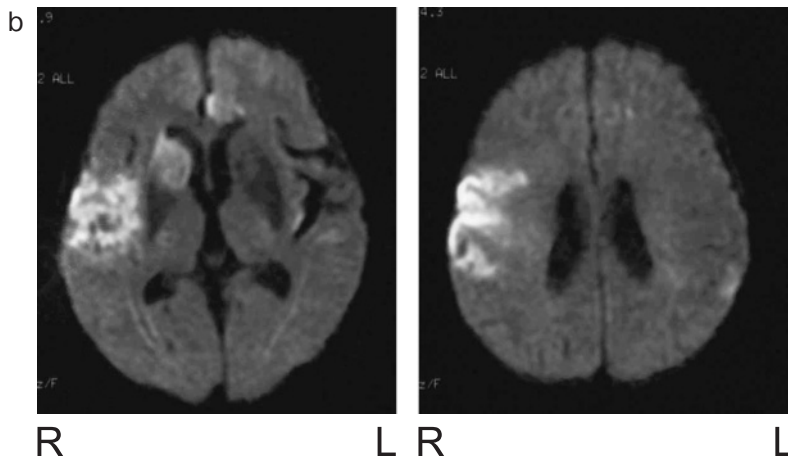


Fig. 2b Magnetic resonance of the brain on the eighth hospital day (diffusion-weighted image): New infarct lesions were identified in the right caudate nucleus, the right temporal/parietal lobe, and the left frontal lobe.

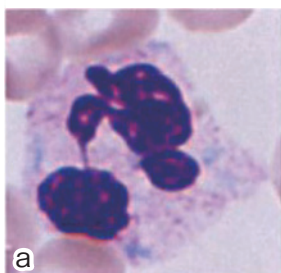
Table 1 Laboratory data of the patient

|                                       |   |                                      |            |
|---------------------------------------|---|--------------------------------------|------------|
| White blood cells                     | 6,200/ $\mu$ L (seg 68.0 neu 0.0 eo 1.5 baso 0.0 mono 1.5 lymph 29.0) |                                      |            |
| Red blood cells                       | 379 $\times$ 10 <sup>4</sup> / $\mu$ L                                |                                      |            |
| Hemoglobin                            | 11.2 g/dL   |                                      |            |
| Hematocrit                            | 35.0%   |                                      |            |
| Platelets                             | 1.0 $\times$ 10 <sup>4</sup> / $\mu$ L (giant platelets ( + ) )       |                                      |            |
| Prothrombin time                      | 12.4 s (international normalized ratio 1.04)                          | Bleeding time                        | 4 min 30 s |
| Activated partial thromboplastin time | 24.5 s  |                                      |            |
| Fibrinogen                            | 314 mg/dL   | Platelet aggregation rate            |            |
| Hepaplastin test                      | 117.3%  | ADP (2.0 $\mu$ M)                    | 54%        |
| Antithrombin III                      | 96.6%   | Collagen (2.0 $\mu$ g/mL)            | 80%        |
| Thrombin-antithrombin III complex     | 13.3 $\mu$ g/L  |                                      |            |
| Plasmin inhibitor complex             | 1.0 $\mu$ g/mL  | $\beta$ -thromboglobulin             | 26 ng/mL   |
| D-dimer                               | 1.0 $\mu$ g/mL  | Platelet factor-4                    | 4 ng/mL    |
| Fibrin degradation product            | 5.9 $\mu$ g/mL  |                                      |            |
| Lupus erythematosus cell test         | negative  | Platelet-associated immunoglobulin G |            |
| Anticardiolipin antibody              | <1.3 U/mL   | 380.0 ng/10 <sup>7</sup> cells       |            |
| Protein C activity                    | 68%   |                                      |            |
| Protein S activity                    | 65%   |                                      |            |

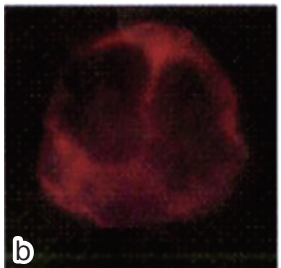
who had a cerebral infarction. At the age of 62, she was found to have idiopathic thrombocytopenic purpura, hypertension, and atrial fibrillation. She had no history of any medication or bleeding. In October 200X, the patient consulted our hospital with a chief complaint of aphasia. She was found to have had a cerebral infarction and was admitted. Upon admission, neurological examination revealed typical conduction aphasia and mild right hemiparesis. No notable physiological findings were present. The patient's family history included thrombocytopenia in a younger sister and two daughters (**Fig. 1**). Hematologic examinations showed thrombocytopenia with a thrombocyte count of 10,000 / $\mu$ L. Computed tomography showed an infarct lesion at the left angular gyrus (**Fig. 2a**). Transthoracic echocardiography showed no intracardiac thrombus or valvular disease. Carotid ultrasonography showed mild bilateral atherosclerotic changes of the carotid arteries. After admission, treatment with concentrated glycerin-fructose (400 mL per day) and edaravone (60 mg per day) was performed. However, impaired consciousness and left hemiplegia appeared on the eighth hospital day, and magnetic resonance of the head revealed new infarct lesions in the right

caudate nucleus, the right temporal/parietal lobe, and the left frontal lobe (**Fig. 2b**). Although no antiphospholipid antibodies or LE cells were found, the titre of platelet-associated IgG (PAIgG) was increased. The bleeding time and platelet aggregation ability were within their normal ranges. Levels of fibrinolytic factors, such as protein S, protein C, and antithrombin III, were within their normal ranges (**Table 1**). Blood smears showed the presence of giant platelets. The findings of the normal bleeding time and the family history of thrombocytopenia suggested the presence of MTCP. To analyze the localization of abnormal NMMHCA protein in platelets and leukocytes, immunofluorescence staining with an anti-NMMHCA antibody was performed with peripheral blood smear specimens. Although the entire cytoplasm of normal control leukocytes was diffusely stained, the inclusion bodies in granulocytes appeared as stained granules (**Fig. 3**). The patient could not give consent for genetic analyses because of aphasia, but after informed consent was obtained from the patient's second daughter, the genetic analyses were performed. A point mutation was detected, and an MYH9 gene abnormality (1,165th arginine was

## NMS 167



control



NMS 163

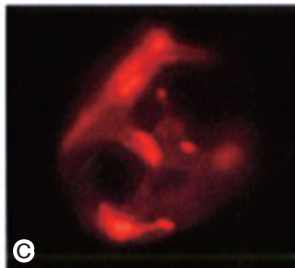


Fig. 3 Blood smear specimens of the patient and the control: (a) A neutrophil of the patient, Wright-Giemsa staining,  $\times 1,000$ . Inclusion bodies in the neutrophil were stained blue. (b) Normal control leukocyte, immunofluorescence staining with an anti-NMMHCA antibody,  $\times 1,000$ . The entire cytoplasm of the neutrophil was diffusely stained. (c) A neutrophil of the patient, fluorescence staining with an anti-NMMHCA antibody,  $\times 1,000$ . Inclusion bodies appeared as stained granules.

changed to cysteine at exon 26) was thus proved. The patient was fed via a tube and was treated with an antihypertensive agent. During hospitalization, neither antithrombotic drugs nor warfarin potassium was administered. On March 200X, the patient was moved to a sanatorium.

### Discussion

MTCP is a rare genetic disease with thrombocytopenia and is associated with NMMHCA gene mutations. Recently, to investigate the localization of NMMHCA in leukocytes, analyses using immunofluorescence staining have been performed<sup>4</sup>. In this case, NMMHCA appeared as stained granules in leukocytes, a staining pattern that differs from that in normal leukocytes. This finding, suggested by Kunishima et al<sup>4</sup>, indicates that

abnormal localization of NMMHCA might be associated with the formation of neutrophilic inclusion bodies. The results of immunofluorescence staining may support the diagnosis of MTCP in our patient.

Many patients with MTCP have no symptoms or exhibit a mild bleeding tendency, depending on the platelet count. Platelet function is normal, the bleeding time is not markedly prolonged, and markers reflecting platelet function, such as  $\beta$ -thromboglobulin and platelet factor-4 are within the normal ranges<sup>5</sup>. In our patient, bleeding symptoms did not appear and platelet dysfunction or prolonged bleeding time was not observed. The characteristics of this case closely resemble those in previous reports.

This case is unusual because cerebral infarction occurred in the setting of thrombocytopenia. As factors inducing thrombosis in thrombocytopenia, the presence of thrombotic thrombocytopenic purpura or antiphospholipid antibody syndrome has been identified. It has been reported that cerebral infarction occurs in 9% to 15% of patients with antiphospholipid antibody syndrome<sup>6,7</sup>. For such patients, an antithrombotic agent (aspirin) or anticoagulant (warfarin potassium) is usually administered to prevent thrombosis. However, because the presence of risk factors of thrombosis, such as the platelet count, bleeding tendency, and atrial fibrillation, differs from patient to patient, a standard treatment to prevent thrombosis in patients with thrombocytopenia has not been established<sup>8</sup>. There were no findings to suggest thrombotic thrombocytopenic purpura or antiphospholipid antibody syndrome in the present case.

Although there have been no reports of cerebral infarction in patients with MTCP, McDunn et al. have reported coronary arterial thrombosis in a 62-year-old woman<sup>9</sup>. Findings in this case were a platelet count of 24,000  $/\mu\text{L}$ , normal platelet function and aggregation ability, and no history of bleeding symptoms. McDunn et al. have suggested that patients with MTCP might have a thrombotic tendency because of the size of platelets rather than the platelet count. In a report on a patient with

MTCP having acute myocardial infarction, Goto et al. have concluded that in MTCP, the platelet count is so low that the size of platelets increases as a compensatory mechanism in view of a von Willebrand factor dependent platelet formation occurring under the effect of blood flow and that that is why a bleeding tendency is absent despite the low platelet count in many patients with MTCP<sup>10</sup>. In our patient, although no complications, such as bleeding symptoms and platelet dysfunction, were found, with a history of hypertension and the presence of atrial fibrillation acting as mechanisms of cerebral infarction, a cardiogenic embolism is possible. However, no cardiac thrombus was found with transthoracic ultrasonography. No clear abnormalities of coagulation were found. Therefore, we could not confirm the main cause of the cerebral embolism in this patient with thrombocytopenia. A standard treatment for thrombosis in MTCP has not been established. However, because patients can have cerebral infarction, as in the present case, it is necessary to find the best medical strategy by accumulating data from such cases in the future.

### References

1. Greinacher A, Mueller-Eckhardt C: Hereditary types of thrombocytopenia with giant platelets and inclusion bodies in the leukocytes. *Blut* 1990; 60: 53-60.
2. Peterson LC, Rao KV, Crosson JT, et al: Fletcher syndrome-A variant of Alport's syndrome with leukocyte inclusions and macrothrombocytopenia. *Blood* 1985; 65: 397-400.
3. Kunishima S, Kojima T, Matsushita T, et al: Mutations in the NMMHC-A gene cause autosomal dominant macrothrombocytopenia with leukocyte inclusions ( May-Hegglin anomaly / Sebastian syndrome). *Blood* 2001; 97: 1147-1149.
4. Kunishima S, Matsushita T, Kojima T, et al: Immunofluorescence analysis of neutrophil nonmuscle myosin heavy chain-A in MYH-9 disorders: Association of subcellar localization with MYH-9 mutations. *Lab Invest* 2003; 83: 115-122.
5. Coller BS, Zarrabi MH: Platelet membrane studies in the May-Hegglin anomaly. *Blood* 1981; 5: 279-284.
6. The Antiphospholipid Antibodies in Stroke study (APASS) Group: Anticardiolipin antibodies are an dependent risk factor for first ischemic stroke. *Neurology* 1993; 43: 2069-2073.
7. Tuhim S, Rando DH, Wu XX, et al: Elevated anticardiolipin antibody titer is a stroke risk factor in multiethnic population independent of isotype or degree of positivity. *Stroke* 1999; 30: 1561-1565.
8. Lim W, Crowther MA, Eikelboom JW: Management of antiphospholipid antibody syndrome. *JAMA* 2006; 295: 1050-1057.
9. McDunn S, Hartz W, Tsao C, et al: Coronary thrombosis in a patient with May-Hegglin anomaly. *Am J Clin Pathol* 1991; 95: 715-718.
10. Goto S, Kasahara H, Sakai H, et al: Functional compensation of the low platelet count by increased individual platelet size in a patient with May-Hegglin anomaly presenting with acute infarction. *Int J Cardiol* 1998; 64: 171-177.

(Received, March 10, 2008)

(Accepted, April 18, 2008)