

## NOTE

# DISTURBANCES OF CROSS-LOCALIZATION OF FINGERTIPS IN A CALLOSAL PATIENT

Kazuo Satomi<sup>1</sup>, Yoshitoshi Kinoshita<sup>2</sup> and Senri Hirakawa<sup>1</sup>

(<sup>1</sup>Second Department of Internal Medicine and <sup>2</sup>Department of Laboratory Medicine, Clinical Psychology, Gifu University School of Medicine)

## INTRODUCTION

A test of cross-localization of fingertips (CLF) is usually performed as follows: the patient with his eyes closed, hands extended and palms up is touched on a finger of one hand and asked to touch the corresponding finger of the other hand with the thumb of that hand. CLF disturbance, i.e., the inability to perform this task in both directions (right-to-left and vice versa), has been reported in patients with callosal lesions (Balaceanu et al., 1970; Jeeves, Simpson and Geffen, 1979; Leiguarda, Starkstein and Berthier, 1989; Sperry, Gazzaniga and Bogen, 1969; Volpe et al., 1982). The fact that the disorder is bi-directional, that the localization is normal when carried out with the same hand that is stimulated and that the test is nonverbal (Bogen, 1979, 1985) suggests that the disturbance is due to callosal disconnection between the somesthetic centers of the two hemispheres.

However, patients with callosal lesions often show left unilateral apraxia (Brion and Jedynak, 1972; Gazzaniga, Bogen and Sperry, 1967; Geschwind and Kaplan, 1962; Graff-Radford, Welsh and Godersky, 1987; Iwata et al., 1980; Liepmann and Maas, 1907; Volpe et al., 1982; Watson and Heilman, 1983; Zaidel and Sperry, 1977) and/or left side tactile anomia of body parts (Barbizet et al., 1974; Degos et al., 1987; Geschwind and Kaplan, 1962; Geschwind, 1965; Goldenberg et al., 1985; Watson and Heilman, 1983). In such a case, it is possible that CLF errors in left-to-right direction are due to left side tactile anomia, because the left hemisphere misnames the touched finger of the left hand and CLF errors in right-to-left direction are due to left unilateral apraxia, which impairs the left hand ability to indicate the target finger. If as predicted by the somesthetic transfer deficit hypothesis, the crucial information is that concerning the stimulated hand, the CLF performance should be disturbed when the patient does not see this hand, but should be unaffected by excluding from vision the responding hand. We now report a patient with CLF disturbance, left unilateral apraxia and left tactile finger anomia caused by callosal lesions, in whom we tested the somesthetic transfer deficit hypothesis.

## CASE REPORT

On November 19, 1982, a 64-year-old right-handed male, without any history of previous illness, suddenly developed a speech arrest followed by inability to stand and drowsiness. Four days after onset, he showed right hemiparesis, while spontaneous speech, repetition and comprehension of simple verbal commands were good. A computed tomography, performed one month after onset, disclosed a low density area in the left medial frontal lobe and the anterior two-thirds of the corpus callosum corresponding to the region irrigated by the left anterior cerebral artery (Figure 1A). Although his right hemiparesis recovered, he consulted Gifu University Hospital on November 7, 1983, because his language was halting and his right hand trembled when excited.

Neurological examination, carried out about one year after onset, revealed a patient who was alert, co-operative and oriented in all spheres. There was no impairment of spontaneous speech, comprehension and repetition. He has no limb or facial weakness. The right limbs

were mildly spastic and the deep tendon reflexes of the right leg were brisk, although Babinski sign was not noted. He showed mild right hemiparetic gait. Grasping reflex was not noted. There was no abnormality of cutaneous or deep sensation regarding touch, pain, temperature, vibration and position sense. His visual fields were apparently normal.

Neuropsychological examination failed to reveal aphasia, agnosia or other deficits except those due to the disconnection syndrome, i.e., left unilateral apraxia, left tactile finger anomia, left unilateral agraphia, cross-replication deficit of hand postures, and cross-localization deficit of fingertips. Praxis of the left hand was tested on verbal command, imitation and object use. With eyes open, the patient could not carry out gestures on verbal command or on imitation. Object use with the left hand was mildly impaired with eyes open, and much more impaired with eyes closed. The W.A.I.S. test, performed on February 2, 1984, showed a verbal I.Q. of 97, a performance I.Q. of 70 and a total I.Q. of 87. M.R.I., performed on October 24, 1985, demonstrated a low signal area involving the anterior five-sixths of the corpus callosum and the left medial frontal lobe (Figure 1B).

#### MATERIALS AND METHODS

The patient was given the following set of finger identification tests.

(1) Tactile-manual test: a routine procedure for CLF with eyes closed has already been mentioned. CLF with eyes open was performed in two ways; either the stimulated hand was covered by a thick cloth and the patient was asked to look at his responding hand, or the responding hand was covered by the cloth and the patient was asked to look at his stimulated hand. Ipsilateral localization of fingertips with eyes close requires the examiner to touch a finger of one hand of the patient with eyes closed for him to indicate the stimulated finger with the thumb of the same hand.

(2) Tactile-verbal test: the patient with eyes closed was requested to name the finger of his hand touched by the examiner.

(3) Verbal-manual test: the patient with eyes closed indicated with the thumb of the same hand the finger named by the examiner.

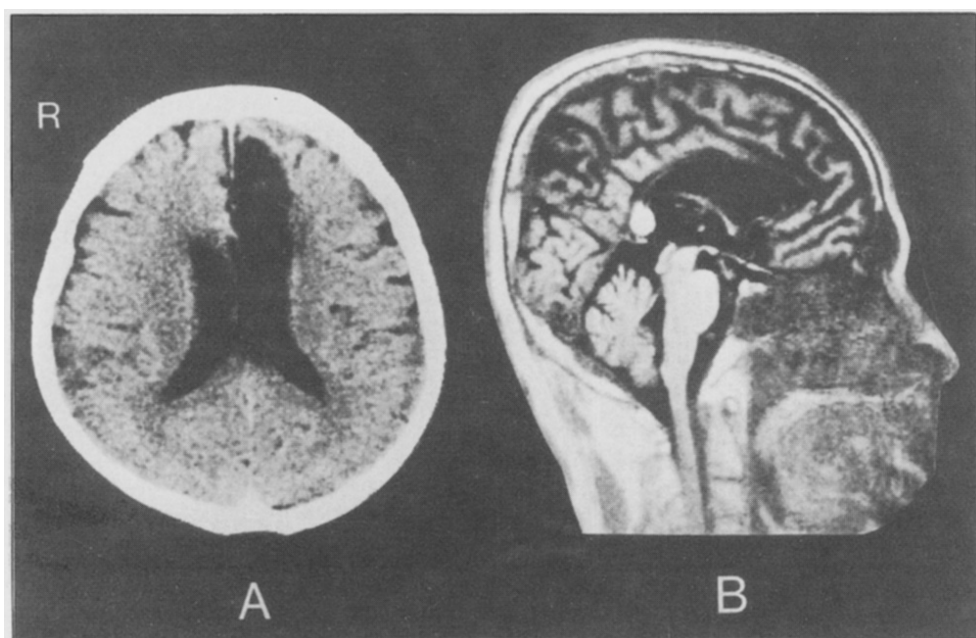


Fig. 1 - A: CT scan showing a low density area of the left medial frontal lobe. B: Magnetic resonance imaging showing a low signal area of the anterior five-sixths of the corpus callosum.

TABLE I  
Test Results

Test items		Correct response rate (percentage)	
(1) Tactile-manual test			
Eyes closed	Ipsilateral localization	R-R 83/84 (99%) L-L 77/68 (88%)	
	Cross-localization	L-R 61/128 (48%) R-L 82/128 (64%)	
	Eyes open	Cross-localization with stimulated hand invisible to the patient	L-R 26/56 (46%) R-L 50/52 (96%)
Cross-localization with responding hand invisible to the patient		L-R 56/56 (100%) R-L 41/56 (73%)	
(2) Tactile-verbal test	R-V 52/55 (95%) L-V 44/71 (62%)		
(3) Verbal-manual test	V-R 83/84 (99%) V-L 65/88 (74%)		
(4) Visual-manual test	Vi-R 93/96 (97%) Vi-L 79/100 (79%)		
(5) Verbal-visual test	V-R 30/30 (100%) V-L 30/30 (100%)		
(6) Visual-verbal test	30/30 (100%)		
(7) Manipulation of objects	with eyes open	Right hand	NE
		Left hand	16/19 (84%)
	with eyes closed	Right hand	20/20 (100%)
		Left hand	19/35 (54%)

R-R (L-L): right-right (or left-left) hand stimulation and response.  
 L-R (R-L): left (right) hand stimulation and right (left) hand response.  
 V-R (V-L): verbal stimulation and right (left) hand response.  
 Vi-R (Vi-L): visual stimulation and right (left) hand response.  
 R-V (L-V): right (left) hand stimulation and verbal response.  
 NE: not examined.

(4) Visual-manual test: the examiner showed one of his finger to the patient for him to point to the corresponding finger of his hand with the thumb of the same hand while this was covered by a cloth.

(5) Verbal-visual test: the patient with eyes open pointed with his right or left index finger to the finger of the examiner's hand that had been named by the examiner.

(6) Visual-verbal test: the patient had his eyes open and named a finger displayed by the examiner.

(7) Manipulation of objects: the patient manipulated familiar objects with his eyes closed or open.

Statistical calculation: a fourfold chi square test after Yates' correction or Fisher's exact test (two-sided probability) was used when two tests were compared.

RESULTS

Table I shows the scores achieved by the patient on the various tests.

Ipsilateral localization of fingertips with eyes closed was almost perfect (right-to-right 99% correct, left-to-left 88% correct). CLF with eyes closed was impaired in both directions (left-to-right 48% correct, right-to-left 64% correct), but the score in the left-to-right direction was significantly lower than that in the right-to-left direction ( $p < 0.05$ ). With eyes open, the right-to-left performance was disturbed when the responding (left) hand was kept out of sight (eyes clo-

sed vs. open: 64% and 73% correct, respectively), whereas it improved when it could be viewed and it was the touched (right) hand to be kept out of sight (eyes closed vs. open: 64% and 96% correct, respectively,  $p < 0.01$ ). The left-to-right performance with eyes open, contrariwise, ameliorated when the responding (right) hand was invisible to him (eyes closed vs. open: 48% and 100% correct, respectively), and it did not improve when the stimulated (left) hand was invisible to him (eyes closed vs. open: 48% and 46% correct, respectively).

Tactile finger naming was impaired in the left hand (right hand 95% correct, left hand 62% correct,  $p < 0.01$ ). Left hand response in verbal-manual and visual-manual tests was impaired (right hand vs. left hand: 99%, 74% correct,  $p < 0.01$ , in the former test and 97%, 79% correct,  $p < 0.01$ , in the latter test). Verbal-visual and visual-verbal tests were perfect.

Left hand manipulation of objects was mildly impaired (84% correct) with eyes open, and much more impaired with eyes closed (54% correct),  $p < 0.05$ .

## DISCUSSION

If cross-localization of fingertips (CLF) disturbance is caused by a deficit in the interhemispheric transfer of somesthetic information, the test scores should improve in both directions, when the test is performed with eyes open and the patient looks at his touched hand, since both hemispheres receive the visual information. On the other hand, no improvement is anticipated when the patient regards his responding hand as long as his touched hand is invisible to him. Moreover, there should not exist a significant score difference between the right-to-left and left-to-right directions of CLF with eyes closed, because the disturbance is not dependent on hemispheric dominance (Leiguarda et al., 1989), but, rather, on a transfer deficit between the two hemispheres. Yet with eyes closed, our patient showed significantly lower score in the left-to-right direction than in the right-to-left direction ( $p < 0.05$ ). With eyes open, the right-to-left direction score did not improve when he regarded his touched hand, but it did improve when he regarded his responding hand. On the contrary, the left-to-right direction score did not improve when he regarded his responding hand, but it improved when he regarded his stimulated hand. Therefore, the CLF disturbance of our patient can not be explained by a deficit in the interhemispheric transfer of somesthetic information, but can be explained by two independent mechanisms, one for the right-to-left and the other for the left-to-right direction.

Disturbance of right-to-left direction with eyes closed appeared to be due to a motor output deficit, because it improved when the test was performed with eyes open and the patient regarded his left hand. This type of visually guided improvement in left hand movement has also been reported in a test of object manipulation (Satomi and Goto, 1985).

Even when nonverbal stimulation and response modes were used in CLF (touching a finger and manual response), it is dubious to what extent the information processing was really nonverbal, because each finger has its own name (Stone and Robinson, 1968). Left side tactile anomia of body parts has been repeatedly reported in patients with callosal lesions, and left tactile finger anomia was indeed observed in our patient. Since the somesthetic transfer deficit hypothesis could not adequately explain the left-to-right CLF disturbance with eyes closed, we hypothesize that it was caused by left tactile finger anomia.

A possible explanation for the different performance in the two directions (left-to-right 48% correct, right-to-left 64% correct) was that his left tactile finger anomia was severer than his left unilateral apraxia, as suggested by the lower percent correct in tactile finger naming test (62%) than in verbal-manual test (74%) and visual-manual test (79%).

In conclusion, our patient's study suggests that when examining somesthetic transfer in patients with callosal lesions, cross-localization of fingertips should always be performed with eyes open and with eyes closed.

## ABSTRACT

If defective cross-localization of fingertips (CLF) in callosal patients is due to a deficit in the interhemispheric transfer of somesthetic information, when the patient's eyes are open, CLF should be affected when the stimulated hand is excluded from vision, not when the responding hand is excluded from vision. In order to investigate this hypothesis, a patient

with a callosal lesion was subjected to CLF with eyes closed and open. With eyes closed, the CLF score in the left-to-right direction was significantly lower than that in the right-to-left direction. With eyes open, the CLF performance in the right-to-left direction was impaired when it was the responding hand to be excluded from vision, not when it was the stimulated hand to be excluded from vision. It would, therefore, appear that the patient's CLF disturbance was not due to a somesthetic transfer deficit, but to left unilateral apraxia for the right-to-left direction errors and to left tactile finger anomia for the left-to-right direction errors.

*Acknowledgments.* We wish to thank Professor P. Rondot, MD, Paris, who provided us with helpful comment and discussion.

## REFERENCES

- BALACEANU, C., GHEORGHIU, M., LUPU, A., and GHEORGHITA, N. Syndrome de dysconnexion interhémisphérique dans un cas de thrombose du tronc artériel brachio-céphalique. *Revue Neurologique (Paris)*, 123: 44-48, 1970.
- BARBIZET, J., DEGOS, J.D., DUILZABO, P., and CHARTIER, B. Syndrome de déconnexion interhémisphérique d'origine ischémique. *Revue Neurologique (Paris)*, 130: 127-141, 1974.
- BOGEN, J.E. The callosal syndrome. In K.M. Heilman and E. Valenstein (Eds.), *Clinical Neuropsychology*. New York/Oxford: Oxford University Press, 1979, ch. 11, pp. 308-359.
- BOGEN, J.E. Split-brain syndromes. In P.J. Vinken, G.W. Bruyn and H.L. Klawans (Eds.), *Handbook of Clinical Neurology, Vol. 45, Clinical Neuropsychology*. Amsterdam: Elsevier Science Publishers, 1985, ch. 8, pp. 99-106.
- BRION, S., and JEDYNAK, C.P. Troubles du transfert interhémisphérique (callosal disconnection). A propos de trois observations de tumeurs du corps calleux. Le signe de la main étrangère. *Revue Neurologique (Paris)*, 126: 257-266, 1972.
- DEGOS, J.D., GRAY, F., LOUARN, F., ANSQUER, J.C., POIRIER, J., and BARBIZET, J. Posterior callosal infarction. Clinicopathological correlations. *Brain*, 110: 1155-1171, 1987.
- GAZZANIGA, M.S., BOGEN, J.E., and SPERRY, R.W. Dyspraxia following division of the cerebral commissures. *Archives of Neurology*, 16: 606-612, 1967.
- GESCHWIND, N. Disconnection syndromes in animals and man. *Brain*, 88: 237-294, 585-644, 1965.
- GESCHWIND, N., and KAPLAN, E. A human cerebral deconnection syndrome. A preliminary report. *Neurology*, 12: 675-685, 1962.
- GOLDENBERG, G., WIMMER, A., HOLZNER, F., and WESSELY, P. Apraxia of the left limbs in a case of callosal disconnection: The contribution of medial frontal lobe damage. *Cortex*, 21: 135-148, 1985.
- GRAFF-RADFORD, N.R., WELSH, K., and GODERSKY, J. Callosal apraxia. *Neurology*, 37: 100-105, 1987.
- IWATA, M., SUGISHITA, M., YOSHIDA, S., and TOYOKURA, Y. Left unilateral ideomotor apraxia due to the lesion in the posterior half of the corpus callosum. *Clinical Neurology (Tokyo)*, 20: 721-726, 1980.
- JEEVES, M.A., SIMPSON, D.A., and GEFFEN, G. Functional consequences of the transcallosal removal of intraventricular tumors. *Journal of Neurology, Neurosurgery, and Psychiatry*, 42: 134-142, 1979.
- LEIGUARDA, R., STARKSTEIN, S., and BERTHIER, M. Anterior callosal haemorrhage. A partial interhemispheric disconnection syndrome. *Brain*, 112: 1019-1037, 1989.
- LIEPMANN, H., and MAAS, O. Fall von linksseitiger Agraphie und Apraxie bei rechtsseitiger Lahmung. *Journal für Psychologie und Neurologie (Leipzig)*, 10: 214-227, 1907.
- SATOMI, K., and GOTO, K. A case of callosal apraxia after left anterior cerebral artery occlusion. *Clinical Neurology (Tokyo)*, 25: 443-447, 1985.
- SPERRY, R.W., GAZZANIGA, M.S., and BOGEN, J.E. Interhemispheric relationships: The neocortical commissures; syndromes of hemisphere disconnection. In P.J. Vinken and G.W. Bruyn (Eds.), *Handbook of Clinical Neurology, Vol. 4, Disorders of Speech, Perception and Symbolic Behavior*. Amsterdam: North-Holland Publishing Co, 1969, ch. 14, pp. 273-290.
- STONE, F.B., and ROBINSON, D.L. The effect of response mode on finger localization errors. *Cortex*, 4: 233-244, 1968.
- VOLPE, B.T., SIDTIS, J.J., HOLTZMAN, J.D., WILSON, D.H., and GAZZANIGA, M.S. Cortical mechanisms involved in praxis: Observations following partial and complete section of the corpus callosum in man. *Neurology*, 32: 645-650, 1982.
- WATSON, R.T., and HEILMAN, K.M. Callosal apraxia. *Brain*, 106: 391-403, 1983.
- ZAIDEL, D., and SPERRY, R.W. Some long-term motor effects of cerebral commissurotomy in man. *Neuropsychologia*, 15: 193-204, 1977.