



Središnja medicinska knjižnica

Habek, M., Šupe, S., Poljaković, Z., Gelpi, E., Alesch, F., Ozretić, D., Brinar, Vesna V. (2008) *Subacute brainstem angioencephalopathy: Favorable outcome with anticoagulation therapy*. Journal of the Neurological Sciences, [Epub ahead of print, Corrected Proof].

<http://www.elsevier.com/locate/issn/0022-510X>

<http://dx.doi.org/10.1016/j.jns.2008.07.036>

<http://medlib.mef.hr/418>

University of Zagreb Medical School Repository

<http://medlib.mef.hr/>

Subacute brainstem angioencephalopathy: favorable outcome with anticoagulation therapy

Mario Habek¹, Svjetlana Šupe¹, Zdravka Poljaković¹, Ellen Gelpi², François Alesch³, David Ozretić⁴, Vesna V. Brinar¹

From the: From the:

¹University Department of Neurology and ⁴Radiology, Zagreb School of Medicine and University Hospital Center, Zagreb, Croatia

²Institute of Neurology and ³Department of Neurosurgery, Medical University of Vienna, Austria

Corresponding author:

Mario Habek, MD

University Department of Neurology

Zagreb School of Medicine and University Hospital Center

Kišpatićeva 12

HR-10000 Zagreb

Croatia

Phone: +38598883323; Fax: +38512421891; e-mail: mhabek@mef.hr

Word count: 1230 (including references and figures)

Key words: subacute brainstem angioencephalopathy, anticoagulation, therapy

Authors' contributions

Study concept and design: Habek, Šupe, Poljaković, Gelpi and Brinar. Acquisition of data: Habek, Šupe, Poljaković, Gelpi, Alesch, Ozretić and Brinar. Analysis and interpretation of data: Habek, Šupe, Poljaković, Gelpi, Alesch, Ozretić and Brinar. Drafting of the manuscript: Habek and Gelpi. Critical revision of the manuscript for important intellectual content: Habek, Šupe, Poljaković, Gelpi, Alesch, Ozretić and Brinar. Administrative, technical, and material support: Habek, Gelpi, Alesch and Ozretić.

Conflict of interest statement: There is no conflict of interest.

Abstract

We present a patient who developed progressive neurological disease caused by lesions histologically compatible with those observed in subacute brainstem angioencephalopathy. The patient was treated with low-molecular weight heparin, and treatment response was monitored clinically and with MRI. Anticoagulation therapy stopped progression of the neurological deficit and led to improvement of MRI findings. This report further supports the existence of subacute brainstem angioencephalopathy as a characteristic disease entity and gives insight into possible therapeutic approach with anticoagulation treatment.

Introduction

Subacute diencephalic or brainstem angioencephalopathy is a rare clinical entity with progressive course, and usually leads to death within few months after symptoms onset. We present a patient with subacute brainstem angioencephalopathy, whose condition significantly improved on anticoagulation therapy.

Case presentation

Otherwise healthy, 30-year-old male patient presented to our emergency room because of speech difficulties and clumsiness of the right hand. First symptoms started two days before with very subtle right hand clumsiness. Neurological examination revealed dysarthric speech and paresis of the right arm (muscle strength was 4/5), the rest of the neurological examination was normal. Multi-sliced computed tomography (MSCT) of the brain showed an hypodense lesion with irregular rim at the left side of the pons, without contrast enhancement. Brain MRI showed hyperintense lesion on T2 weighted sequences (dimensions 1.6x2 cm) in the left pons with spreading to left crus cerebri and minimal post –gadolinium enhancement (Fig. 1). DWI sequences showed significantly low diffusion and signs of microhaemorrhages were present. Cell blood count (CBC), standard laboratory, and coagulation tests were normal. ECG and chest X-ray were unremarkable. CSF examination revealed one lymphocyte, slightly elevated proteins of 0.40 g/l (normal value < 0.37), normal CSF protein electrophoresis, and absent oligoclonal bands. Serum and CSF serology for Varicella, Toxoplasmosis, Rubella, Mumps, Morbilli, Mycoplasma pneumoniae, HSV 1 and 2, EBV, CMV, Adenovirus, Borrelia burgdorferi, Syphilis, hepatitis B and C, and HIV were negative. CSF cultures for tuberculosis, candida, aspergilus and cryptococcus were negative as well. Tumor markers (AFP, CEA, CYFRA 21-1, beta HCG, anti Hu, Yo and Ri antibodies), immunologic tests (IgG, IgA, IgM, beta2-microglobulin, ANA, cardiolipin antibodies IgM and IgG, RF, ANCA, CH 50, C3, C4) were all negative. Vascular risk factors (hypertension, hypercholesterolemia, cigarette smoking) were not present.

Corticosteroid treatment (methylprednisolone 500 mg per day) was initiated, however on the second day after hospitalization patient's condition worsened. His speech was severely dysarthric and dysphonic, he had saccadic eye movements, severe paresis of the right arm

(muscle strength 2/5) and severe dysmetria of the right leg. Two days later he further worsened, he had complete plegia of the right arm and positive Babinski sign with brisk reflexes on the right extremities. Because he was now unable to walk low-molecular heparin – enoxaparin 0.6 ml was administered subcutaneously together with dexamethasone 16 mg. After this therapy his condition stabilized.

To clarify the etiology of the pontine lesion stereotactic biopsy was performed before anticoagulation treatment was started. Histopathology showed small edematous CNS tissue fragments with multiple small sized areas of complete and incomplete necrosis (Fig. 2D) with old blood remnants. A striking microangiopathy with severe fibrosis of small and middle sized veins and single arteries (Fig. 2B, 2E) as well as some vascular occlusions (Fig. 2C, 2F) were observed. Inflammatory infiltrates were not present. These changes were reminiscent to those described in subacute brainstem / diencephalic angioencephalopathy, but other causes of microangiopathy (e.g. collagenosis, thrombotic thrombocytopenic purpura) were histologically not excluded.

Control brain MRI performed after the biopsy showed reduction of the lesion, there was still hyperintense T2 lesion in the left pons, however with lesser degree of edema and smaller lesion in the middle cerebellar peduncles (Fig. 1). MRI angiography performed on 3 Tesla MRI was normal. We additionally did protein C and S analysis, and factor V Leyden (R506Q), factor II (G2021A), MELAS (MTTL! A3243G and T3271C) and MERF (MTTK A8344G) mutation analysis, which were negative.

The patient was referred to rehabilitation and showed progressive improvement in the following six weeks. His speech was discreetly dysarthric, he had full right arm movements with weakness of the finger extensors, and he could walk without help. Anticoagulation therapy was continued.

Discussion

Foix–Alajouanine syndrome consists of subacute myelopathy secondary to thrombosis of abnormal vascular channels in which venous congestion causes progressive subacute myelopathy.[1] A cranial variant of this syndrome has been described in 4 cases with lesions in a symmetrical diencephalic distribution and typical histopathological findings.[2-5] Characteristically, all patients were in the older age groups, suffered from progressive neurological deficit which eventually lead to death in the time course of 2-3 months. A single

case of subacute brainstem angioencephalopathy has been described in a 69-year old male patient.[6] Histopathological findings were also consistent with subacute diencephalic angioencephalopathy. Characteristic pathology in this patient affected veins, and venous hypertension due to outflow obstruction is sufficient to explain the subacute progressive course and the type of parenchymal damage.[6] Characteristic histopathological findings of striking microangiopathy with severe fibrosis of small and middle sized veins and single arteries, as well as some vascular occlusions without inflammatory infiltrates were also present in our patient. Although these findings could not exclude other disease like collagenosis and thrombotic thrombocytopenic purpura (TTP), these are very unlikely after extensive laboratory examinations and absence of other signs or symptoms.

Another striking feature in our patient was disease stabilization on anticoagulation therapy. This may be due to prevention of new vascular occlusions. All other described cases were treated with corticosteroids, with little or no success. Our patient recovered extremely well, and showed clinical and neuroradiological improvement after six months of follow-up.

This report further supports the existence of subacute brainstem angioencephalopathy as a characteristic disease entity and gives insight into possible therapeutic approaches.

References

- 1) Bhatt N, Bhatt N. Foix-Alajouanine syndrome: a case report. *Eur J Neurol* 2007;14:e4-5.
- 2) DeGirolami U, Haas ML, Richardson RP. Subacute diencephalic angioencephalopathy: a clinicopathological case study. *J Neurol Sci* 1974;22:197–210.
- 3) Kinney H, Burger PC, Vogel FS. Subacute diencephalic angioencephalopathy: report of an additional case. *J Neurol Sci* 1980;45:73–81.
- 4) Schmidbauer M, Lassmann J, Pilz P, Vass K, Budka H. Subacute diencephalic angioencephalopathy: an entity similar to angiodysgenetic necrotizing encephalopathy and Foix–Alajouanine disease. *J Neurol* 1992;239:379–381.

- 5) Tihan T, Burger PC, Pomper M, Sanchez O, Ramzan M, Eberhart CG et al. Subacute diencephalic angioencephalopathy: biopsy diagnosis and radiological features of a rare entity. *Clin Neurol Neurosurg* 2001;103:160–167
- 6) Rauschka H, Retzl J, Baumhackl U, Bankl HC, Salomonowitz E, Schmidbauer M. Subacute brainstem angioencephalopathy: a case report and review of the literature. *J Neurol Sci* 2003;208:101-4.

Figure legends

Figure 1

Brain MRI on the day of the admission (A-C): A and B) T2 weighted sequences: hyperintense lesion in the left pons with spreading to left crus cerebri; C) T1 weighted sequence after gadolinium application: note the minimal post –gadolinium enhancement.

Brain MRI 10 days after admission (D-F): D and E) T2 weighted sequences; F) T1 weighted sequence after gadolinium application: Note the progression of the lesion.

Control brain MRI after the biopsy and introduction of anticoagulation therapy (G-H): T2 weighted sequences: hyperintense T2 lesion in the left pons, however with lesser degree of edema and smaller lesion in the middle cerebellar peduncles.

Brain MRI at three month interval (I-K): I and L) T2 weighted sequences; K) T1 weighted sequence after gadolinium application: note further improvement.

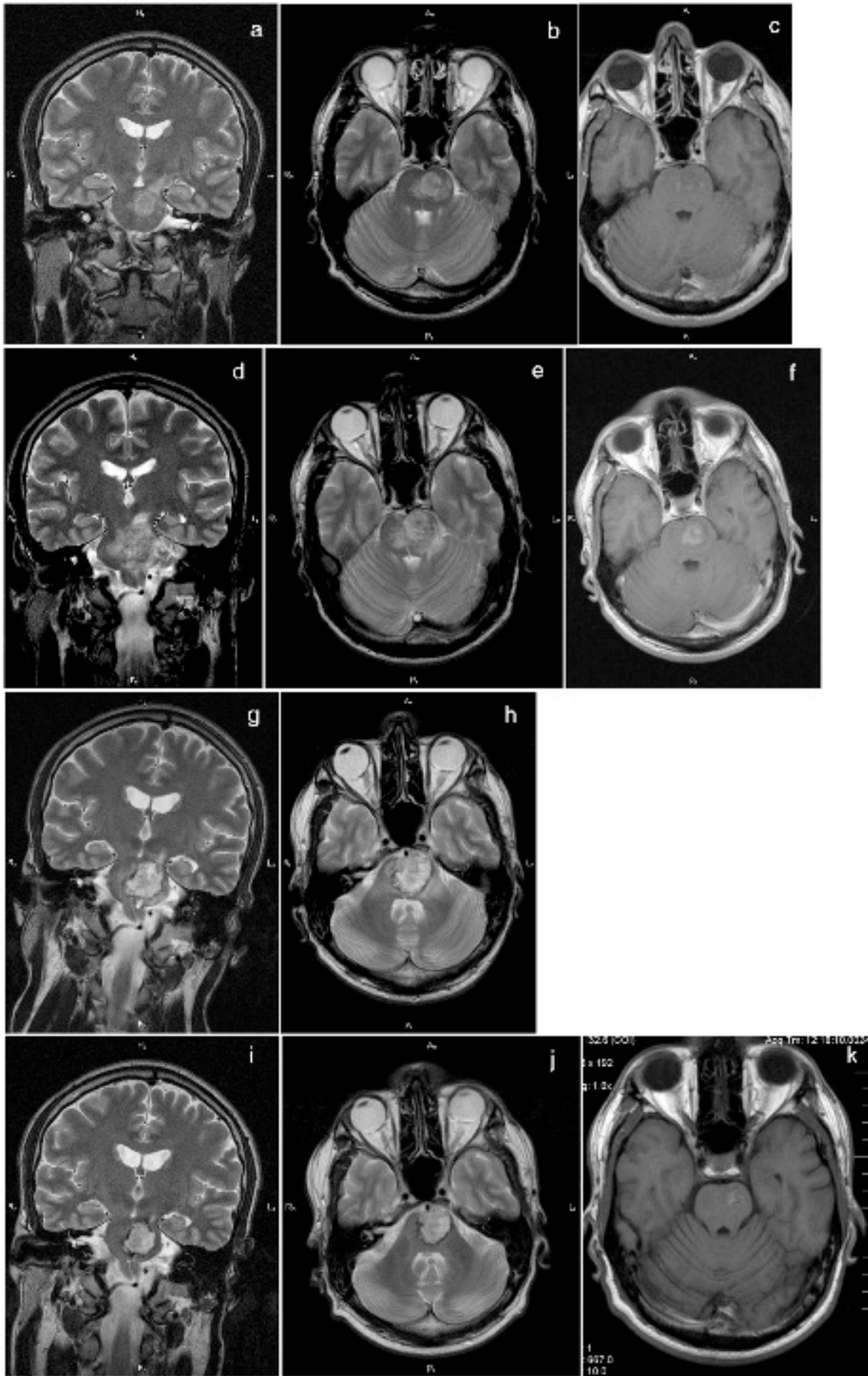


Figure 2

A: Low magnification of the stereotactic biopsy showing tiny CNS tissue fragments with edematous change and small foci of complete and incomplete necrosis lacking inflammatory infiltrates (Hematoxylin-Eosin (HE) x 40). D: Higher magnification of a necrotic area (Hematoxylin-Eosin x 400). B, E: Extensive fibrosis of small and middle-sized vessels, corresponding mostly to veins and, to a lesser extent, small arteries (B: HE x 200, E: elastica van Gieson x 200). C, F: Thrombotic occlusion of small and middle-sized vessels (C: HE x 400, F: elastica van Gieson x 400).

