

Spontaneous rapid resolution of acute subdural hematoma after head trauma: Is it truly rare?

Case report and relevant review of the literature

L. Wen · W. G. Liu · L. Ma · R. Y. Zhan · G. Li ·
X. F. Yang

Received: 28 July 2007 / Accepted: 23 April 2008 / Published online: 20 September 2008
© Royal Academy of Medicine in Ireland 2008

Abstract

Background Spontaneous rapid resolution of acute subdural hematoma (ASDH) is a rare phenomenon for this severe insult after head trauma.

Case report We present a 22-year-old patient who developed ASDH with a moderate midline shift and compression of lateral ventricle after a truncal collision but without a direct beat on the head. Conservative management was performed under close monitoring because of unexpected improvement of clinical signs and symptoms. Unexpectedly, the ASDH resolved spontaneously within 13 h after the trauma, and he was discharged 1 week later without any neurological deficit. In addition, similar cases reported in literature were reviewed.

Conclusion Because most of the patients developing ASDH underwent emergent surgical intervention, the incidence of this phenomenon may be underestimated. Although emergent surgical removal remains the first choice for the treatment of ASDH, conservative management with careful monitoring may also work out in selected

patients who show neurologic and radiologic improvements.

Keywords Acute subdural hematoma · Spontaneous resolution · Traumatic brain injury

Introduction

Acute subdural hematoma (ASDH) is a severe insult with a mortality rate of 60–80% [1], resulting from traumatic brain injuries (TBI). Most cases undergo urgent surgical removal of ASDH or external decompression, and the natural process of ASDH was rarely observed. Only a minor part of patients with good neurological state and without mass effect on CT imaging may be safely managed conservatively. Commonly the nonsurgical management for nonacute hematomas presenting several days after injury has shown that an intracranial, extracerebral hematoma may resolve spontaneously, but it usually takes weeks or months [2]. However, spontaneous rapid resolution of ASDH within 72 h has been infrequently reported in previous literature. In this manuscript, we presented a young patient who developed ASDH after a truncal collision without direct beat on the head, and this hematoma resolved spontaneously within 13 h. In addition, a review of the cases undergoing rapid resolution of traumatic ASDH spontaneously in previous literatures was performed.

Case report

A 22-year-old male, who was a soldier, suffered a truncal collision without a direct blow on the head in

L. Wen · R. Y. Zhan · G. Li · X. F. Yang (✉)
Department of Neurosurgery, First Affiliated Hospital,
College of Medicine, Zhejiang University,
No. 79 Qingchun Road, Hangzhou 310003,
Zhejiang, People's Republic of China
e-mail: jediwen@163.com; zjcswk@126.com

W. G. Liu · L. Ma
Department of Neurosurgery, Second Affiliated Hospital,
College of Medicine, Zhejiang University,
Hangzhou, Zhejiang, People's Republic of China

L. Wen · W. G. Liu · L. Ma · R. Y. Zhan · G. Li · X. F. Yang
Institute of Brain Medicine, Zhejiang University, Hangzhou,
Zhejiang, People's Republic of China

Fig. 1 a, b CT scan performed on admission disclosed an ASDH located on left frontotemporoparietal region and a moderate midline shift without cranial fracture and cerebral contusion. **a** The adjacent sulci are obliterated and there is slight mass effect to the lateral ventricle. **b** Axial image at higher level showed a band of low density between the inner table and the hematoma

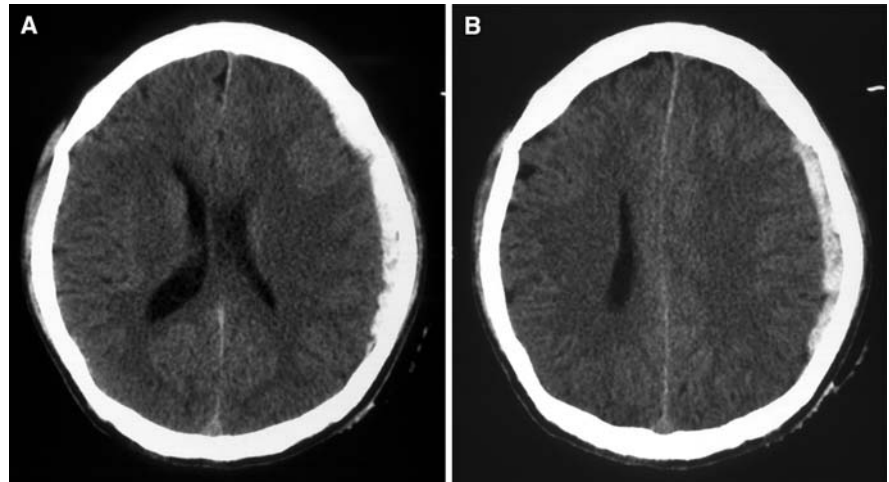
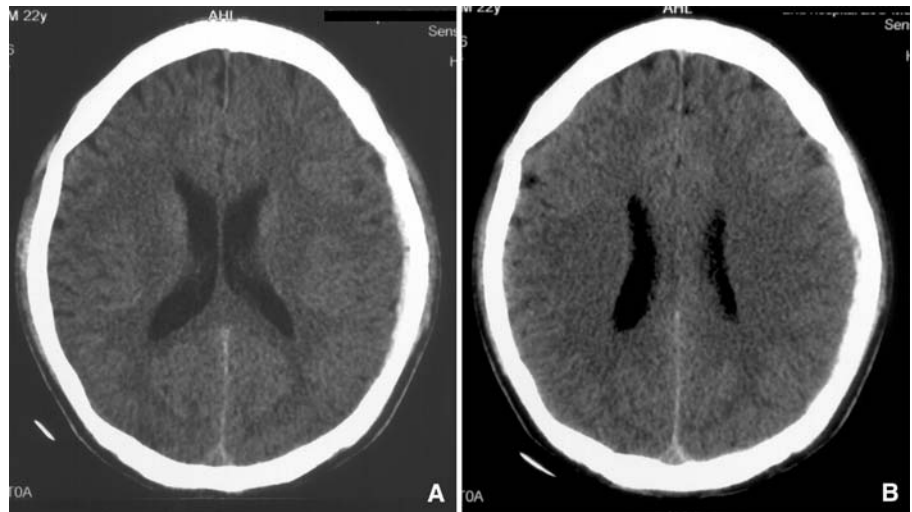


Fig. 2 a, b A second CT scan obtained 4 h after admission disclosed a manifest decrease in the size of hematoma, the mass effect and midline shift could not be noted at that time



training. He reportedly lost consciousness immediately and turned to be lucid 30 min later. On admission 1 h after the trauma, he was lethargic, with a GCS score of 11 (score of 5 for motor response, score of 4 for verbal response and score of 2 for eye opening). His pupils were of equal size and reacted normally to light, and no motor weakness was noted; however, he still complained of severe headache and vomiting. A computed tomographic (CT) scan performed consequently revealed an ASDH located in the left frontotemporoparietal region and a moderate midline shift as well as compression of lateral ventricle without cranial fracture and cerebral contusion (Fig. 1). Conservative management was performed under close monitoring because of the unexpected improvement of clinical signs and symptoms after admission. A second CT scan obtained 4 h after the first examination disclosed a significant decrease in the size of hematoma as well as the disappearance of midline shift, and so the conservative therapy was continued

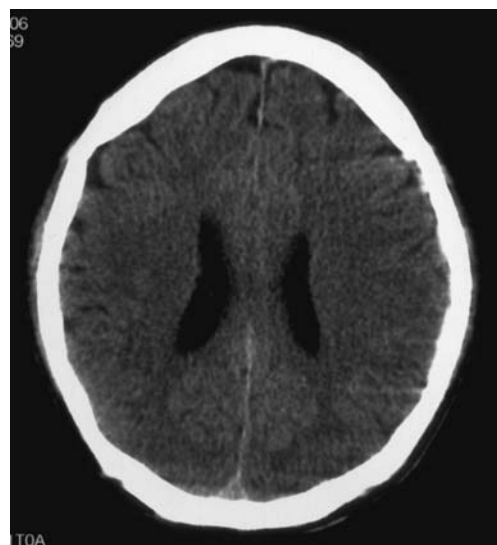


Fig. 3 CT scan performed 12 h after admission disclosed the disappearance of hematoma

Table 1 Cases undergoing rapid spontaneous resolution of ASDH reported in the previous literature

| Case no. | Age/sex | Unconsciousness (time) | Interval (h) ^a | Contusion | Cranial fracture ^b | Herniation signs | Hematoma width ^c | Hematoma location | Dramatic shift of middle line ^d | GCS | Severe atrophy | Brain swelling | Outcome |
|----------|-----------------|------------------------|---------------------------|-----------|-------------------------------|------------------|-----------------------------|-------------------|--|-----|----------------|----------------|---|
| No. 1 | 63 years/M | No | 24 | No | No | No | Thick | F-T-P | No | 13 | No | Yes | Good |
| No. 2 | 16 years/M | Yes (>24 h) | 48 | No | No | No | Thick | F-T-P | Yes | 3 | No | Yes | Moderately disabled |
| No. 3 | 27 years/F | No | 6 | Yes | No | No | Thick | F-T-P | Yes | 10 | No | Yes | Good |
| No. 4 | 48 years/M | Yes (NC) | 6 | Yes | Yes | Yes | Thin | F-T-P | No | 9 | No | No | Mild memory disturbance |
| No. 5 | 17 years/M | No | 12 | No | No | No | Thin | F-T-P | No | 15 | No | Yes | Good |
| No. 6 | 18 years/M | Yes (1 h) | 2 | No | No | Yes | Thick | F-T-P | Yes | 9 | No | Yes | Good |
| No. 7 | 20 years/F | Yes (NC) | 36 | No | No | Yes | Thin | Entire hemisphere | Yes | 5 | NC | NC | Mild hemiparesis and intellectual deficit |
| No. 8 | 92 years/F | No | 72 | No | No | No | Thin | Entire hemisphere | No | NC | NC | NC | Good |
| No. 9 | 67 years/M | Yes (NC) | 96 | No | No | NC | Thin | Entire hemisphere | No | 7 | NC | NC | Good |
| No. 10 | 27 years/M | Yes (12 h) | 12 | No | No | Yes | Thick | Entire hemisphere | No | 7 | yes | Yes | Good |
| No. 11 | 54 years/M | No | 6 | No | No | No | Thin | Entire hemisphere | No | 15 | No | Yes | Good |
| No. 12 | 79 years/F | No | 12 | No | No | No | Thin | F-T | No | >13 | Yes | Yes | Good |
| No. 13 | 41 years/F | Yes (<2 h) | 12 | No | No | No | Thin | F-T | Yes | >10 | No | Yes | Good |
| No. 14 | 16 years/M | Yes (<2 h) | 48 | No | No | Yes | Thin | Entire hemisphere | Yes | 9 | No | No | Good |
| No. 15 | 83 years/F | Yes (6 h) | 48 | No | No | Yes | Thick | Entire hemisphere | Yes | 6 | Yes | Yes | Mild hemiparesis |
| No. 16 | 57 years/M | Yes (<2 h) | 2 | No | Yes | Yes | Thick | Entire hemisphere | Yes | 7 | No | No | Good |
| No. 17 | 13 months/ M | No | 36 | No | No | No | Thin | F-T | No | >13 | No | NC | Good |
| No. 18 | 3 years | No | 6 | No | Yes | No | Thin | F-T | No | >10 | No | Yes | NC |
| No. 19 | 23 months/ M | No | 65 | No | No | No | Thin | F-T-P | No | 14 | No | yes | Good |

F-T-P frontotemporoparietal region, *F-T* frontotemporal region, *NC* not commented

^a Interval, the interval between the onset and the disappearance of ASDH

^b Cranial fracture, cranial fracture transverses the hematoma

^c Hematoma width, thick: >15 mm in the CT imaging, thin: <15 mm

^d Dramatic shift of middle line, shift of middle line > 10 mm in the CT imaging

Table 2 Analysis of cases undergoing rapid spontaneous resolution of ASDH

| | |
|--|-------|
| Conscious or coma lasting not more than 12 h | 15/19 |
| Without contusion | 17/19 |
| Cranial fracture | 3/19 |
| Herniation signs | 7/19 |
| Hematoma width < 1.5 mm | 12/19 |
| Hematoma location | |
| Entire hemisphere | 8/19 |
| F-T-P | 7/19 |
| Dramatic shift of middle line | 8/19 |
| GCS > 8 on admission | 12/19 |
| Atrophy | 3/19 |
| Low-density band | 12/19 |
| Good outcomes or only with mild disability | 16/19 |

F-T-P frontotemporoparietal region

(Fig. 2). Physical examination on the next day revealed complete recovery and a GCS score of 15, and the CT scan (12 h after admission) disclosed the disappearance of hematoma (Fig. 3). He was discharged 1 week later without any neurological deficit.

Discussion

Traumatic ASDH is a frequent lesion following head trauma, and most of them require emergent surgical management. Rapid resolution of ASDH is considered as a rare phenomenon in the ASDH, and we collected the 19 cases reported in previous literature who had experienced this phenomenon following head trauma. The information about these cases reported is shown in Table 1 [1–13]. An analysis of these cases was performed as well and the outcome was shown in Table 2.

Based on this reported case and others reviewed, most of the patients who developed this rapid resolution of ASDH seem to share some characteristics: (1) Transitory coma which last no longer than 12 h after head trauma; (2) Exclusion of cerebral contusion; (3) Widely distributed hematoma with thin width; (4) A band of low density between the hematoma and the inner table of the skull in the CT imaging; (5) A minor or moderate head trauma sustained (GCS > 8 on admission).

Several hypotheses have been proposed to explain this interesting phenomenon. One such hypothesis suggests that rapid spontaneous resolution of ASDH was due to flow of CSF through the tear in the arachnoid layer, resulting in dilution of the hematoma and retrograde flow into the subarachnoid space [3, 6]. Another acceptable explanation considered it was secondary to redistribution of the hematoma due to decrease in the intracranial

pressure or washing out of the hematoma by cerebrospinal fluid (CSF), and the redistribution had been confirmed by the imaging of MRI in some cases [7, 11]. Both of the two hypotheses suggested the participation of CSF and that the presence of a low density band between the hematoma and the inner table of the skull, present in most cases may be a sign of this participation. So Matsuyama et al. [1] further considered that these two mechanisms are not independent of each other and both contribute to rapid spontaneous resolution of ASDH. In addition, several authors suggested that brain swelling itself may facilitate the redistribution of subdural collection in a widened subdural space and thus aid in the rapid resolution of ASDH [3, 13]. Cerebral contusion has also been considered by some authors to contribute to the rapid resolution. However, in this present case both of these two lesions were excluded, and also they occur infrequently in the reported cases (3/19 for the brain swelling and 2/19 for cerebral contusion). Indeed cerebral contusion is more likely to block the foramina and obstruct CSF circulation, which would mitigate the dilution and redistribution mentioned earlier [11]. Considering that most patients with ASDH undergo prompt surgical removal of the hematoma, the true incidence of the rapid resolution of ASDH may be underestimated, and the mechanism for this is difficult to determine from the limited cases. However, the mechanism may predict a potential new method for the management of ASDH.

Conclusion

We report a patient who underwent rapid spontaneous resolution of ASDH and the results of a review of relevant literature. These cases suggest that although emergent surgical removal remains the treatment of first choice for ASDH, conservative management with careful monitoring may be appropriate in selected patients who show neurologic and radiologic improvements, especially for the conscious patients for whom the CT scan shows a simple thin ASDH distributed abroad without marked brain shift. In addition, the importance of repeated CT scan for ASDH has been emphasized again in these cases.

References

1. Matsuyama T, Shimomura T, Okumura Y et al (1997) Rapid resolution of symptomatic acute subdural hematoma: case report. *Surg Neurol* 48:193–196
2. Cohen JE, Eger K, Montero A et al (1998) Rapid spontaneous resolution of acute subdural hematoma and HIV related cerebral atrophy: case report. *Surg Neurol* 50:241–244
3. Niikawa S, Sugimoto S, Hattori T et al (1989) Rapid resolution of acute subdural hematoma—report of four cases. *Neurol Med Chir (Tokyo)* 29:820–824

4. Kuroiwa T, Tanabe H, Takatsuka H et al (1993) Rapid spontaneous resolution of acute extradural and subdural hematomas. Case report. *J Neurosurg* 78:126–128
5. Juran V, Smrcka M (1997) Rapid resolution of acute subdural hematoma. Case report. *Clin Neurol Neurosurg* 99 (supplement(1)):S73
6. Tsui EY, Fai Ma K, Cheung YK et al (2000) Rapid spontaneous resolution and redistribution of acute subdural hematoma in a patient with chronic alcoholism: a case report. *Eur J Radiol* 36:53–57
7. Kato N, Tsunoda T, Matsumura A et al (2001) Rapid spontaneous resolution of acute subdural hematoma occurs by redistribution—two case reports. *Neurol Med Chir (Tokyo)* 41:140–143
8. Inamasu J, Nakamura Y, Saito R et al (2002) Rapid resolution of traumatic acute subdural hematoma by redistribution. *Am J Emerg Med* 20:376–377
9. Imai K (2003) Rapid spontaneous resolution of signs of intracranial herniation due to subdural hematoma—case report. *Neurol Med Chir (Tokyo)* 43:125–129
10. Berker M, Gulsen S, Ozcan OE (2003) Ultra rapid spontaneous resolution of acute posttraumatic subdural hematomas in patient with temporal linear fracture. *Acta Neurochir (Wien)* 145:715–717
11. Erol FS, Kaplan M, Topsakal C et al (2004) Coexistence of rapidly resolving acute subdural hematoma and delayed traumatic intracerebral hemorrhage. *Pediatr Neurosurg* 40:238–240
12. Kundra SN, Kundra R (2005) Extracranial redistribution causing rapid spontaneous resolution of acute subdural hematoma. *Neurol India* 53:124
13. Huang SH, Lee HM, Lin CK et al (2005) Rapid resolution of infantile acute subdural hematoma: a case report. *Kaohsiung J Med Sci* 21:291–294