

DELAYED VISUAL DEFICITS AND MONOCULAR BLINDNESS AFTER ENDOVASCULAR TREATMENT OF LARGE AND GIANT PARAOPHTHALMIC ANEURYSMS

Raymond D. Turner, M.D.

Department of Neurological Surgery,
Cleveland Clinic,
Cleveland, Ohio

James V. Byrne, M.D.

Department of Neuroradiology,
The John Radcliffe Hospital,
University of Oxford,
Oxford, England

Michael E. Kelly, M.D.

Department of Neurological Surgery,
Cleveland Clinic,
Cleveland, Ohio

Aristotelis P. Mitsos, M.D.

Department of Neuroradiology,
The John Radcliffe Hospital,
University of Oxford,
Oxford, England

Vivek Gonugunta, M.D.

Department of Neurological Surgery,
Cleveland Clinic,
Cleveland, Ohio

Shivu Laloo, M.D.

Department of Neuroradiology,
The John Radcliffe Hospital,
University of Oxford,
Oxford, England

Peter A. Rasmussen, M.D.

Department of Neurological Surgery,
Cleveland Clinic,
Cleveland, Ohio

David Fiorella, M.D., Ph.D.

Departments of Neurological Surgery
and Radiology,
Cleveland Clinic,
Cleveland, Ohio

Reprint requests:

David Fiorella, M.D., Ph.D.,
Department of Neurological Surgery,
Cleveland Clinic,
9500 Euclid Avenue, S-80,
Cleveland, OH 44195.
Email: fioreld@ccf.org

Received, April 18, 2007.

Accepted, April 30, 2008.

OBJECTIVE: Paraophthalmic aneurysms may exert mass effect on the optic apparatus. Although surgical clipping and endovascular coiling of these aneurysms can be complicated by immediate postoperative visual deterioration, endovascular coil embolization has the unique risk of visual complications later (>24 h) in the perioperative period.

METHODS: Six patients with a delayed onset of vision loss after technically successful coil embolization of paraophthalmic region aneurysms were identified. All available clinical, angiographic, and cross sectional imaging for these patients, in addition to histopathological data, were reviewed.

RESULTS: Six patients who underwent endovascular treatment of paraclinoid aneurysms at our institutions developed delayed postoperative visual decline. Four were treated with combination hydrogel-coated and bare platinum coils, one with hydrogel-coated coils, and one with bare platinum coils. Three patients presented with some degree of visual impairment caused by their aneurysms. Catheter angiography performed after the visual decline revealed no etiology in any of the cases. Magnetic resonance imaging was performed in all patients and was unremarkable in two. At follow-up, two had improved, three remained unchanged, and one patient died before any follow-up assessment of her vision.

CONCLUSION: Both acute and delayed visual disturbances can present after the endovascular treatment of carotid artery paraophthalmic aneurysms. Delayed visual deterioration can be observed up to 35 days after embolization. Although the cause is still undefined, it is likely that the more delayed visual deterioration can be attributed to progression of mass effect and/or perianeurysmal inflammatory change. Our case series raises the possibility that this phenomenon may be more likely with HydroCoil (HydroCoil Embolic System; MicroVention, Aliso Viejo, CA). This possibility should be taken into account by neurointerventionists when selecting a coil type to treat large paraophthalmic aneurysms.

KEY WORDS: Bare platinum coil, Blindness, Coiling, Cranial neuropathy, HydroCoil

Neurosurgery 63:469–475, 2008

DOI: 10.1227/01.NEU.0000324730.37144.4B

www.neurosurgery-online.com

Cerebral aneurysms are common lesions, with autopsy studies suggesting an adult population prevalence of 1 to 5% (23). Before the early 1990s, the vast majority of treated aneurysms were performed with the use of surgical clipping. However, since 1995, when the Food and Drug Administration approved Guglielmi detachable coils, more than 100,000 patients have undergone endo-

vascular aneurysm treatment (24). Paraophthalmic aneurysms may compress the optic apparatus and present clinically with visual deterioration. The proximity of these aneurysms to the optic apparatus accounts for the risk of acute visual complications after both endovascular and surgical clipping (1). Visual complications after the clipping of paraophthalmic aneurysms usually are evident immediately after open surgery. However, both acute and delayed (>24 h) visual deterioration may be observed after coil

ABBREVIATIONS: ICA, internal carotid artery; MRI, magnetic resonance imaging

embolization. We present six cases of delayed visual impairment after the coil embolization of paraophthalmic aneurysms.

PATIENTS AND METHODS

Six patients who presented with a delayed onset of vision loss after technically successful coil embolization of periorbital region aneurysms were identified at our two institutions. All available clinical, angiographic, and cross sectional imaging for these patients, in addition to histopathological data, were reviewed.

RESULTS

Six patients experienced delayed visual deterioration after endovascular coil embolization (Table 1). Three of the six patients presented with symptoms related to mass effect on the optic apparatus. Four of the patients had been treated with HydroCoil (HydroCoil Embolic System; MicroVention, Aliso Viejo, CA) and bare platinum, one with HydroCoil alone, and one with bare platinum alone. In one patient, the monocular vision loss and contralateral hemianopia was gradual during a 24-hour period and was associated with headache. A second patient developed rapidly progressive monocular blindness at 48 hours without additional symptoms. In four patients, the visual deterioration occurred much later in the recovery period (7–35 d). On magnetic resonance imaging (MRI), two patients had T2 signal changes in the optic nerve and enhancement of the optic chiasm and nerve, whereas a third patient had evidence of mass effect from the aneurysm on the optic apparatus. MRI studies in two patients were unremarkable, demonstrating no significant peri-

aneurysmal enhancement or signal abnormality within the adjacent brain parenchyma.

All six patients were treated with corticosteroids after their vision deteriorated. At follow-up, two had improved, three remained unchanged, and one patient died before any follow-up assessment of her vision.

ILLUSTRATIVE CASES

Patient 1

A 69-year-old right-handed woman presented at an outside institution with decreased peripheral vision and was found to have an unruptured large (17- × 22- × 13-mm) paraophthalmic aneurysm in the right internal carotid artery (ICA). She underwent failed surgical clipping and a subsequent muslin wrap. During intraoperative angiography, the patient sustained an embolic left posterior cerebral artery infarct, which left her with a right homonymous hemianopsia. The patient was referred to our institutions for endovascular treatment and presented to us with short-term memory deficits, progressive vision loss, and hydrocephalus. A baseline ophthalmological examination revealed bilateral optic nerve compression from the aneurysm that limited her visual perception to the appreciation of hand motion only at 20/400 in each eye. The patient underwent ventriculoperitoneal shunting with some subjective improvement in her visual symptoms. After pretreatment with aspirin and clopidogrel, she underwent successful stent-assisted coiling with HydroCoils and bare platinum coils (Fig. 1).

Two weeks after the procedure, the patient presented with visual deterioration. She was found to have no light reflex, with pupils measuring 7 mm bilaterally and unresponsive visual evoked potentials bilaterally. Her left optic nerve had good color; however, her right optic nerve showed mild atrophy, both of which were unchanged from her previous examination. MRI revealed T2 signal changes within the basal

TABLE 1. Patient data and outcome for six patients^a

Patient no.	Age (yr)/sex	Aneurysm size (mm)	Coil type	Stent-assisted coiling?	HydroCoil length (cm)/total coil length (%)	HydroCoil packing density/total packing density ^b	Presented with visual symptoms?	Time to visual deterioration (d)	Visual outcome	Response to corticosteroids
1	69/F	17 × 22 × 13	B	Yes	267/373 (71.6%)	50.6%/54.4%	Yes	14	Blind (bilateral) ^c	Died
2	40/F	26 × 23 × 22	H	Yes	570/570 (100%)	47.8%	No	30	Hand motion only (left eye)	Improved
3	18/M	20 × 16 × 10	B	No	180/270 (66.7%)	48.7%/54.8%	Yes	2	Light perception (left eye)	No change
4	55/F	14 × 14 × 13	B	No	85/296 (29%)	30.8%/46.2%	No	2	Blind (left eye)	No change
5	68/F	23 × 16 × 8	B	Yes	135/291 (46.4%)	32.3%/41.2%	No	21	Inferior quadrant-anopia (right eye)	No change
6	44/F	21 × 19 × 18	P	Yes	0/806 (0%)	0%/23.8%	Yes	7	20/400 (bilaterally), temporal field cut (left eye)	Improved

^a B, both HydroCoil and bare platinum coils; H, HydroCoil; P, bare platinum coil.

^b Packing density was calculated using software found at www.angiocalc.com.

^c Patient 1 developed blindness 14 days after the procedure; however, she died from a fatal stroke 5 weeks after the procedure.

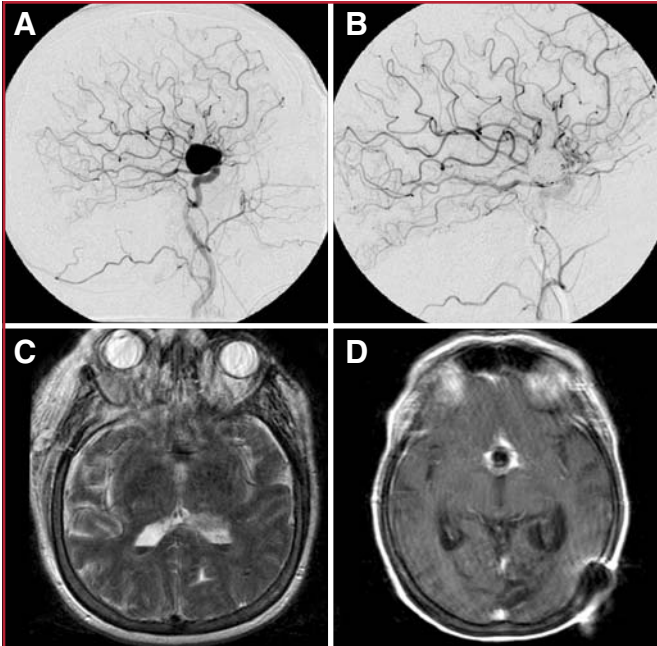


FIGURE 1. **A** and **B**, pre- (**A**) and postoperative (**B**) lateral angiograms significant for a coiled large right internal carotid artery aneurysm and a patent ophthalmic artery. **C** and **D**, magnetic resonance images. The pre-embolization T2-weighted image (**C**) shows minimal perianeurysmal edema. After muslin wrapping and coil embolization, the postgadolinium T1-weighted image (**D**) shows enhancement surrounding the hypointense coil mass.

forebrain surrounding the aneurysm dome with a thick and intense perianeurysmal cuff of contrast enhancement. Angiography revealed a patent right ophthalmic artery (Fig. 1). She was started on corticosteroids for a presumed inflammatory etiology for these findings.

Three weeks later, the patient developed respiratory distress and neurological deterioration, and she subsequently died. Noninvasive imaging had demonstrated an occluded right ICA and a large right middle cerebral artery infarct. A review of her outpatient medications revealed that aspirin and clopidogrel had been discontinued (after her presentation with perioperative vision loss), likely leading to the thrombosis of her indwelling right ICA Neuroform stent (Boston Scientific, Fremont, CA). On autopsy, a foreign body giant cell reaction was identified surrounding the aneurysm and extending along the leptomeninges of the right sylvian fissure. Macrophage and T-cell lymphocyte infiltrates were identified within the adventitia of the aneurysm wall and adjacent to both optic nerves, which adhered densely to the aneurysm. No inflammatory infiltrate was identified within the lumen of the coiled aneurysm. Subacute infarcts of both optic nerves were noted, along with acute hemorrhage within the left optic nerve. The right ICA was thrombosed in the segment containing the stent, with acute infarction of the right frontal and temporal lobes. Cerebrospinal fluid collected at the time of the autopsy was significant for increased cellularity with lymphomononuclear cells.

Although these changes are suggestive of an aneurysmal-based inflammatory process as a cause for the associated visual deterioration, the clinical picture is obscured to a large extent by the history of an attempted surgical clipping and subsequent muslin wrapping. It is possible that the previous muslin wrapping contributed significantly to the subsequent leptomeningeal inflammatory process and subsequent

visual deterioration. The development of hydrocephalus and visual compromise in this patient after the muslin wrapping and before endovascular treatment raises the suspicion that a significant inflammatory response to the muslin had been developing before the attempted coiling. The phenomenon of chronic inflammatory reactions to muslin wrapping with delayed visual deterioration was first described by Carney and Oatey (5) and, subsequently, by a number of other investigators (3, 9, 10, 13, 17, 19).

Patient 2

A 40-year-old woman presented with hyperprolactinemia, hypothyroidism, and adrenocorticotropic hormone deficiency caused by stalk disconnection syndrome. Imaging revealed a giant (26- × 23- × 22-mm), partially thrombosed ICA aneurysm located just distal to the left ophthalmic artery origin. The patient's vision was normal, and she was started on hormone replacement therapy, including corticosteroids. Two months later, the aneurysm was treated by stent-assisted coiling with HydroCoil. The procedure was complicated by immediate right visual field loss secondary to a small left occipital lobe infarct, likely attributable to an intraprocedural thromboembolism. Her vision improved over the course of 24 hours, and she was discharged from hospital 2 days later without any visual defect.

A month later, she developed rapidly progressive monocular vision loss in the left eye; her vision deteriorated to perception of hand movements only. On examination, the left optic disc was pale with inflammatory characteristics. The right eye was normal. MRI revealed communicating hydrocephalus (Fig. 2) as well as high T2 signal in the left optic nerve with gadolinium enhancement of the chiasm, the adjacent left optic nerve, and the aneurysm wall (Fig. 3). A laboratory examination of her cerebrospinal fluid was normal. A neurophysiological evaluation with cortical visual evoked potentials confirmed a left optic neuropathy. The patient was treated by cerebrospinal fluid diversion (ventriculoperitoneal shunt) and high doses of corticosteroids. At 6 months' follow-up, her left eye vision has improved, and MRI has shown a reduction in the chiasmatic T2 signal abnormality and contrast enhancement.

Patient 3

An 18-year-old man presented with a 3-month history of blurred vision in the left eye. The ophthalmological examination was normal, but imaging revealed a 20- × 15- × 15-mm left carotid ophthalmic

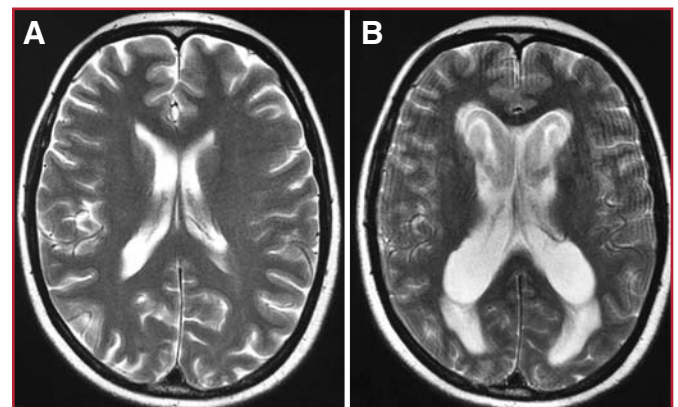


FIGURE 2. Pre- (**A**) and postoperative (**B**) T2-weighted magnetic resonance images showing a significant increase in ventricular size after endovascular coiling.

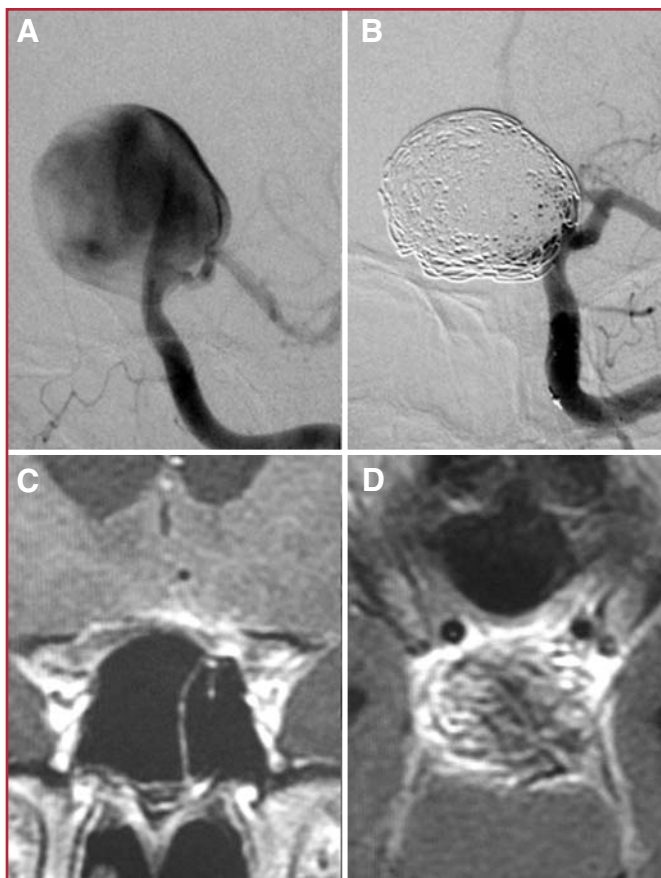


FIGURE 3. **A** and **B**, pre- (**A**) and postoperative (**B**) left internal carotid artery angiograms showing near-complete coil embolization of the giant aneurysm. **C** and **D**, magnetic resonance images. Postembolization coronal (**C**) and axial (**D**) T1-weighted images with gadolinium showing intense perianeurysmal enhancement with compression on the optic chiasm.

aneurysm. He was treated by endovascular coiling with a combination of bare platinum coils and HydroCoils. The procedure was uncomplicated, and his postprocedure vision was initially normal. Two days later, vision in his left eye deteriorated, and MRI suggested local compression of the optic nerve with T2 hyperintensity in the left optic nerve (Fig. 4). Treatment with corticosteroids was started, but after a further 48 hours, his vision remained at finger counting only, and transthemoidal decompression of the optic nerve was performed without effective improvement. On follow-up at 9 months, his vision in the left eye remains at the level of light perception only.

DISCUSSION

Paraophthalmic ICA aneurysms, because of their direct proximity to the optic apparatus, are unique with respect to the risk of visual deterioration after both surgical and endovascular treatment (1, 16, 20). Although few data exist, the risk of this complication seems to occur in 5 to 10% of patients, regardless of the treatment strategy. Andaluz et al. (1) reported that 3 (7.9%) of 38 patients who underwent surgical clipping of para-

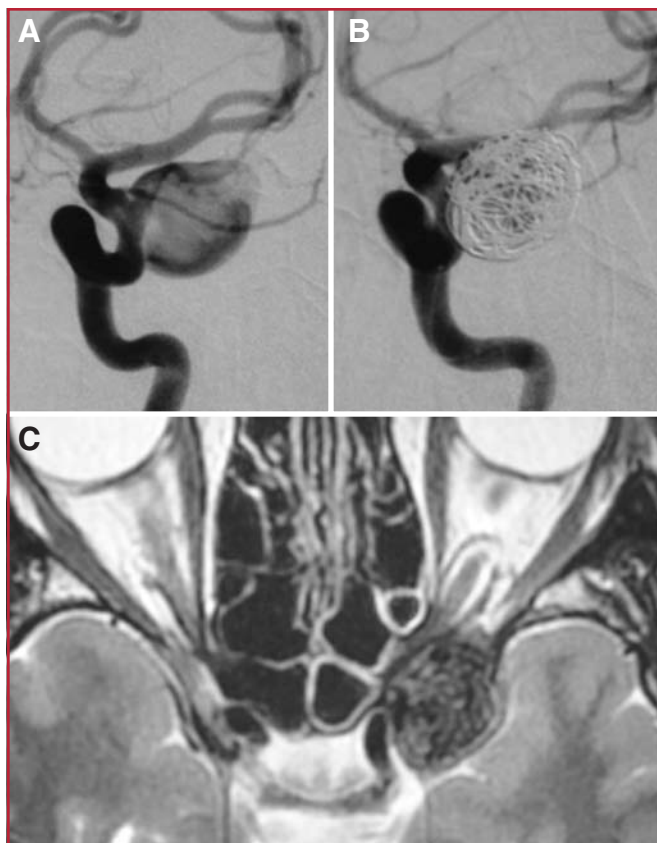


FIGURE 4. **A** and **B**, pre- (**A**) and postoperative (**B**) left internal carotid artery angiograms showing near-complete coil embolization of the aneurysm. **C**, postembolization axial T2-weighted magnetic resonance image showing significant mass effect on the left optic nerve and hyperintensity within the left optic nerve.

clinoid aneurysms experienced new visual field deficits, and 1 (8.3%) of 12 patients who underwent endovascular embolization had an acute onset of blindness requiring immediate surgical decompression of the optic nerve. Vargas et al. (22) reported 19 patients who underwent endovascular treatment of giant aneurysms and who were symptomatic with vision loss. Of these patients, 18 were improved or unchanged, and 1 (5.3%) experienced further visual deterioration after treatment.

Categorization of the new-onset visual deficits or blindness after endovascular treatment of paraclinoid aneurysms can be based on the etiology, timing, and acuity of the symptom onset. Deficits that occur abruptly and are maximal at onset are likely thromboembolic, related to direct retinal infarcts via the ophthalmic artery or posterior communicating artery to posterior cerebral artery emboli and leading to occipital lobe infarcts and cortical blindness. These events are most common during the procedure or in the immediate periprocedural period (7). These ischemic deficits typically do not improve with time or respond to corticosteroid therapy and may require emergent intervention to save vision.

Progressive visual changes, as observed in our series, typically occur hours to weeks after the procedure. Unlike the thromboembolic events, which have an abrupt and maximal onset, these changes have a slower, more progressive onset and are likely secondary to evolving mass effect from aneurysm thrombosis and/or perianeurysmal inflammation and edema (15, 21, 25). The severity of edema, the anatomic configuration of the aneurysm, its relationship to the optic apparatus, and the degree of mass effect and visual compromise before the embolization likely dictate the ultimate outcome of the visual deficits in these patients. These visual disturbances may stabilize or improve with administration of corticosteroids.

The workup of patients presenting with visual changes after coil embolization of paraophthalmic aneurysms can be simplified on the basis of presentation. Patients who present with abrupt, maximal-at-onset vision decline within hours to days after the procedure likely have a thromboembolic etiology. Immediate catheter angiography may be performed in these cases to identify an occluded ophthalmic artery, which may be amenable to therapeutic revascularization, depending on the time frame. However, for patients presenting with a slow, progressive deterioration in their vision, MRI is often useful to evaluate for mass effect and/or edema. If present, corticosteroids or decompressive surgery may be of benefit.

Five of the six aneurysms in our series were embolized, at least partially, with HydroCoil. Embolization with the HydroCoil has been associated with postprocedure headaches (8), worsening cranial neuropathy (8), aseptic meningitis (6, 8, 14), and delayed hydrocephalus (2, 8). These sequelae are postulated to be secondary to perianeurysmal inflammation and mass effect on adjacent structures, particularly the cranial nerves and dura mater. However, although these phenomena have been reported to occur in association with the use of HydroCoils, similar findings also are observed after the embolization of aneurysms with bare platinum (11, 12) and polyglycolic-poly-lactic acid-coated coils (14, 18). In the current series, the HydroCoil component of the coil mass could be contributing to perianeurysmal edema and inflammation. This inflammatory process, even in the absence of significant mass effect on MRI, could conceivably cause delayed visual loss.

Cantón et al. (4) found that aneurysm packing densities of up to 93% with HydroCoil did not increase intra-aneurysmal pressures, suggesting that mass effect-related symptoms may be minimized by not overpacking (>100% packing density), a phenomenon that can be achieved with HydroCoil but not bare platinum. In fact, improvement in cranial neuropathies caused by decreased mass effect and aneurysmal pulsatility has been noted in association with low packing density (<50%) embolization, regardless of the coil type (4, 8). In the present series, no aneurysm was packed to a density greater than 55% (Table 1).

Because the present series does not represent an all-inclusive, prospective study at either institution, it is possible (although not probable) that additional periophthalmic aneurysms were treated with other coil types and that delayed blindness resulted but was not captured in this retrospective

evaluation. It is also certainly true that many other periophthalmic aneurysms were treated at both institutions with HydroCoil (and other coil types) over the same time period without resulting in blindness. As such, no precise estimate of the rate at which these complications occur can be provided. The present data are therefore not sufficient to draw any firm conclusions as to a relationship between HydroCoil use in these aneurysms and delayed blindness. At the same time, we do raise the possibility that this phenomenon of delayed blindness, although observed with other coil types as well, may be more likely with HydroCoil.

CONCLUSION

Both acute and delayed visual disturbances can present after the endovascular treatment of carotid artery paraophthalmic aneurysms. Delayed visual deterioration can be observed up to 35 days after embolization. It is likely that the more delayed visual deterioration can be attributed to progression of mass effect and/or perianeurysmal inflammatory change. In our series, this complication occurred exclusively after the treatment of large paraophthalmic aneurysms, half of which had initially presented with mass effect or visual disturbance. In this series, five of six patients underwent coiling with HydroCoil, which raises significant concerns that delayed vision loss may be more likely with the use of HydroCoil than other coil types. This possibility should be taken into account by neurointerventionists when selecting a coil type to treat large periophthalmic aneurysms.

REFERENCES

- Andaluz N, Beretta F, Keller JT, Zuccarello M: Aneurysms of the ophthalmic (C6) segment of the internal carotid artery: Clinical experience, treatment options, and strategies (Part 2). *Neurosurg Q* 15:91–102, 2005.
- Berenstein A, Song JK, Niimi T, Namba K, Heran NS, Brisman JL, Nahoum MC, Madrid M, Langer DJ, Kupersmith MJ: Treatment of cerebral aneurysms with hydrogel-coated platinum coils (HydroCoil): Early single-center experience. *AJNR Am J Neuroradiol* 27:1834–1840, 2006.
- Berger C, Hartmann M, Wildemann B: Progressive visual loss due to a meningioma—Report of a case and review of the literature. *Eur J Neurol* 10:153–158, 2003.
- Cantón G, Levy DI, Lasheras JC: Changes in the intraaneurysmal pressure due to HydroCoil embolization. *AJNR Am J Neuroradiol* 26:904–907, 2005.
- Carney PG, Oatey PE: Muslin wrapping of aneurysms and delayed visual failure. A report of three cases. *J Clin Neuroophthalmol* 3:91–96, 1983.
- Cloft HJ: Correction of HEAL Registry Data Report. *AJNR Am J Neuroradiol* 27:2023, 2006.
- Derdeyn CP, Cross DT 3rd, Moran CJ, Brown GW, Pilgram TK, Diringner MN, Grubb RL Jr, Rich KM, Chicoine MR, Dacey RG Jr: Postprocedure ischemic events after treatment of intracranial aneurysms with Guglielmi detachable coils. *J Neurosurg* 96:837–843, 2002.
- Deshaies EM, Adamo MA, Boulos AS: A prospective single-center analysis of the safety and efficacy of the HydroCoil embolization system for the treatment of intracranial aneurysms. *J Neurosurg* 106:226–233, 2007.
- Felsberg GJ, Tien RD, Haplea S, Osumi AK: Muslin-induced optic arachnoiditis (“gauzoma”): Findings on CT and MR. *J Comput Assist Tomogr* 17:485–487, 1993.
- Goldsberry DH, Ross IB, Dhillon G, Corbett JJ: Visual dysfunction caused by gauze wrapping of an intracranial aneurysm. *J Neuroophthalmol* 24:42–45, 2004.

11. Horie N, Kitagawa N, Morikawa M, Tsutsumi K, Kaminogo M, Nagata I: Progressive perianeurysmal edema induced after endovascular coil embolization. Report of three cases and review of the literature. *J Neurosurg* 106:916–920, 2007.
12. Malisch TW, Guglielmi G, Viñuela F, Duckwiler G, Gobin YP, Martin NA, Frazee JG, Chmiel JS: Unruptured aneurysms presenting with mass effect symptoms: Response to endosaccular treatment with Guglielmi detachable coils. Part I. Symptoms of cranial nerve dysfunction. *J Neurosurg* 89:956–961, 1998.
13. McFadzean RM, Hadley DM, McIlwaine GG: Optochiasmal arachnoiditis following muslin wrapping of ruptured anterior communicating artery aneurysms. *J Neurosurg* 75:393–396, 1991.
14. Meyers PM, Lavine SD, Fitzsimmons BF, Commichau C, Parra A, Mayer SA, Solomon RA, Connolly ES Jr: Chemical meningitis after cerebral aneurysm treatment using two second-generation aneurysm coils: Report of two cases. *Neurosurgery* 55:1222, 2004.
15. Nakayama T, Tanaka A, Ohshiro S, Yoshinaga S: Extensive edema in the thalamus caused by thrombosed basilar artery aneurysm. *Neurol Med Chir (Tokyo)* 38:274–277, 1998.
16. Park HK, Horowitz M, Jungreis C, Kassam A, Koebe C, Genevro J, Dutton K, Purdy P: Endovascular treatment of paraclinoid aneurysms: Experience with 73 patients. *Neurosurgery* 53:14–24, 2003.
17. Prabhu SS, Keogh AJ, Parekh HC, Perera S: Optochiasmal arachnoiditis induced by muslin wrapping of intracranial aneurysms. A report of two cases and a review of the literature. *Br J Neurosurg* 8:471–476, 1994.
18. Stracke CP, Krings T, Möller-Hartmann W, Mahdavi A, Klug N: Severe inflammation reaction of the optic system after endovascular treatment of a supraophthalmic aneurysm with bioactive coils. *AJNR Am J Neuroradiol* 28:1401–1402, 2007.
19. Taravati P, Lee AG, Bhatti MT, Lewis SB: That's a wrap. *Surv Ophthalmol* 51:434–444, 2006.
20. Thornton J, Aletich VA, Debrun GM, Alazzaz A, Misra M, Charbel F, Ausman JJ: Endovascular treatment of paraclinoid aneurysms. *Surg Neurol* 54:288–299, 2000.
21. Ushikoshi S, Kikuchi Y, Houkin K, Miyasaka K, Abe H: Aggravation of brainstem symptoms caused by a large superior cerebellar artery aneurysm after embolization by Guglielmi detachable coils—Case report. *Neurol Med Chir Tokyo* 39:524–529, 1999.
22. Vargas ME, Kupersmith MJ, Setton A, Nelson K, Berenstein A: Endovascular treatment of giant aneurysms which cause visual loss. *Ophthalmology* 101:1091–1098, 1994.
23. Wiebers DO, Whisnant JP, Huston J 3rd, Meissner I, Brown RD Jr, Piepgras DG, Forbes GS, Thielens K, Nichols D, O'Fallon WM, Peacock J, Jaeger L, Kassel NF, Kongable-Beckman GL, Torner JC: Unruptured intracranial aneurysms: Natural history, clinical outcome, and risks of surgical and endovascular treatment. *Lancet* 362:103–110, 2003.
24. Wijidicks EF, Kallmes DF, Manno EM, Fulgham JR, Piepgras DG: Subarachnoid hemorrhage: Neurointensive care and aneurysm repair. *Mayo Clin Proc* 80:550–559, 2005.
25. Yamada K, Shrier DA, Tanaka H, Okawara SH: Cerebral giant aneurysm with extensive vasogenic edema. *Radiat Med* 16:305–307, 1998.

Acknowledgments

The Cleveland Clinic receives a research and education grant from Terumo/Microvention to support the neuroendovascular fellowship program.

COMMENTS

Turner et al. presented a small case series of subacute to chronic visual loss in patients with paraophthalmic aneurysms undergoing endovascular treatment. In this series of six patients, they described different patterns of visual loss in presumed association with the treatment of the aneurysms by coiling. Although four of the six patients had been treated exclusively with HydroCoils (HydroCoil Embolic System; Microvention, Aliso Viejo, CA), one patient had been treated with a bare platinum coil alone and one patient was treated with a combination of coils.

An important complication in the endovascular treatment of aneurysms of the ophthalmic region is also described. This timely contribution emphasized other recent publications describing similar results in the endovascular treatment of aneurysms of that region (1). Interestingly, Turner et al. point out that mass effect may not be the only cause for visual loss, especially in the delayed setting. Indeed, Schmidt et al. made this suggestion as well, especially in light of the fact that several of the patients in the series presented 24 hours later with pyrexia (unpublished data), which seems to correlate with various laboratory studies. It is unclear in this limited series and in other published series as to whether the problem is truly a consequence of the HydroCoils. Given the combined assessment of several articles, HydroCoils per se may not be the cause. Rather, the presence of a large thrombus burden may be the true cause.

A better understanding of the pathobiological basis of aneurysm therapy, be it endovascular or microsurgical, is necessary. Future case series and in vitro analyses will certainly help provide the needed answers to effect safe, definitive treatments for aneurysms.

Charles J. Prestigiacomo
Newark, New Jersey

1. Schmidt GW, Oster SF, Golnick KC, Tumialan LM, Biousse V, Turbin R, Prestigiacomo CJ, Miller NR: Isolated, progressive visual loss after coiling of paraclinoid aneurysms. *AJNR Am J Neuroradiol* 28:1882–1889, 2007.

Turner et al. reported a case series of six patients with delayed monocular blindness after endovascular treatment of paraclinoid aneurysms. Three of these patients presented with a history of some visual deterioration preoperatively and five of six of the patients were treated with HydroCoils. They concluded that this phenomenon is related to both the mass effect and inflammatory reactions after the use of HydroCoils. One of the fundamental principles in treating many neurosurgical problems is relieving the mass effect. This is important in a wide range of neurological disorders ranging from acute epidural hematomas, spinal compression from disc or tumors, or compression of the brain stem in cranial base tumors. It is therefore surprising that the authors would not expect this result as these were mostly large paraclinoid aneurysms with mass effect on the optic apparatus, and therefore visual loss would occur regardless of the type of coils used. In my practice in which I coil a large number of paraophthalmic aneurysms, I manage large aneurysms and treat those with clinical evidence of optic nerve compression with intradural clinoid removal and microsurgical clipping to prevent early and delayed visual deterioration.

Gavin W. Britz
Durham, North Carolina

Turner et al. reported their experience with six patients who underwent endovascular treatment of paraclinoid aneurysms and developed delayed postoperative visual field deficits or decline. In four of the patients, a hydrogel-coated coil was used along with a bare platinum coil, and one patient had a hydrogel coil alone.


Hydrogel has been implicated in a significant perivascular inflammatory response, which clearly may have led to the delayed visual loss in these patients. Even with bare platinum and thrombosis of the lesion, an inflammatory response can occur, often with swelling, edema formation of the lesion, and compression of the optic apparatus. After surgical manipulation, visual loss is often acute and is detected immediately upon the patient's emergence from anesthesia; however, I think

there is a need to be aware of this possibility in an endovascularly treated group. Perhaps these patients should be treated more aggressively with large doses of steroids in a prophylactic fashion. Oftentimes, however, the use of steroids is more for the treating physician than for an actual change in the course of the disease.

As Turner et al. stated in their article, these deficits, when they occur, may require urgent surgical decompression. This certainly could make the case for considering surgical intervention for large lesions such as

these; however, six patients is quite a small number for the numerator, and I am sure the denominator needs to be considered as well. If visual loss associated with endosaccular occlusion is raised as an issue, then the numerator and denominator for surgical intervention should be intellectually examined as well.

Robert H. Rosenwasser
Philadelphia, Pennsylvania



Istanbul. Image courtesy of Earth Sciences and Image Analysis Laboratory, NASA Johnson Space Center, (<http://eol.jsc.nasa.gov>).