

Sabareesh K. Natarajan, M.D., M.S.

Department of Neurological Surgery,
University of Washington,
Seattle, Washington

Basavaraj Ghodke, M.D.

Departments of Neurological Surgery
and Neuroradiology,
University of Washington,
Seattle, Washington

Gavin W. Britz, M.D.

Departments of Neurological Surgery
and Neuroradiology,
University of Washington,
Seattle, Washington

Donald E. Born, M.D.

Department of Neuropathology,
University of Washington,
Seattle, Washington

Laligam N. Sekhar, M.D.

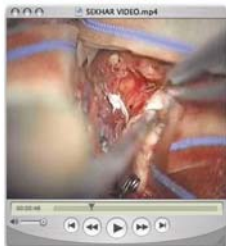Department of Neurological Surgery,
University of Washington,
Seattle, Washington

Reprint requests:

Laligam N. Sekhar, M.D.,
Department of Neurological Surgery,
Harborview Medical Center,
Box 359766,
Seattle, WA 98104.
Email: lsekhar@u.washington.edu

Received, May 11, 2007.

Accepted, February 13, 2008.



ONLINE
DIGITAL
VIDEO

MULTIMODALITY TREATMENT OF BRAIN ARTERIOVENOUS MALFORMATIONS WITH MICROSURGERY AFTER EMBOLIZATION WITH ONYX: SINGLE-CENTER EXPERIENCE AND TECHNICAL NUANCES

OBJECTIVE: To report our experience with the treatment of brain arteriovenous malformations (AVM) with microsurgical resection after embolization with Onyx liquid embolic agent (eV3, Irvine, CA).

METHODS: Between August 2005 and December 2006, 28 patients were treated by the same surgical-endovascular team. Twenty-eight AVMs were embolized preoperatively in 55 sessions (71 pedicles) with Onyx. We analyzed the AVM size, volume, number of embolization sessions, degree of preoperative obliteration, time to embolization and resection after the bleed, intraoperative complications, intraoperative blood loss, other complications, and postoperative outcome at 6 months. Technical nuances of the embolization and surgical resection of the embolized AVMs are illustrated in illustrative cases.

RESULTS: The average size and volume of AVMs treated with Onyx were 3.56 cm (largest, 7.6 cm), and 13.03 ml, respectively. The average Spetzler-Martin grade was 2.75. The average preoperative volumetric obliteration was 74.1%. The average blood loss during resection of embolized AVMs was 348 ml. Complications related to embolization were stuck microcatheter (two patients), proximal vessel perforation (one patient), and anterior choroidal territory stroke (one patient). Surgical complications included wound infection (one patient), residual AVM nidus (one patient), normal pressure perfusion breakthrough with worsening of neurological deficit caused by embolization (one patient), and new-onset motor deficits in five patients. At the time of the 6-month follow-up examination, four patients with new-onset motor deficits had recovered completely or nearly completely, and one patient was disabled. One patient died, never recovering from the initial poor condition due to the bleed. Pathological examination of resected AVMs showed angioneurosis in 42.9%, foreign body giant cells in 39.3%, and evidence of recanalization of Onyx-embolized vessels in 14.3% of specimens.

CONCLUSION: Multimodality treatment with microsurgery is safe and effective after embolization with Onyx. High occlusion rates and low complication rates were observed after Onyx embolization and were comparable to those in previous reports. Superselective intranidal or perinidal catheter positions and slow, controlled injections that protect the draining veins make the therapy safe even in complex AVMs and critical locations. We recommend resection of the AVM despite apparently complete embolization with Onyx. Team work and coordination between the surgeon and the interventional neuroradiologist are important to achieve a good outcome.

KEY WORDS: Brain arteriovenous malformation, Embolization, Microsurgery, Onyx, Outcomes, Recanalization, Technique

Neurosurgery 62:1213–1226, 2008

DOI: 10.1227/01.NEU.0000316860.35705.AA

www.neurosurgery-online.com

Modern treatment of arteriovenous malformations (AVM) of the brain includes the following interventions alone or in combination: endovascular embolization, microsurgical resection, and radiosurgery (6, 15, 23, 30, 35,

42). Microsurgical resection is preferred for treatment of AVMs in resectable areas (6, 30, 36). Radiosurgical treatment of small (<3 cm) AVMs has also shown good obliteration rates at 3 years (41). Embolization is mainly used to reduce the size of a

large AVM, to enhance the safety of surgery, or to make the AVM amenable to radiosurgery (10, 11, 18, 45). Some small AVMs have been reported to have been cured by embolization alone (5, 10, 28, 29, 54, 55). Resection of AVMs, especially large ones and those in or around critical regions, requires considerable technical expertise even after embolization. Before 2005, the most commonly used embolic agent for AVM treatment was the fast polymerizing liquid adhesive n-butylcyanoacrylate (NBCA; Cordis Neurovascular, Inc., Miami, FL). The use of NBCA in brain AVMs requires experience and skill because intranidal flow and polymerization of NBCA are quick and largely unpredictable (21, 28, 51). Recently, a new liquid embolic agent has become available: Onyx liquid embolic system (eV3, Irvine, CA). Onyx is less adhesive, polymerizes slowly, and has advantages over NBCA. In this article, we outline the technical aspects of Onyx embolization and microsurgical resection of AVMs. We describe our experience with microsurgical resection of AVMs after Onyx embolization. Technical nuances of the embolization and surgical resection of the embolized AVMs are illustrated with illustrative cases.

PATIENTS AND METHODS

Between August 2005 and December 2006, 28 patients with AVMs (14 with acute hemorrhage) were managed by the cerebrovascular service (LNS, GWB, BG) at the University of Washington Harborview Medical Center by embolization and microsurgical resection (does not include radiosurgical cases). The clinical data were collected and analyzed by a single surgeon (SKN). Twenty-eight AVMs were embolized preoperatively in 55 sessions with Onyx and subsequently resected. The following data were collected: admission World Federation of Neurological Societies (WFNS) grade, AVM diameter, volume, number of embolization sessions, degree of preoperative obliteration, time to embolization after the bleed, time to surgical resection after the bleed, intraoperative complications, intraoperative blood loss, other complications, and postoperative outcome (modified Rankin Scale [mRS] score) at 6 months. The postoperative outcomes were verified by telephone interviews conducted by a single author (SKN). AVM size was obtained from the angiographic images, and AVM volume was calculated retrospectively by the method described by Pasqualin et al. ($V = \text{width} \times \text{height} \times \text{length} \times 0.52$) (38).

Treatment Strategy for AVMs

The treatment strategy for AVMs was decided after joint evaluation of the magnetic resonance imaging (MRI) and angiography studies by the neurosurgeons and endovascular neuroradiologists. AVM size was measured from MRI and angiography, and all AVMs were classified according to the Spetzler-Martin grading system. AVM factors considered important in the evaluation process by the treating physicians included size, deep feeders, eloquent or deep location, compact versus racemose nidus, and aneurysms (distant or intranidal). When treatment was considered to be clinically indicated, AVMs larger than 3 cm and those in surgically accessible areas were preferentially managed by microsurgical resection after staged embolization. Radiosurgery was preferentially used for small (<3 cm) AVMs in surgically inaccessible areas and in some cases of Spetzler-Martin Grade IV and V AVMs considered to be inappropriate for surgical resection. In patients undergoing preoperative embolization, Onyx was used to decrease the arterial blood supply of the AVM and to facilitate intra-

operative localization in AVMs, particularly near eloquent areas. Embolization was not used as the only treatment modality.

Onyx Liquid Embolic Agent

Onyx is a less adhesive liquid embolic agent and is supplied in ready-to-use vials. Each vial contains ethylene vinyl alcohol copolymer mixed with tantalum and dimethyl sulfoxide (DMSO) as a solvent for the ethylene vinyl alcohol. Ethylene vinyl alcohol copolymer is formed of 48 mol/L ethylene and 52 mol/L vinyl alcohol. Micronized tantalum powder (35% wt/vol) is added for radiopacity. The vials are kept on a shaker (Vortex Genie; Scientific Industries, Bohemia, NY) for at least 20 minutes to ensure proper mixing of the tantalum powder. The lower the concentration of the copolymer, the less viscous the agent and the more distal the penetration that can be achieved. The polymer is dissolved in DMSO and is prepared in two different concentrations: 6.0 and 8.0% (Onyx 18 and Onyx 34) (viscosity 18 and 34 cP [centipoise, unit of viscosity], respectively). Generally, Onyx 18 is used for embolization of a plexiform nidus, and Onyx 34 is used for embolization of large arteriovenous shunts in the AVM. DMSO is potentially angiotoxic, but this effect is considered negligible if used at the recommended infusion rates (1). When Onyx comes into contact with water-containing liquids such as blood, precipitation of the polymer is initiated by diffusion of DMSO. This process begins on the surface while the core is still liquid, resulting in a soft, nonadherent mass. Therefore, Onyx has a lava-like flow pattern within blood vessels without any fragmentation during the injection. Due to these properties and because Onyx is not absorbable, it is capable of producing occlusion of the nidus of the AVM (33). In addition, prolonged injections of the embolic agent into the feeding artery can be performed, and the Onyx flows along newer areas of the AVM around areas of previous solidification. It can also flow backward (reflux into the artery) and block important branch arteries.

Catheterization of Nidus and Assessment of AVM for Onyx

All embolization procedures were performed with the patient under general anesthesia in a biplane angiographic unit. Systolic blood pressure during the procedure was controlled at less than 120 mmHg. Postembolization, the blood pressure was kept 10% lower than the baseline systolic pressure in children or less than 120 mmHg in adults after the procedure for 24 hours. Catheterization was performed by a transfemoral approach using standard coaxial techniques. The patient was heparinized before embolization to maintain activated clotting time at 300 seconds. The heparin was not reversed at the end of the procedure unless there was intraoperative perforation of the vessel or rupture of AVM. The guiding catheter was constantly flushed via a pressure bag with saline containing 5 U of heparin/ml. A DMSO-compatible microcatheter (Marathon 1.3 F; eV3) was navigated to the nidus of the AVM with aid of a 0.008-inch microguidewire (Mirage; eV3). Once microcatheterization as close as possible to the nidus was achieved, an angiogram was obtained to check the position of the microcatheter. The course of the microcatheter within the vasculature (redundancy released by withdrawing the catheter), the caliber of the feeders, the distance from the catheter tip to the nidus (in case of perinidal catheterization), and origin of normal brain-supplying vessels were assessed. Depending on the morphological features of the superselective contrast injection described above, the most appropriate Onyx type was selected for embolization, and the maximum possible reflux to avoid embolization of normal brain vessels was estimated. (It is important to have the microcatheter tip as close to the nidus as possible and to have a good distance between the catheter tip and any normal branch proximal to it

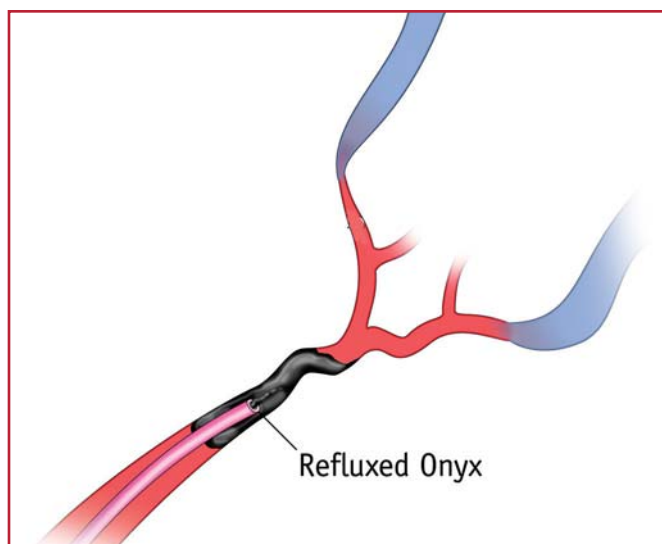


FIGURE 1. Position of the microcatheter for Onyx (eV3, Irvine, CA) embolization. Note the reflux of Onyx around the tip of the microcatheter to form a plug.

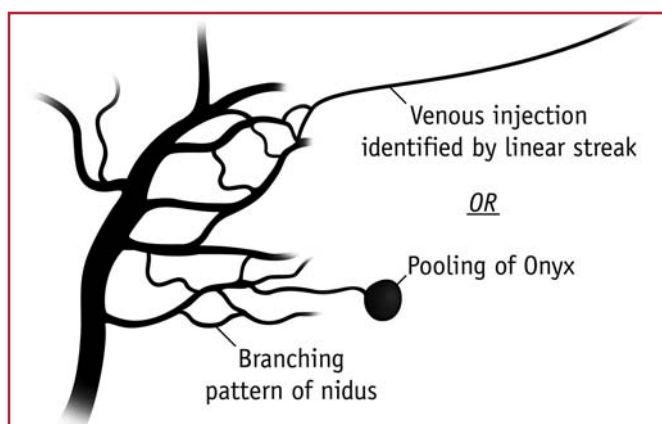


FIGURE 2. Patterns for identifying nidal injection and venous injection during Onyx injection.

[reflux distance] [Figs. 1 and 2]). The guidewire was then pulled out, and a biplane supraselective arteriogram to analyze the anatomy of the nidus segment was obtained via the microcatheter.

Technical Nuances of Onyx Injection

(see video at web site)

First Penetration

Before Onyx injection, a blank road map (subtracted fluoroscopy) was obtained. Oblique views were obtained to see the tip of the catheter clearly, so that the reflux could be appreciated readily. We needed to decide ahead of time the safe distance of reflux that could be allowed during injection. Once the microcatheter tip was in the desired position, the injection of Onyx was carried out as follows: the microcatheter was flushed with 10 ml of normal saline; 0.23 ml DMSO was

injected into the Marathon microcatheter to fill the dead space. DMSO was also used to wash the hub of the syringe to avoid the polymerization of Onyx (when it comes in contact with water). Onyx was aspirated into a 1-ml syringe. Meniscus-to-meniscus connection was made between the Onyx (in the syringe) and the DMSO (in the catheter hub). Onyx was injected slowly at a flow rate of 0.1 ml/s to fill the microcatheter and replace the DMSO in the dead space. The embolic agent was released at the tip of the microcatheter under free-flow conditions and filled the directly dependent nidus compartment antegradely, and subsequently refluxed into the feeding artery beyond the tip of the microcatheter (first penetration). The goal was to form a cast of Onyx around the tip of the microcatheter over a short distance, so that when Onyx was injected, it would flow forward into the AVM and not retrograde into the feeding vessel. The injection procedure was then interrupted for as long as 1 minute to allow the cast to form, and small volumes of the Onyx were injected per cycle until there was enough reflux to form an attenuated cast for a second penetration of the nidus. The maximum safe distance of reflux was usually approximately 2 cm back or at least 1 cm distal to a cortical branch of the feeding artery.

Monitoring Onyx Penetration

One must have a good idea of the perimeter of the AVM by angiography; angiograms in two views were stored in the monitor for repeated viewing. Repeated biplanar angiography was performed via the guiding catheter during injection of Onyx to look for remnants of the nidus (Fig. 3). Intermittent new road maps (with the previous Onyx cast subtracted) were obtained to observe where subsequent Onyx deposition occurred. When reflux occurred in other feeding arteries of the AVM or in normal brain areas, the injection was stopped for a minute and started again to avoid these areas. Avoiding venous embolization is very important. When passing through a vein, Onyx tends to laminate initially along the venous wall. Venous deposition was suspected if there was pooling of Onyx or if Onyx traveled in a straight line without branching. The operator must also have a good understanding of where the veins are inside the AVM and in its periphery to identify and avoid venous embolization.

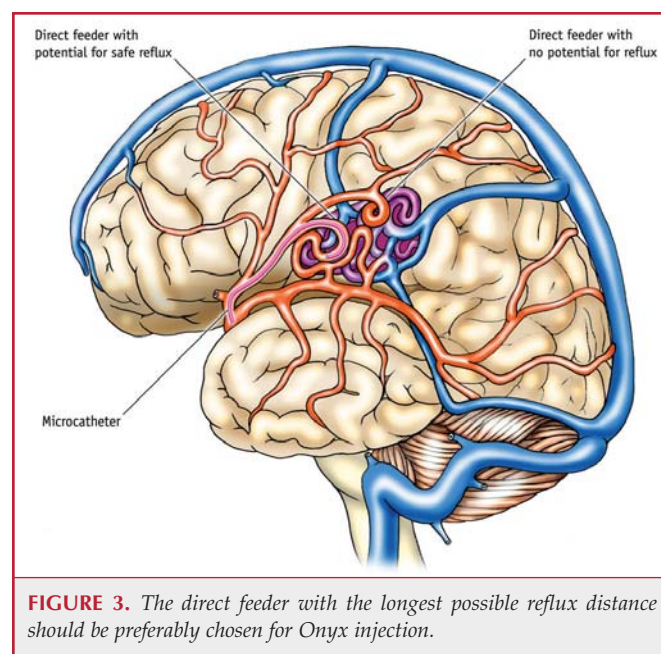


FIGURE 3. The direct feeder with the longest possible reflux distance should be preferably chosen for Onyx injection.

When to Stop?

When to end an embolization session is a matter of great importance and individual judgment. Typically with large AVMs, we decided how much and which portions were to be embolized in each session. The considerations were to embolize large AVMs (>3 cm) in a staged fashion to achieve maximal but safe reduction of the AVM volume and to embolize areas that were surgically difficult. We always started with direct feeders to the AVM (not en passage feeders) and progressed to more surgically difficult areas. Initial embolization was usually performed through one pedicle, chosen for direct nidus access with a possibility of maximum reflux distance (greatest distance from normal branches) (Fig. 1). In subsequent sessions, the focus was on areas of the AVM that were difficult for surgical resection, such as perimotor or deep-seated areas. In the final session 2 to 3 days before surgical excision, a larger volume of the AVM was usually embolized, and the patient remained in the hospital until the surgical resection. Although it was our goal, we found it difficult to embolize the apex of the AVM in most cases. The embolization session was stopped when: 1) the desired volume of embolization had been reached, 2) there was repeated opacification of draining veins, 3) the maximum safe distance for reflux was exceeded, or 4) despite a moderate injection pressure, there was no forward flow of Onyx.

Microcatheter Removal

The microcatheter was then removed at the end of the procedure as follows: after aspirating with the Onyx syringe, the microcatheter was pulled back slowly, increasing the tension on the tip during withdrawal, holding the tension for a few seconds, and repeating this maneuver a few times until the microcatheter pulled out of the cast of Onyx around it. We have observed that it is easier to withdraw the catheter if it is not steam-shaped. Catheter retrieval was performed in all but two patients (one with a steam-shaped catheter and one without a steam-shaped catheter). Both were subsequently removed at surgery. During retrieval, the anesthetist kept protamine ready for reversal of anticoagulation should an accidental rupture occur, but we never had to use it in our series of patients. Immediately after retrieval of the microcatheter, the position of the guiding catheter must be checked because it may migrate cranially. The guiding catheter should be thoroughly aspirated to remove any clots before performing postprocedural angiography.

Management of Vessel Perforation

Perforation of a vessel by the microguidewire or the microcatheter may occur during the initial catheterization. It may be recognized by an unexplained position (from the arterial anatomy) of the wire or catheter and in extreme cases, by changes in the patient's vital signs. It can be confirmed by a small-volume contrast injection through the microcatheter or by angiography through the guiding catheter. If a perforation is identified, the anesthesiologist should immediately reverse the heparin with protamine. The microcatheter is left in place through the perforation while the protamine is reversed, and a small amount of Onyx is injected through the catheter as it is withdrawn to seal the perforation and the perforated artery. If the feeding artery is well sealed and the extravasation is minimal, then embolization can be continued through another feeding vessel. If a large extravasation is noticed or there are changes in vital signs, then the procedure should be stopped. In patients who were in poor condition after hemorrhage from the AVM, we frequently performed early embolization followed by surgical resection (average length from bleed to first embolization, 15 d; 7 of 14 [50%] were performed within 1 wk) rather than wait for the clot to clear.

Technical Nuances of Surgical Resection

Timing of Surgery, Anesthesia, and Intraoperative Monitoring

After Onyx embolization, the surgery was frequently performed within a few days after the last embolization session because a much greater AVM volume was embolized and there was concern about the prospect of hemorrhage from the AVM while awaiting surgery. Total intravenous anesthesia was used for the AVM surgery to allow the monitoring of motor evoked potentials. A slack brain, mild hypotension during AVM resection, and adequate replacement of blood or blood products were important elements for the anesthesia. Somatosensory and motor evoked potentials were usually monitored during the surgery. Direct electrode localization of the sensorimotor areas was also used in some patients.

Craniotomy and Localization of AVM

While planning the craniotomy, the surgeon should pay careful attention to which areas have been completely embolized and which areas remain unembolized. The exposure of the AVM takes into account the entire AVM as well as the important feeding arteries. This review should also include evaluation of the original angiogram (before embolization) to fully understand the extent of the AVM. This is important because Onyx embolization may fragment areas of an AVM such that a small region of active AVM still lies outside an angiographically well-embolized area. However, after Onyx embolization, the surgeon can focus attention on areas of the AVM that are still active. In some patients with hemispheric AVMs who still have a major supply from a deep artery, one may expose the artery by an additional basal approach, if it is practical. A temporary clip is placed on that vessel with the benefit of somatosensory evoked and motor evoked potentials monitoring. At the conclusion of AVM resection, the temporary clip is removed or replaced with a permanent clip. With small AVMs, frameless stereotactic guidance is frequently used to locate the AVM. The presence of Onyx in the perinidal arteries also helps in localization of small AVMs.

Dissection of the AVM

Resection of the AVM was performed as follows (37). After exposing the AVM, arachnoidal dissection was performed circumferentially. Temporary clips were placed on the feeding arteries. The AVM was disconnected circumferentially. Small vessels entering or exiting the AVM were interrupted by low power (nonsticking or irrigating) bipolar cautery or small clips. The dissection proceeded circumferentially around the AVM, going from superficial to deep, keeping the field dry at all times. The black color of the Onyx-embolized vessels and the firm consistency of the embolized AVM assist in identifying the plane of resection. One must cut through feeding arteries that have an Onyx cast. This can be done easily, and these arteries are left behind (they will be visible in postoperative studies). When the nidus is diffuse or racemose, we recommend that the resection margin be somewhat away from the main nidus, if this is possible. This is also true of areas of neovascularization. Although Onyx embolization is advantageous in general, extensive embolization does make it difficult to shrink and retract the AVM, in contrast to cases in which no embolization is performed.

Retractors are rarely placed on the brain, but rather on the AVM if necessary. As always, the most difficult area of AVM resection is near the apex. The most important draining vein is ligated at the end of AVM disconnection, only after it turns blue. Troublesome bleeding from an area usually indicates residual AVM in that region. Most AVMs extend into the ventricle or the periventricular region. Bleeding may occur from arterialized periventricular veins until the deep blood supply is interrupted. Sometimes small feeding arteries may lie deep to a large drain-

ing vein and may be a source of persistent bleeding from an AVM after the remaining part of the AVM is disconnected. Intraoperative angiography is usually performed to verify the AVM resection. Occasionally, intraprocedural angiography may be necessary to see whether there is a remaining major feeding vessel or a nidus in case of persisting redness of the draining vein.

Collaboration between the Surgeon and Interventionist

Close collaboration between the surgeon and interventionist was maintained in all our patients' cases. The neurosurgeon either performed or was present during all embolization procedures. The interventional neuroradiologist was frequently present during some aspects of the AVM resection to observe the ease or difficulty of resection. This process allowed the team to learn from the experience.

Pathological Examination

The specimens of resected AVMs were examined. Resected specimens were fixed in 10% buffered formalin and embedded in paraffin in a standard fashion. Sections from the specimens were prepared for histological examination with hematoxylin and eosin stain and Verhoeff-van Gieson stain. Specimens were evaluated for the presence of Onyx, inflammation, angioneurosis, and evidence of recanalization (endothelium-lined spaces within a fibrosed Onyx cast) by a neuropathologist.

RESULTS

Patient Characteristics

Twenty-eight patients with brain AVMs were managed by microsurgical excision after preoperative Onyx embolization from July 2005 to December 2006 (Table 1). Fourteen AVMs (50%) were located in eloquent brain regions. The average age was 45.6 years and the male-to-female ratio was 4:3. The most common presentation was hemorrhage (50% of patients). Fourteen patients were managed after an acute bleed. The average AVM diameter was 3.56 ± 5.25 cm and the average volume was 13.03 ± 13.81 ml. Ten AVMs treated were larger than 4 cm, of which four were larger than 6 cm. The largest AVM was 7.6 cm in diameter. The average Spetzler-Martin Grade was 2.75 ± 1.04 . There were seven patients with Spetzler-Martin Grade IV and V. Fifteen (53.6%) patients with deep venous drainage were treated. Seven (25%) patients had associated arterial or venous aneurysms; five had venous aneurysms, two patients had distant arterial aneurysms managed by clipping, one had an intranidal aneurysm, and one had a feeding artery aneurysm coiled before embolization.

Embolization

Seventy-one arterial pedicles were embolized in 28 patients in 55 sessions. The average bleed-to-embolization time was 29.2 ± 27.6 days (range, 1–63 d). The average time from bleed to first embolization was 15 days. The average injection time with a single intranidal catheterization was 16 minutes. The average final percentage of preoperative nidal obliteration was $74.11 \pm 18.21\%$. Six (21.4%) AVMs (2.0, 2.1, 3.0, 3.1, 3.5, and 4.8 cm) could be obliterated completely with Onyx by angiographic criteria. All these AVMs were resected after embolization and were found to have

active remnants (the draining vein was red) during surgery, even though the angiograms showed complete obliteration.

Complications of Embolization

There were four complications after embolization. One patient had left-sided hemiplegia 8 hours after embolization of a Spetzler-Martin Grade V AVM in the occipitotemporal region through feeders from the anterior choroidal artery. She had an infarct in the right occipitoparietal and thalamic region on MRI. A second patient had an arterial perforation by the microguidewire that was managed by immediate reversal of heparin with protamine and termination of the procedure. She was successfully embolized the next day and had complete microsurgical resection after 2 more days. She had no neurological deficits. Two patients had stuck microcatheters after the embolizations that were left in situ (Fig. 4); they were identified intraoperatively and were extracted in both cases.

Surgery

All 28 patients had surgical resection after embolization. The average blood loss was 348 ml. In one patient, persistent intraoperative bleeding from the AVM led to intraoperative angiography and identification of a remaining feeding artery. After this vessel was occluded, the remaining AVM was excised. One patient with a Spetzler-Martin Grade V AVM had normal pressure perfusion breakthrough bleeding at the end of the AVM resection. After Gelfoam (Pfizer, Inc., New York, New York) hemostasis, removal of the bone flap, and sedation with systolic blood pressure less than 110 mmHg for 5 days, her condition stabilized. One patient with a premotor AVM (who did not have intraoperative angiography performed because of logistical reasons) was found to have a residual AVM nidus. He underwent reoperation, and the AVM was removed completely without deficit.

Six patients had new motor deficits after embolization followed by surgery (one after embolization and five after surgery). Five of these six patients had complete recovery of motor function within 6 months. One patient who had an anterior choroidal territory stroke and hemiplegia after embolization has been recovering but has permanent hemiparesis and requires assistance with walking and activities of daily living.

Immediate postoperative angiography (in addition to intraoperative angiography) and 6 months postoperative angiography were performed in all patients. In two patients, the postoperative angiogram showed some vessels suggesting abnormal arteries or residual AVM. On 6-month angiography, these vessels had disappeared in one patient. In a second patient, a few vessels persisted, and this patient was treated with radiosurgery. One patient experienced wound infection and another had pneumonia and hydrocephalus postoperatively.

Pathology

Angioneurosis was observed in the specimens of 12 of the 28 (42.9%) Onyx-embolized patients, presumably owing to the solvent DMSO. Chronic foreign body giant cells were seen in 11 of the 28 (39.3%) specimens. There was evidence of recanalization (endothelium-lined spaces within a fibrosed Onyx cast) in Onyx-

TABLE 1. Characteristics, treatment, and outcome of arteriovenous malformations^a

Patient no.	Size (cm)	Volume (ml)	Location	Rupture	SM grade	WFNS grade	Obt %	Endovascular complication	Surgical complication and recovery	Mortality	mRS score at 6 mo
1	2.7	3.58	Cerebellum	Yes	I	5; coma with flexion withdrawal	80		Hemiparesis recovered in 3 d		1
2	2.1	3.56	Parieto-occipital	No	I	1	100				0
3	4.5	14.51	Parieto-occipital	No	II	1	50				0
4	1.5	2.34	Mid-frontal, motor	No	II	1	60				0
5	2.7	1.35	Cerebellum	Yes	II	2; ICH, seizure	60				1
6	4.5	21.72	Frontal	No	II	1	65	Perforation	Wound infection		0
7	3.6	3.28	Occipital	No	II	1	65				1
8	2	3.74	Occipital, calcarine	Yes	II	2; ICH, headache, right hemianopsia	70				0
9	4.6	21.84	Parietal	Yes	II	5; coma with flexion withdrawal	80				1
10	2	0.53	Frontoparietal, motor	Yes	II	4; ICH, headache, right hemiparesis	80				0
11	3.1	3.93	Temporal	No	II	1	100				0
12	2	3.87	Frontal, motor	Yes	II	4; ICH, headache, right hemiparesis	100				0
13	3	4.98	Cerebellum	Yes	II	5; coma with extensor posturing	100			ICH after 2 wk	6
14	1.5	2.86	Temporal, Broca	Yes	III	2; seizure, aphasia	30				1
15	1	1	Parietal, motor	No	III	1	50				1
16	4.7	19.72	Occipital	No	III	1	55				0
17	3.2	14.76	Occipital	Yes	III	2; migraine, headache, visual field deficit	75				1
18	4.5	21.68	Frontal, premotor	Yes	III	2; left upper extremity weakness	75				0
19	1.6	0.73	Frontal, premotor	No	III	1	80		Residual AVM re-resected		0
20	3.3	3.51	Cerebellum	Yes	III	4; ICH, headache, vomiting, diplopia	100				1
21	3	4.82	Occipital	No	III	1	100				0
22	4	18	Temporal, Broca	Yes	IV	1	55	Catheter stuck	Hemiparesis recovered completely at 6 mo; severe cognitive deficits		2
23	6	32.84	Frontal	No	IV	1	70		Hemiparesis; recovered in 6 mo		1
24	5.5	19.25	Frontal	No	IV	1	60		Hemiparesis; recovered at 3 mo		0
25	7	38.67	Frontal, premotor	Yes	IV	5; coma with extensor posturing	75	Catheter stuck	Recovered to have left leg weakness after surgery and recovered at 3 mo		1
26	4.5	22.68	Frontal, premotor	No	V	1; tingling and episodic left side weakness	80		Hemiparesis; nearly completely recovered at 6 mo (power 4/5 in upper and lower limbs)		1
27	6.1	39.22	Frontoparietal, motor	Yes	V	2	75				0
28	7.6	50.32 calcarine	Occipitotemporal	No	V	1; tingling and episodic right side weakness	85	Left hemiplegia after 8 h	Normal pressure perfusion breakthrough; permanent left hemiparesis (power 2/5 in upper limb, 4/5 in lower limb)		4

^a SM, Spetzler-Martin; WFNS, World Federation of Neurological Societies; Obt, obliteration; mRS, modified Rankin Scale; ICH, intracranial hemorrhage.

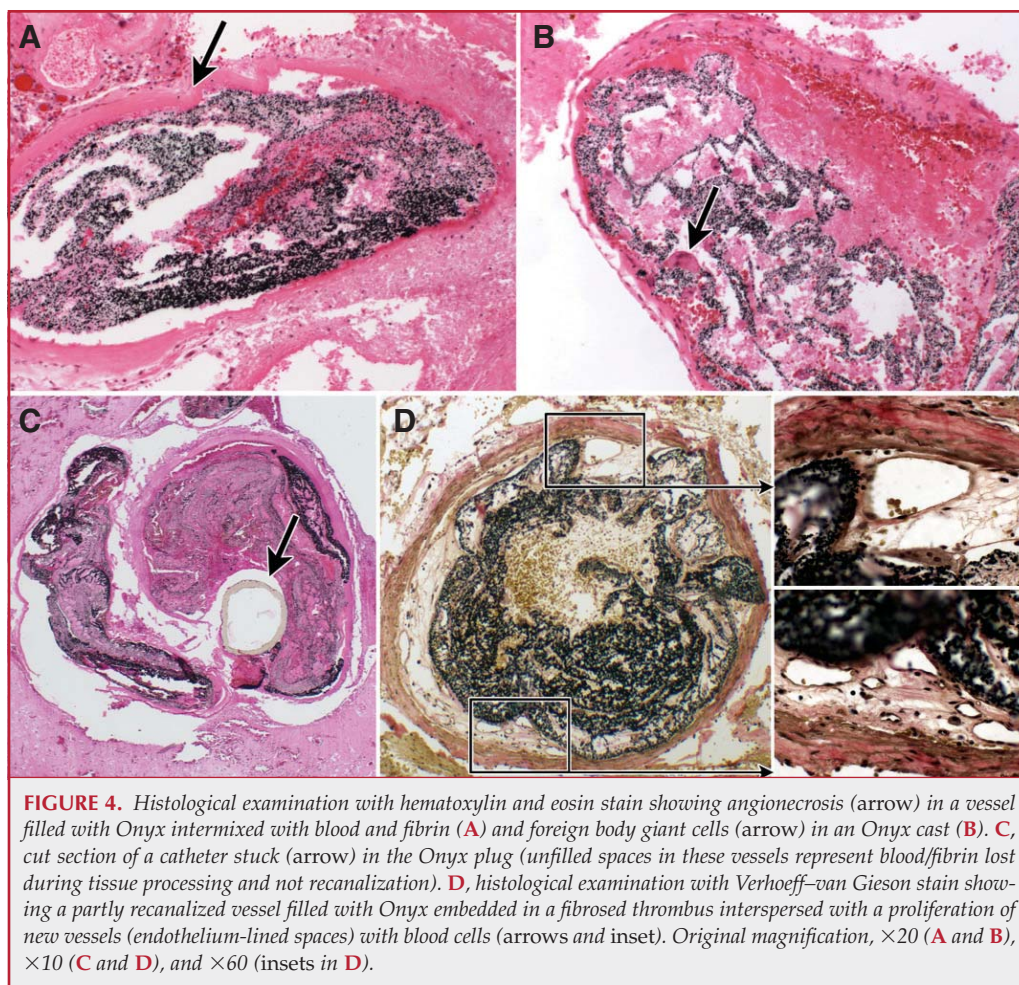


FIGURE 4. Histological examination with hematoxylin and eosin stain showing angionecrosis (arrow) in a vessel filled with Onyx intermixed with blood and fibrin (A) and foreign body giant cells (arrow) in an Onyx cast (B). C, cut section of a catheter stuck (arrow) in the Onyx plug (unfilled spaces in these vessels represent blood/fibrin lost during tissue processing and not recanalization). D, histological examination with Verhoeff-van Gieson stain showing a partly recanalized vessel filled with Onyx embedded in a fibrosed thrombus interspersed with a proliferation of new vessels (endothelium-lined spaces) with blood cells (arrows and inset). Original magnification, $\times 20$ (A and B), $\times 10$ (C and D), and $\times 60$ (insets in D).

another after surgery. The patient who had hemiparesis after surgery recovered nearly completely (power 4+/5) within 6 months and has an mRS score of 1. The second patient who had hemiparesis after embolization is improving but has not completely recovered and has an mRS score of 4 (power 2/5 in upper limb and 4/5 in lower limb, able to walk with assistance). This patient had an occipitotemporal AVM and had hemiplegia secondary to embolization of the anterior choroidal artery and, subsequently, normal pressure perfusion breakthrough phenomenon. Six months after surgery, the patient has normal cognition and speech, is able to walk with assistance, but has minimal recovery of left upper limb function. The third patient had no motor deficits and has an mRS score of 0 at the time of a recent follow-up examination.

Illustrative Cases

(see video at web site)

embolized vessels in four of the 28 (14.3%) specimens resected 42, 46, 70, and 81 days after the first embolization session.

Outcomes

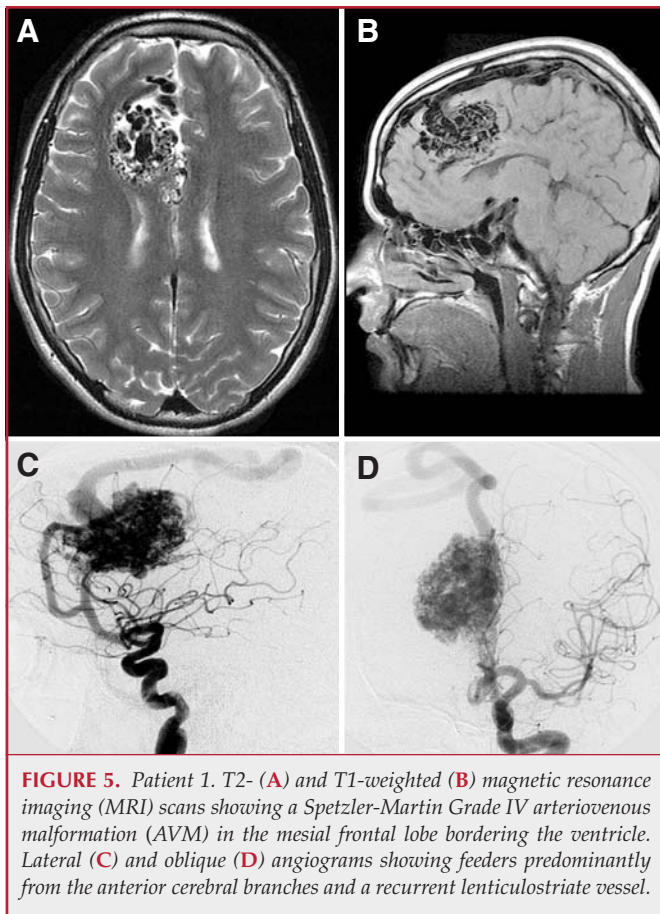
Outcomes were measured by 6-month mRS score (Table 1). Twenty-one patients had Spetzler-Martin Grade I to III AVMs. Of these, one had new motor deficit after surgery but recovered completely within 3 days. Twelve had an mRS score of 0, and eight had an mRS score of 1 at 6 months. One patient who was in poor neurological condition from the initial hemorrhage remained unchanged after the AVM resection. The family decided to withdraw supportive care 2 weeks after surgery, and the patient died. One patient had transient reversible alopecia of the scalp, probably due to higher radiation exposure.

Four patients had Spetzler-Martin Grade IV AVMs. Of these four, three had new motor deficits after surgery but recovered completely within 6 months. One had an mRS score of 2 because of severe cognitive dysfunction, and the other three recovered, with mRS scores of 0 or 1.

Three patients had Spetzler-Martin Grade V AVMs. Two had motor deficits after treatment, one after embolization and

Patient 1: Feeder to the Apex Could Not Be Embolized; Operative Approach Modified to Occlude the Feeder

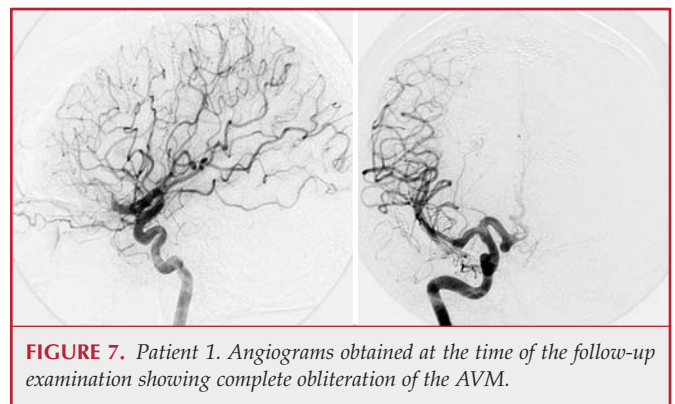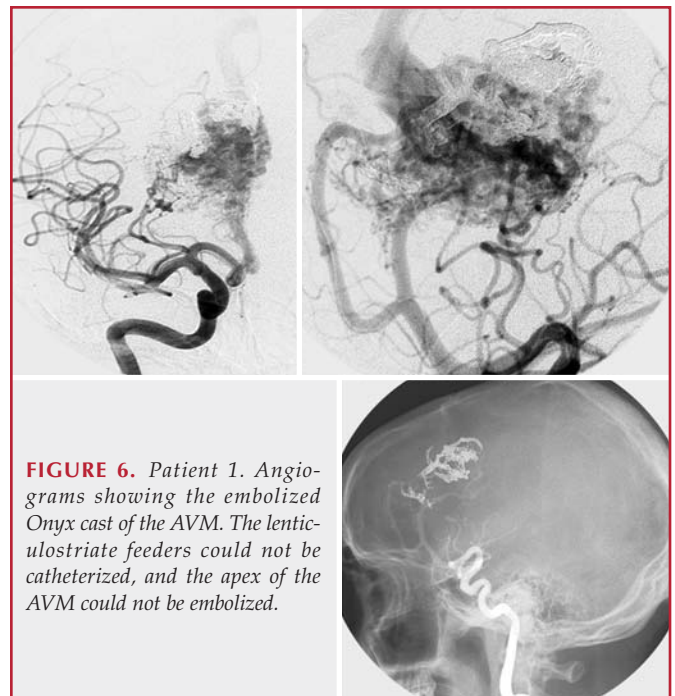
A 17-year-old boy presented with disabling headaches and vertigo and was diagnosed as having a Spetzler-Martin Grade IV AVM measuring $5.5 \times 3.5 \times 2.0$ cm in size in the mesial frontal lobe bordering the ventricle (Fig. 5). The AVM was supplied predominantly by the right anterior cerebral artery, both the callosomarginal and pericallosal vessels. In addition, there was a very large lenticulostriate perforator that was recurrent and was supplying the apex of the AVM. Preoperative embolization of the patient's AVM was performed in three stages using Onyx. However, we were unable to catheterize the lenticulostriate recurrent vessel and the apex of the AVM could not be embolized (Fig. 6). A frontal craniotomy up to the midline was performed to expose the AVM, but a frontotemporal craniotomy and a transsylvian approach was added to expose the feeding artery (Video 2). The lenticulostriate feeding artery was temporarily occluded, and we looked for any changes in motor evoked potentials. When none was observed for more than 15 minutes, the vessel was permanently occluded. The AVM was removed completely (Fig. 7). Postoperatively, the patient had mild left hemiparesis, more so on the lower limb. He was discharged to rehabilitation, recovered completely from the hemiparesis in 3 months, and returned to school with normal performance (mRS score, 0).



Patient 2: Young Girl with a Large AVM Bordering the Motor Area

(see video at web site)

An 8-year-old girl presented with recurrent tingling sensations on the left side of the body and weakness of the left arm and leg. She was found to have a Spetzler-Martin Grade V AVM measuring $7.0 \times 4.5 \times 2.8$ cm in size, involving the motor area (Fig. 8). Embolization was aimed at parts of the AVM that were more difficult to manage with surgery: the apex and the posterior part bordering the sensorimotor cortex. Onyx embolization was performed in four sessions over 3 weeks (Fig. 9). The posterior portion of AVM bordering the Rolandic fissure was embolized, but the apex could not be embolized. Resection was elected after multiple discussions with the parents and the patient and other treating physicians because of her young age, which has a greater potential for cerebral plasticity. The AVM was excised completely 4 days after the last stage of embolization. Surgery was still quite difficult, taking approximately 12 hours (Video 3). During the procedure, an intraoperative angiogram was obtained because the surgeon could not be sure about a persisting feeder from a branch of the anterior cerebral artery and the apical vessels supplying the AVM. She had significant left hemiparesis postoperatively. The postoperative angiogram showed a questionable remnant/neovascularization (Fig. 10A). We decided to observe this. She received postoperative rehabilitation, and at follow-up examination 9 months after the surgery, angiography showed complete removal of the AVM (Fig. 10, B and C) with regression of the questionable arteries.



Power in her left arm and leg was 4+/5. She had returned to school and to normal activities including sports (mRS score, 1).

Patient 3: Large AVM in the Basal Ganglia and Deep Frontal Lobe

(see video at web site)

A 52-year-old woman presented with recurrent severe headaches. She was found to have a Spetzler-Martin Grade IV AVM in the right Sylvian fissure, the basal ganglia, and the frontal lobe (Figs. 11 and 12). Embolization was performed with Onyx in four sessions over 4 weeks, aiming at the medial portion of the AVM in the basal ganglia (Fig. 13). Surgery was performed 2 days after the last embolization, and the AVM was removed completely (Video 4). The patient had left hemiparesis postoperatively and had inpatient rehabilitation. At a follow-up examination 8 months after surgery, power in all four limbs was normal, and she had returned to her normal activities and work (mRS score, 1). Angiography 8 months after surgery showed complete obliteration of the AVM (Fig. 14).

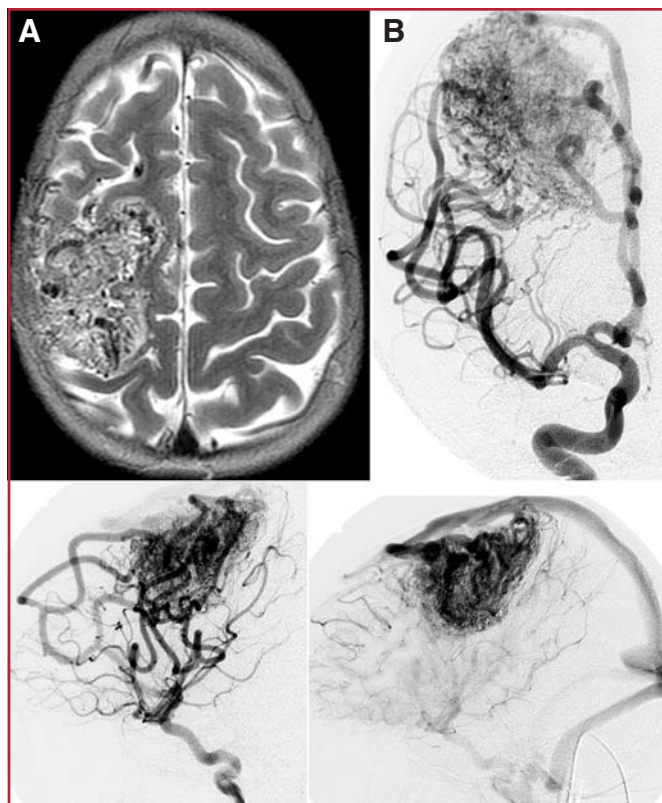


FIGURE 8. Patient 2. **A**, MRI scan showing a 7-cm AVM in the frontal lobe bordering the sensorimotor cortex. **B**, angiograms showing a Spetzler-Martin Grade V AVM.

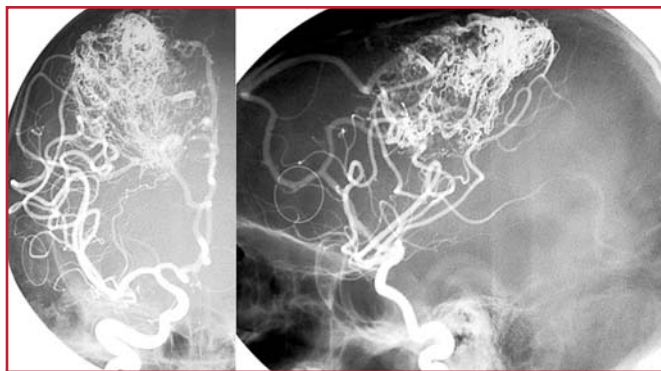


FIGURE 9. Patient 2. Angiograms showing Onyx cast obliterating the posterior portion of the AVM bordering the Rolandic fissure.

DISCUSSION

Treatment Decisions

The principal goal of AVM treatment is the elimination of bleeding risk. Improvement of other symptoms such as headache or seizures is also an additional benefit. Treatment results have to be considered in comparison with the natural

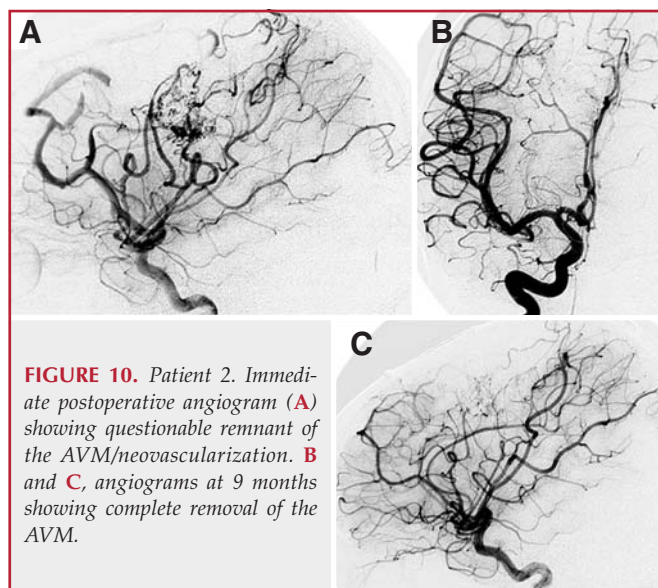


FIGURE 10. Patient 2. Immediate postoperative angiogram (**A**) showing questionable remnant of the AVM/neovascularization. **B** and **C**, angiograms at 9 months showing complete removal of the AVM.

history of AVMs and have to take into account the results of the entire AVM management, including embolization and microsurgery or radiosurgery. In this series of patients, 53% of the patients presented with hemorrhage. The indications for treatment were self-evident in most patients. However, the philosophy for treatment of Grade IV and V AVMs is controversial (2, 13, 14, 19, 20). Several authors believe that the risks of treatment outweigh those of the natural history. In our series, we treated four Grade IV and two Grade V AVMs. In all but one Grade V AVM, the outcome was excellent or good. The two patients with a Grade V AVM were not treated, as they were young and, in one, the AVM was located in the temporo-occipital region.

Advantages of Embolization before Surgery

The goal of embolization in a patient who is to undergo surgical resection is to make the surgery easier. This may be achieved by reduction of intraoperative time or bleeding or by the elimination of difficult surgical areas such as perimotor/sensory and apical regions. By the gradual reduction of the AVM nidus, embolization is also thought to reduce the risk of normal pressure perfusion breakthrough (22, 25, 27, 33, 39, 45, 56). Elimination of difficult areas of the AVM by embolization allows the surgeon to focus on other regions. However, the ideal goal of embolizing the apical regions of the AVM was not achieved in most cases.

Advantages and Disadvantages of Onyx Embolization

Multimodality therapy with Onyx embolization and microsurgical excision allowed us to safely treat large AVMs. The slow-flowing characteristic of Onyx and the surgeon-interventionist collaboration allowed more specific areas of an AVM to be treated. Superselective intranidal or perinidal catheter positions and slow, controlled injections that protect the draining veins make the therapy safe in complex AVMs

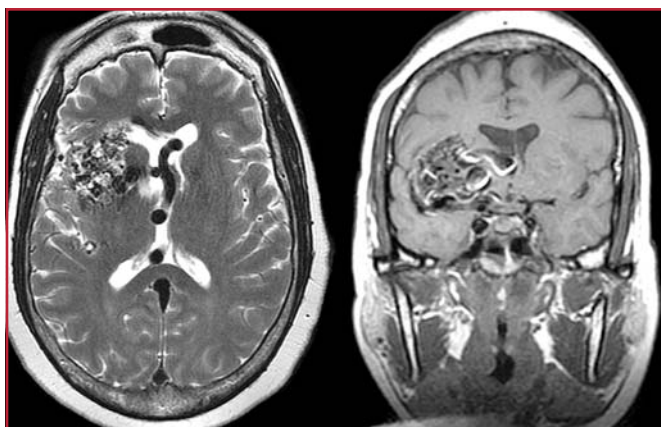


FIGURE 11. Patient 3. MRI scans showing an AVM in the right sylvian fissure and frontal lobe.

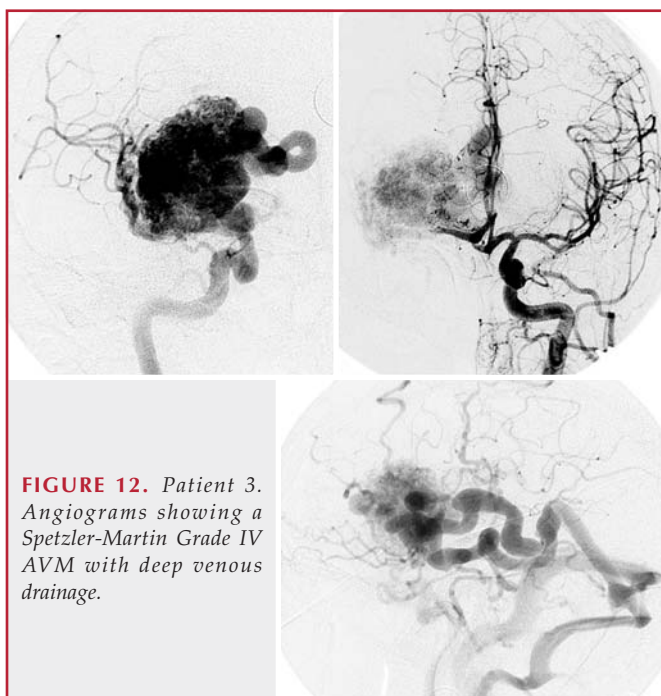


FIGURE 12. Patient 3. Angiograms showing a Spetzler-Martin Grade IV AVM with deep venous drainage.

and critical locations, even in less experienced hands. In our series, the bleed to embolization time was much shorter than previously described. This difference may be attributable to a change in the treating physician's philosophy or to the ability to perform safer embolization earlier after a bleed. The senior author (LNS) believes that there is no advantage during surgical resection after Onyx when compared with NBCA, except that it helps to localize the AVM and identify the brain-AVM interface better. There was no difference in the handling characteristic of Onyx when compared with other embolic agents. A partially obliterated AVM has the same dimensions from the perspective of the surgeon, and the process of resection after Onyx embolization is still complex.

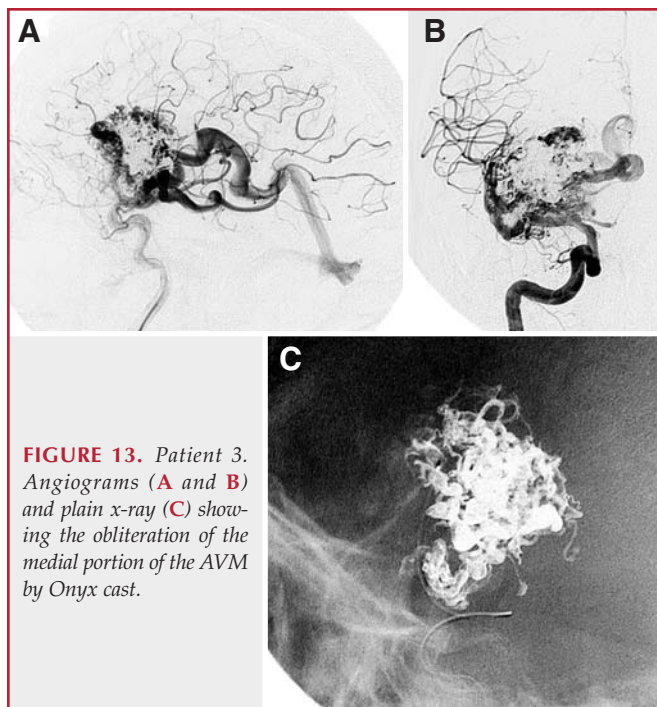


FIGURE 13. Patient 3. Angiograms (A and B) and plain x-ray (C) showing the obliteration of the medial portion of the AVM by Onyx cast.

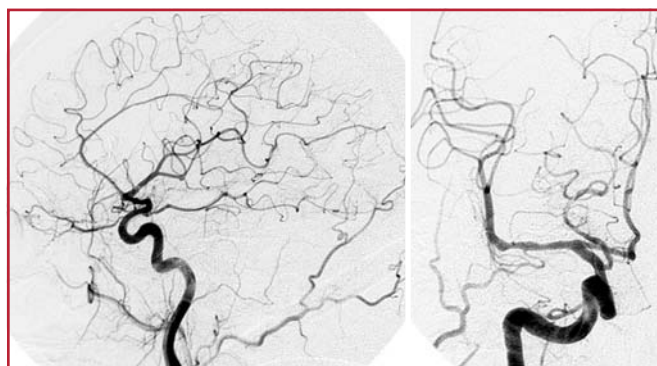


FIGURE 14. Patient 3. Angiograms obtained at the time of follow-up showing complete obliteration of the AVM nidus.

Embolization of intracranial AVMs with ethylene vinyl alcohol-containing embolic agents was first described by Taki et al. (46) and Terada et al. (48) in the early 1990s. The previous reports of treatment of AVMs with Onyx (Table 2) show that our clinical complication and mortality rates are comparable.

The disadvantage of Onyx is the potential for angiototoxicity of DMSO, which is dangerous and sometimes lethal. There was evidence of angiototoxicity in the pathological analysis of our specimens. The potential for dangerous or lethal angiototoxicity is less if the volume of DMSO injected in milliliters is less than half the weight of the patient in kilograms and the speed of DMSO injection is kept at less than 0.1 ml/min. There are potential complications of longer exposure to radiation due to longer injection times. One patient in our group had transient alopecia after Onyx embolization.

TABLE 2. Previously reported series of Onyx/ethylene vinyl alcohol for embolization of arteriovenous malformations^a

Series (ref. no.)	Patients	Embolizing agent	Angiographic cure, no. (%)	Permanent neurological deficit, no. (%)	Mortality, no. (%)
Hamada et al., 2002 (12)	57	EVOH + alcohol	0	3 (5.3)	0
Simonetti et al., 2001 (40)	2	Onyx	1 (50)	NA	NA
Florio et al., 2003 (7)	10	Onyx	2 (20)	1 (10)	NA
Song et al., 2004 (43)	3	Onyx	0	1 (33.3)	0
He et al., 2005 (17)	22	Onyx	3 (13.6)	0	0
Jahan et al., 2001 (21)	23	Onyx	0	9 (4)	0
van Rooij et al., 2007 (51)	44	Onyx	7 (16)	2 (4.6)	1 (2.3)
Weber et al., 2007 (54)	94	Onyx	19 (20); 2 recurrences in 3 mo	9 (9)	0
Mounayer et al., 2007 (32)	53	Onyx + NBCA	26 (49)	5 (8.5)	3 (5.7)
Current study	28	Onyx	6 (21.4)	1 (3.6)	0

^a EVOH, ethylene vinyl alcohol; NA, not available; NBCA, n-butylcyanoacrylate.

Complete Obliteration of the AVM Nidus with Onyx Embolization: Is Surgical Resection Necessary?

Although some interventionists in Europe believe that AVMs can be cured by using Onyx, this agent is not approved for such use in the United States. In our series, six patients had complete obliteration of the AVM nidus after embolization by angiographic criteria. All six patients had their AVMs surgically removed, and the AVMs were found to have residual filling during surgery. This implies that we are overestimating the efficacy of embolization and that AVMs that appear cured on angiography may still require resection. There have been recent series (32, 51, 54) from Europe in which Onyx was the only modality for curative embolizations. In one short-term series (54) with Onyx, two recurrences shown on angiography were evident at the 3-month follow-up examination. Recanalization after embolization with acrylics (4, 8, 11, 28, 33, 54) has been described at the time of long-term follow-up evaluations. Because of lack of long-term follow-up data, no conclusions can be drawn regarding the permanence of occlusion using Onyx. No long-term studies have been performed with regard to toxicity or carcinogenicity of Onyx.

In our pathological study, there was evidence of chronic foreign body giant cells and angioneurosis in 39 and 43% of specimens, respectively, suggesting that Onyx is not inert. There was evidence of recanalization in 18% of specimens, suggesting that there may be angiographic evidence of recurrence if these patients had been followed without surgical resection. Because of these factors, we recommend resection of an AVM despite an apparently complete embolization.

Complications of AVM Embolization

Immediate postembolization complications occurred in four of 55 (7.3%) embolization sessions (four of 28 [14.3%] patients). Three patients had vascular complications with no neurologi-

cal deficit, and one patient had a permanent neurological deficit. Other investigators (3, 9, 15, 16, 21, 24, 26, 31, 34, 35, 44, 47, 49, 50, 53) have reported that death occurred in 0 to 3% and permanent disability in 2 to 20% of patients undergoing embolization. Comparing our own experience with embolization using NBCA, embolization using Onyx has comparable complication rates but allows more controlled embolization of the AVM, even in less experienced hands.

Complications of Multimodality Treatment of AVMs

The complication rate of multimodality treatment of surgery followed by embolization was eight of 28 (28.6%) patients. Of these, five patients had new neurological deficits after surgery and one patient had worsening of deficit caused by embolization (six of 28 [21.4%]). At the time of the 6-month follow-up examination, one patient (3.6%) had a severe deficit and five patients (17.9%) had recovered completely or nearly completely. The mortality rate was one in 34 (3%), and it was attributable to the insult of the initial hemorrhage. In reviewing the literature (3, 4, 7, 12, 21, 26, 31, 35, 51–53) on AVMs, we found a complication rate for a severe deficit of 5.5% and a mortality rate of 2.3% after embolization and surgical resection.

CONCLUSION

With knowledge of the morphological characteristics of AVMs, high occlusion rates and low complication rates are feasible with Onyx and comparable with those of other previous embolic agents. Superselective intranidal or perinidal catheter positions and slow, controlled injections that protect the draining veins make the therapy safe in complex AVMs and critical locations, even in less experienced hands. Large AVMs can be adequately reduced in size for surgical treatment. We recommend resection of an AVM despite apparently complete embolization with Onyx.

Multimodality treatment with microsurgery appears to be safe and feasible after Onyx. Despite treatment of large AVMs in deep locations, the outcomes and complication rates are low and comparable with those reported in previous series. Teamwork and coordination between the surgeon and the interventional neuro-radiologist are important to plan strategies and to have good outcomes with fewer complications in these complex lesions.

REFERENCES

- Chaloupka JC, Huddle DC, Alderman J, Fink S, Hammond R, Vinters HV: A reexamination of the angiotoxicity of superselective injection of DMSO in the swine rete embolization model. *AJNR Am J Neuroradiol* 20:401–410, 1999.
- Chang SD, Marcellus ML, Marks MP, Levy RP, Do HM, Steinberg GK: Multimodality treatment of giant intracranial arteriovenous malformations. *Neurosurgery* 53:1–13, 2003.
- Debrun GM, Aletich V, Ausman JJ, Charbel F, Dujovny M: Embolization of the nidus of brain arteriovenous malformations with n-butyl cyanoacrylate. *Neurosurgery* 40:112–121, 1997.
- DeMerritt JS, Pile-Spellman J, Mast H, Moohan N, Lu DC, Young WL, Hachein-Bey L, Mohr JP, Stein BM: Outcome analysis of preoperative embolization with N-butyl cyanoacrylate in cerebral arteriovenous malformations. *AJNR Am J Neuroradiol* 16:1801–1807, 1995.
- Deveikis JP: Endovascular therapy of intracranial arteriovenous malformations. Materials and techniques. *Neuroimaging Clin N Am* 8:401–424, 1998.
- Fleetwood IG, Steinberg GK: Arteriovenous malformations. *Lancet* 359:863–873, 2002.
- Florio F, Lauriola W, Nardella M, Strizzi V, Vallone S, Trossello MP: Endovascular treatment of intracranial arterio-venous malformations with Onyx embolization: Preliminary experience [in English and Italian]. *Radiol Med (Torino)* 106:512–520, 2003.
- Fournier D, TerBrugge KG, Willinsky R, Lasjaunias P, Montanera W: Endovascular treatment of intracerebral arteriovenous malformations: Experience in 49 cases. *J Neurosurg* 75:228–233, 1991.
- Frizzel RT, Fisher WS 3rd: Cure, morbidity, and mortality associated with embolization of brain arteriovenous malformations: A review of 1246 patients in 32 series over a 35-year period. *Neurosurgery* 37:1031–1040, 1995.
- Gobin YP, Laurent A, Merienne L, Schlienger M, Aymard A, Houdart E, Casasco A, Lefkopoulou D, George B, Merland JJ: Treatment of brain arteriovenous malformations by embolization and radiosurgery. *J Neurosurg* 85:19–28, 1996.
- Gruber A, Ungersböck K, Reinprecht A, Czech T, Gross C, Bednar M, Richling B: Evaluation of cerebral vasospasm after early surgical and endovascular treatment of ruptured intracranial aneurysms. *Neurosurgery* 42:258–268, 1998.
- Hamada J, Kai Y, Morioka M, Kazekawa K, Ishimaru Y, Iwata H, Ushio Y: A mixture of ethylene vinyl alcohol copolymer and ethanol yielding a nonadhesive liquid embolic agent to treat cerebral arteriovenous malformations: Initial clinical experience. *J Neurosurg* 97:881–888, 2002.
- Han PP, Ponce FA, Spetzler RF: Intention-to-treat analysis of Spetzler-Martin grades IV and V arteriovenous malformations: Natural history and treatment paradigm. *J Neurosurg* 98:3–7, 2003.
- Harbaugh RE, Heros RC, Hadley MN: More on ISAT. *Lancet* 361:783–784, 2003.
- Hartmann A, Pile-Spellman J, Stapf C, Sciacca RR, Faulstich A, Mohr JP, Schumacher HC, Mast H: Risk of endovascular treatment of brain arteriovenous malformations. *Stroke* 33:1816–1820, 2002.
- Haw CS, terBrugge K, Willinsky R, Tomlinson G: Complications of embolization of arteriovenous malformations of the brain. *J Neurosurg* 104:226–232, 2006.
- He HW, Jiang CH, Liu HB, Li YX, Zhang JB, Wu ZX: Endovascular treatment of cerebral arteriovenous malformations with Onyx embolization. *Chin Med J (Engl)* 118:2041–2045, 2005.
- Henkes H, Nahser HC, Berg-Dammer E, Weber W, Lange S, Kuhne D: Endovascular therapy of brain AVMs prior to radiosurgery. *Neurol Res* 20:479–492, 1998.
- Hernesniemi JA, Keränen T: Microsurgical treatment of arteriovenous malformations of the brain in a defined population. *Surg Neurol* 33:384–390, 1990.
- Heros RC, Korosue K, Diebold PM: Surgical excision of cerebral arteriovenous malformations: Late results. *Neurosurgery* 26:570–578, 1990.
- Jahan R, Murayama Y, Gobin YP, Duckwiler GR, Vinters HV, Viñuela F: Embolization of arteriovenous malformations with Onyx: Clinicopathological experience in 23 patients. *Neurosurgery* 48:984–997, 2001.
- Jizong Z, Shuo W, Jingsheng L, Dali S, Yuanli Z, Yan Z: Combination of intraoperative embolisation with surgical resection for treatment of giant cerebral arteriovenous malformations. *J Clin Neurosci* 7 [Suppl 1]:54–59, 2000.
- Jung HW, Yoo H, Paek SH, Choi KS: Long-term outcome and growth rate of subtotally resected petroclival meningiomas: Experience with 38 cases. *Neurosurgery* 46:567–575, 2000.
- Kim LJ, Albuquerque FC, Spetzler RF, McDougall CG: Postembolization neurological deficits in cerebral arteriovenous malformations: Stratification by arteriovenous malformation grade. *Neurosurgery* 59:53–59, 2006.
- Kinouchi H, Mizoi K, Takahashi A, Ezura M, Yoshimoto T: Combined embolization and microsurgery for cerebral arteriovenous malformation. *Neurol Med Chir (Tokyo)* 42:372–379, 2002.
- Liu HM, Huang YC, Wang YH: Embolization of cerebral arteriovenous malformations with n-butyl-2-cyanoacrylate. *J Formos Med Assoc* 99:906–913, 2000.
- Luessenhop AJ, Rosa L: Cerebral arteriovenous malformations. Indications for and results of surgery, and the role of intravascular techniques. *J Neurosurg* 60:14–22, 1984.
- Lundqvist C, Wikholm G, Svendsen P: Embolization of cerebral arteriovenous malformations: Part II—Aspects of complications and late outcome. *Neurosurgery* 39:460–469, 1996.
- Martin NA, Khanna R, Doberstein C, Bentson J: Therapeutic embolization of arteriovenous malformations: The case for and against. *Clin Neurosurg* 46:295–318, 2000.
- Mattle HP, Schroth G, Seiler RW: Dilemmas in the management of patients with arteriovenous malformations. *J Neurol* 247:917–928, 2000.
- Meisel HJ, Mansmann U, Alvarez H, Rodesch G, Brock M, Lasjaunias P: Effect of partial targeted N-butyl-cyanoacrylate embolization in brain AVM. *Acta Neurochir (Wien)* 144:879–888, 2002.
- Mounayer C, Hammami N, Piotin M, Spelle L, Benndorf G, Kessler I, Moret J: Nidal embolization of brain arteriovenous malformations using Onyx in 94 patients. *AJNR Am J Neuroradiol* 28:518–523, 2007.
- Murayama Y, Malisch T, Guglielmi G, Mawad ME, Viñuela F, Duckwiler GR, Gobin YP, Klucznick RP, Martin NA, Frazee J: Incidence of cerebral vasospasm after endovascular treatment of acutely ruptured aneurysms: Report on 69 cases. *J Neurosurg* 87:830–835, 1997.
- Nakstad PH, Nornes H: Superselective angiography, embolisation and surgery in treatment of arteriovenous malformations of the brain. *Neuroradiology* 36:410–413, 1994.
- n-BCA Trial Investigators: N-butyl cyanoacrylate embolization of cerebral arteriovenous malformations: Results of a prospective, randomized, multicenter trial. *AJNR Am J Neuroradiol* 23:748–755, 2002.
- Ogilvy CS, Stieg PE, Awad I, Brown RD Jr, Kondziolka D, Rosenwasser R, Young WL, Hademenos G; Special Writing Group of the Stroke Council, American Stroke Association: AHA Scientific Statement: Recommendations for the management of intracranial arteriovenous malformations: A statement for healthcare professionals from a special writing group of the Stroke Council, American Stroke Association. *Stroke* 32:1458–1471, 2001.
- Oliveira E, Sekhar LN: *General Techniques of Arteriovenous Malformation Surgery*. New York, Thieme, 1999.
- Pasqualin A, Barone G, Cioffi F, Rosta L, Scienza R, Da Pian R: The relevance of anatomic and hemodynamic factors to a classification of cerebral arteriovenous malformations. *Neurosurgery* 28:370–379, 1991.
- Pasqualin A, Scienza R, Cioffi F, Barone G, Benati A, Beltramello A, Da Pian R: Treatment of cerebral arteriovenous malformations with a combination of preoperative embolization and surgery. *Neurosurgery* 29:358–368, 1991.
- Simonetti L, Cenni P, de Santis F, Stunale C, Andreoli AF, Calbucci A, Fioravanti A, Leonardi M: Prime esperienze di embolizzazione di MAV cerebrali con Onyx [in Italian]. *Riv Neuroradiol* 14 [Suppl 3]:251–256, 2001.
- Sirin S, Kondziolka D, Niranjan A, Flickinger JC, Maitz AH, Lunsford LD: Prospective staged volume radiosurgery for large arteriovenous malforma-

- tions: Indications and outcomes in otherwise untreatable patients. *Neurosurgery* 58:17–27, 2006.
42. Söderman M, Andersson T, Karlsson B, Wallace MC, Edner G: Management of patients with brain arteriovenous malformations. *Eur J Radiol* 46:195–205, 2003.
 43. Song DL, Leng B, Zhou LE, Gu YX, Chen XC: Onyx in treatment of large and giant cerebral aneurysms and arteriovenous malformations. *Chin Med J (Engl)* 117:1869–1872, 2004.
 44. Sorimachi T, Koike T, Takeuchi S, Minakawa T, Abe H, Nishimaki K, Ito Y, Tanaka R: Embolization of cerebral arteriovenous malformations achieved with polyvinyl alcohol particles: Angiographic reappearance and complications. *AJNR Am J Neuroradiol* 20:1323–1328, 1999.
 45. Spetzler RF, Martin NA, Carter LP, Flom RA, Raudzens PA, Wilkinson E: Surgical management of large AVM's by staged embolization and operative excision. *J Neurosurg* 67:17–28, 1987.
 46. Taki W, Yonekawa Y, Iwata H, Uno A, Yamashita K, Amemiya H: A new liquid material for embolization of arteriovenous malformations. *AJNR Am J Neuroradiol* 11:163–168, 1991.
 47. Taylor CL, Dutton K, Rappard G, Pride GL, Replogle R, Purdy PD, White J, Giller C, Kopitnik TA Jr, Samson DS: Complications of preoperative embolization of cerebral arteriovenous malformations. *J Neurosurg* 100:810–812, 2004.
 48. Terada T, Nakamura Y, Nakai K, Tsuura M, Nishiguchi T, Hayashi S, Kido T, Taki W, Iwata H, Komai N: Embolization of arteriovenous malformations with peripheral aneurysms using ethylene vinyl alcohol copolymer. Report of three cases. *J Neurosurg* 75:655–660, 1991.
 49. Toda N, Ozaki T, Ohta T: Cerebrovascular sensitivity to vasoconstricting agents induced by subarachnoid hemorrhage and vasospasm in dogs. *J Neurosurg* 46:296–303, 1977.
 50. Valavanis A, Yaşargil MG: The endovascular treatment of brain arteriovenous malformations. *Adv Tech Stand Neurosurg* 24:131–214, 1998.
 51. van Rooij WJ, Sluzewski M, Beute GN: Brain AVM embolization with Onyx. *AJNR Am J Neuroradiol* 28:172–178, 2007.
 52. Vinters HV, Lundie MJ, Kaufmann JC: Long-term pathological follow-up of cerebral arteriovenous malformations treated by embolization with bucrylate. *N Engl J Med* 314:477–483, 1986.
 53. Wallace RC, Flom RA, Khayata MH, Dean BL, McKenzie J, Rand JC, Obuchowski NA, Zepp RC, Zabramski JM, Spetzler RF: The safety and effectiveness of brain arteriovenous malformation embolization using acrylic and particles: The experiences of a single institution. *Neurosurgery* 37:606–618, 1995.
 54. Weber W, Kis B, Siekmann R, Kuehne D: Endovascular treatment of intracranial arteriovenous malformations with onyx: Technical aspects. *AJNR Am J Neuroradiol* 28:371–377, 2007.
 55. Yakes WF, Krauth L, Ecklund J, Swengle R, Dreisbach JN, Seibert CE, Baker R, Miller M, VanderArk G, Fullagar T, Prenger E: Ethanol endovascular management of brain arteriovenous malformations: Initial results. *Neurosurgery* 40:1145–1154, 1997.
 56. Zhao M, Charbel FT, Alperin N, Loth F, Clark ME: Improved phase-contrast flow quantification by three-dimensional vessel localization. *Magn Reson Imaging* 18:697–706, 2000.

COMMENTS

Natarajan et al. report on a series of 28 patients treated by endovascular occlusion with Onyx followed by surgical excision. In the 28 patients, they had four complications related to the endovascular procedure, with one patient being left with a left-sided hemiplegia. Two patients experienced adherence of the microcatheters to the cerebral vessel, which were left in situ and identified intraoperatively and extruded at the time of the surgery.

What I am surprised about is that all patients had surgery despite angiographic obliteration. In 21% of their series, or six patients, endovascular therapy resulted in angiographic occlusion; despite this, the patients underwent surgical resection. I submit that it is very reasonable to bring the patient back in 4 to 6 weeks to repeat the angiogram, and if there is shunting, then certainly surgery or radiation

can be contemplated. I see no rationale for operating on all patients despite angiographic cure. Clearly, if these patients were cured angiographically, perhaps the overall management outcome would have even been better than in the current series.

There is no question that Onyx is a relatively safe embolic material and that it does not require the skill and experience as is needed for the use of other liquid acrylic agents. It clearly has gained a role in the armamentarium of multimodality management of brain arteriovenous malformations (AVMs).

Robert H. Rosenwasser
Philadelphia, Pennsylvania

Natarajan et al. present a consecutive series of 28 patients with cerebral AVMs treated with preoperative Onyx embolization and surgical resection. Their series includes four Grade IV AVMs and two Grade V AVMs. Patients in this series did extremely well: there were four transient and one permanent neurological deficit and a wound infection. Six lesions were completely obliterated angiographically after Onyx embolization; although intraoperatively, all lesions were found to have residual filling.

This series contributes to the growing body of evidence supporting the safety and efficacy of Onyx embolization for AVMs. At our institution, we too have found that the slow-flow characteristics of Onyx allow our endovascular team to be more aggressive in embolizing large AVMs, thereby making subsequent resections safer. Moreover, we agree with the authors in underscoring the fact that angiographic obliteration with Onyx embolization is not equivalent to a cure and that surgical resection may still be necessary. More studies with longer follow-up are necessary to further clarify this issue.

Brendan Killory
Robert F. Spetzler
Phoenix, Arizona

Natarajan et al. present a single center series of cerebral AVMs that were adjunctively embolized with Onyx before surgical resection. Twenty-eight lesions were embolized in 55 sessions with a complication rate of 7.3%. Permanent endovascular morbidity was 1.8%. The surgical morbidity was 3.6% at 6 months.

The strength of the article is the emphasis on a multidisciplinary approach, morbidities comparable with those in other studies, the surgical evaluation of “angiographically occult” lesions, and the pathological evaluations of resected lesions. At our center, we have also adopted Onyx as a first-line adjunctive therapy. We have also produced some angiographic “cures.” The comments of Natarajan et al. on the need to resect “angiographically occult” lesions are well timed and supported by the presence of “red veins” during surgical evaluation. A point to discuss is the effect of angiographic cures on those patients who present only with seizures.

Although the outcomes reported are comparable with those of other Onyx series, it would be helpful to read a similar report from the same center on lesions treated with *n*-butylcyanoacrylate. It is important to realize that Onyx is yet another tool and not a replacement for other treatment modalities in the adjunctive therapy of AVMs.

Babu G. Welch
Duke S. Samson
Dallas, Texas

Natarajan et al. report their experience with 28 patients who had intracranial AVMs treated by preoperative embolization with Onyx followed by microsurgical resection. A total of 71 pedicles were

embolized in 55 sessions. The average final AVM nidus obliteration was 74.11%, and total angiographic obliteration was achieved in six patients. Surgical resection was performed in all patients, and an AVM remnant could be identified in each. Complications related to embolization were found in four patients, one of which was caused by embolization of the anterior choroidal artery and resulted in a permanent neurological deficit, one was caused by arterial perforation, and two were caused by a stuck catheter. Complications related to surgery included five temporary neurological deficits, which resolved completely. At 6 months follow-up, 86% of the patients had a modified Rankin Scale (mRS) score of 0 or 1, 7% had a mRS score of 2, and 3.5% had an mRS score of 4. One patient died.

The authors concluded that preoperative embolization with Onyx allows for safe treatment of large AVMs by effectively reducing nidus size and, thus, intraoperative bleeding. This result is provided by the flow characteristics of Onyx, which permit embolization of a more intricate vascular network. They point out the angiotoxicity that might be caused by dimethyl sulfoxide with the use of Onyx and a greater exposure to radiation because of increased injection times. On the other hand, the authors advocate surgical resection of an AVM despite evidence of complete angiographic obliteration after preoperative embolization. Stated reasons include evidence of residual filling during surgery in six of the patients who had complete angiographic obliteration and the potential for recanalization reported in some studies, the lack of adequate follow-up data after embolization with Onyx, and the potential for angiotoxicity demonstrated in this study.

Although this work should not be solely relied on to change treatment paradigms, it does seem to add to a growing number of reports about Onyx, demonstrating that it is safe and effective. The application of Onyx to higher Spetzler-Martin Grade AVMs may also allow for the treatment of some AVMs previously considered untreatable. There are some drawbacks, as the authors point out, such as increased embolization sessions and radiation exposure. Only through more controlled scientific inquiry can we be certain that this material is safe and effective in the long-term for AVM embolization.

An important part of this work is the discussion of the need for, and benefit of, surgeon-interventionalist collaboration. This cannot be overemphasized. Considering that AVM embolization, regardless of the material used, does carry significant risks and that these risks correspond to the number of sessions, number of pedicles embolized, and overall aggressiveness of the approach, only through close collaboration of the members of the neurovascular team can the specific goals of the embolization be realized at the lowest possible risk.

Ziad Hage
Daniel Surdell
H. Hunt Batjer
Chicago, Illinois

This report describes the use of Onyx in the multimodality management of 28 patients with brain AVMs. Those of us who use this embolic agent are generally excited about its performance, but several cautionary comments are in order.

First, this article suggests that Onyx embolization reduces AVM size and makes surgical resection easier. However, an AVM nidus that is nearly obliterated by Onyx still has the same anatomical dimensions as without embolization, and microsurgical dissection must progress through the same tissue planes. Furthermore, there are many other important factors besides size that influence the safety and ease of resection, including AVM location, eloquence, deep per-

forating artery supply, hemorrhagic presentation, margins (compact versus diffuse), and patient age. Onyx embolization has no impact on these other factors either.

Second, although not stated explicitly, this article suggests that Onyx embolization will enable us to tackle tougher AVMs and still achieve excellent clinical outcomes. Seven AVMs (25%) in this series were high-grade lesions (Spetzler-Martin Grade IV or V), and only one of these patients had a poor outcome (mRS score <2). However, Onyx is no substitute for surgical skill. The outstanding results in this report reflect the expertise of Dr. Sekhar rather than the properties of Onyx. Even in his skilled hands, five of the seven patients with high-grade AVMs had new, significant deficits resulting from treatment. The recovery observed in these patients was equally significant, but in three patients some treatment-related neurological symptoms remained (mRS score 1 or 2). It is worth considering these results to emphasize the fact that no matter how good the neurosurgeon or how injected the nidus, high-grade AVMs are associated with significant surgical morbidity that may not be counted in our calculus of outcome reporting but leaves patients who were neurologically normal at the beginning of treatment less than normal afterwards. I think it is advisable to treat high-grade AVMs conservatively, even as our embolic agents improve.

Finally, for AVM surgeons who feared that Onyx would put an end to AVM surgery, this report demonstrates that angiography overestimates the efficacy of embolization. All six AVMs deemed to be occluded completely had residual filling at the time of surgical resection. In addition, AVMs embolized with Onyx had a recanalization rate of 14%, on the basis of pathological evidence in four specimens. Therefore, no matter how impressive the postembolization angiograms look, we should operate and finish the job, even with endovascularly "cured" AVMs.

Michael T. Lawton
San Francisco, California

This is a single center study in which the senior author reviews his experience with 28 patients treated with Onyx and subsequent surgical resection. Natarajan et al. do an admirable job of evaluating the AVMs on the basis of size, volume, number of embolizations, percent obliteration by embolization, the timing of all procedures, and intraprocedural complications, blood loss, and complications related to the surgery at 6 months. The important points to be raised include the lack of any difference between complication rates when *n*-butylcyanoacrylate or Onyx is used. We all recognize that Onyx is a more user-friendly agent. In addition to this, the complication rate after treatment with Onyx versus *n*-butylcyanoacrylate and surgical manipulation is also quite similar. Therefore, it remains unclear as to whether Onyx is an agent superior to those used previously. The authors do an excellent job of describing their treatment strategy, which in most cases is standard therapy. The authors also review several patients with Grade IV and V AVMs. This is obviously a controversial topic, which should be addressed at centers that deal with large numbers of AVMs.

Overall, the authors' results are excellent. This article emphasizes the need for an organized team of physicians including endovascular surgeons, neurosurgeons, neurologists, intensivists, and anesthesiologists, all playing an equal part in the diagnosis, decision to treat, and management of the patient perioperatively. It is clear that the best outcomes occur in institutions that have organized teams such as the one in this article treating a high volume of patients.

Philip E. Stieg
New York, New York