

# Development of Spontaneous Subdural Hematoma and Bone Marrow Depression after Hydroxyethyl Starch Administration

DANIEL CHAPPELL, MD,\* WALTRAUD BRUCHELT, MD,\* WILFRIED SCHENK, MD, MATTHIAS JACOB, MD, KLAUS HOFMANN-KIEFER, MD, PETER CONZEN, MD, UWE KREIMEIER, MD, AND MARKUS REHM, MD

**A**lthough hydroxyethyl starch (HES) solutions are known to interfere with hemostasis, the various available HES preparations are frequently used in clinical practice for volume therapy and to improve blood rheology.<sup>1</sup> We report a serious hemostatic disturbance in a 17-month-old toddler after the infusion of 6% HES 450/0.72 over 10 days, resulting in cutaneous bleeding and subdural hematoma necessitating surgical intervention. In addition, severe pruritis occurred, and histiocytes with hydroxyethyl starch-associated vacuoles were found in aspirated bone marrow, combined with severe hyporegenerative anemia and thrombopenia.

## CASE REPORT

A 17-month-old, previously healthy boy (89 cm, 12.1 kg) was treated with intravenous cefotaxime and dexamethasone for pneumococcal meningitis. At the end of therapy, acute deafness occurred and was treated according to the Stennert-scheme (dextran 40, cortisone, and pentoxifylline),<sup>2</sup> but modified to 6% HES 450 kDa/0.72 (Plasmasteril; Fresenius, Bad Homburg, Germany) instead of dextran to benefit from the prolonged drug effect. The cumulative amount of HES administered over 10 days was 2500 mL (1.2 g/kg/d). Two days after completion of therapy, several hematomas appeared on the boy's head, back, and lower extremities. Results of laboratory tests performed on day 2 after HES administration showed profound anemia, which was treated by red blood cell transfusion. Results of coagulation tests were severely abnormal (Table). Three days after the last HES administration, the patient became somnolent and had development of anisocoria. A magnetic resonance imaging scan showed a subacute, right-sided subdural hematoma (>2.5 cm, temporoparietal, Figure 1), which was immediately evacuated. Repeated bleeding was detected in a postoperative scan, necessitating revision surgery on the same night. Despite perioperative substitution of red blood cells, platelet concentrate, and fresh frozen plasma, the coagulation disturbance persisted (Table).

The observed factor VIII deficiency was treated for 24 days after surgery with a continuous infusion of up to 15 IU/kg/h of factor VIII:C and von Willebrand factor (vWF):RCoF (Haemate; CLS Bering, Marburg, Germany) until laboratory measures of factor VIII activity normalized. Development of unexplained hepatosplenomegaly, hyporegenerative anemia, and thrombocytopenia led to bone marrow aspiration. This showed no evidence of malignancy, although numerous storage cells with vacuoles, a maturation-arrest of granulopoiesis, an increased number of megakaryocytes, and a dysplastic erythropoiesis were present (Figure 2; available at [www.jpeds.com](http://www.jpeds.com)). Highly elevated HES concentrations were measured in the plasma throughout treatment. HES was detectable in the boy's plasma 6 months after treatment (Table), indicating highly prolonged accumulation. Severe pruritis, a characteristic side effect of HES,<sup>3</sup> occurred 25 days after the last HES application and was successfully treated with intravenously and topically applied diphenhydramine. There were no signs of impaired renal function. The boy was discharged in good general condition. Labyrinthine deafness persisted, but there were no other neurologic deficits.

## DISCUSSION

Serious hemostatic complications and bone marrow depression developed in a 17-month-old boy after a 10-day infusion of 6% HES 450/0.72 administered at recommended doses. Our findings of severe factor VIII deficiency, decreased activity of vWF:RiCO (ristocetin cofactor) after HES administration, and the fact that bleeding persisted until the specific therapy with factor VIII/vWF concentrate (Haemate) was initiated

From the Clinic of Anesthesiology, Ludwig-Maximilians University Munich (D.C., W.B., M.J., K.H., P.C., U.K., M.R.), Munich, and the Department of Pediatrics, Central Clinic of Augsburg (W.S.), Augsburg, Germany.

\*Drs. Chappell and Bruchelt contributed equally to this work.

This study was performed using departmental money from the Ludwig-Maximilians University of Munich, Germany.

Submitted for publication Feb 5, 2008; last revision received Mar 27, 2008; accepted Apr 30, 2008.

Reprint requests: Dr. Daniel Chappell, Clinic of Anesthesiology, Ludwig-Maximilians University Munich, Nussbaumstrasse 20, 80336 Munich, Germany. E-mail: [daniel.chappell@med.uni-muenchen.de](mailto:daniel.chappell@med.uni-muenchen.de).

J Pediatr 2008;153:579-81

0022-3476/\$ - see front matter

Copyright © 2008 Mosby Inc. All rights reserved.

10.1016/j.jpeds.2008.04.073

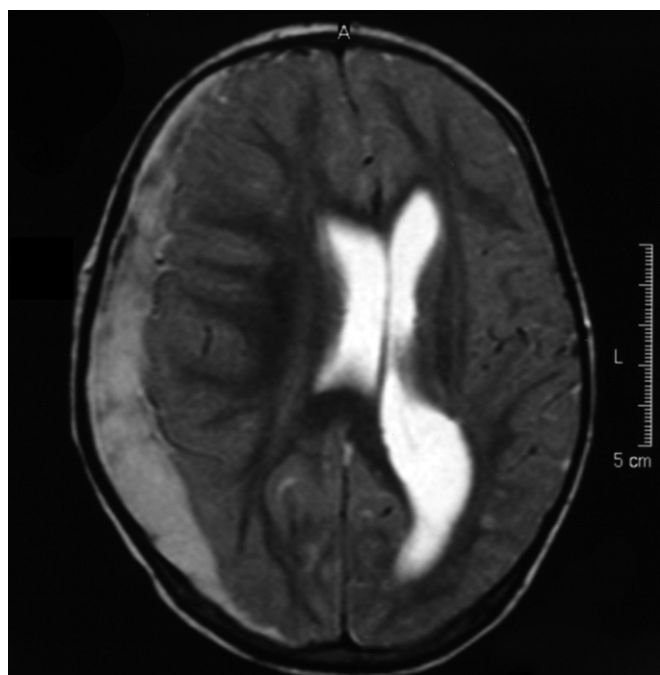
HES	Hydroxyethyl starch	vWS	Von Willebrand syndrome
vWF	Von Willebrand factor		

**Table. Laboratory parameters**

Days after administration of HES	Admission	2	3	4	10	18	27	68	186	Normal values
White blood cells [ $\times 10^9/L$ ]	7.8			6.1	8.6	8.8	6.9	6.8		6-15
Red blood cells [ $\times 10^{12}/L$ ]	4.35			3.45	2.44	3.24	3.66	3.89		3.7-5.3
Hematocrit [%]	36			28	22	26	33	36		35-43
HES [g/dL]				2.16			1.83	0.74	0.29	0
Quick [%]	109	41	47	66	72	80	95	92		70-100
PTT [sec]	32	90	79	136	46	40	38	36		20-38
Factor VIII:C [%]				38	54	67	85	97		70-200
Factor IX [%]				49			86	102		70-110
Factor XI [%]				34			71	82		70-120
vWF:RiCO [%]				26	106	112	110	102		50-150
Bleeding time [sec]				>300	196	169	176	155		<180
Platelets [ $\times 10^9/L$ ]	322			174	128	119	93	341		150-350
Hemoglobin [g/dL]		8.1	5.9	9.7			6.1	10.3		10.7-13.1
Reticulocytes [%]				0			2.57	4.75		1-13
Fibrinogen [mg/dL]				108			165	210		150-350
ATIII [%]			60	61			83	97		80-120
D-Dimer [ng/mL]				819			430	322		<500

PTT, Partial thromboplastin time; vWF:RiCO, von Willebrand ristocetin cofactor; ATIII, antithrombin III.

Admission day was before starting the HES application. On day 2 after HES administration, a cutaneous hematoma occurred. In the evening of day 3, anisocoria was noticed and MRT scanning revealed subdural bleeding, which resulted in emergency craniotomy. Laboratory measurements on day 4 were obtained after revision surgery, during which transfusion of platelets, red blood cells, and fresh frozen plasma was performed. Haemate therapy was started on day 4 and discontinued on day 28.



**Figure 1.** Magnetic resonance imaging scan of the head demonstrates a subacute, right-sided subdural temporoparietal hematoma (>2.5 cm).

strongly suggests a HES-associated von Willebrand-like syndrome as the underlying reason for development of subdural hematoma and cutaneous bleeding.

HES exerts pleiotropic effects on coagulation, including reductions in factors, decreased number and function of platelets, and increased fibrinolysis.<sup>4</sup> Various HES solutions spe-

cifically impair fibrinogen/fibrin polymerization.<sup>5</sup> In addition, HES solutions impair platelet reactivity by reducing the availability of the platelet fibrinogen receptor glycoprotein IIb/IIIa and by decreasing platelet-linking properties of vWF.<sup>1,6,7</sup>

It has been reported before that the decline of vWF after HES infusion is greater than can be explained by simple hemodilution and a decrease of coagulation factor VIII and vWF by up to 80% in healthy volunteers<sup>6</sup> and in patients,<sup>7</sup> even when used below the recommended daily amounts.<sup>6</sup> At admission our patient showed normal routine coagulation test results, especially activated partial thromboplastin time results within the normal range (Table), and specific laboratory workup after recovery excluded possibly unknown von Willebrand syndrome (vWS) Type 1, which would have been aggravated by the administration of HES. Because meningitis was the underlying cause, the observed bleeding could also have been provoked by an infection-associated acquired vWS. Acquired vWS is a rare bleeding disorder and describes a very complex syndrome usually occurring in patients with myeloproliferative and cardiocirculatory disease and mostly classified as von Willebrand disease type IIa.<sup>8</sup> The ultimate diagnosis is made by the lack of multimers of the vWF because frequently vWF:Ag and sometimes also vWF:RiCo can be reduced or even normal.<sup>9</sup> In our patient, bleeding occurred in the late course of meningitis during appropriate therapy, thus an underlying infection-related acquired vWS seems very unlikely.

The indication for the HES infusion reported on here was acute deafness occurring after pneumococcal meningitis. The Stennert scheme has proved to be safe and effective<sup>2</sup> but

in this case was modified from dextran 40% to 6% HES 450/0.72. This high molecular colloid with a high substitution degree was administered in expectation of greater and longer enduring plasma persistence. However, the daily amount of 1.2 g/kg corresponded to the recommended daily maximum dose. Dextran is rarely used because of its pronounced effects on hemostasis and considerable high incidence of anaphylactic reactions.<sup>10</sup> HES is well known to persist in a minimal remaining quantity for several months<sup>11</sup> and is by no means restricted to high molecular-weight colloids. Serum concentrations were measured by the hexokinase method as previously described.<sup>12</sup> However, serum concentrations of HES detected here were higher than measured after an acute normovolemic hemodilution performed before surgery in young children by applying  $1469 \pm 246$  mL of HES 200/0.5:2.16 versus  $1.95 \pm 0.5$  g/dL.<sup>13</sup> Elimination of HES is known to be impaired with increasing molecular weight, grade of substitution, C2/C6 ratio, and concentration and it can, therefore, accumulate.<sup>14</sup> Repeated application of HES has been shown to impede macromolecule elimination, causing an accumulation of molecules and leading to an increase of the serum concentration.<sup>15</sup> This evidently occurred, because much higher HES concentrations were measured in the patient's plasma than previously reported.<sup>14</sup> Even after 6 months significant HES values were still detectable in plasma. Accumulation of HES is believed to increase complex formation and clearance of factor VIII and vWF.<sup>16</sup> After infusion of HES, previous studies have shown vacuolation in perivascular histiocytes of the skin and in other mononuclear cells<sup>17</sup> and a nearby accumulation of radioactively labeled HES. However, this is the first report of vacuolation in the bone marrow in combination with prolonged accumulation of HES in blood plasma, severe hyporegenerative anemia, and thrombocytopenia.

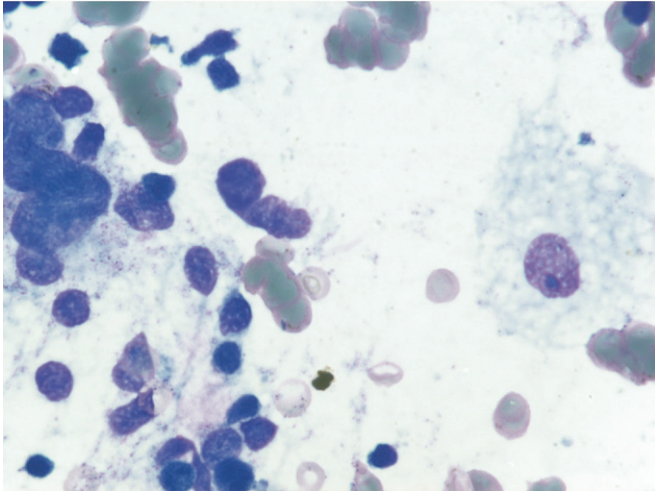
HES tissue deposition has been shown to lead to major organ dysfunction, for example, in the liver.<sup>18</sup> The HES storage in the bone marrow might have caused myelosuppression; however, platelets were not reduced to levels associated with spontaneous bleeding, platelet function was not assessed, and FVIII/vWF synthesis is not related to the bone marrow.

Our case report shows several severe hemostatic complications after infusion of high molecular-weight hydroxyethyl starch. In view of these observed possibly HES-related side effects, such intravenous solutions, and especially high

molecular-weight highly substituted HES, should be used with caution, and regular and appropriate monitoring of coagulation seems mandatory if prolonged administration is necessary.

## REFERENCES

1. Kozek-Langenecker SA. Effects of hydroxyethyl starch solutions on hemostasis. *Anesthesiology* 2005;103:654-60.
2. Michel O, Jahns T, Joost-Ennekling M, Neugebauer P, Streppel M, Stennert E. The Stennert antiphlogistic-rheologic infusion schema in treatment of cochleovestibular disorders. *HNO* 2000;48:182-8.
3. Bork K. Pruritis precipitated by hydroxyethyl starch: a review. *Br J Dermatol* 2005;152:3-12.
4. de Jonge E, Levi M. Effects of different plasma substitutes on blood coagulation: a comparative review. *Crit Care Med* 2001;29:1261-7.
5. Mittermayr M, Streif W, Haas T, Fries D, Velik-Salchner C, Klingler A, et al. Hemostatic changes after crystalloid or colloid fluid administration during major orthopedic surgery: the role of fibrinogen administration. *Anesth Analg* 2007;105:905-17.
6. de Jonge E, Levi M, Buller HR, Berends F, Kesecioglu J. Decreased circulating levels of von Willebrand factor after intravenous administration of a rapidly degradable hydroxyethyl starch (HES 200/0.5/6) in healthy human subjects. *Intensive Care Med* 2001;27:1825-9.
7. Jones SB, Whitten CW, Despotis GJ, Monk TG. The influence of crystalloid and colloid replacement solutions in acute normovolemic hemodilution: a preliminary survey of hemostatic markers. *Anesth Analg* 2003;96:363-8.
8. Sadler JE, Budde U, Eikenboom JC, Favaloro EJ, Hill FG, Holmberg L, et al. Update on the pathophysiology and classification of von Willebrand disease: a report of the Subcommittee on von Willebrand factor. *J Thromb Haemost* 2006;4:2103-14.
9. Nitu-Whalley IC, Lee CA. Acquired von Willebrand syndrome-report of 10 cases and review of the literature. *Haemophilia* 1999;5:318-26.
10. Barron ME, Wilkes MM, Navickis RJ. A systematic review of the comparative safety of colloids. *Arch Surg* 2004;139:552-63.
11. Boon JC, Jesch F, Ring J, Messmer K. Intravascular persistence of hydroxyethyl starch in man. *Eur Surg Res* 1976;8:497-503.
12. Rehm M, Haller M, Orth V, Kreimeier U, Jacob M, Dressel H, et al. Changes in blood volume and hematocrit during acute preoperative volume loading with 5% albumin or 6% hetastarch solutions in patients before radical hysterectomy. *Anesthesiology* 2001;95:849-56.
13. Aly HA, Lochbuehler H, Frey L, Messmer K. Global tissue oxygenation during normovolaemic haemodilution in young children. *Paediatr Anaesth* 1997;7:197-204.
14. Jungheinrich C, Neff TA. Pharmacokinetics of hydroxyethyl starch. *Clin Pharmacokinet* 2005;44:681-99.
15. Treib J, Haass A, Pindur G, Seyfert UT, Treib W, Grauer MT, et al. HES 200/0.5 is not HES 200/0.5. Influence of the C2/C6 hydroxyethylation ratio of hydroxyethyl starch (HES) on hemorrhheology, coagulation and elimination kinetics. *Thromb Haemost* 1995;74:1452-6.
16. Jonville-Bera AP, Utret-Leca E, Gruel Y. Acquired type I von Willebrand's disease associated with highly substituted hydroxyethyl starch. *N Engl J Med* 2001;345:622-3.
17. Sirtl C, Laubenthal H, Zumbobel V, Kraft D, Jurecka W. Tissue deposits of hydroxyethyl starch (HES): dose-dependent and time-related. *Br J Anaesth* 1999;82:510-15.
18. Christidis C, Mal F, Ramos J, Senejoux A, Callard P, Navarro R, et al. Worsening of hepatic dysfunction as a consequence of repeated hydroxyethylstarch infusions. *J Hepatol* 2001;35:726-32.



**Figure 2.** Bone marrow smear reveals numerous storage cells with vacuoles, a maturation-arrest of granulopoiesis, an increased number of megakaryocytes, and dysplastic erythropoiesis.