

Multiple Aneurysms of the Distal Posterior Inferior Cerebellar Artery: Two Case Reports

Authors

B. Demirgil, Ö. Günaldi, B. Tugcu, L. Postalci, B. Colluoglu, O. Tanriverdi, M. Asilturk

Affiliation

Bakırköy Research and Training Hospital for Neurology, Neurosurgery and Psychiatry, 2nd Neurosurgery Clinic, Istanbul, Turkey

Key words

- distal posterior inferior cerebellar artery
- aneurysm
- multiple aneurysms

Abstract



Introduction: The distal segment of the PICA (posterior inferior cerebellar artery) is a very rare localization for the occurrence of intracranial aneurysms. They are almost always presented with SAH (subarachnoid hemorrhage). Hydrocephalus often develops following intraventricular hemorrhage (IVH). The distal PICA segment is a quite difficult localization for neurosurgical procedures. The authors could not find any case report presenting multiple aneurysms on a distal segment of PICA in the literature.

Case 1: A 62-year-old male patient was admitted to the emergency room with complaints of sudden headache, vomiting and blackout of consciousness. Early CT scans demonstrated SAH and intraventricular hemorrhage (IVH). In his medical history, SAH had been determined in our clinic 3 month previously. He had carried out conservative treatment ever since the distal located PICA aneurysm had been determined. There was no determined symptom except for moderate neck stiffness in his physical examination. In his neurological examination, he was stuporous and he localized the pain in his left arm. A ventriculo-atrial shunt operation was performed after the external ventricular drainage which was applied at the acute period of hydrocephalus in his previous SAH. Both of the left distal PICA aneurysms were clipped via a left lateral suboc-

cipital craniotomy. The patient was discharged from the hospital without neurological deficit in the seventh day postoperatively. His control examination was normal and there was not any fixed pathological filling in the control cerebral digital subtraction angiography (DSA).

Case 2: A 49-year-old female patient was admitted to the emergency service with the complaint of headache, dizziness and vomiting. She was neurologically intact except for neck stiffness. A cranial CT demonstrated triventricular hydrocephalus and a hemispheric cerebellar hematoma, which was about 1 × 1.5 cm in diameter. The cerebellar DSA was normal. The patient was discharged with no neurological impairment. In the examination of the control cerebral DSA, two aneurysmatic fillings were determined in the distal segments of right posterior inferior cerebellar artery (PICA). Both of the aneurysms were clipped through a microsurgical approach. No neurological deficit was determined in the postoperative early and late stages. In the control cerebral DSA, no aneurysmatic filling was seen.

Discussion: Distal PICA aneurysms constitute only 0.28–1.4% of all intracranial aneurysms. Most of the patients present with SAH and along with this; intraventricular hemorrhage is seen and later on, hydrocephalus develops. As for treatment, surgery and endovascular interference methods can be applied.

Bibliography

DOI 10.1055/s-0028-1082302
Minim Invas Neurosurg 2008;
51: 249–252
© Georg Thieme Verlag KG
Stuttgart · New York
ISSN 0946-7211

Correspondence

Dr. Ö. Günaldi

Atakent mah
İkitelli cad
İhlamurevleri B2 blok No:10
Halkalı/Küçükçekmece
İstanbul
Turkey
Tel.: +90/212/543 86 67
gunaldi@mynet.com

Introduction



The PICA is an uncommon localization for intracranial aneurysms and distal PICA aneurysms are particularly rare. They almost always present with SAH. Hydrocephalus often develops following intraventricular hemorrhage. The distal PICA segment is a quite difficult localization for neurosurgical procedures. Because of the narrowing of

the arterial diameter, endovascular procedures are not suitable for aneurysms of this region. False negative DSA results are another problem from the point of diagnosis [1,2].

The authors present two cases of multiple aneurysms localized on a single PICA distal segment.

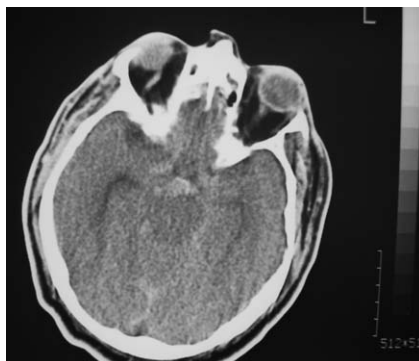


Fig. 1 Cranial computed tomography revealed subarachnoid hemorrhage in the posterior fossa.

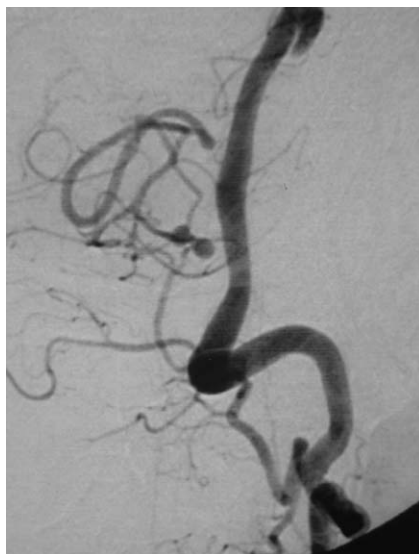

Fig. 2 Two small saccular aneurysms were demonstrated on the digital subtraction angiography.

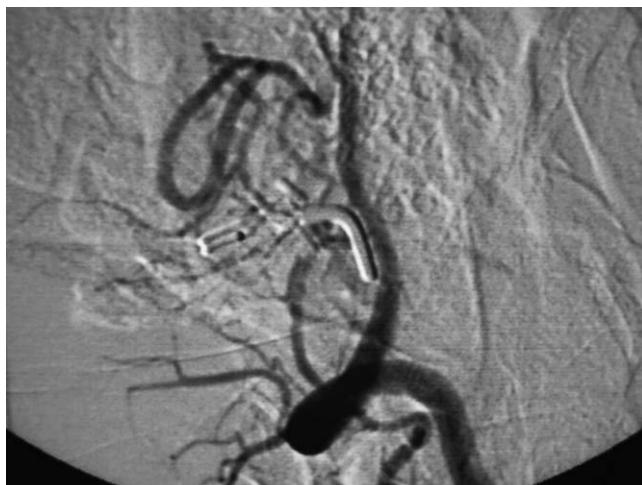

Fig. 3 Control digital subtraction angiography demonstrated no aneurysmatic fillings.

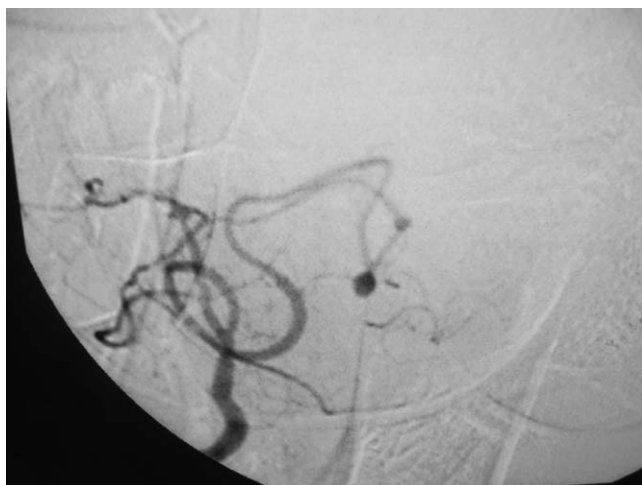

Fig. 4 Digital subtraction angiography after one month from the first bleeding demonstrated two small aneurysmatic fillings located at the right PICA distal segment.

Case Reports

Patient 1

History and examination

A 62-year-old male was admitted to the emergency room with the complaints of sudden headache, vomiting and disturbance of consciousness.

Treatment and post-treatment course

On neurological examination, he was stuporous. He had hemiplegia on the right side. A cranial CT examination demonstrated posterior fossa SAH (● Fig. 1). A cerebral DSA examination showed two small saccular aneurysms localized at the left distal segment of the PICA (● Fig. 2). Because of developing hydrocephalus in his clinical and radiological follow-up, an external ventricular drainage was inserted and the patient underwent a surgical procedure for clipping both aneurysms via a left lateral suboccipital craniotomy, following a ventriculoatrial shunt procedure. The patient was discharged from the hospital at postoperative seventh day. He was neurologically intact. Cerebral DSA performed in the follow-up period, was unremarkable (● Fig. 3).

Patient 2

History and examination

The second patient, a 49-year-old female was admitted with complaints of headache, dizziness and vomiting. She had no neurological deficit but cranial CT demonstrated a triventricular hydrocephalus and a 1×1.5 cm sized hemispheric cerebellar

hematoma related to the fourth ventricle. DSA analysis showed no vascular abnormality so she was discharged from the hospital following a ventriculo-peritoneal shunt operation. She was neurologically intact. A control DSA was performed 1 month later. Two small aneurysmatic fillings located at right PICA distal segment were seen in the DSA (● Fig. 4).

Treatment and post-treatment course

The aneurysms were clipped via a midline suboccipital craniotomy. She was discharged from hospital as neurologically intact following a control DSA (● Fig. 5).

Discussion

The PICA may show a very high rate variations according to the localizations that its origin takes. It usually originates from the intradural vertebral artery (VA). However, a PICA originating from the extradural VA may rarely be seen [3,5–8]. Variations that take an origin below the foramen magnum level are seen in about 18% of all cases [9]. The PICA consists of six anatomic segments, namely: anterior, lateral, posterior medullar segments,

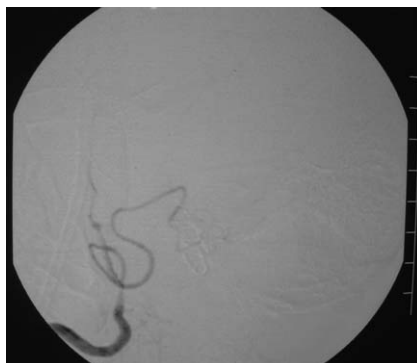

Fig. 5 Control digital subtraction angiography demonstrated no aneurysmatic fillings.

tonsillomedullar, telovelotonsillar and cortical segments [10]. Distal PICA aneurysms are particularly rare. It is reported that their observation rate is about 0.28–1.4% among all cerebral aneurysms [1]. The VA-originated aneurysms appear in the PICA in 80% and usually in the VA-PICA division point. And this rate is lower in the distal area. 15–30% of all PICA aneurysms are seen in the distal part and especially in the peripheral PICA segments [2]. Although in some series, the distal segment PICA aneurysm incidence is higher in the telovelotonsillar and tonsillomedullar segments [1], it is reported that, in a 16-case-series which comprises 18 aneurysms, the incidence is higher in the anterior medullar segment [11]. It is thought that hemodynamic stress and congenital factors play role in the occurrence of distal PICA aneurysms [12].

Most of the cases present with SAH [4]. Compared with other intracranial aneurysms they have a higher incidence of IVH and hydrocephalus. In ruptured PICA aneurysms, the re-bleeding risk is about 78% which is considerably high [13, 14]. In the cases reported by Sadato, IVH is seen in 85% of distal PICA aneurysm hemorrhages. In Kallmes's report [11], it is stated that in the 95% of the PICA aneurysms with IVH, hydrocephalus developed. 75% of these cases are graded as 4, according to the Fisher grading scale. In the present study, two aneurysms in one distal PICA segment were determined for each patient. SAH, IVH and accompanying hydrocephalus were determined. In the first case, a conservative approach was applied because of the patient having refused the surgical approach, but one month later; he presented with SAH along with intraventricular hemorrhage and in a short time hydrocephalus developed. In the second case; SAH, IVH and hydrocephalus were existing at the first admission of the patient to our hospital. No aneurysm had been seen in the first cerebral DSA but an aneurysm was seen in the control DSA examination. AVM (arteriovenous malformations), dural fistula, hypoplastic vertebral artery and cerebral aneurysms in further areas may accompany distal PICA aneurysms [11]. In the present cases, no additional pathology was found that accompanied the aneurysm. Microsurgical clipping or coil occlusion [4, 15–17] of the main arteries which the aneurysm is located on, has been used by many authors. Some others have combined the occlusion of the main arteries with distal bypass procedures [16–19]. Nussbaum has emphasized the significance of the PICA-PICA or PICA-OA anastomoses used in the dissection of the distal PICA. The surgical treatment of PICA aneurysms is quite difficult [20, 21]. In PICA aneurysms, surgeons have to use surgical dissection corridors with deep, narrow trajectories that are intimately involved with perforating brainstem arteries and cranial nerves [22–24]. However, in the diagnosis and the treatment of the disease, crucial improvements are recorded in the latest report of the past 5

years [11, 20, 25–27]. The literature contains rare reports of distal PICA aneurysms treated by an endovascular approach. The distal PICA aneurysm location and vascular tortuosity may make it impossible to superselectively catheterize the PICA for effective coil deployment. Furthermore, compared with endovascular treatment, open surgery may serve to remove subarachnoid blood. In the present cases, the aneurysms were clipped successfully via a suboccipital craniotomy. Postoperatively, no neurosurgical deficit was seen in the early and late stages. In the control DSA which was made 3 months later, no occlusion findings were observed in the distal part of the aneurysm and the clipped segment.

Conclusion



Distal PICA aneurysms are extremely rare and comprise less than 30% of all PICA aneurysms [1, 2]. The authors found only one case report presenting multiple aneurysms on a single PICA distal segment [28]. Both of the patients we described were symptomatically similar to a posterior fossa circulation SAH. Because there is not enough experience reported in the literature, two alternative microsurgical approaches were performed for the treatment, namely one lateral and one midline suboccipital craniotomy. The present report aims to add new knowledge to the literature about these very unique and rare types and localizations of intracranial aneurysms.

References

- 1 Tamano Y, Kobayashi T, Hagiwara S et al. Aneurysm of the distal posterior inferior cerebellar artery originating from the extracranial and extradural vertebral artery. *Neurol Med Chir (Tokyo)* 2003; 43: 301–303
- 2 Ishikawa T, Suzuki A, Yasui N. Distal posterior inferior cerebellar aneurysms – report of 12 cases. *Neurol Med Chir (Tokyo)* 1990; 30: 100–108
- 3 Bertalanffy H, Seeger W. The dorsolateral, suboccipital, transcondylar approach to the lower clivus and anterior portion of the craniocervical junction. *Neurosurgery* 1991; 19: 29
- 4 Liew D, Ng PY, Ng I. Surgical management of ruptured and unruptured symptomatic posterior inferior cerebellar artery aneurysms. *Br J Neurosurg* 2004; 18: 608–612
- 5 Lister JR, Rhoton AL Jr, Matsushima T et al. Microsurgical anatomy of the posterior inferior cerebellar artery. *Neurosurgery* 1982; 10: 170–199
- 6 Margolis MT, Newton TH. The posterior inferior cerebellar artery. In: Newton TH, Potts DG, eds. *Radiology of the Skull and Brain*. St Louis: Mosby 1974; Vol. 2 Bk 2: 1719–1775
- 7 Osborn AG. *Introduction to cerebral angiography*. Philadelphia: Harper & Row 1980; 379–427
- 8 Sen CN, Sekhar LN. An extreme lateral approach to intradural lesions of the cervical spine and foramen magnum. *Neurosurgery* 1990; 27: 197–204
- 9 Horiuchi T, Tanaka Y, Hongo K et al. Characteristics of distal posterior inferior cerebellar artery aneurysms. *Neurosurgery* 2003; 53: 589–595; discussion 595–596
- 10 Lister JR, Rhoton AL Jr, Matsushima T et al. Microsurgical anatomy of the posterior inferior cerebellar artery. *Neurosurgery* 1982; 10: 170–199
- 11 Orakcioglu B, Schuknecht B, Otani N et al. Distal posterior inferior cerebellar artery aneurysms: Clinical characteristics and surgical management. *Acta Neurochir (Wien)* 2005; 147: 1131–1139
- 12 Todaka T, Hamada J, Yano S et al. Successful clipping of a distal posterior inferior cerebellar artery aneurysm located on the anterior surface of the medulla oblongata – case report. *Neurol Med Chir (Tokyo)* 2002; 42: 158–161
- 13 Dinichert A, Rufenacht DA, Tribollet N. Dissecting aneurysms of the posterior inferior cerebellar artery: report of four cases and review of the literature. *J Clin Neurosci* 2000; 6: 515–520
- 14 Jamjoom A. Recurrent subarachnoid haemorrhage from an angiographically occult large distal pica aneurysm. *Br J Neurosurg* 1991; 5: 393–398
- 15 Ikeda A, Yamaguchi T, Yamaguchi T et al. Excision and end-to-end anastomosis of a fusiform aneurysm of the distal posterior inferior cerebellar

- lar artery associated with ischemia – case report. *Neurol Med Chir (Tokyo)* 1991; 31: 351–355
- 16 Nishino A, Sakurai Y, Satoh H *et al.* Aneurysms of the distal posterior inferior cerebellar artery; the report of 10 cases. *No Shinkei Geka* 1991; 19: 925–932
 - 17 Yamaura A, Isobe K, Nakamura T *et al.* Posterior inferior cerebellar aneurysm in the fourth ventricle. *Surg Neurol* 1980; 13: 297–299
 - 18 Hudgins RJ, Day AL, Quisling RG *et al.* Aneurysms of the posterior inferior cerebellar artery. A clinical and anatomical analysis. *J Neurosurg* 1983; 58: 381–387
 - 19 Kaptain GJ, Lanzino G, Do HM *et al.* Posterior inferior cerebellar artery aneurysms associated with posterior fossa arteriovenous malformation: report of five cases and literature review. *Surg Neurol* 1999; 51: 146–152
 - 20 Mukonoweshuro W, Laitt RD, Hughes DG. Endovascular treatment of PICA aneurysms. *Neuroradiology* 2003; 45: 188–192
 - 21 Salcman M, Rigamonti D, Numaguchi Y *et al.* Aneurysms of the posterior inferior cerebellar artery-vertebral artery complex: variations on a theme. *Neurosurgery* 1990; 27: 12–20; discussion 20–21
 - 22 Nussbaum ES, Mendez A, Camarata P *et al.* Surgical management of fusiform aneurysms of the peripheral posteroinferior cerebellar artery. *Neurosurgery* 2003; 53: 831–834
 - 23 Tawk RG, Bendok BR, Qureshi AI *et al.* Isolated dissections and dissecting aneurysms of the posterior inferior cerebellar artery: topic and literature review. *Neurosurg Rev* 2003; 26: 180–187
 - 24 Yamamoto I, Tsugane R, Ohya M *et al.* Peripheral aneurysms of the posterior inferior cerebellar artery. *Neurosurgery* 1984; 15: 839–845
 - 25 Tikkakoski T, Leinonen S, Siniluoto T *et al.* Isolated dissecting aneurysm of the left posterior inferior cerebellar artery: endovascular treatment with a Guglielmi detachable coil. *AJNR Am J Neuroradiol* 1997; 18: 936–938
 - 26 Fujimura M, Nishijima M, Midorikawa H *et al.* Fatal rupture following intra-aneurysmal embolization for the distal posterior inferior cerebellar artery aneurysm with parent artery preservation. *Clin Neurol Neurosurg* 2003; 117–120
 - 27 Dinichert A, Rufenacht DA, Tribolet N. Dissecting aneurysms of the posterior inferior cerebellar artery: report of four cases and review of the literature. *J Clin Neurosci* 2000; 7: 515–520
 - 28 Beyerl BD, Heros RC. Multiple peripheral aneurysms of the posterior inferior cerebellar artery. *Neurosurgery* 1986; 19: 285–289