

Efficacy and Toxicity of Thromboxane Synthetase Inhibitor for Cerebral Vasospasm After Subarachnoid Hemorrhage

Koji Tokiyoshi, M.D., Takanori Ohnishi, M.D., and Yasuo Nii, M.D.

Department of Neurosurgery, Iseikai Hospital, and Department of Neurosurgery, Osaka University Medical School, Osaka, Japan

Tokiyoshi K, Ohnishi T, Nii Y. Efficacy and toxicity of thromboxane synthetase inhibitor for cerebral vasospasm after subarachnoid hemorrhage. *Surg Neurol* 1991;36:112-8.

The efficacy and possible side effects of thromboxane A₂ (TXA₂) synthetase inhibitor in the treatment of cerebral vasospasm after subarachnoid hemorrhage (SAH) were assessed for 24 patients who presented with grades I to IV of the Hunt and Hess classification. All patients underwent aneurysmal clipping within 48 hours after SAH. Postoperatively, TXA₂ synthetase inhibitor, Cataclor® {sodium (E)-3-[p-(1H-imidazol-1-ylmethyl)phenyl]-2-propenoate} was administered to 13 patients by continuous drip infusion at a dose of 1 µg/kg/min for 8 to 14 days (group A). The remaining 11 patients did not receive this drug (group B). Of the 13 patients in group A, seven patients (54%) showed no symptomatic vasospasm after SAH. Four patients (31%) developed a transient deterioration of consciousness and/or motor disturbance. Three of these patients fully recovered, while one of them showed a mild neurological deficit on discharge. One patient (8%) developed permanent dysphasia and hemiparesis as a result of ischemic brain damage due to vasospasm. One patient (8%) died of the side effect. On the other hand, of the 11 patients in group B, only three (27%) showed no symptomatic vasospasm. One (9%) patient presented a transient neurological deficit but fully recovered upon discharge. Four patients (36%) showed permanent neurological deficits, although they all could lead an independent life after discharge. The three remaining patients developed a severe disturbance of consciousness caused by ischemia due to vasospasm, and two of them died within 1 month after the onset of SAH. In the group treated with Cataclor, two patients developed an epidural hematoma late during the administration of the drug. Of these two, one patient died of increased intracranial pressure that was accelerated by the complication. These results indicate that TXA₂ synthetase inhibitor is effective in not only decreasing the occurrence of symptomatic vasospasm but also reducing the neurological deterioration due to vaso-

spasm after SAH. However, this drug has a hazardous side effect in that it may promote a tendency to bleed, which caused death in one of our patients.

KEY WORDS: Subarachnoid hemorrhage; Cerebral vasospasm; Ruptured aneurysm; Thromboxane synthetase inhibitor

Vasospasm and rebleeding are two major factors related to mortality and morbidity after subarachnoid hemorrhage (SAH) due to ruptured cerebral aneurysms. It has been reported that an early operation of aneurysmal clipping and extensive removal of the clots can not only prevent rebleeding but also decrease the incidence of cerebral vasospasm [10,22]. Ischemic brain damage due to vasospasm, however, has not yet been successfully controlled by any treatment modality.

Nonsurgical treatment to prevent cerebral ischemia after SAH includes calcium entry blockers, such as nicardipine [5]; high-dose corticosteroids [2]; hypervolemia; and induced hypertension [13], all of which have been shown to be partly effective in both experimental and clinical studies.

Previous studies in experimental SAH have demonstrated that angiographic spasm or regional cerebral blood flow can be improved by intravenous administration of a thromboxane A₂ (TXA₂) synthetase inhibitor [7,19]. Thromboxane A₂, which is one of the prostaglandin metabolites, causes strong platelet aggregation and vasoconstriction in the cerebral arteries [3]. In addition, a disproportionate increase in TXA₂ after SAH may lead to release of adenosine diphosphate and serotonin from the platelets, thus promoting further platelet aggregation and local vasoconstriction [8,17].

It has been reported that the clinical application of TXA₂ synthetase inhibitor in patients with aneurysmal SAH led to favorable results, as evidenced by a decrease in the incidence of low-density areas on postoperative computed tomography (CT) scan [23]. In the present study, we evaluated the effect of TXA₂ synthetase inhibitor on the clinical outcome of patients with aneurysmal SAH in comparison with an untreated control group. In

Address reprint requests to: Takanori Ohnishi, M.D., Department of Neurosurgery, Osaka University Medical School, 1-1-50 Fukushima, Fukushima, Osaka 553, Japan.

Received December 13, 1990; accepted February 21, 1991.

Table 1. Age Distribution in 24 Patients

Age (yr)	Group A	Group B	Total
<35	2	0	2
36-45	4	1	5
46-55	4	2	6
56-65	3	6	9
>66	0	2	2
Mean age	50.0	59.1	54.2

Patients in group A received thromboxane A₂ synthetase inhibitor, Cataclot, whereas those in group B did not.

addition, two cases showing adverse effects of the drug, which caused death in one of them, are reported.

Clinical Materials and Methods

Patient Population

Twenty-four patients with a ruptured aneurysm of the anterior circulation who presented with Hunt and Hess's [11] grade I-IV on admission were enrolled in the study. All patients were admitted to our hospital between November 1986 and December 1989 and within 24 hours after the onset of SAH. All patients underwent CT after admission. Four-vessel studies were carried out to verify the location of aneurysms in all cases. The age and aneurysmal site distributions are shown in Tables 1 and 2, respectively. The intensity of preoperative SAH, which was graded on CT scans according to the classification of Fisher et al [4], is shown in relation to the preoperative neurological grade classified according to Hunt and Hess (Table 3). Patients with severe cardiac, hepatic, or renal insufficiency were excluded. The patients were randomly assigned to one of two treatment groups: 13 patients (group A) received intravenous TXA₂ synthetase inhibitor, Cataclot® {sodium (E)-3-[p-(1H-imidazol-1-ylmethyl)phenyl]-2-propenoate} (Ono Pharmaceutical Co., Ltd., Osaka, Japan) after the surgery, and 11 patients (group B) were treated with the same modality but without the drug. When administration of the drug or the placebo was started, both groups had comparable neurological and general conditions. Postoperative angiogra-

phy, which was carried out immediately before administration of the drug or the placebo, showed no abnormal changes, including narrowing of cerebral vessels.

Treatment Protocol

All 24 patients underwent aneurysmal clipping within 48 hours after the onset of SAH. The frontotemporal and transsylvian approaches with standard microsurgical technique were employed in the surgery for these patients. Subarachnoid clots in the cisterns were removed as much as possible, and cisternal drainage was performed on patients who had grade III and IV of Fisher's classification.

Postoperatively, all patients were treated with induced arterial hypertension and hypervolemic therapy using dopamine and plasma fractionates. The arterial systolic and central venous pressure were maintained in respective ranges from 140 to 160 mm Hg and from 5 to 8 cm H₂O. Methylprednisolone was also given to all patients for 7 days after the operation.

An intravenous continuous infusion of Cataclot was given to 13 patients (group A) at a dose of 1 µg/kg/min for 8 to 14 days. The remaining 11 patients (group B) received a placebo instead of Cataclot.

Clinical Evaluation

The presence of symptomatic vasospasm was assessed on the basis of clinical signs and symptoms, including deterioration of consciousness, speech and/or motor dysfunctions, and positive pathological reflex. In addition, CT scans and laboratory examinations, including serum electrolytes, were repeated in all patients to assure that the neurological deterioration was actually due to vasospasm. In cases in which the occurrence of vasospasm was uncertain, angiography was carried out to confirm the presence of vasospasm. Clinical outcome was determined 1 month after surgery. "Excellent" corresponded to good recovery on the Glasgow Outcome Scale [12] in which the patient could lead a full and independent life without any or with only minimal neurological deficit. Patients with a "good outcome" had some neurological deficit but could lead a full and independent life. Patients with a "poor result" were not independent, or had a major neurological deficit. Statistical analysis was evaluated with the χ^2 test.

Results

Effect of Cataclot on Postoperative Outcome (Table 4)

Of the 13 patients in group A, seven patients (54%) showed no clinical signs of symptoms due to vasospasm

Table 2. Site of Aneurysm Responsible for SAH*

Artery	Group A	Group B	Total
ICA	5	5	10
ACA	3	3	6
MCA	5	3	8
Total cases	13	11	24

Abbreviations: ACA, anterior cerebral artery; ICA, internal carotid artery; MCA, middle cerebral artery; SAH, subarachnoid hemorrhage.

* The number of aneurysms only responsible for SAH was counted both in group A (with Cataclot) and in group B (without Cataclot).

Table 3. Preoperative Neurological Grade Correlated with SAH Grade^a

Preoperative neurological grade	SAH grade on CT scan							
	Group A				Group B			
	I	II	III	IV	I	II	III	IV
I	0	2	1	0	1	0	1	0
II	0	0	3	1	0	0	1	0
III	1	0	2	1	0	0	4	0
IV	0	0	1	1	0	0	1	3
Total cases	1	2	7	3	1	0	7	3

^a Subarachnoid hemorrhage (SAH) was graded from computed tomography (CT) scan according to the classification of Fisher et al [4]. Neurological grade was classified according to Hunt and Hess [11]. Group A, treated with Cataclot; group B, not treated with Cataclot.

after SAH and were discharged with excellent outcome. Five patients (39%) developed symptomatic vasospasm from 4 to 13 days (8.7 ± 3.0) after the onset of SAH. Among these, four patients (31%) presented a transient disturbance of consciousness and/or motor weakness. Three of these four patients fully recovered from their symptomatic vasospasm and were discharged with excellent result, while one of them had a mild neurological deficit that made no or little difference in leading an independent life. One patient (8%) developed right hemiparesis and motor dysphasia 9 days after SAH and could not recover from the neurological deficits on discharge. One patient died of an epidural hematoma, which was thought to have been the result of tendency to bleed induced by Cataclot.

On the other hand, of the 11 patients in group B, only three (27%) did not show any ischemic symptoms due to vasospasm after SAH and had excellent outcome on discharge. Eight patients (73%) developed deterioration of consciousness and/or neurological deficits such as motor weakness from 4 to 13 days (8.0 ± 3.6) after

SAH. Of these, two patients died of ischemic brain damage caused by vasospasm within 1 month after the onset of SAH. Among the remaining six patients, one who showed symptomatic vasospasm 13 days after SAH had excellent outcome, four had good results, and one showed severe disability due to ischemic damage.

The number of patients with permanent neurological deficits due to symptomatic vasospasm in group A was one (7.7%) and in group B, seven (63.6%). There was a significant difference in the frequency of symptomatic vasospasm between these two groups ($p < 0.005$). However, the mean period from SAH to the onset of symptomatic vasospasm in group A (8.7 days) was not significantly different from that in group B (8.0 days). As for the results 1 month after surgery, 10 patients in group A (76.9%) showed excellent, one (7.7%) good, and one (7.7%) poor results, while one (7.7%) died. In group B, four patients (36.3%) showed excellent, four (36.3%) good, and one (9.1%) poor results, while two (18.2%) died. The outcome for patients in group A was significantly more favorable than that for patients in group B

Table 4. Frequency of Symptomatic Vasospasm and Outcome Correlated with Preoperative Clinical Grade^a

	Clinical grade	No. of cases	Symptomatic vasospasm		Overall outcome ^b			
			Transient	Permanent	Excellent	Good	Poor	Dead
Group A (treated with Cataclot)	I	3	1	0	3	0	0	0
	II	4	1	0	4	0	0	0
	III	4	1	1	1	1	1	1 ^c
	IV	2	1	0	2	0	0	0
	Total	13	4 (31%)	1 (8%) ^d	10 (77%) ^e	1 (8%)	1 (8%)	1
Group B (not treated with Cataclot)	I	2	0	1	1	1	0	0
	II	1	0	0	1	0	0	0
	III	4	0	4	0	2	0	2
	IV	4	1	2	2	1	1	0
	Total	11	1 (9%)	7 (64%) ^d	4 (36%) ^e	4 (36%)	1 (9%)	2

^a Preoperative clinical grade was classified according to Hunt and Hess [11].

^b Clinical outcome was determined at 1 month after surgery.

^c Died due to side effect of Cataclot.

Statistically significant between group A and B at ^d $p < 0.005$ and ^e $p < 0.01$ (χ^2 test).

($p < 0.01$). Neither group showed a correlation between preoperative neurological grade and postoperative outcome or between preoperative grade on CT scan and postoperative outcome.

Side Effects of TXA₂ Synthetase Inhibitor, Cataclot

Two of our patients presented an epidural hematoma relatively late during the administration of Cataclot. One of them died of increased intracranial pressure that was thought to have been accelerated by this complication. Our report on these two cases follows.

Case 1. A 35-year-old man was admitted to our hospital with a sudden onset of consciousness disturbance and motor weakness. The neurological examination revealed confusion and left hemiparesis. A CT scan showed a hematoma in the right temporal lobe and SAH in the basal cisterns (Figure 1 A). A preoperative cerebral angiogram disclosed a saccular aneurysm of the right middle cerebral artery. On the same day, aneurysmal neck clipping was performed and the hematoma evacuated. The patient showed mild postoperative confusion, while the left hemiparesis remained unchanged. A postoperative CT scan demonstrated no more hematoma in the right temporal lobe (Figure 1 B). One day after the operation, Cataclot was administered in accordance with the treatment protocol, but 7 days after the operation, consciousness suddenly deteriorated and he fell into a coma. A CT scan disclosed subgaleal and massive epidural hematomas on the right side, a low-density area in the right temporoparietal lobe, and a marked midline shift from right to left (Figure 1 C). Although the epidural hematoma was immediately evacuated, the patient died 10 days after the first operation.

Case 2. A 42-year-old man was admitted to our hospital with a sudden severe headache accompanied by nausea and vomiting. Neurological examination on admission revealed only stiffness of the neck. A CT scan showed SAH in bilateral sylvian and interhemispheric fissures (Figure 2 A). A cerebral angiogram disclosed a saccular aneurysm of the anterior communicating artery. On the same day, right frontotemporal craniotomy and aneurysmal neck clipping were performed. In addition, a silicone tube was placed in the basal cistern for continuous drainage. Postoperatively, the patient was well and a CT scan showed no abnormalities except for the slightly persistent SAH (Figure 2 B). He was administered Cataclot from 1 day after the operation. Ten days after the operation, the cisternal drainage was terminated because the cerebrospinal fluid had become clear. Twelve days after the operation, however, the patient began to show

consciousness disturbance. A CT scan disclosed hematomas in the right epidural and subgaleal regions (Figure 2 C). After the hematomas had been evacuated, the patient became well and was discharged without any neurological deficit 1 month after the onset of SAH.

Discussion

Recent studies have suggested that not only vasoconstriction of the main cerebral arteries but also thrombus formation by platelet aggregation in the peripheral arteries play an important role in symptomatic delayed ischemia after aneurysmal SAH [21]. It is well known that free oxygen radicals and lipid peroxides, which are generated from lipid peroxidation initiated by lysis of clots after SAH, damage the vascular endothelium and inhibit the synthesis of prostaglandin I₂ (PGI₂) [14,15]. Sasaki et al [18] further demonstrated that PGI₂ synthesis in the cerebral arteries significantly diminished after experimental SAH. The decreased level of PGI₂ may in turn increase the synthesis of TXA₂, which is a powerful vasoconstrictor and platelet-aggregating substance [3]. Thus, the shift to TXA₂ synthesis at the blood-endothelial interface could lead to disturbance of peripheral cerebral blood microcirculation. For this reason, it is supposed that inhibition of TXA₂ synthesis may correct the imbalance between TXA₂ and PGI₂ and thereby protect brains from ischemic changes after SAH, not only by preventing vasoconstriction but also by improving cerebral microcirculation.

Cataclot, which was used in the present study, selectively decreases the production of TXA₂ from prostaglandin endoperoxide (PGH₂) by inhibiting TXA₂ synthetase in human and rabbit platelets and is expected to prevent platelet aggregation (Figure 3). The IC₅₀ value (concentration at 50% inhibition) of the drug for TXA₂ synthetase is 4–11 nM, while that for cyclooxygenase, PGI₂ synthetase, or PGE₂ isomerase is greater than 1 mM [9]. It has been demonstrated that Cataclot inhibits the aggregation of platelets by arachidonate or collagen, prolongs a bleeding time at the incision of rat tails, and can decrease the incidence of cerebral infarction induced by injection of arachidonate into the internal carotid artery in rabbits [9,16].

In our study, the frequency of symptomatic vasospasm as well as the incidence of irreversible ischemic changes was significantly lower in patients treated with Cataclot (group A). Since there was no significant difference in the interval from SAH to the onset of symptomatic vasospasm between the treated (group A) and untreated (group B) patients, this drug may not affect occurrence of arterial vasospasm. In fact, Tani et al [23] reported that TXA₂ synthetase inhibitor (OKY-1581) did not significantly reverse angiographic vasospasm. Re-

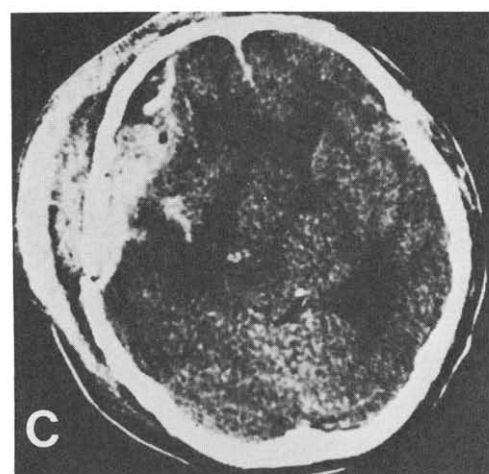
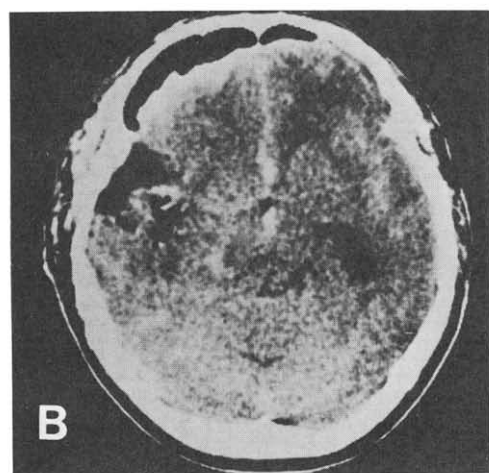
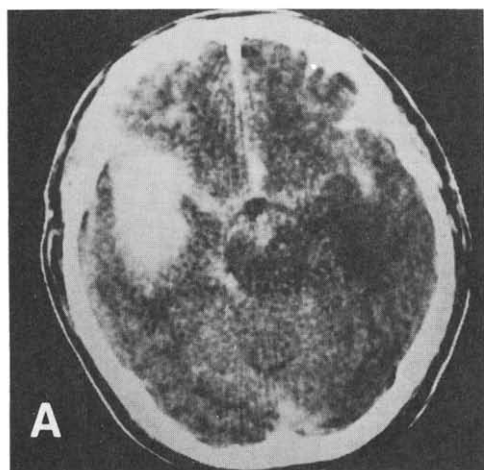


Figure 1. Case 1. (A) Preoperative CT scan showing a hematoma in the right temporal lobe and SAH in the basal cisterns. (B) CT scan 1 day after surgery showing disappearance of the hematoma. (C) CT scan 7 days after surgery disclosing the right subgaleal and epidural hematomas with a marked midline shift from right to left.

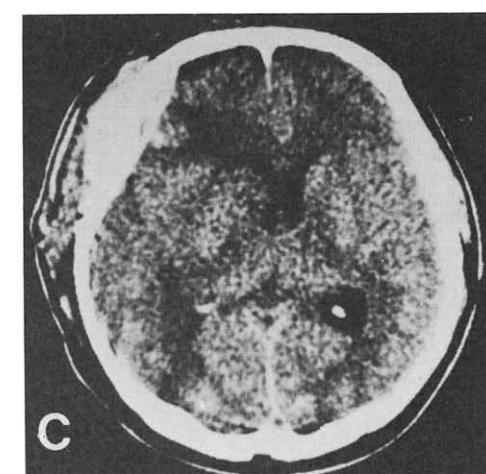
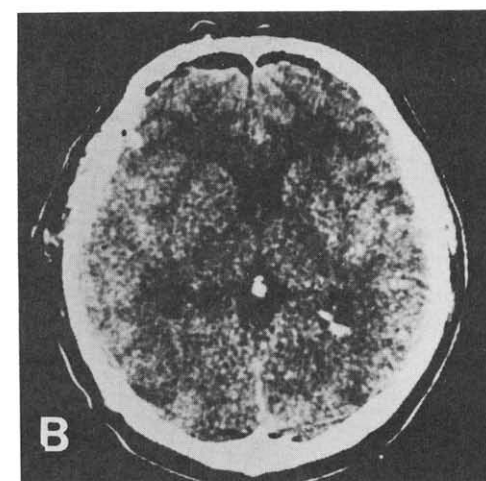
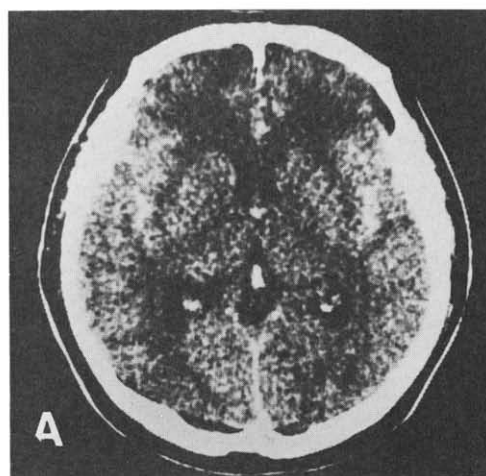


Figure 2. Case 2. (A) Preoperative CT scan showing SAH in bilateral sylvian and interhemispheric fissures. (B) CT scan 1 day after surgery showing no apparent abnormalities except for the persistent SAH and postoperative changes. (C) CT scan 12 days after surgery demonstrating the right subgaleal and epidural hematomas.

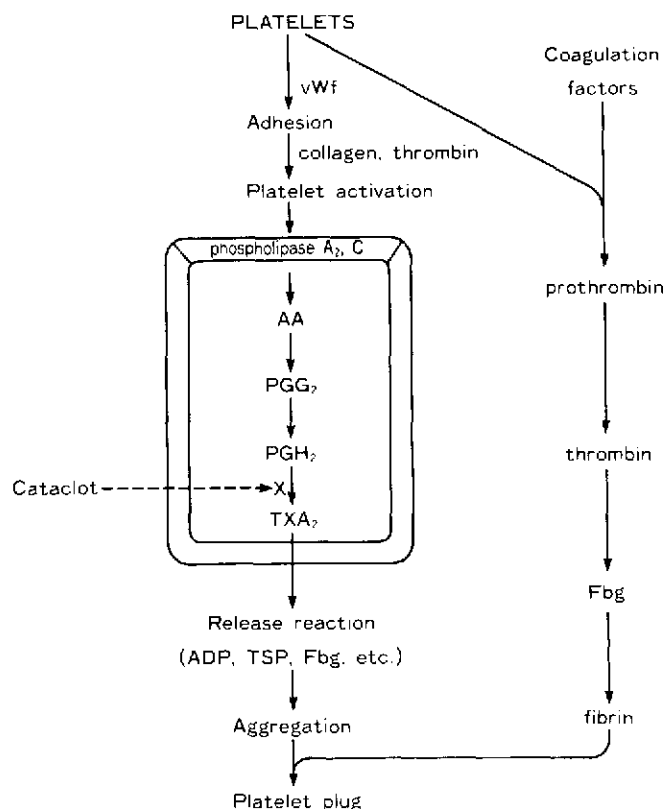


Figure 3. Diagram showing the mechanism of platelet plug formation. Cataclot inhibits thromboxane A₂ (TXA₂) synthetase in platelets, by which prostaglandin endoperoxide (PGH₂) is converted to TXA₂ (shown by a dotted line). Abbreviations: AA, arachidonic acid; ADP, adenosine diphosphate; Fbg, fibrinogen; TSP, thrombospondin; vWf, von Willebrand factor.

cently, it has been reported that intravascular volume expansion, which has been used to improve blood flow in ischemic brains, affects cerebral blood flow through decreased blood viscosity rather than through cardiac output augmentation [1]. It is commonly observed that the ischemic signs of patients with aneurysmal SAH, in whom ischemic neurological syndromes tend to fluctuate after the occurrence of symptomatic vasospasm, rapidly improve as a result of the administration of volume expander. This suggests that cerebral microcirculation may actually play a key role in the development of ischemic neurological syndrome.

Thromboxane A₂ synthetase inhibitor may not be so effective in the prevention of vasoconstriction after SAH, because a wide variety of substances found in the cerebrospinal fluid after SAH, including catecholamines and serotonin in addition to TXA₂, have been implicated in the pathogenesis of cerebral vasospasm [6,24]. Since this drug is an antiplatelet reagent, however, it can make the peripheral circulation of the brain much better, thus possibly preventing permanent neurological deficits due to vasospasm. Therefore, a combination of vasodilating

reagents such as calcium entry blockers and TXA₂ synthetase inhibitor may be much more effective in the treatment of vasospasm than their single use.

Serious adverse effects of TXA₂ synthetase inhibitor have not been reported except for rare complications. These include thrombocytopenia [23], rerupture of aneurysm, and gastrointestinal bleeding [20]. In the present study, two of our patients suffered epidural hematoma during treatment with Cataclot. In both cases, the hematoma occurred relatively late after the administration of this drug. Therefore, this complication is not thought to have been the direct result of the first operation. The adverse effects of TXA₂ synthetase inhibitor may occur because of an enhanced tendency to bleed, mainly as a result of the inhibition of platelet aggregation. Of these two patients, one died of increased intracranial pressure that was thought to have been accelerated by the complication of a rapidly formed epidural hematoma.

Although TXA₂ synthetase inhibitor seems to be effective for the prevention of ischemic brain insults after aneurysmal SAH, safe application of this drug requires that it should be used in conjunction with an appropriate monitoring system to check for tendency to bleed. Because Cataclot inhibits the aggregation of platelets but has little effect on the coagulation of blood, the measurement of both bleeding time and the number of platelets is recommended. These examinations should be performed at least once a day during the administration of the drug. When patients begin to show thrombocytopenia or prolongation of bleeding time more than twice the normal value, the dose must be reduced or discontinued in order to prevent any complication induced by the drug.

References

1. Bouma GJ, Muizelaar JP. Relationship between cardiac output and cerebral blood flow in patients with intact and with impaired autoregulation. *J Neurosurg* 1990;73:368-74.
2. Chyatte D, Fode NC, Nichols DA, Sundt TM Jr. Preliminary report: effects of high dose methylprednisolone on delayed cerebral ischemia in patients at high risk for vasospasm after aneurysmal subarachnoid hemorrhage. *Neurosurgery* 1987;21:157-60.
3. Ellis EF, Nies AS, Oates JA. Cerebral arterial smooth muscle contraction by thromboxane A₂. *Stroke* 1977;8:480-2.
4. Fisher CM, Kistler JP, Davis JM. Relation of cerebral vasospasm to subarachnoid hemorrhage visualized by computerized tomographic scanning. *Neurosurgery* 1980;6:1-9.
5. Flamm ES, Adams HP, Beck DW, Pinto RS, Marler JR, Walker MD, Godersky JC, Loftus CM, Biller J, Boarini DJ, O'Dell C, Banwart K, Kongable G. Dose-escalation study of intravenous nicardipine in patients with aneurysmal subarachnoid hemorrhage. *J Neurosurg* 1988;68:393-400.
6. Flamm ES, Yasargil MG, Ransohoff J II. Alteration of experimental cerebral vasospasm by adrenergic blockade. *J Neurosurg* 1972;37:294-301.

7. Fukumori T, Tani E, Maeda Y, Sukenaga A. Effects of selective inhibitor of thromboxane A₂ synthetase on experimental cerebral vasospasm. *Stroke* 1984;15:306-11.
8. Hamberg M, Svensson J, Samuelsson B. Thromboxanes: a new group of biologically active compounds derived from prostaglandin endoperoxides. *Proc Natl Acad Sci USA* 1975;72:2994-8.
9. Hiraku S, Taniguchi K, Wakitani K, Omawari N, Kira H, Miyamoto T, Okegawa T, Kawasaki A, Ujiiie A. Pharmacological studies on the TXA₂ synthetase inhibitor (E)-3-[p-(1H-imidazol-1-ylmethyl)phenyl]-2-propenoic acid. *Jpn J Pharmacol* 1986;41:393-401.
10. Hugenholtz H, Elgie RG. Considerations in early surgery on good-risk patients with ruptured intracranial aneurysms. *J Neurosurg* 1982;56:180-5.
11. Hunt WE, Hess RM. Surgical risk as related to time of intervention in the repair of intracranial aneurysms. *J Neurosurg* 1968;28:14-20.
12. Jennet B, Bond M. Assessment of outcome after severe brain damage. A practical scale. *Lancet* 1975;1:480-4.
13. Kassell NF, Peerless SJ, Durward QJ, Beck DW, Drake CG, Adams HP. Treatment of ischemic deficits from vasospasm with intravascular volume expansion and induced arterial hypertension. *Neurosurgery* 1982;11:337-43.
14. Kontos HA, Wei EP, Povlishock JT, Dietrich WD, Magiera CJ, Ellis EF. Cerebral arteriolar damage by arachidonic acid and prostaglandin G₂. *Science* 1980;209:1242-5.
15. Moncada S, Gryglewski RJ, Bunting S, Vane JR. A lipid peroxide inhibits the enzyme in blood vessel microsomes that generates from prostaglandin endoperoxides the substance (prostaglandin X) which prevents platelet aggregation. *Prostaglandins* 1976;12:715-37.
16. Naito J, Komatsu H, Ujiiie A, Hamano S, Kubota T, Tsuboshima M. Effects of thromboxane synthetase inhibitors on aggregation of rabbit platelets. *Eur J Pharmacol* 1983;91:41-8.
17. Samuelsson B, Hamberg M, Malmsten C, Svensson J. The role of prostaglandin endoperoxides and thromboxanes in platelet aggregation. *Adv Prostaglandin Thromboxane Leukotriene Res* 1976;2:737-46.
18. Sasaki T, Murota S, Wakai S, Asano T, Sano K. Evaluation of prostaglandin biosynthetic activity in canine basilar artery following subarachnoid injection of blood. *J Neurosurg* 1981;55:771-8.
19. Sasaki T, Wakai S, Asano T, Takakura K, Sano K. Prevention of cerebral vasospasm after SAH with a thromboxane synthetase inhibitor, OKY-1581. *J Neurosurg* 1982;57:74-82.
20. Suzuki S, Iwabuchi T, Tanaka T, Kanayama S, Ottomo M, Hatanaka M, Aihara H. Prevention of cerebral vasospasm with OKY-046 an imidazole derivative and a thromboxane synthetase inhibitor. A preliminary co-operative study. *Acta Neurochir (Wien)* 1985;77:133-41.
21. Suzuki S, Suzuki M, Iwabuchi T, Kamata Y. Role of multiple cerebral microthrombosis in symptomatic cerebral vasospasm: with a case report. *Neurosurgery* 1983;13:199-203.
22. Taneda M. Effect of early operation for ruptured aneurysms on prevention of delayed ischemic symptoms. *J Neurosurg* 1982;57:622-8.
23. Tani E, Maeda Y, Fukumori T, Nakano M, Kochi N, Morimura T, Yokota M, Matsumoto T. Effect of selective inhibitor of thromboxane A₂ synthetase on cerebral vasospasm after early surgery. *J Neurosurg* 1984;61:24-9.
24. Zabramski J, Spetzler RF, Bonstelle C. Chronic cerebral vasospasm: effect of calcium antagonists. *Neurosurgery* 1986;18:129-35.