

Acute ischaemic stroke in pregnancy: a severe complication of ovarian hyperstimulation syndrome

Andrea Bartkova · Daniel Sanak · Jiri Dostal · Roman Herzig · Pavel Otruba · Ivanka Vlachova · Petr Hlustik · David Horak · Petr Kanovsky

Received: 21 February 2008 / Accepted in revised form: 29 August 2008 / Published online: 15 October 2008
© Springer-Verlag 2008

Abstract Ovarian hyperstimulation syndrome (OHSS) is the most serious complication of sterility treatment. It is characterised by ovarian enlargement, ascites, electrolyte disturbance, hypovolaemia and haemoconcentration. A case of ischaemic stroke due to right middle cerebral artery (MCA) occlusion in a young female with OHSS after pharmacological treatment of sterility is reported. Left central hemiparesis occurred suddenly within a few days after the embryo transfer. Magnetic resonance imaging diffusion-weighted images showed infarction in the right basal ganglia and magnetic resonance angiography (MRA) revealed the occlusion of the M1 segment of the right MCA. The haemodilution and the anticoagulation therapy were effective. Twenty-four hours after the stroke onset, MRA showed MCA recanalisation. The neurological deficit resolved completely within 3 months. The patient delivered 2 healthy infants at term. This case emphasises that the recent advent of ovulation induction

and reproductive techniques is a newly recognised cause of cerebral stroke in otherwise healthy females.

Keywords · Ovarian hyperstimulation syndrome · Pregnancy · Ischaemic stroke

Introduction

Ovarian hyperstimulation syndrome (OHSS) is a serious iatrogenic complication of infertility treatment. OHSS can be considered as the loss of control over the intended therapeutic ovarian hyperstimulation [1] and an increase in its incidence after the development of a new method of *in vitro* fertilisation [2]. Characteristic pathophysiological phenomena of OHSS include overproduction of ovarian hormones and vasoactive peptides increasing the capillary permeability, leading to the massive accumulation of extravascular exudates with intravascular volume depletion and to haemoconcentration. The resulting clinical manifestation may vary. OHSS is characterised by ovarian enlargement, abdominal distension, ascites, pleural effusion and electrolyte disturbance. In its severe form, OHSS can lead to multiple organ failure with adult respiratory distress syndrome, renal and liver insufficiency, and to thromboembolic events. These thromboembolic events represent the most serious complications of OHSS. Their exact incidence in severe OHSS is unknown and, according to the literature, ranges from 0.2% to 10% [1–3]. Most (75%) of the thrombotic events are of venous origin and the remaining 25% are of arterial origin [4]. It seems that thrombotic events in OHSS are related to the thrombophilic reaction caused by oestrogens, low plasma circulation volume and haemoconcentration.

Stroke represents a rare but life-threatening complication of severe OHSS. A case of acute ischaemic stroke (IS) caused by OHSS is reported.

A. Bartkova (✉) · D. Sanak · R. Herzig · P. Otruba · I. Vlachova · P. Hlustik · P. Kanovsky
Stroke Centre, Department of Neurology
Faculty of Medicine and Dentistry
Palacký University and University Hospital Olomouc
I. P. Pavlova 6
CZ-775 20 Olomouc, Czech Republic
e-mail: abartkova@seznam.cz

J. Dostal
Department of Obstetrics and Gynecology
Faculty of Medicine and Dentistry
Palacký University and University Hospital Olomouc
Olomouc, Czech Republic

D. Horak
Department of Radiology
Faculty of Medicine and Dentistry
Palacký University and University Hospital Olomouc
Olomouc, Czech Republic

Case report

A 31-year-old female, without the presence of thromboembolic risk factors, had a 6-year history of primary infertility and 2 unsuccessful cycles of ovulation induction. The third course of controlled ovarian hyperstimulation (COH) (long protocol E2 4 400) during *in vitro* fertilisation (IVF) was used in this patient. Two embryos were transferred 4 days after the aspiration of 19 oocytes. In that time, the oestradiol level was 1440 pg/ml and 10,000 IU of human chorionic gonadotropin (hCG) was administered. Seven days after the embryo transfer, the patient developed nausea, vomiting and abdominal distension with ovarian enlargement. The ultrasound revealed the presence of ascites and polycystic ovaries. She was admitted to the hospital because of suspected OHSS. The pregnancy test was positive (hCG level was 46 IU). Nine days after the embryo transfer, she suddenly developed a severe central left-sided hemiparesis, with the central lesion of the left facial nerve, deviation of the head to the right with left-side conjugate gaze palsy and drowsiness (National Institute of Health Stroke Scale (NIHSS) of 11 points). Magnetic resonance imaging diffusion-weighted images (MRI-DWI) showed acute infarction (volume 23.2 ml) of the right basal ganglia (Fig. 1) and magnetic resonance angiography (MRA) showed the occlusion of the main stem of the right middle cerebral artery (MCA/M1) (Fig. 2). The patient was transferred to the Stroke Unit. Laboratory tests, including tests for thrombophilia used in young stroke patients were performed. Leukocytosis (total leukocyte count 29,200/mm³) and the evidence of haemoconcentration (haematocrit 45%, fibrinogen level 5.6 g/l) were found. The use of intravenous thrombolysis (IVT) was considered, but the patient refused this treatment because of a probable pregnancy. She was treated with subcutaneous administration of

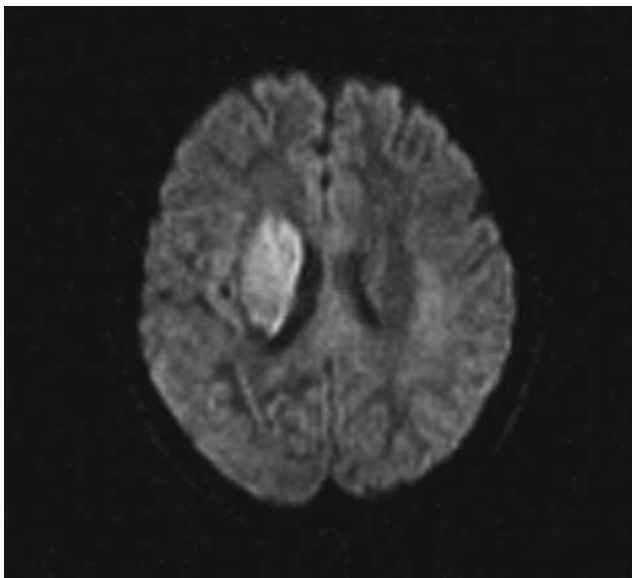


Fig. 1 MRI-DWI. Acute cerebral infarction of the right basal ganglia

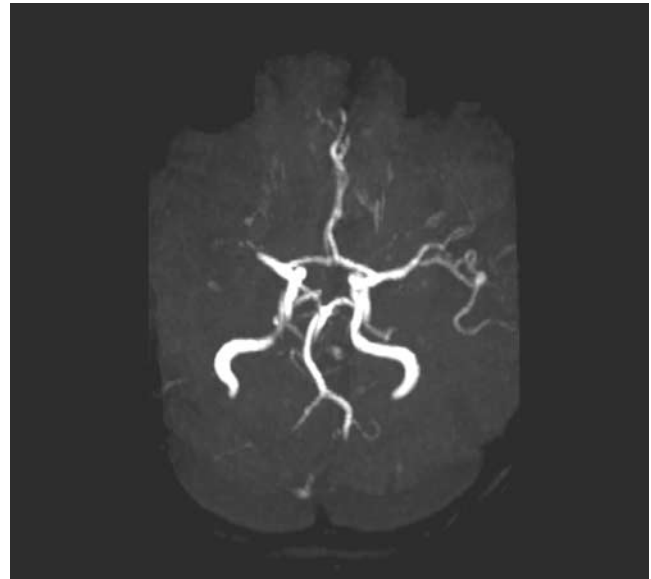


Fig. 2 MRA. Occlusion of the right middle cerebral artery in the M1 segment

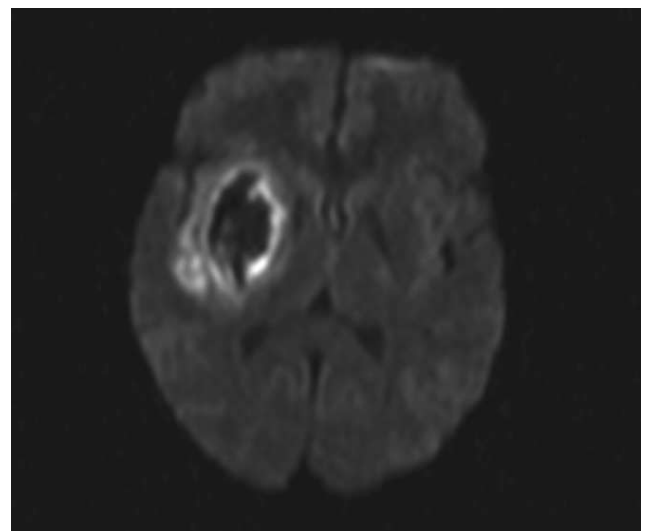


Fig. 3 MRI-DWI – performed 24 h after stroke onset. Slight progression of infarct volume with haemorrhagic transformation of the infarction

nandoparine 0.6 ml twice daily and haemodilution with crystalloid fluid infusions with target haematocrit of 35%. The MCA/M1 recanalised (as detected with MRA performed 24 h after the stroke onset (Fig. 3)) and the neurological status improved (NIHSS decreased to 6 points). MRI Turbo Spin Echo (TSE) T2 and DWI sequences demonstrated the haemorrhagic transformation of infarction with slight infarct growth (volume 32.5 ml) (Fig. 4). The nandoparine dose was reduced to 0.3 ml twice daily. Due to the successful gravidity, the OHSS symptoms, such as dyspnoea, arterial hypotension (100/60 mmHg), tachycardia (120 beats/min), hypoalbuminaemia (26 g/l), ascites and fluidothorax worsened.

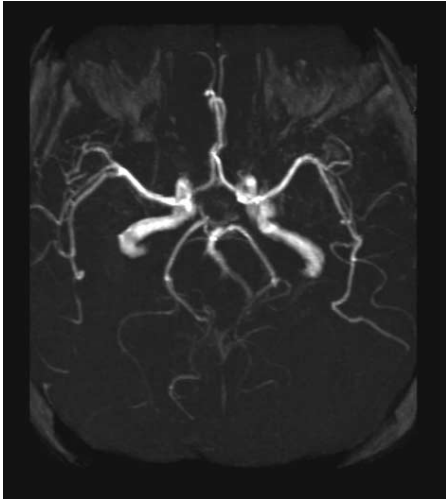


Fig. 4 MRA – performed 24 h after stroke onset. Successful recanalisation of the right middle cerebral artery

Repeated transabdominal aspiration of the ascitic fluid and intravenous administration of albumin 100 ml daily for a period of 7 days was used. The OHSS symptoms resolved slowly over 14 days.

The neurological state of the patient normalised gradually; after 3 months she manifested no residual neurological deficit. She delivered healthy twins at term by caesarean section. During the pregnancy and puerperium she was maintained on acetylsalicylic acid 100 mg daily.

Discussion

The incidence of IS during pregnancy is 0.003/1000 (RR 0.7); two days before and one day after delivery the risk of stroke incidence increases (RR 2.5) [5]. The risk has also increased with the higher frequency of *in vitro* fertilisation during recent years [2].

OHSS is an iatrogenic complication of ovarian stimulation usually occurring during the luteal phase or during the early phase of pregnancy [6]. The most common form of OHSS occurs within a few days after follicular rupture or puncture, when follicular growth has been medically induced [1]. The prevalence of the severe form of OHSS is low, with a reported value ranging from 0.5% to 5% of stimulated ovarian cycles resulting in severe OHSS [1] with an estimated mortality rate of 1/50,000–450,000 patients [7].

It is difficult to estimate the incidence of the thromboembolic events, because no systematic registration of OHSS cases and their complications exists. Delvigne and Rozenberg reported a 0.2% incidence of thrombotic events and 10% incidence of a severe OHSS in a series of 2924 IVF cycles [1].

Stroke represents a rare but often fatal thromboembolic complication of OHSS.

The following factors were recognised as presenting an increased risk for the severe form of OHSS with thromboem-

bolism: rapid rise of oestradiol levels (with serum concentration >2500 pg/ml), increased number of developing follicles and the number of oocytes retrieved during IVF (>14), previous history of OHSS, age under 35 years, use of gonadotropin releasing agonist (GRA) protocol, higher or repeated dose of exogenous hCG and polycystic ovary. Our patient was 31 years old and underwent a long-term GRA protocol; she presented with a serum oestradiol level of 1440 pg/ml and a high number of oocytes [8] were retrieved. Routine screening of the mentioned risk factors should be performed. Screening for thrombophilia (personal and family history of thrombosis) should be recommended to rule out thrombophilia before the ovulation induction. It is important to prevent thromboembolism in OHSS [1]. In our case, heterozygosity of MTHFR without a homocysteine plasma level increase was found. However, it is difficult to establish its relationship to IS, because of a very mild thrombotic potential, although a similar case was reported by Di Micco et al. [9].

The diagnostic approach in suspected stroke in a pregnant female does not significantly differ from that in a non-pregnant one. The radiation dose during a routine head examination with computed tomography (CT) is as low as 1 mrad and seems to be safe for the foetus [10]. Thus, brain CT can be performed during the whole period of pregnancy in indicated cases, as long as the uterus is protected during the examination [10].

Nevertheless, the use of MRI scanning during pregnancy remains controversial. MRI use is mostly not recommended within the first 12 weeks of pregnancy due to the higher frequency of congenital anomalies [11, 12]. The safe use of MRI is reported in the third trimester and the potential benefit of MRI should be considered in individual cases in the first and second trimesters. Although the MRI was performed 9 days after the embryo transfer, no foetal injury occurred in the presented case.

In our opinion, consistent with the literary data, the use of haemodilution and rehydration therapy seems rational, because haemoconcentration is one of the factors leading to thrombotic events [1, 13]. The use of infusion of crystalloids represents the method of the choice in these cases. Intravenous administration of albumin is recommended in cases of severe OHSS (as a plasma expander) and in cases of severe hypoalbuminaemia or tense ascites [1, 13]. Abdominal paracentesis is a common procedure used in severe OHSS. Paracentesis may be needed for symptomatic relief of tense ascites, but it may also be indicated in cases of oliguria, increasing creatinine or decreasing creatinine clearance, and haemoconcentration refractory to medical therapy [1, 13]. In our case, paracentesis was performed due to haemodynamic instability.

IVT should be considered as the first treatment method in a case of IS caused by the cerebral artery occlusion. However, it is not recommended in pregnancy and lactation according to recent guidelines [14]. The major concern regarding the use of thrombolytics during pregnancy is their

effect on the placenta, possibly resulting in premature labour, placental abruption or foetal demise. Most pregnant females were treated with intra-arterial thrombolysis [15–17]. Reported complication rates were similar when compared to thrombolytic treatment of non-pregnant females. Child outcomes appeared not to be affected. Considering the best level of medical evidence, alteplase should not be withheld in the pregnant patient with acute IS, and limited risks and benefits must be carefully weighted [14, 18]. Also our patient refused IVT because of its potential risk of abortion and she was anticoagulated with nandroparine. Antithrombotic primary prevention is not used in all COH cycles, as the incidence of OHSS is low. In COH with signs of severe OHSS, anticoagulant therapy is indicated if there is clinical evidence of a thromboembolic complication or laboratory evidence of hypercoagulability [8, 19]. The Authors presume that early administration of heparin at the time of first OHSS symptoms could prevent serious thromboembolic events.

In the presented case, a complex treatment (rehydration, haemodilution, anticoagulation, close gynaecological monitoring) was effective, with a good clinical outcome for the patient and no harm to the infants.

Conclusion

The reported case emphasises that the development of ovulation induction and reproductive techniques is a newly recognised cause of cerebral stroke in otherwise healthy women. Females with mild forms of OHSS without neurological symptoms should be closely monitored and a sudden onset of neurological deficit in such patients with OHSS symptoms must be considered as an acute IS and a severe OHSS complication.

References

1. Delvigne A, Rozenberg S (2003) Review of clinical course and treatment of ovarian hyperstimulation syndrome (OHSS). *Human Reprod Update* 9:77–96
2. Abramov Y, Elchalal U, Schenker JG (1999) Severe OHSS. An “epidemic” of severe OHSS: A price to pay? *Hum Reprod* 14:2181–2185
3. Serour GI, Aboulghar M, Mansour R et al (1998) Complications of medically assisted conception in 3,500 cycles. *Fertil Steril* 70:638–642
4. Stewart JA, Hamilton PJ, Murdoch AP (1998) Upper limb thrombosis associated with assisted conception treatment. *Hum Reprod* 12:2174–2175
5. Kittner SJ, Stern BJ, Feesser BR et al (1996) Pregnancy and the risk of stroke. *N Engl J Med* 335:768–774
6. Avelillas JF, Falcone T, Arroliga AC (2004) Ovarian hyperstimulation syndrome. *Crit Care Clin* 20:679–695
7. Brinsden PR, Wada I, Tan SL et al (1995) Diagnosis, prevention and management of ovarian hyperstimulation syndrome. *Br J Obstet Gynaecol* 102:767–772
8. Rizk B (2007) Classification, pathophysiology and management of ovarian hyperstimulation syndrome. In: Brinsden P (ed.) *Textbook of in vitro fertilization and assisted reproduction*, 1st Edn. Informa Healthcare, pp 217–258
9. Di Micco P, D’Uva M, Romano M et al (2003) Stroke due to left carotid thrombosis in moderate ovarian hyperstimulation syndrome. *Thromb Haemost* 90:957–960
10. Schwartz RB (2002) Neuroradiographic imaging: techniques and safety considerations. *Adv Neurol* 90:1–8
11. Tyndall DA, Sulik KK (1991) Effects of magnetic resonance imaging on eye development in the C57BL/6J mouse. *Teratology* 43:263–275
12. Heinrichs WL, Fong P, Flannery M et al (1988) Midgestational exposure of pregnant BALB/c mice to magnetic resonance imaging conditions. *Magn Reson Imaging* 6:305–311
13. Budev MM, Arroliga AC, Falcone T (2003) Ovarian hyperstimulation syndrome. *Crit Care Med* 33:301–306
14. De Keyser J, Gdovinova Z, Uyttenboogaart M et al (2007) Intravenous alteplase for stroke: beyond the guidelines and in particular clinical situations. *Stroke* 38:2612–2618
15. Elford K, Leader A, Wee R et al (2002) Stroke in ovarian hyperstimulation syndrome in early pregnancy treated with intra-arterial r-tPA. *Neurology* 59:1270–1272
16. Murugappan A, Coplin WM, Al-Sadat AN et al (2006) Thrombolytic therapy of acute ischemic stroke during pregnancy. *Neurology* 66:768–770
17. Leonhard G, Gaul Ch, Nietsch HH et al (2006) Thrombolytic therapy in pregnancy. *J Thromb Thrombolysis* 21:271–276
18. Boehringer Ingelheim (October 2002) Fachinformation (SPC) Actilyse
19. Rizk B, Meagher S, Fisher AM (1990) Severe ovarian hyperstimulation syndrome and cerebrovascular accidents. *Hum Reprod* 5:697–698