

Hydrogen peroxide–induced stroke: elucidation of the mechanism in vivo

Laboratory investigation

MELIKE MUT, M.D., PH.D.,¹ MUGE YEMISCI, M.D., PH.D.,²
YASEMIN GURSOY-OZDEMIR, M.D., PH.D.,² AND UGUR TURE, M.D.³

¹Department of Neurosurgery, ²Institute of Neurological Sciences and Psychiatry, Hacettepe University, Ankara; and ³Department of Neurosurgery, Yeditepe University, Istanbul, Turkey

Object. Hydrogen peroxide (H₂O₂) is used as a hemostatic agent in many neurosurgery centers. The authors used a 3% H₂O₂ solution for final hemostasis after removal of a left insular tumor. Immediately afterward, air bubbles were observed within the lumen of the polar temporal artery. Postoperative MR imaging revealed punctate areas of infarction in the lenticulostriate artery territory. The authors designed an experimental study to elucidate the mechanism of remote O₂ emboli and reactive O₂ species–related vasoactive responses and thrombus formation.

Methods. In this study, H₂O₂ irrigation was used in mice with either an intact pial layer or after the pia mater was removed through a corticotomy. Normal saline irrigation was used in the corresponding control groups. Vessels were examined for intravascular O₂ emboli under the microscope. Tissue sections were then obtained and stained with H & E and the 3-nitrotyrosine (3-NT) antibody to evaluate intravascular thrombus formation and peroxynitrite reaction, respectively.

Results. Multiple bubbles were observed within the lumen of the vessels after exposure to H₂O₂ regardless of whether the pial layer was destroyed or intact. Immunofluorescent staining for 3-NT showed an abundant positive reaction in the vessel walls of all animals exposed to H₂O₂ as well as vascular occlusion with acute thrombus formation. Samples taken from the animals that received saline showed no positive staining for 3-NT and no vascular occlusion.

Conclusions. Exposure to H₂O₂ may cause serious ischemic complications. The formation of peroxynitrite may cause vasoactive responses to H₂O₂ and platelet aggregation/thrombus formation, and the free diffusion of H₂O₂ through the vessel walls and its conversion to water and O₂ leads to O₂ bubbles within the closed vessel lumen. If used intradurally, H₂O₂ may have deleterious ischemic effects, and it can only be used carefully in open extradural spaces. (DOI: 10.3171/2008.3.17434)

KEY WORDS • hydrogen peroxide • insula •
lenticulostriate artery • mouse • oxygen embolus •
peroxynitrite • stroke • thrombus

HYDROGEN peroxide is used as a hemostatic agent in several neurosurgical centers. Although its exact mechanism has not been clarified, H₂O₂ is believed to establish hemostasis through its vasoconstrictive properties.²² A few studies, however, have drawn attention to a deleterious effect of the use of H₂O₂: that is, O₂ emboli.^{6,21,22,36,38} Another mechanism could be disruption of the blood-brain barrier and aggregation of platelets and neutrophils, leading to thrombus formation and occlusion of the vessel.^{26,30}

We describe the case of a patient who developed postoperative hemiparesis and dysphasia caused by an LSA stroke after irrigation with H₂O₂ for hemostasis, although the LSAs were remote from the surgical field and not directly exposed to H₂O₂. To elucidate the pathophysiological mechanisms of injury caused by H₂O₂ in vivo, we conducted an experiment in mice in which H₂O₂ was administered to the brain surface over either an intact or destroyed pial layer and ischemia was reproduced.

Illustrative Case

This 40-year-old man came to our attention when he experienced generalized seizures for the first time in his life. His neurological examination revealed no pathological findings, but MR imaging revealed a nonenhancing

Abbreviations used in this paper: BA = basilar artery; H₂O₂ = hydrogen peroxide; LSA = lenticulostriate artery; MCA = middle cerebral artery; NO = nitric oxide; ROS = reactive oxygen species; 3-NT = 3-nitrotyrosine.

Hydrogen peroxide–induced stroke

lesion consistent with a low-grade glioma in the left insular region (Fig. 1). The patient was followed up for 4 months, but his seizures continued despite multiple anti-epileptic medications. After detailed preoperative assessment and epilepsy monitoring, surgery was planned to resect the tumor.

A left extended pterional craniotomy was performed, and dissection of the sylvian fissure revealed the tumor in the insula. The tumor was removed gross totally as described elsewhere.^{31,32,36,37} All branches of the MCA were meticulously preserved, but the LSAs were not exposed and stayed buried in the putamen. After resection, the tumor cavity was irrigated with 3% H₂O₂ for ~ 15 seconds to establish hemostasis. As the H₂O₂ was removed from the cavity by irrigation with saline, multiple bubbles were observed filling the lumen of the polar temporal artery and pulsating along the vessel (see intraoperative video at <http://thejns.org>). Irrigation with copious amounts of saline immediately removed the H₂O₂ and no hemodynamic changes were seen during or after this event.

Video 1. Intraoperative video showing multiple bubbles in the polar temporal artery in a patient in whom H₂O₂ was used for hemostasis after tumor removal.

The patient awoke with dense right hemiparesis (more pronounced in his arm, 0–2/5) and dysphasia. By his 6-month follow-up examination, the motor strength had returned to normal in his leg and only the distal muscle groups in his right arm remained paretic (2–3/5). His dysphasia had resolved completely. Postoperative MR imaging revealed small, punctate areas of infarction in the distribution of the lenticulostriate vessels (Figs. 2 and 3). Oxygen emboli did not appear in the vascular territory of other branches of the left MCA because of their collateral circulation. The LSAs, however, are small end arteries without collateral circulation.^{31,32,36,37}

Experimental Study

Study Design and Methods

We designed an experimental study to evaluate in vivo the mechanism of stroke after irrigation with H₂O₂. All experiments were done according to local ethics committee regulations. Twenty Swiss albino mice weighing between 22 and 34 g were used for the experiments. The mice were kept at 18–21°C in a 12-hour dark/12-hour light cycle before surgery and anesthetized intraperitoneally with 50 mg/kg ketamine (Ketalar, Parke-Davis) and 5 mg/kg xylazine (Alfazine, Alfasan). Body temperatures were recorded with a rectal probe and kept at 37 ± 1°C with the aid of a homeothermic temperature control unit (Harvard Apparatus).

Four experimental groups of 5 mice each were created and the surgical procedures were performed with the aid of the operating stereomicroscope (Zeiss). In the first group of mice, a unilateral craniectomy with a diameter of 1 cm was made in the right frontal lobe, the dura mater was removed with the pia left intact, and the brain surface was irrigated with normal saline (0.09% NaCl) for 1 minute. In the second group, after the craniectomy the dura mater was removed and the pia left intact, as in the first group. The brain surface was irrigated with 1 ml 3% H₂O₂ over the intact pial layer for 15 seconds, and then irrigated with normal saline for 1 minute. In the third group of mice, a unilateral frontal craniectomy with resection of the dura mater and peeling of the pia was done. This was followed by a 0.5-cm corticotomy, and the brain surface was irrigated with saline for 1 minute. The fourth group of 5 mice underwent the same procedure as the third, after which the brain surface in the corticotomy area was irrigated for 15 seconds with 1 ml 3% H₂O₂ and then with saline for 1 minute.

After irrigation with either H₂O₂ or saline, the animals' hearts were perfused with 4% paraformaldehyde.

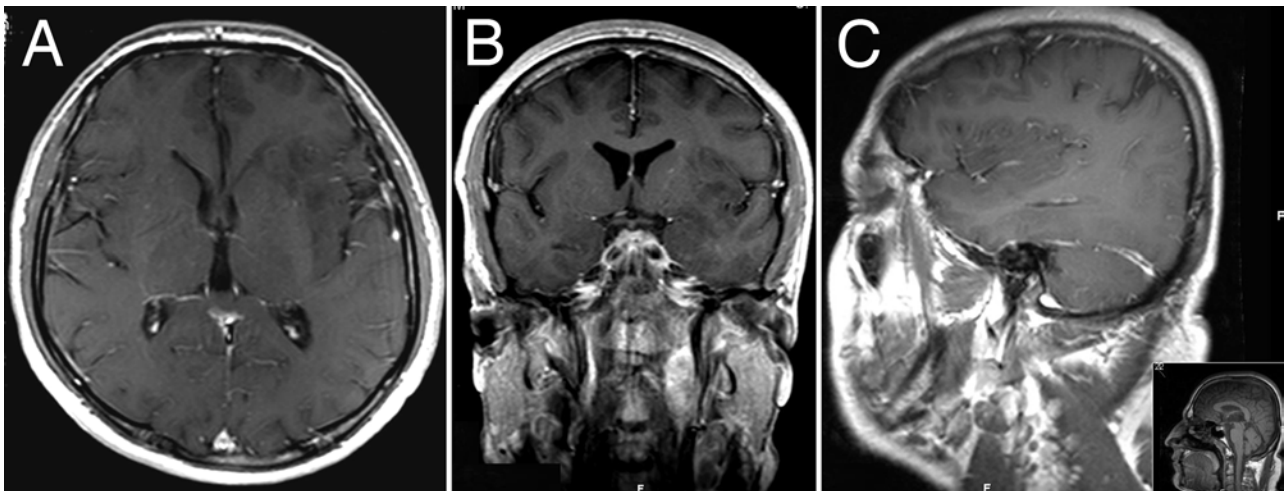


FIG. 1. Illustrative case. Preoperative axial, coronal, and sagittal T1-weighted MR images of the brain obtained with contrast material revealing a left insular tumor.

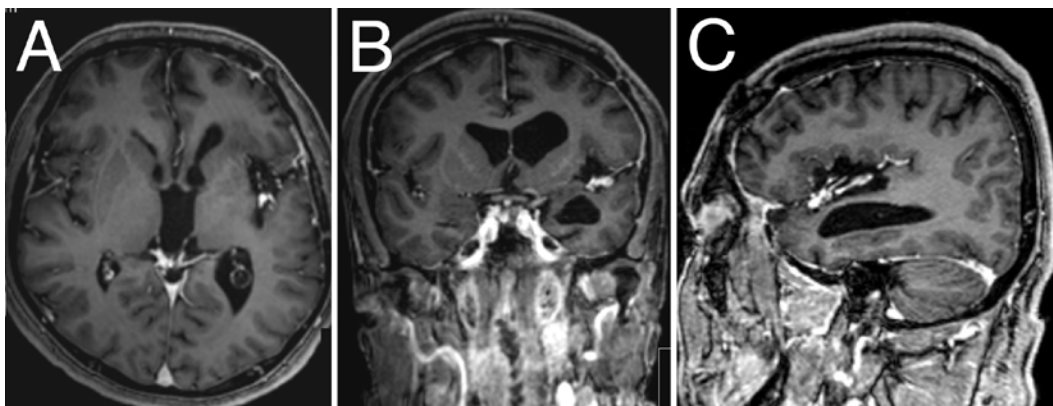


FIG. 2. Illustrative case. Postoperative axial, coronal, and sagittal T1-weighted MR images obtained with contrast material demonstrating total resection of the left insular tumor.

The brain tissues were removed and cryoprotected in 30% sucrose. Serial tangential sections of 20 μ m, passing through the craniectomy area, were cut with a cryostat. These sections were stained with 3-NT antibody to detect structures nitrated with peroxynitrite, which causes changes in protein function by nitrating tyrosine residues on the structures. Staining with an antibody against 3-NT indirectly shows peroxynitrite production. Sections were blocked with 5% normal goat serum for 10 minutes; then they were incubated overnight with 3-NT monoclonal antibody (1:100 dilution, Upstate Biotechnology), washed, and incubated with an appropriate secondary antibody for 3 hours (Cy3 Molecular Probes, Invitrogen). The sections were then mounted with Hoechst solution and examined under a Nikon Eclipse E600 fluorescent microscope.

Results

Tissue Inspection

When H_2O_2 was applied to the cortical surfaces, a

vasoconstrictive response was immediately observed in all the arteries and arterioles within the exposed areas. After 15 seconds of exposure to H_2O_2 , multiple bubbles formed almost instantaneously within the lumen of all subpial arteries in the animals in Group 4, in which pial layers had been destroyed and corticotomies had been done. Surprisingly, bubbles were also observed inside the lumen of surface vessels in the animals in Group 2, in which pial layers were intact, immediately after the H_2O_2 was removed. Application of saline in Groups 1 and 3 did not cause any bubble formation, vasoconstriction, or vasodilation.

Histopathological and Immunofluorescence Examination

No positive staining for 3-NT immunofluorescence was seen in Group 1 (craniectomy only) or Group 3 (craniectomy only plus corticotomy). Significant immunoreactivity for 3-NT in vessel walls was seen in both groups of H_2O_2 -treated mice (Groups 2 and 4). The 3-NT formation was prominent around the vessels below the site

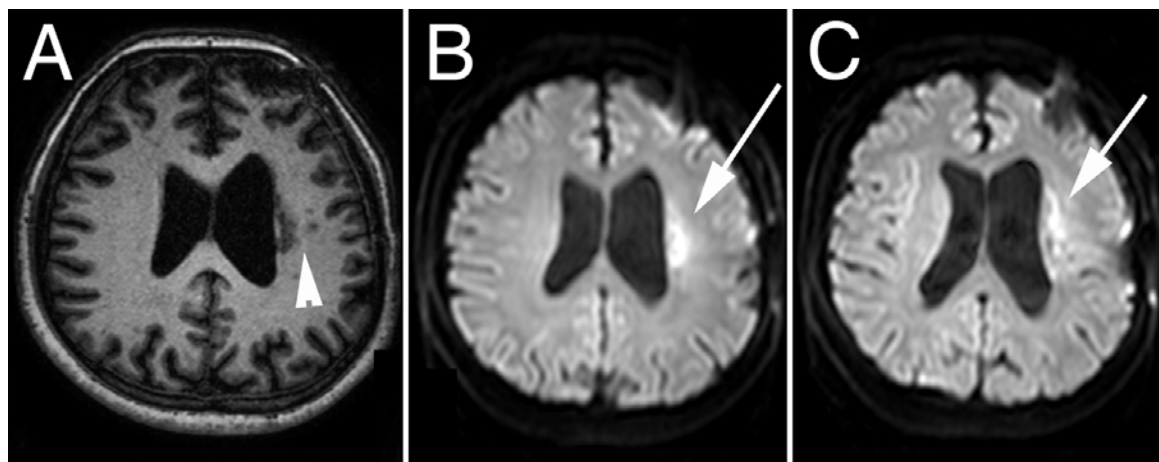


FIG. 3. Axial FLAIR image (A) revealing the punctate areas of infarction in the periventricular white matter (arrowhead). The axial diffusion-weighted images (B and C) reveal the punctate areas of infarction (arrows), which were found in the vascular territory of the LSAs.

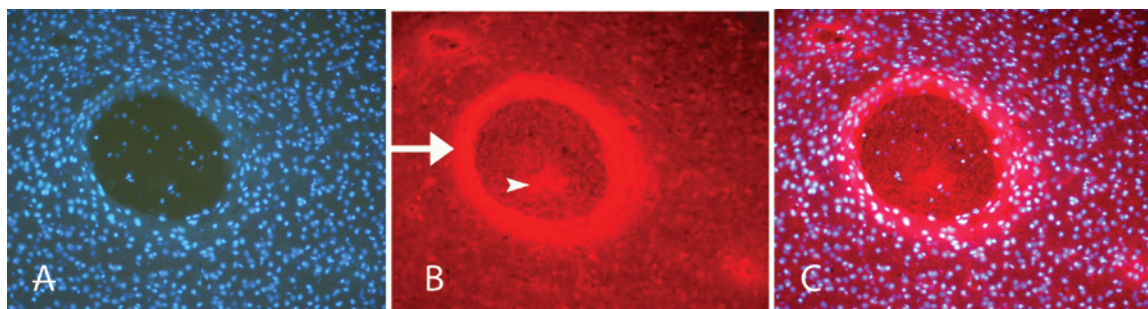


FIG. 4. Photomicrographs showing that application of H_2O_2 produces peroxynitrite in the vessel wall. The tissue section was obtained from the right frontal area in a mouse in which the pia was kept intact and the cortical surface was irrigated with H_2O_2 (Group 2). A: Section with Hoechst staining used as a nuclear marker. B: Section with 3-NT staining in which the peroxynitrite formation was identified. Note the intense perivascular staining encircling a dilated vessel (arrow). Inside the vessel, thrombosis aggregation can be seen (arrowhead). C: The merged images show prominent peroxynitrite formation in the arterial vessel wall. Original magnification $\times 20$.

of H_2O_2 irrigation (Figs. 4 and 5), and there was some positive labeling inside the tissue that clearly reflected the production of peroxynitrite. It is clear that H_2O_2 application caused prominent peroxynitrite production around the vessels. It must also be noted that 3-NT formation was still prominent in the vessels buried within the neuropil below the intact pial layer, emphasizing the passive and free diffusion of H_2O_2 through those layers (Fig. 5).

The addition of H_2O_2 and peroxynitrite production resulted in platelet aggregation and acute thrombus formation within the vessels of animals exposed to H_2O_2 . The thrombus formation was demonstrated in sections stained with H & E (Fig. 6). Vascular occlusion is another mechanism responsible for stroke related to H_2O_2 administration.

Discussion

Induction of O_2 Emboli by H_2O_2

Hydrogen peroxide can permeate cells relatively well, although some movement through cell membranes may occur via aquaporins.² Along with its effects on vascular tone, H_2O_2 can increase the permeability of the endothelium.^{4,9}

A ubiquitous metabolite in living cells, H_2O_2 is known to decompose into water and O_2 by exposure to the family of catalase enzymes. Catalase is found in all cells and acts as a catalyst in the decomposition of H_2O_2 to avoid production of cell-damaging hydroxyl radicals via reaction with iron ions (Fenton reaction), and thereby regulates the concentration of H_2O_2 to physiological levels. The production of O_2 and water from the decomposition of 2 molecules of H_2O_2 by catalase is a multistep reaction with iron as a key intermediate.²⁷

Catalase decomposes H_2O_2 extremely efficiently; up to 200,000 reactions/second. The amount of O_2 suddenly liberated can be large enough to cause serious hemodynamic consequences; 1 ml of 3% H_2O_2 can release 10 ml of O_2 .^{10,37,38} There are sporadic reports of O_2 embolism after irrigation of the surgical field with H_2O_2 during neurosurgical procedures such as cervical spine surgery and lumbar discectomy.^{6,21,22,37,38} In our study, H_2O_2 caused copious O_2 bubbles on the exposed areas of brain (see intraoperative video) after the reaction with catalase in surface cells. More importantly, H_2O_2 resulted in severe O_2 emboli within the surface and also in the deeply embedded arteries and arterioles immediately after its administration to the surface of the brain. Our experimental findings supported the clinical observation that even though

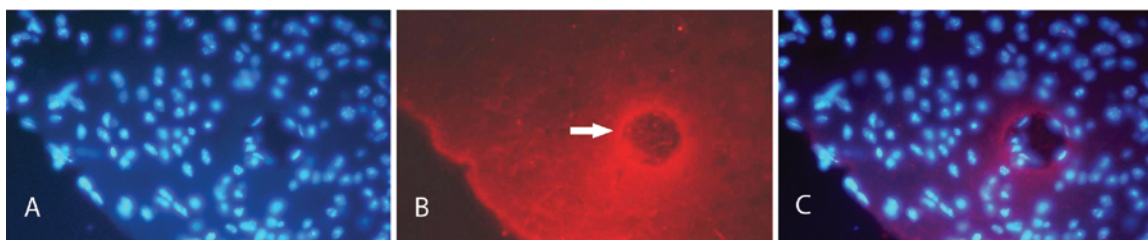


FIG. 5. Photomicrographs showing that H_2O_2 produces peroxynitrite in the vessel wall in which the pial barrier is kept intact. The tissue section was obtained in a mouse frontal lobe just below the area treated with H_2O_2 and in which the pial barrier was kept intact. A: Section with Hoechst staining used as a nuclear marker. B: Section showing prominent peroxynitrite formation around a vessel and very low-intensity 3-NT staining in the tissue. Note that although strongly positive, the stained vessel is not in direct contact with H_2O_2 application; peroxynitrite formed around it, possibly due to migration of H_2O_2 to deep vessels (arrow). C: The merged images show prominent peroxynitrite formation in the arterial vessel wall. Original magnification $\times 40$.

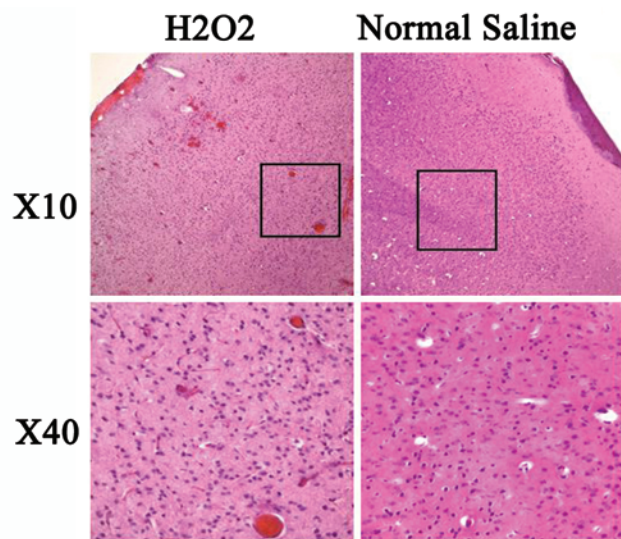


FIG. 6. Photomicrographs of tissue sections showing that H_2O_2 produces acute intravascular thrombus formation in the remote vessels in animals in which the pial barrier is kept intact. *Left:* Tissue section obtained in a mouse frontal lobe just below the area treated with H_2O_2 . H & E staining shows intravascular thrombus formation and occlusion of vessels. *Right:* Tissue section obtained in a mouse frontal lobe just below the area treated with normal saline. H & E staining shows no intravascular thrombus formation and no evidence of vessel occlusion. Original magnifications as marked; boxes delineate the enlarged areas on the lower row.

the LSAs were not visualized during the surgery, H_2O_2 diffused through the putamen and reached these arteries with high affinity to produce O_2 emboli after its decomposition into O_2 and water by the endothelial catalases.

Our findings support the suggestion that the use of an excess amount of H_2O_2 may overwhelm the protective mechanisms of the endothelium, which cannot then cope with the heavy burden of oxidative stress. Excess amounts of H_2O_2 may diffuse into intravascular compartments through the endothelium and decompose into water and O_2 by the action of catalase, in which entrapped free O_2 produces the bubbles. The sudden release of excess amounts of O_2 cannot be managed, and the O_2 itself produces the emboli.

Induction of Vasoconstriction and Vascular Occlusion by H_2O_2

Hydrogen peroxide is commonly used in many neurosurgical centers as a hemostatic agent because of its tentatively identified vasoconstrictive properties,²² but the role of H_2O_2 in regulating cerebral arterial tone is not completely understood. Exposure to H_2O_2 may constrict or dilate vessels depending on the species, the segment of the vessel, and the concentration used.^{1,5,7,20,29} The application of H_2O_2 dilates the BA in rats.²⁴ Although the endothelial layer is believed to play a role in the dilation of cerebral arteries by H_2O_2 , the exact mechanism in the endothelial cell has not been illuminated. The response to H_2O_2 has been variously reported to be endothelium-dependent, to be unaffected by the removal of the endothelium, and to occur only in the absence of endothelium.⁷

In canine BAs, H_2O_2 produced endothelium-dependent contraction in intact vessels,¹⁷ but it produced marked relaxation in arteries without endothelium.¹⁴ When the direct relaxation effects of H_2O_2 on vascular muscle have been observed, there has been strong evidence that the response is mediated by potassium channels. In vivo studies have consistently described the dilator response of small cerebral arteries and arterioles to H_2O_2 .^{19,28,34,35} Very high concentrations of H_2O_2 can produce vasoconstriction followed by vasodilation.¹⁹

Even more perplexing is the fact that H_2O_2 application to mouse brain produced peroxynitrite around the vessel walls (Figs. 4 and 5). Hydrogen peroxide is a toxic ROS that is kept at physiological levels via degradation by catalase and the glutathione/glutathione peroxidase system.²⁵ The ROS may convert to each other through a series of reactions in the presence of nitric oxide synthase, iron, copper, glutathione peroxidase, superoxide dismutase, catalase, and nicotinamide adenine dinucleotide phosphate (reduced form) oxidase.^{7,23,33} In the presence of excess amounts of H_2O_2 , which the protective mechanisms of the endothelium cannot manage, the reaction of NO with H_2O_2 generates peroxynitrite via multiple reactions; a high amount of O_2 inside the vessel can produce superoxide. Production of superoxide exceeding the limits of elimination enters the reaction with NO produced in endothelium, causing peroxynitrite formation.¹⁸ Additionally, hydroxyl radicals generated by the Fenton reaction or H_2O_2 itself react with NO in the presence of iron to produce peroxynitrite.^{8,11,15,16}

The combination of NO and H_2O_2 was particularly cytotoxic and mediated by generated NO radicals. Among the NO radicals, peroxynitrite is a very potent and destructive oxidant and may produce some of its deleterious effects by nitrating tyrosine residues on target proteins. The number of studies showing evidence that peroxynitrite is produced in the brain or cerebral blood vessels under various pathophysiological conditions continues to increase.^{12,13} Nevertheless, relatively few investigators have examined what direct effects peroxynitrite may have on vascular tone. Wei and colleagues³⁵ were the first to show that relatively low concentrations of peroxynitrite dilate cerebral arterioles in vivo. The pharmacological profile they obtained suggested that this response was mediated by adenosine 5'-triphosphate-sensitive potassium channels. In contrast, other studies have reported that peroxynitrite contracts cerebral arteries in vitro via an inhibitory effect of the basal activity of calcium-activated potassium channels.³ In our study in mice, in which we used a high concentration of H_2O_2 administered directly to the brain and cerebral vasculature, severe vasoconstriction followed by vasodilation was observed. This response might be specifically mediated by the production of peroxynitrite in the endothelial cells.

Another deleterious effect of H_2O_2 and peroxynitrite is blood-brain barrier breakdown and intravascular aggregates of platelets and neutrophils and thrombus formation. Although this mechanism has not been mentioned in the surgical literature, platelet aggregation could be another series of events leading to acute thrombus formation and hemostasis after application of H_2O_2 .

Hydrogen peroxide has an affinity to vessel walls. In our experimental study, even when the pial layers were kept intact, H₂O₂ diffused through the neuropil and reached the vessel walls to produce its ROS and resultant vasoactive responses that may be the cause of ischemia. Besides the vasoactive responses and platelet aggregation, which are most likely created by the ROS and nitrous species, the abundant existence of O₂ bubbles within the vessel lumen may result in stroke. In considering significant adverse effects due to H₂O₂ irrigation, formation of O₂ emboli on the vessel wall as well as injury to the wall by ROS should be kept in mind as underlying mechanisms.

Conclusions

Hydrogen peroxide is used in neurosurgical practice as a hemostatic agent. However, it may cause serious complications due to cerebral or systemic O₂ emboli and cerebral vasoconstriction. Because H₂O₂ can easily pass through the intact pial layer and penetrate cerebral vessels, its use intradurally for hemostasis should be prohibited. Hydrogen peroxide can cause severe embolic strokes. In fact, its use should be strictly limited to clearly open wounds in which no possibility of gas entrapment can occur. The only indication for H₂O₂ as a hemostatic agent may be in extradural skull base surgery, but even so, this substance should be cautiously administered with immediate irrigation and removal.

Disclosure

The authors report no conflict of interest concerning the materials or methods used in this study or the findings specified in this paper.

References

1. Ardanaz N, Pagano PJ: Hydrogen peroxide as a paracrine vascular mediator: regulation and signaling leading to dysfunction. **Exp Biol Med** 231:237–251, 2006
2. Bienert GP, Schjoerring JK, Jahn TP: Membrane transport of hydrogen peroxide. **Biochim Biophys Acta** 1758:994–1003, 2006
3. Brzezinska AK, Gebremedhin D, Chilian WM, Kalyanaram B, Elliott SJ: Peroxynitrite reversibly inhibits Ca(2+)-activated K(+) channels in rat cerebral artery smooth muscle cells. **Am J Physiol Heart Circ Physiol** 278:H1883–H1890, 2000
4. Cai H: Hydrogen peroxide regulation of endothelial function: origins, mechanisms, and consequences. **Cardiovasc Res** 68:26–36, 2005
5. Cheranov SY, Jaggar JH: Mitochondrial modulation of Ca²⁺ sparks and transient K⁺ currents in smooth muscle cells of rat cerebral arteries. **J Physiol** 556:755–771, 2004
6. Despond O, Fiset P: Oxygen venous embolism after the use of hydrogen peroxide during lumbar discectomy. **Can J Anaesth** 44:410–413, 1997
7. Faraci FM: Reactive oxygen species: influence on cerebral vascular tone. **J Appl Physiol** 100:739–743, 2006
8. Farias-Eisner R, Chaudhuri G, Aeberhard E, Fukuto JM: The chemistry and tumoricidal activity of nitric oxide/hydrogen peroxide and the implications to cell resistance/susceptibility. **J Biol Chem** 271:6144–6151, 1996
9. Fischer S, Wiesnet M, Renz D, Schaper W: H₂O₂ induces paracellular permeability of porcine brain-derived microvascular endothelial cells by activation of the p44/42 MAP kinase pathway. **Eur J Cell Biol** 84:687–697, 2005
10. Fuson RL, Kysltra JA, Hochstein P, Saltzman HA: Intravenous hydrogen peroxide infusion as a means of extrapulmonary oxygenation. **Clin Res** 15:74, 1967
11. Goldstein S, Meyerstein D, Czapski G: The Fenton reagents. **Free Radic Biol Med** 15:435–445, 1993
12. Gursoy-Ozdemir Y, Bolay H, Saribas O, Dalkara T: The role of endothelial nitric oxide generation and peroxynitrite formation in reperfusion injury after focal cerebral ischemia. **Stroke** 31:1974–1980, 2000
13. Gursoy-Ozdemir Y, Can A, Dalkara T: Reperfusion-induced oxidative/nitrative injury to neurovascular unit after focal cerebral ischemia. **Stroke** 35:1449–1453, 2004
14. Iida Y, Katusic ZS: Mechanisms of cerebral arterial relaxations to hydrogen peroxide. **Stroke** 31:2224–2230, 2000
15. Ioannidis I, de Groot H: Cytotoxicity of nitric oxide in Fu5 rat hepatoma cells: evidence for co-operative action with hydrogen peroxide. **Biochem J** 296:341–345, 1993
16. Ischiropoulos H, Zhu L, Beckman JS: Peroxynitrite formation from macrophage-derived nitric oxide. **Arch Biochem Biophys** 298:446–451, 1992
17. Katusic ZS, Schugel J, Cosentino F, Vanhoutte PM: Endothelium dependent contraction to oxygen-derived free radicals in the canine basilar artery. **Am J Physiol** 264:H859–H864, 1993
18. Koppenol WH, Moreno JJ, Pryor WA, Ischiropoulos H, Beckman JS: Peroxynitrite, a cloaked oxidant formed by nitric oxide and superoxide. **Chem Res Toxicol** 5:834–842, 1992
19. Leffler CW, Busija DW, Armstead WM, Mirro R: H₂O₂ effects on cerebral prostanooids and pial arteriolar diameter in piglets. **Am J Physiol** 258:H1382–H1387, 1990
20. Miller AA, Drummond GR, Schmidt HH, Sobey CG: NADPH oxidase activity and function are profoundly greater in cerebral versus systemic arteries. **Circ Res** 97:1055–1062, 2005
21. Miranda P, Cabrera A, Esparza J, Jerez A: An oxygen embolism after hydrogen peroxide scalp infiltration. Case illustration. **J Neurosurg** 104 (2 Suppl):152, 2006
22. Morikawa H, Mima H, Fujita H, Mishima S: Oxygen embolism due to hydrogen peroxide irrigation during cervical spinal surgery. **Can J Anaesth** 42:231–233, 1995
23. Pacher P, Beckman JS, Liaudet L: Nitric oxide and peroxynitrite in health and disease. **Physiol Rev** 87:315–424, 2007
24. Paravicini TM, Chrissobolis S, Drummond GR, Sobey CG: Increased NADPH-oxidase activity and Nox4 expression during chronic hypertension is associated with enhanced cerebral vasodilatation to NADPH in vivo. **Stroke** 35:584–589, 2004
25. Rauen U, Li T, Ioannidis I, de Groot H: Nitric oxide increases toxicity of hydrogen peroxide against rat liver endothelial cells and hepatocytes by inhibition of cytochrome peroxide degradation. **Am J Physiol Cell Physiol** 292:C1440–C1449, 2007
26. Redondo PC, Jardin I, Hernández-Cruz JM, Pariente JA, Salido GM, Rosado JA: Hydrogen peroxide and peroxynitrite enhance Ca²⁺ mobilization and aggregation in platelets from type 2 diabetic patients. **Biochem Biophys Res Commun** 333:794–802, 2005
27. Sicking W, Korth HG, Jansen G, de Groot H, Sustmann R: Hydrogen peroxide decomposition by a non-heme iron(III) catalase mimic: a DFT study. **Chemistry** 13:4230–4245, 2007
28. Sobey CG, Heistad DD, Faraci FM: Mechanisms of bradykinin-induced cerebral vasodilatation: evidence that reactive oxygen species activate K⁺ channels. **Stroke** 28:2290–2295, 1997
29. Suvorava T, Lauer N, Kumpf S, Jacob R, Meyer W, Kojda G: Endogenous vascular hydrogen peroxide regulates arteriolar tension in vivo. **Circulation** 112:2487–2495, 2005
30. Szabó C, Ischiropoulos H, Radi R: Peroxynitrite: biochemistry, pathophysiology and development of therapeutics. **Nat Rev Drug Discov** 6:662–680, 2007
31. Ture U, Yaşargil DC, Al-Mefty O, Yaşargil MG: Topograph-

- ic anatomy of the insular region. **J Neurosurg** **90**:720–733, 1999
32. Türe U, Yaşargil MG, Al-Mefty O, Yaşargil DC: Arteries of the insula. **J Neurosurg** **92**:676–687, 2000
 33. Valko M, Leibfritz D, Mocol J, Cronin MTD, Mazur M, Telser J: Free radicals and antioxidants in normal physiological functions and human disease. **Int J Biochem Cell Biol** **39**:44–84, 2007
 34. Wei EP, Kontos HA: H₂O₂ and endothelium-dependent cerebral arteriolar dilation. **Hypertension** **16**:162–169, 1990
 35. Wei EP, Kontos HA, Beckman JS: Mechanisms of cerebral vasodilation by superoxide, hydrogen peroxide, and peroxynitrite. **Am J Physiol** **271**:H1262–H1266, 1996
 36. Yaşargil MG: The central zone in white matter (external and internal capsules), in **Microneurosurgery**. Stuttgart: Thieme, Vol 4A, 1994, pp 65–73
 37. Yaşargil MG: **Microneurosurgery**. Stuttgart: Thieme, Vol 4B, 1996, pp 262–276
 38. Zimmerman GA, Lipow KI: Pneumocephalus with neurologi-

cal deficit from hydrogen peroxide irrigation. Case illustration. **J Neurosurg** **100**:1122, 2004

Manuscript submitted September 6, 2007.

Accepted March 10, 2008.

Please include this information when citing this paper: published online October 17, 2008; DOI: 10.3171/2008.3.17434.

Supplemental online information:

Video: To view with Windows Media Player and a broadband connection go to: http://mfile.akamai.com/21490/wmv/digitalwbc.download.akamai.com/21492/wm.digitalsource-na-regional/17434_Mut.asx or to view with RealPlayer go to: http://mfile.akamai.com/21489/rm/digitalwbc.download.akamai.com/21492/real.digitalsource-na-regional/17434_Mut.rm.

Address correspondence to: Melike Mut, M.D., Ph.D., Department of Neurosurgery, Hacettepe University, Beyin Cerrahisi 1. Kat Sihhiye, 06100 Ankara, Turkey. email:melikem@hacettepe.edu.tr or mm2ee@virginia.edu.