

# Closed traumatic head injury: dural sinus and internal jugular vein thrombosis

J M Caplan,<sup>1</sup> Z Khalpey,<sup>1</sup> J Gates<sup>2</sup>

Dural sinus thrombosis (DST) has an annual incidence of 3–4 per million and can result from many aetiologies. Presentation of the disease can vary considerably, as can the aetiology and delay of symptoms to clinical detection. Symptoms on presentation include headache, seizures, focal neural deficits and altered mental status. There are many aetiological risk factors associated with DST, which include hypercoagulable states, oral contraceptive use, infection and mechanical causes such as cranial trauma. DST as a result of trauma is rare and aetiologies range from mechanical falls with or without skull fracture, firework explosions, gunshots to the head, blunt trauma to the head and closed head injury. Internal jugular vein thrombosis is also a rare disease and as with DST, traumatic aetiologies are uncommon. More common aetiologies include iatrogenic causes related to catheterisation as well as infectious causes (eg, Lemierre's syndrome). A case of thrombosis of the transverse sinus, sigmoid sinus and internal jugular vein associated with a closed head injury as the result of a motorcycle accident is presented.

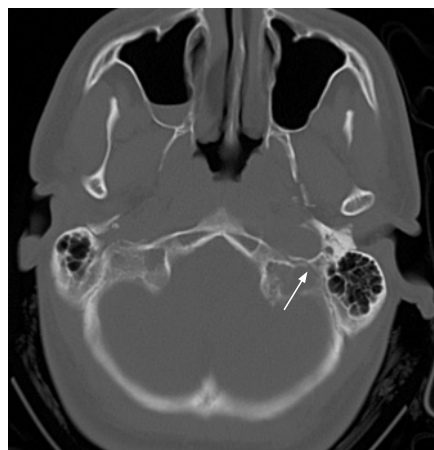
A 27-year-old-man was involved in a high speed (55 mph) motorcycle collision with a tree. He was wearing a helmet. At an outside hospital a maxillofacial and cervical spine computed tomography (CT) scan did not indicate evidence of injury. Given persistent headaches and upper extremity paraesthesias, he was transferred to our institution for evaluation on the day of the accident.

On arrival he complained of bilateral upper extremity paraesthesias. Neurological examination was grossly intact and unremarkable, with the exception of a hoarse voice. Head and neck CT revealed a left side basilar skull fracture lateral to the occipital condyles with fracture lines extending to the hypoglossal canal and jugular foramen (fig 1). A cervical spine magnetic resonance imaging scan and plain cervical spine films revealed no evidence of acute injury. A head and neck magnetic resonance angiography revealed a haemorrhagic contusion in the medial left cerebellar hemisphere and thrombosis of the left sigmoid sinus and left jugular vein (fig 2). Neurologists noted a partial VI nerve palsy with left beating nystagmus and a hoarse voice. Sensation was intact bilaterally.

The patient was admitted and started on subcutaneous heparin. The ENT service noted the left vocal cord was paretic in a paramedian position, with a mild posterior glottis gap; the right vocal cord was normal. Supraglottic sensation was decreased with no cough elicited, consistent with a vagal nerve paralysis, probably secondary to oedema at the site of the skull fracture. Fluoroscopic speech and swallow evaluation showed significant residue with puree and soft solids, but

without evidence of penetration or aspiration. A thin liquid diet was recommended.

On hospital day 3, repeat magnetic resonance venography revealed no interval change. In the interim, the patient was changed to a therapeutic dose of intravenous heparin (without a bolus). An interval head CT on hospital day 5 did not reveal any new haemorrhage; however, there was an area of increased attenuation in the distribution of the transverse sinus, consistent with an extension of the thrombosis. While on therapeutic heparin, he was started on warfarin. Repeat video swallow showed residue within the piriform sinuses and silent aspiration. A diet of thin liquids and thin puree followed by sips was recommended. The patient's warfarin dosing was changed to crushed pills thereafter.



**Figure 1** Axial computed tomography section showing left-sided skull base fracture (arrow) with fracture lines extending to the jugular foramen.

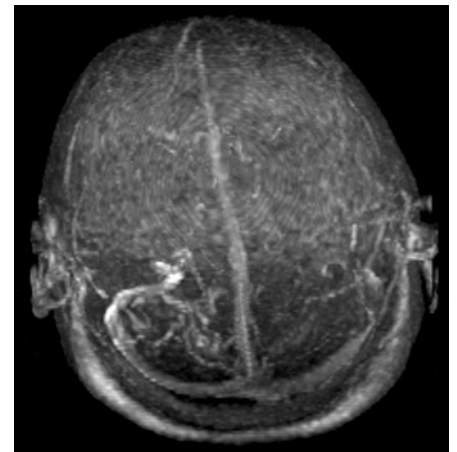
At the time of discharge, the patient's headaches and upper extremity paraesthesias had resolved, an interval head CT showed no significant change and his international normalised ratio was therapeutic (goal 2–3). He was discharged home with planned follow-up in trauma clinic, neurology clinic (including laryngeal electromyography) and ENT clinic.

Three weeks after discharge, he had lost 20 pounds since the accident and had difficulty swallowing liquids and solids. His voice remained soft. The patient was subsequently lost to follow-up. A phone call for the purposes of this case report revealed that the patient stopped taking warfarin at 5.5 months; 2 weeks short of his 6-month course. He reports that his voice has not returned to normal, although it is improved, he is continuing to have difficulty with hoarseness and controlling tone. Furthermore, he continues to have difficulty swallowing, although this too is improved, requiring liquid boluses to help swallow at times.

## DISCUSSION

The incidence of dural sinus thrombosis (DST) is three to four cases per million people per year.<sup>1</sup> Risk factors for DST formation include prothrombotic conditions, infections, inflammatory diseases, haematological conditions, drugs (eg, oral contraceptives), mechanical causes, tumours and iatrogenic causes such as lumbar punctures.<sup>1</sup> Among the mechanical causes are traumatic head injury, as occurred in our patient.

In a prospective study of 624 patients with cerebral vein thrombosis and DST, the superior sagittal sinus was most often



**Figure 2** Three-dimensional magnetic resonance venography projection showing decreased flow within the sigmoid sinus and internal jugular vein.

## Emergency casebook

involved (62%), followed by the lateral sinuses (44.7% and 41.2% left and right, respectively).<sup>2</sup> Jugular veins were involved in 11.9% of cases. Thrombophilia, haematological conditions and infection were among the most common risk factors for all study participants. Pregnancy, puerperium and oral contraceptive use were among the most common risk factors in women. Mechanical precipitants were identified in only 28 patients (4.5%), with cranial trauma identified in only seven (1.1%).

DST can present with headaches most frequently.<sup>1</sup> Other manifestations include focal neurological signs, hemispheric symptoms secondary to cortical lesions, seizures, behavioural symptoms, coma and even death.<sup>1</sup>

Treatment is aimed at preventing cerebral herniation and the prevention of extension or new formation of thrombus. The risks of haemorrhage with anticoagulation should be balanced against the possible complications of the thrombosis, including pulmonary embolism and the development of new venous infarcts.<sup>1-3</sup> A Cochrane literature review revealed that anticoagulation for patients with DST appeared safe and was associated with a non-statistically significant

risk reduction of death and dependency.<sup>3</sup> The role of thrombolysis (either systemic or local) in the management of DST has not yet been fully elucidated.

Internal jugular vein thrombosis (IJVT) is also rare, often associated with infectious aetiologies (eg, Lemierre's syndrome), or vascular trauma associated with catheterisation. IJVT secondary to trauma is uncommon.<sup>4</sup> In one case the authors report traumatic bilateral IJVT associated with increased intracranial pressure, treated endovascularly with urokinase, followed by stenting and anticoagulation.<sup>4</sup> Other traumatic causes reported include neck injuries while exercising and penetrating trauma to the palate.

In conclusion, we present a traumatic head injury with a skull base fracture resulting in a vagal nerve palsy with an associated DST and IJVT. The patient was bridged (via heparin) to warfarin for 5.5 months, with a gradual but progressive improvement of focal neurological symptoms. The merits of and duration of anticoagulation should be further evaluated; one could argue for a longer duration of anticoagulation; however, this would depend on the extent of the functional deficit and evidence from further large-scale

studies. This case study raises awareness of the significance of common closed head and neck injuries associated with the possible neurological sequelae of dural sinus and IJVT.

<sup>1</sup> Department of Surgery, Brigham and Women's Hospital, Harvard Medical School, Boston, Massachusetts, USA; <sup>2</sup> Brigham and Women's Hospital, Harvard Medical School, Boston, Massachusetts, USA

**Correspondence to:** Dr Z Khalpey, Brigham and Women's Hospital (PB-B-4), 75 Francis Street, Boston, MA 02115, USA; [zkhalpey@partners.org](mailto:zkhalpey@partners.org)

**Accepted:** 12 May 2008

**Competing interests:** None.

**Patient consent:** Obtained.

JMC and ZK contributed equally towards this manuscript.

*Emerg Med J* 2008;**25**:777-778.

doi:10.1136/emj.2008.061952

## REFERENCES

1. **Stam J.** Thrombosis of the cerebral veins and sinuses. *N Engl J Med* 2005;**352**:1791-8.
2. **Ferro JM, Canhao P, Stam J, et al.** Prognosis of cerebral vein and dural sinus thrombosis: results of the International Study on Cerebral Vein and Dural Sinus Thrombosis (ISCVT). *Stroke* 2004;**35**:664-70.
3. **Stam J, de Bruijn SFTM, DeVeber G.** Anticoagulation for cerebral sinus thrombosis. *Cochrane Database Syst Rev* 2002;**4**:CD002005.
4. **Duke BJ, Ryu RK, Brega KE, et al.** Traumatic bilateral jugular vein thrombosis: case report and review of the literature. *Neurosurgery* 1997;**41**:680-3.

## Drug and Therapeutics Bulletin (DTB)

**Your key source of unbiased, independent advice**

For over 45 years DTB has been an independent, indispensable part of evidence-based clinical practice. DTB offers healthcare professionals detailed assessment of, and practical advice on, individual medicines and other treatments, groups of treatment and the overall management of disease.

DTB is now also available online at <http://dtb.bmj.com>:

- ▶ browse or search all DTB content from the latest issue back to 1994
- ▶ email alerting, sophisticated searching, RSS feeds and full text links from cited references
- ▶ interactive services such as My Folders for quick access to articles that you have viewed previously and My Searches to save and re-use useful searches
- ▶ comment online on any DTB article

To subscribe, or for further information, please visit <http://dtb.bmj.com>





# Closed traumatic head injury: dural sinus and internal jugular vein thrombosis

J M Caplan, Z Khalpey and J Gates

*Emerg Med J* 2008 25: 777-778  
doi: 10.1136/emj.2008.061952

---

Updated information and services can be found at:  
<http://emj.bmj.com/content/25/11/777>

---

*These include:*

## References

This article cites 4 articles, 1 of which you can access for free at:  
<http://emj.bmj.com/content/25/11/777#BIBL>

## Email alerting service

Receive free email alerts when new articles cite this article. Sign up in the box at the top right corner of the online article.

---

## Topic Collections

Articles on similar topics can be found in the following collections

[Venous thromboembolism](#) (140)  
[Trauma](#) (979)  
[Trauma CNS / PNS](#) (274)  
[Head injury](#) (44)  
[Headache \(including migraine\)](#) (104)  
[Epilepsy and seizures](#) (88)  
[Fractures](#) (212)  
[Pain \(neurology\)](#) (936)

---

## Notes

---

To request permissions go to:  
<http://group.bmj.com/group/rights-licensing/permissions>

To order reprints go to:  
<http://journals.bmj.com/cgi/reprintform>

To subscribe to BMJ go to:  
<http://group.bmj.com/subscribe/>