

Misdiagnosis of spontaneous cervical epidural haemorrhage

Che-Chuan Wang · Chin-Hung Chang ·
Hung-Jung Lin · Kao-Chang Lin · Jinn-Rung Kuo

Received: 12 March 2008 / Revised: 1 September 2008 / Accepted: 17 October 2008 / Published online: 13 November 2008
© Springer-Verlag 2008

Abstract Spontaneous spinal epidural haemorrhage is a rare condition. The initial clinical manifestations are variable. Nonetheless, most spinal cord lesions result in paraparesis or quadriparesis, but not hemi-paresis, if motor function is involved. We report on a 69-year-old man who presented initially with right-side limb weakness. He was initially misdiagnosed at emergency room with a cerebral stroke and treated inappropriately with heparin. One day after admission, correct diagnosis of acute spinal epidural haematoma was based on the repeated neurological examination and cervical magnetic resonance imaging study. The patient underwent emergency surgical decompression and hematoma removal. The pathogenesis of the haematoma could have been due to hypertension, increased abdominal pressure and anticoagulant therapy. We emphasize that patients with hemi-paresis on initial presentation could have an acute spinal epidural haemorrhage. We also draw the misdiagnosis to the attention of the reader because early recognition of spontaneous spinal epidural haematoma is very important for prompt and appropriate treatment to improve the overall prognosis.

Keywords Spontaneous spinal epidural haemorrhage · Hemi-paresis · Cerebrovascular disease

Introduction

Spontaneous spinal epidural haemorrhage (SSEDH) is an uncommon condition. The incidence of SSEDH is estimated to be 0.1 per 100,000 individuals [3]. The typical clinical presentation is acute onset of local and radiation pain, sometimes paresthesia, followed by acute myelopathy [1, 6, 7]. Unilateral hemi-paresis is an extremely rare presentation and is sometimes misdiagnosed for cerebrovascular ischemic disease [5, 8]. The treatment of choice is nearly always surgical decompression [2, 6]. Prognostic factors are strongly related to the time intervals from symptom onset to diagnosis and to surgical decompression, and to the level of pre-operative neurological deficit [4, 6]. The following case report is unusual in that patient with cervical SSEDH presented with hemi-paresis, which led to an initial misdiagnosis.

Case report

A 69-year-old, 75 kg, right-handed man was brought to the emergency room (ER) by ambulance with the chief complaint of sudden onset of neck and shoulder pain followed by right side weakness while he was riding his motorcycle 1 h before arrival at the ER. His blood pressure was 186/104 mmHg on arrival in the ER. He had a history of shoulder trauma 3 months earlier and he had complained of right shoulder soreness since that time. He also had a history of type II diabetes mellitus and hypertension, and was on regular medical treatment. Neurological and physical

C.-C. Wang · C.-H. Chang · J.-R. Kuo (✉)
Department of Neurosurgery, Chi-Mei Medical Center,
901 Chung Hwa Road, Yung Kang City,
Tainan 710, Taiwan
e-mail: cmh7520@mail.chimei.org.tw

H.-J. Lin
Department of Emergency Medicine, Chi-Mei Medical Center,
Yung Kang City, Tainan, Taiwan

K.-C. Lin
Department of Neurology, Chi-Mei Medical Center,
Yung Kang City, Tainan, Taiwan

examinations revealed right-side limb weakness (muscle power scored as 3/5 in right upper and 2/5 in right lower limbs), without sensory impairment. A complete blood count, platelet count, prothrombin time, partial thromboplastin time and biochemistry profile were unremarkable. Based on the patient's elevated blood pressure and right limb paresis, brain computerized tomography (CT) was performed to rule out left cerebral intracranial haemorrhage. The results were normal and no focal lesion was found. Electrocardiography demonstrated normal sinus rhythm. Under the impression of left cerebral infarction, the patient was admitted to the neurology ward for heparin treatment and further evaluation.

After admission, heparin (heparin sodium, China Chemical & Pharmaceutical Co., Ltd, Taipei City, Taiwan ROC) was continuously administered. Neck duplex ultrasound showed mild atherosclerosis in both internal carotid arteries. Brain magnetic resonance imaging (MRI) revealed no evidence of acute brain infarction.

By 26 h after admission, the patient became anxious and complained of neck and severe right shoulder pain. His right side muscle power score fluctuated between 2/5 and 4/5 after heparin treatment. At this time, another neurological examination revealed right-side motor impairment, exaggerated tendon reflexes and an equivocal left-side sensory deficit sparing his face. Emergency cervical spine MRI was performed because of suspected partial Brown-Sequard syndrome. The results revealed a well-defined lesion about $2.5 \times 1.0 \times 0.6$ cm in size with heterogeneous signal intensity in the C4/5 right postero-lateral epidural region, without definite post-contrast enhancement, and causing severe right spinal cord compression (Figs. 1, 2). Under the impression of C4/5 acute spinal epidural haematoma (EDH) with spinal cord compression, the patient underwent an emergency C4/5 laminectomy for removal of the epidural haematoma (Fig. 3). Upon removal of the haematoma, blood continued to ooze from multiple sites on the posterior right C4/5 dural surface

Histological examination disclosed a haematoma without evidence of neoplasm or vessel abnormality. The patient's right shoulder pain improved post-operatively and he had near full recovery of right side muscle power. At the 1 month post-operative follow-up, the patient was asymptomatic and had returned to normal activities.

Discussion

The initial manifestation of SSEDH is non-specific and is easily misdiagnosed [1, 5–8]. In our case, the initial presentation with acute right side hemi-paresis and high blood pressure misled the attending ER physician to suspect a cerebral stroke. These signs led the clinical evaluation to

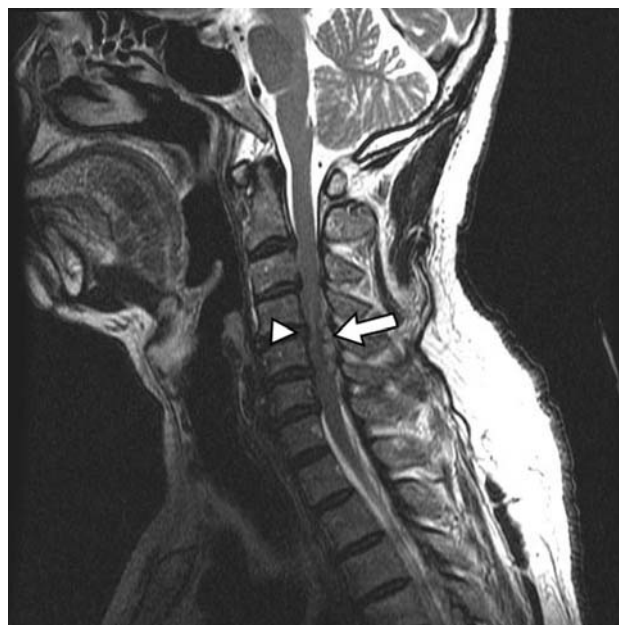

Fig. 1 Sagittal T2-weighted cervical magnetic resonance image shows a longitudinal posterior epidural hematoma from C4 to C5 (arrow), compressing the spinal cord (arrowhead)

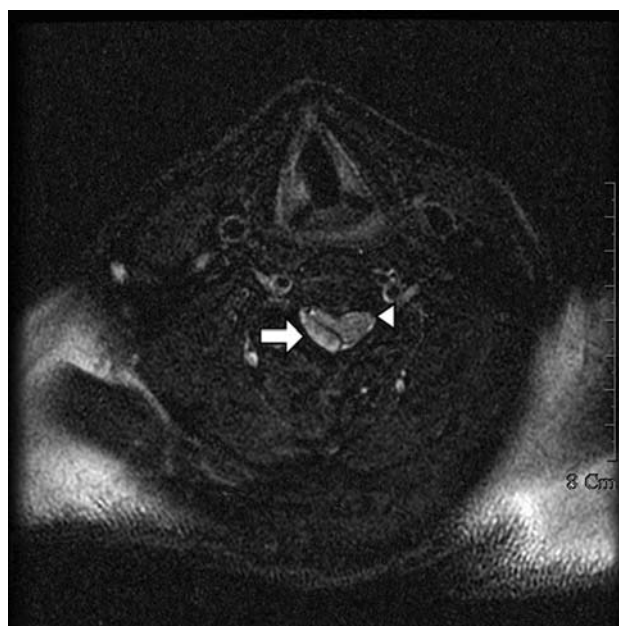

Fig. 2 Axial T2-weighted cervical magnetic resonance image shows an ovoid epidural hematoma (arrow) in the right postero-lateral aspect and spinal cord compression (arrowhead)

focus on the prominent paresis of the patient's arm and leg, and on the neck pain, without searching for other neurological signs. For example, the fact that the patient's face was spared and no specific brain stroke symptoms such as dysarthria, cranial nerve malfunction was not taken into consideration. We emphasize that when a patient has

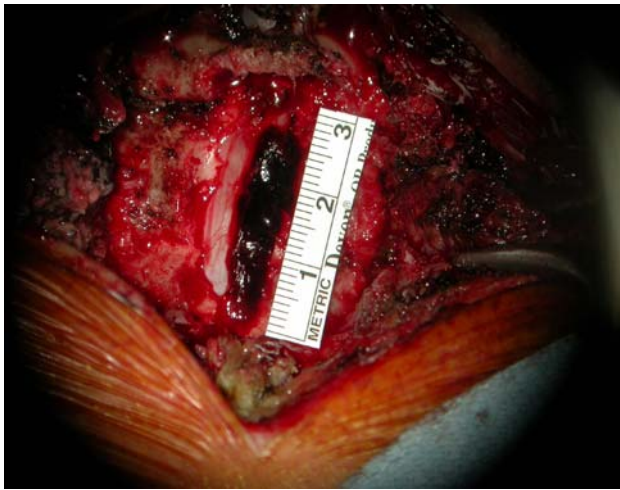


Fig. 3 Intra-operative findings show a $2.5 \times 0.6 \times 1.0$ cm organized hematoma in the right posterior-lateral C4/5 epidural area

hemi-paresis, in the absence of cranial signs or facial palsy, cervical spinal cord lesions such as epidural haemorrhage should always be included in the differential diagnosis.

Although the pathogenesis of SSEDH is unknown, predisposing factors such as coagulopathies, anticoagulant therapy, hypertension, increased venous pressure (increased abdominal pressure), and vascular malformation are described [3, 6]. Our patient had no coagulopathy because the laboratory data showed normal platelets, and normal prothrombin and partial thromboplastin times. The pathological findings disclosed no vascular abnormality. We considered that the initial cause of SEDH in our patient was multifactorial, including his hypertensive condition and increased abdominal pressure with prolonged motor-cycle riding. Furthermore, the unnecessary anticoagulation therapy could have been another major cause of hematoma expansion, with accompanying cord compression. The intra-operative picture showed multiple vessels oozing on the epidural surface supporting this hypothesis.

Prognostic factors after spinal cord compression is diagnosed are strongly related to the time interval between symptom onset and surgical decompression. These intervals appear to be related to the level of pre-operative neurological deficit [4, 6]. Groen [4] demonstrated that better outcomes occur if the time interval is within 48 h in cases of incomplete spinal cord dysfunction and 36 h for complete spinal cord dysfunction. In our patient, surgical evacuation of the haematoma occurred within 27 h of symptomatic onset. We expect that our patient had a favourable outcome because of his incomplete spinal dysfunction at the time of misdiagnosis, the short time to the

correct diagnosis, and our rapid treatment response to the correct diagnosis.

We emphasize that only early recognition, accurate diagnosis and appropriate treatment can decrease morbidity and improved prognosis and outcome for patients with SSEDH.

Conclusion

While we report an unusual clinical presentation for SSEDH, we want to highlight hemi-paresis as a possible initial presentation of acute spinal epidural haemorrhage. Perhaps, the neck pain could draw an attention to the spine symptomatology if the CT study did not show any specific finding. Furthermore, we also draw attention to the complication of misdiagnosis because early recognition of SSEDH is critically important for prompt initiation of appropriate therapy to improve the overall prognosis and outcome.

Conflict of interest statement None of the authors has any potential conflict of interest.

References

- Alexiadou-Rudolf C, Emestus RI, Nanassis K (1998) Acute non-traumatic spinal epidural hematoma. An important differential diagnosis in spinal epidural emergencies. *Spine* 23:1810–1813. doi:[10.1097/00007632-199808150-00018](https://doi.org/10.1097/00007632-199808150-00018)
- Born W, Mohr K, Hassepass U et al (2004) Spinal hematoma unrelated to previous surgery. *Spine* 29:E555–E561. doi:[10.1097/01.brs.0000147743.46315.8b](https://doi.org/10.1097/01.brs.0000147743.46315.8b)
- Groen RJ (2004) Non-operative treatment of spontaneous spinal epidural hematoma: a review of the literature and comparison with operative cases. *Acta Neurochir Wien* 146:103–110. doi:[10.1007/s00701-003-0160-9](https://doi.org/10.1007/s00701-003-0160-9)
- Groen RJ, van Alphen HA (1996) Operative treatment of spontaneous spinal epidural hematomas: a study of the factors determining postoperative outcome. *Neurosurgery* 39:494508. doi:[10.1097/00006123-199609000-00012](https://doi.org/10.1097/00006123-199609000-00012)
- Hsieh CF, Lin HJ, Chen KT et al (2006) Acute spontaneous cervical spinal epidural hematoma with hemiparesis as the initial presentation. *Eur J Emerg Med* 13:36–38. doi:[10.1097/00063110-200602000-00009](https://doi.org/10.1097/00063110-200602000-00009)
- Liao CC, Lee ST, Hsu WC et al (2004) Experience in the surgical management of spontaneous spinal epidural hematoma. *J Neurosurg* 100:38–45
- Muthukumar N (2003) Chronic spontaneous spinal epidural hematoma—a rare cause of cervical myelopathy. *Eur Spine J* 12:100–103
- Sakamoto N, Yanaka K, Ibaraki T, Matsumaru Y (2003) Cervical epidural hematoma causing hemiparesis. *Arch Neurol* 60:783. doi:[10.1001/archneur.60.5.783](https://doi.org/10.1001/archneur.60.5.783)