

K Samura, Y Miyagi, T Morioka, N Murakami, F Yoshida, K Hashiguchi, N Sakae, R Yamasaki, M Kawaguchi, S Nagata, T Sasaki

¹ Department of Neurosurgery, Graduate School of Medical Sciences, Kyushu University, Fukuoka, Japan; ² Division of Digital Patient, Digital Medicine Initiative, Kyushu University, Fukuoka, Japan; ³ Department of Neurosurgery, Kaizuka Hospital, Fukuoka, Japan; ⁴ Department of Neurology, Graduate School of Medical Sciences, Kyushu University, Fukuoka, Japan; ⁵ Department of Rehabilitation, Kyushu University Hospital, Fukuoka, Japan

Correspondence to: Dr Y Miyagi, Division of Digital Patient, Digital Medicine Initiative, Kyushu University, 3-1-1 Maidashi, Higashi-ku, Fukuoka, 812-8582 Japan; yamiyagi@digital.med.kyushu-u.ac.jp

Competing interests: None.

Ethics approval: Ethics approval was obtained.

Patient consent: Obtained.

Received 18 March 2008

Revised 8 July 2008

Accepted 18 July 2008

J Neurol Neurosurg Psychiatry 2008;**79**:1410–1411.
doi:10.1136/jnnp.2008.149831

REFERENCES

1. Honey CR, Stoessl AJ, Tsui JK, *et al.* Unilateral pallidotomy for reduction of parkinsonian pain. *J Neurosurg* 1999;**91**:198–201.
2. Lohrer TJ, Burgunder JM, Weber S, *et al.* Effect of chronic pallidal deep brain stimulation on off period dystonia and sensory symptoms in advanced Parkinson's disease. *J Neurol Neurosurg Psychiatry* 2002;**73**:395–9.
3. Tinazzi M, Del Vesco C, Fincati E, *et al.* Pain and motor complications in Parkinson's disease. *J Neurol Neurosurg Psychiatry* 2006;**77**:822–5.
4. Ford B. Pain in Parkinson's disease. *Clin Neurosci* 1998;**5**:63–72.
5. Shimizu T, Iwata S, Miyata A, *et al.* Delayed L-DOPA-induced hyperalgesia. *Pharmacol Biochem Behav* 2006;**85**:643–7.

Hypokinetic dysarthria and palilalia in midbrain infarction

Dysarthria is a speech disturbance that often occurs following brain damage. The characteristics of dysarthria, however, differ according to the location of the lesion. Hypokinetic dysarthria and palilalia are closely associated with basal ganglionic dysfunction, which is common in patients with Parkinson's disease (PD). In this report, we present a patient who showed these speech problems after left midbrain infarction. The speech disturbance observed in this patient may be caused by the same underlying mechanism as occurs in PD.

CASE REPORT

A 55-year-old diabetic, right-handed woman was admitted to the Asan Medical Centre after suddenly developing diplopia. She was a homemaker with 9 years of education. She had no history of stroke or other brain injury. On neurological examination, she showed left third nerve palsy sparing the pupil, clumsiness in the right arm and slight gait instability. Prominent dysarthria was noted. Muscle strength and sensory perception were normal in the extremities as well

as in the face. Although there was slight ataxia in the right extremities, she was able to walk without difficulty. Her facial expressions were normal, and there was no voice tremor. There was no rigidity, bradykinesia or tremors in the extremities. MRI showed an acute infarct in the paramedian portion of the left midbrain (fig 1A). There were no lesions in the basal ganglia. MR angiogram findings were normal.

Speech language evaluation was performed 4 days after onset. She showed no evidence of aphasia or dysphagia, but there was severe hypokinetic dysarthria with palilalia. Her speech was characterised by hypophonia with breathy and harsh voice quality, mild pitch and loudness variations, imprecise consonants, short rushes of speech and accelerations in AMR/SMR (alternate/sequential motion rate) tasks. Palilalia, compulsive repetitions of parts of or whole words and phrases, and increased speech rate were also frequently noticed across the tasks. There were no deviations of the tongue, and the rate and range of tongue movement were normal. There was no bucco-facial apraxia. Vocal cord examination results were normal. To elucidate the mechanism

underlying her speech disturbances, dopamine transporter positron emission tomography (PET) imaging, using fluorine-18-labelled (fluoropropyl)-2 β -carbomethoxy-3 β -(4-iodophenyl)tropane (¹⁸F-FP-CIT), was performed. There was decreased uptake of ¹⁸F-FP-CIT PET in the left basal ganglia, particularly in the anterior putamen (fig 1B).

One month later, her ocular motor dysfunction had resolved, but the loudness of her voice was still reduced and she had slight difficulty using chopsticks. Four months after admission, mild hypokinetic dysarthria was still present, whereas palilalia was no longer observed.

DISCUSSION

Dysarthria occurs in approximately half of patients with pure midbrain infarction and is most often related to weakness and incoordination of bulbar muscles caused by involvement of the pyramidal tract or fibres connecting with the cerebellum. In our patient, however, bulbar motor function was intact. As speech evaluation showed slight irregularity of pitch and loudness on

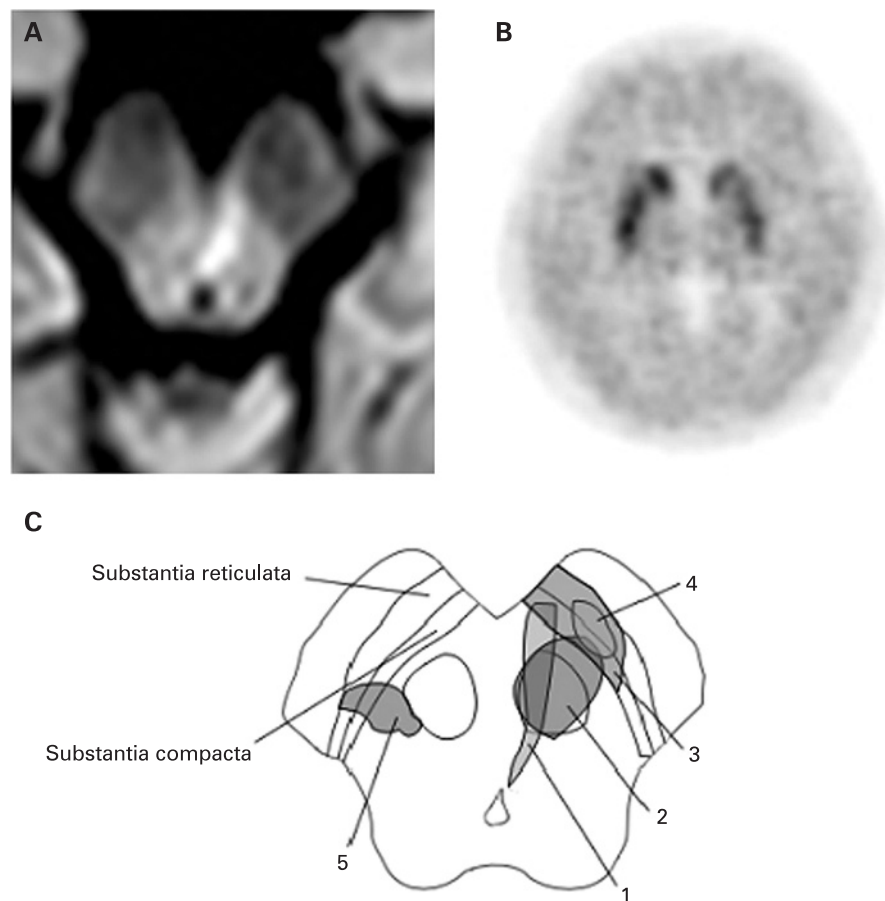


Figure 1 (A) Diffusion weighted MRI showing an acute infarct in the midbrain involving the medial ventral part of the substantia nigra. (B) Fluorine-18-labelled (fluoropropyl)-2 β -carbomethoxy-3 β -(4-iodophenyl)tropane positron emission tomography (¹⁸F-FP-CIT PET) showing decreased uptake in the left basal ganglia, particularly in the anterior putamen. (C) Schematic representation of the midbrain and lesions causing parkinsonian symptoms. (1) Hypokinetic dysarthria and palilalia in our patient; (2) bradykinesia of the right upper limb and micrographia²; (3) micrographia¹; (4) right lower limb tremor⁴; (5) left lower limb tremor³.

vowel prolongation tasks, her dysarthria may have been associated, at least in part, with cerebellar tract involvement. However, hypokinetic dysarthria and palilalia, characteristics of basal ganglionic dysfunction, were the most predominant features in this patient.

To elucidate the mechanism underlying her speech disturbances, we used ^{18}F -FP-CIT PET imaging. FP-CIT is a ligand that is specific to the dopamine transporter in the presynaptic dopaminergic neurons in the striatum and can therefore be used to assess the integrity of dopaminergic nerve terminals in the striatum. The PET scan revealed decreased ^{18}F -FP-CIT uptake in the left basal ganglia, including the caudate nucleus, which was most marked in the anterior part of the putamen. This result, together with previous reports showing micrographia,¹ micrographia with bradykinesia² and lower limb tremors^{3,4} after a focal lesion in the midbrain, suggests that the speech disorder observed in our patient may have been related to disruption of nigrostriatal dopaminergic pathways involving the substantia nigra pars compacta (fig 1C).

The lesion in our patient seems to have involved the most ventral–medial part of the substantia nigra, which was associated with decreased FP-CIT uptake mainly in the medial–anterior part of the putamen. This topography of nigrostriatal projections (medial nigra to medial striatum, and lateral nigra to lateral striatum) has been shown to be maintained in rodents, although the interconnecting fibres are more overlapping in primates.⁵ In patients with PD, nigral cell loss is greatest in the middle or lateral substantia nigra, and their motor symptoms correlate well with decreased uptake in the posterior putamen. Moreover, sensorimotor representation in the putamen of primates consists of zones of the lower limb in the posterior part, of the face in the anterior part and of the upper limbs in the middle.⁵ These findings may explain why our patient, with lesions selectively involving the medial substantia nigra producing anterior putaminal dopaminergic dysfunction, had hypokinetic dysarthria and palilalia without PD symptoms in the extremities; leg tremors are associated with lesions involving the more lateral part of the substantia nigra (fig 1C).

Finally, palilalia improved earlier than hypokinetic dysarthria in our patient. In general, palilalia is observed in patients with more advanced stage PD compared with hypokinetic dysarthria. Thus the different course of recovery of speech symptoms may be related either to different thresholds of symptom development or slightly different pathophysiological mechanisms of these two symptoms.

M Kwon,¹ J-H Lee,¹ J Kim,² J S Kim¹

¹ Department of Neurology, Asan Medical Centre, University of Ulsan College of Medicine, Seoul, South Korea;

² Department of Nuclear Medicine, Asan Medical Centre, University of Ulsan College of Medicine, Seoul, South Korea

Correspondence to: Professor J S Kim, Department of Neurology, Asan Medical Centre, Song-Pa PO Box 145, Seoul 138-600, South Korea; jongskim@amc.seoul.kr

Funding: This study was supported by a grant from the Brain Research Centre of the 21st Century Frontier Research Program funded by the Ministry of Science and Technology of Korea (M103KV010010 06K2201 01010).

Competing interests: None.

Patient consent: Obtained.

Received 8 April 2008

Revised 17 June 2008

Accepted 4 July 2008

J Neural Neurosurg Psychiatry 2008;**79**:1411–1412.

doi:10.1136/jnnp.2008.151530

REFERENCES

1. Kim JS, Im JH, Kwon SU, *et al.* Micrographia after thalamo-mesencephalic infarction: evidence of striatal dopaminergic hypofunction. *Neurology* 1998;**51**:625–7.
2. Morgan JC, Sethi KD. Midbrain infarction with parkinsonism. *Neurology* 2003;**60**:E10.
3. Akyol A, Akyildiz UO, Tataroglu C. Vascular parkinsonism: a case of lacunar infarction localized to mesencephalic substantia nigra. *Parkinsonism Relat Disord* 2006;**12**:459–61.
4. Gonzalez-Alegre P. Monomelic parkinsonian tremor caused by contralateral substantia nigra stroke. *Parkinsonism Relat Disord* 2007;**13**:182–4.
5. Lynd-Balta E, Haber SN. The organization of midbrain projections to the striatum in the primate: Sensorimotor-related striatum versus ventral striatum. *Neuroscience* 1994;**59**:625–40.

Abnormal transcranial magnetic stimulation in a patient with presumed psychogenic paralysis

Conversion disorders (CD) are frequently related to the locomotor system (paresis, abnormal movements) but also to the somatosensory system (positive and negative symptoms) or visual system (tunnel vision, blindness).^{1,2} CD is classified within the group of “somatoform disorders” in the Diagnostic and Statistical Manual of Mental Disorders-IV and its definition implies that the patient has no voluntary control over the production of symptoms (unlike factitious disorder or malingering). The reported rate of misdiagnosis of conversion symptoms has, on average, been 4% since 1970.¹ Psychogenic paralysis (PP) is generally a diagnostic challenge for the neurologist, usually leading to an expensive work-up to exclude organic lesions.

There are several theories explaining CD. There are, however, few methods that are able to highlight the mechanisms underlying this disorder.^{1,2} Some reports suggest that functional brain imaging³ and neurophysiological studies may prove to be a useful approach. We report a case of PP where changes in transcranial magnetic stimulation (TMS) were found.

A 25-year-old married healthy woman was referred to the neurology department with a 3 day history of mild headaches and gradual left lower limb weakness which progressed to affect the left upper limb. She had no pain but mentioned numbness in both lower limbs. She suffered from urinary retention, and catheterisation was performed. Two days

later it was possible to remove the catheterisation without any complications.

The previous year she had suffered generalised arthralgia but no definite diagnosis was made after extensive investigation. She had no personal or family history of psychiatric or neurological disorders, in particular migraine, and she was not taking any CNS medications.

On neurological examination she was calm, showing no concern for her disability, cranial nerve examination was unremarkable, the right limbs had normal power but the left limbs showed marked paresis, with the left lower limb showing no movement (even after noxious stimuli). Pinprick hypoaesthesia was discovered with a T8 midline sharp sensory level and anaesthesia in the left lower limb. In addition, frequent errors for positional sense were observed in the left toes. Reflexes were weak but symmetric, and plantar response was flexor on the right side but seemed absent on the left.

On admission the medical staff noticed normal left body movements when the patient was distracted. The patient underwent a psychiatric interview and the diagnosis of presumed PP was confirmed. Immediately, the patient assumed that she had suffered stressful events at the time of symptoms onset (familial conflicts) and 30 min later she started walking with no support.

A number of investigations were performed. Brain and spinal cord MRI were normal. CSF analysis was unremarkable. Nerve conduction studies, and visual and somatosensory evoked potentials were normal. TMS showed a clearly asymmetric corticomotor threshold (minimum intensity able to evoke $\geq 50\%$ responses with more than 50 μV of amplitude in 10 consecutive stimuli), which was higher on the right hemisphere (table 1). Moreover, the motor evoked potential (MEP) recorded in the left abductor hallucis had a very small amplitude. Central conduction times (using Kimuras formula to calculate peripheral conduction time) were normal (table 1).

The very positive reaction to the psychiatry intervention and the absence of any secondary gain favoured the diagnosis of CD. Escitalopram was started and the patient was referred to the psychiatry outpatient clinic. She remained well on follow-up, with no neurological symptoms.

One month after admission TMS was repeated. MEP amplitudes and abnormal right hemisphere corticomotor threshold became normal (table 1).

Motor evoked potentials have been suggested to be useful in the diagnosis of PP, as they are normal in these patients. In our patient, central conduction time was normal in both the lower and upper limbs, and symmetric. In contrast, the corticomotor threshold was clearly asymmetric, being increased in the right hemisphere. This abnormal asymmetry normalised on the second study. Either cortical or lower motor