

Acute auditory agnosia as the presenting hearing disorder in MELAS

Gabriele Miceli · Guido Conti · Alessandro Cianfoni
Raffaella Di Giacomo · Patrizia Zampetti · Serenella Servidei

Received: 29 April 2008 / Accepted in revised form: 19 September 2008 / Published online: 15 November 2008
© Springer-Verlag 2008

Abstract MELAS is commonly associated with peripheral hearing loss. Auditory agnosia is a rare cortical auditory impairment, usually due to bilateral temporal damage. We document, for the first time, auditory agnosia as the presenting hearing disorder in MELAS. A young woman with MELAS (A3243G mtDNA mutation) suffered from acute cortical hearing damage following a single stroke-like episode, in the absence of previous hearing deficits. Audiometric testing showed marked central hearing impairment and very mild sensorineural hearing loss. MRI documented bilateral, acute lesions to superior temporal regions. Neuropsychological tests demonstrated auditory agnosia without aphasia. Our data and a review of published reports show that cortical auditory disorders are relatively frequent in MELAS, probably due to the strikingly high incidence of bilateral and symmetric dam-

age following stroke-like episodes. Acute auditory agnosia can be the presenting hearing deficit in MELAS and, conversely, MELAS should be suspected in young adults with sudden hearing loss.

Keywords MELAS syndrome · Auditory agnosia · Temporal lobes · Hearing loss · Bilateral and symmetric stroke-like episodes

Introduction

MELAS (Mitochondrial myopathy, Encephalopathy with seizures and/or dementia, Lactic Acidosis and Stroke-like episodes) is a rare disorder, resulting from mitochondrial DNA (mtDNA) mutations [1, 2]. Mild-to-severe sensorineural hearing loss (SNHL) of cochlear origin affects more than 75% of MELAS subjects [3].

Auditory agnosia (i.e., inability to process environmental sounds and speech, in the absence of aphasia) is a rare cognitive disorder. Most cases result from bilateral temporal or putaminal lesions, but reports of unilateral or brainstem damage are on record [4]. Stroke is by far the most frequent cause [4], but occasionally other aetiologies were reported [5–7].

Auditory agnosia is mentioned as an incidental finding in some MELAS cases with advanced disease and severe pre-existing SNHL [8–11]. In our subject, it was the presenting auditory symptom.

Case history

A right-handed woman of 36, a lawyer, acutely presented with transient hemianopia in May 2002 (left) and in

G. Miceli (✉)

Center for Mind-Brain Sciences
Dept. of Cognitive and Educational Sciences
University of Trento
Corso A. Bettini 31, 38068 Rovereto, Italy
e-mail: gabriele.miceli@unitn.it

G. Conti
Department of Otolaryngology
Università Cattolica, Rome, Italy

A. Cianfoni
Department of Radiology
Università Cattolica, Rome, Italy

R. Di Giacomo · S. Servidei
Department of Neuroscience
Università Cattolica, Rome, Italy

P. Zampetti
Fondazione Don Gnocchi IRCCS
Rome, Italy

November 2003 (right). On the latter episode, which followed minor physical exercise and was associated with high serum lactate levels, MRI showed left occipital damage and MRI-spectroscopy revealed increased lactate and decreased N-acetyl aspartate, even in intact areas (images are not available, as these exams were performed at a different hospital, before the subject was referred to the Authors). Muscle biopsy showed mitochondrial abnormalities typical of MELAS. A3243G DNA mutations were documented in mitochondrial genomes in muscle (50%) and blood (45%) [2].

Hearing and cognitive functions were clinically normal until May 2004 when, following minor exercise, our patient experienced sudden hearing loss. On admission, narratives were fluent and syntactically complex, with very isolated semantic substitutions. Voice pitch was louder than normal, according to the patient's husband. There was severe difficulty understanding speech (unless lipreading was allowed) and environmental sounds.

Lactic acid at rest was 4.9 mEq/l (n.v. 0.5–2.2). Treatment with coenzyme Q10 and steroids yielded regression after 3 weeks.

Case study (4–15 days post-onset)

Audiological testing shows a marked cortical auditory disorder, associated with mild SNHL (Fig. 1a–d).

MRI (Fig. 1e) shows bilateral, almost symmetrical damage to superior temporal gyri (damage to left Heschl's gyrus is extensive) and circumscribed damage to posterior inferomesial temporal regions (right parahippocampal gyrus and subiculum; portions of left parahippocampal and fusiform gyri). In these regions, diffusion-weighted MR and apparent diffusion coefficient (ADC) findings suggest acute vasogenic oedema, and MR spectroscopy reveals increased lactate and reduced N-acetyl aspartate. No occipital damage was evident.

Language testing [12] shows a clear and selective difficulty processing auditory verbal input. Our subject performed very poorly on auditory tasks, and obtained normal scores on analogous visual tasks that use stimuli of comparable linguistic complexity (Table 1). Performance on the auditory word–picture matching task is relatively less disrupted than that on other auditory tests, presumably because this easy task only involves matching an

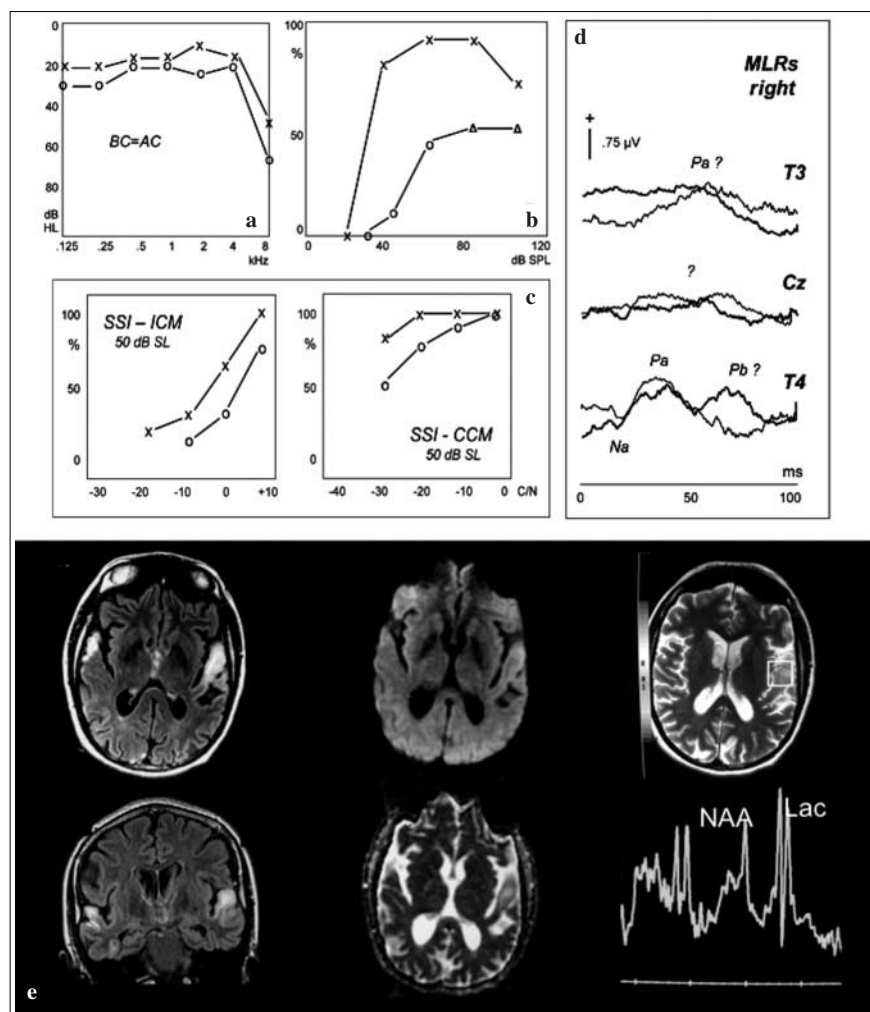


Fig. 1a–d Audiological evaluation. **a** Pure tone audiometry. **b** Speech audiometry (bisyllabic words): maximum intelligibility scores decreased to 50% in the right ear and 90% in the left, where a “roll over” phenomenon (from 90 to 70%) was evident. **c** Synthetic Sentence Identification test (SSI): mild impairment during the ipsilateral competing message (ICM) procedure and severe impairment during the contralateral competing message (CCM) procedure, mostly in the right ear. **d** Middle latency electric responses (MLRs): absent at the vertex, recordable at electrode sites over the temporal lobes where clear response abnormalities were found, in particular over the left temporal lobe after right ear stimulation. Symbols: right (O: unmasked, Δ : masked) and left (X: unmasked) air conduction threshold. **e** MRI through the superior temporal gyri. *Left*: increased T2-FLAIR signal and swelling. *Middle*: faint hyperintensity in DWI images (top) and high signal in ADC map (bottom) suggesting unrestricted diffusion due to vasogenic oedema. *Right*: single voxel proton-MRI spectroscopy TE 35: increased lactate (Lac) and reduced N-acetyl aspartate (NAA) peaks

Table 1 Performance on neuropsychological tasks [12]

	Input modality Auditory	Cut-off	Visual	Cut-off
Phoneme discrimination (n=60)	14 (23.3)	2	0 (0.0)	1
Lexical decision (n=80)	15 (18.7)	3	4 (5.0)	3
Word–picture matching (phonemic/orthographic foil) (n=30)	4 (13.3)	2	1 (3.3)	2
Sentence–picture matching (auditory: n=60; visual: n=45)	16 (26.7)	3	2 (4.4)	2
Nonword transcoding tasks				
Dictation (n=25)	16 (64.0)	1		
Repetition (n=36)	17 (47.2)	1		
Reading aloud (n=45)			1 (2.2)	1
Word transcoding tasks				
Dictation (n=46)	11 (23.9)	2		
Repetition (n=45)	17 (37.8)	1		
Reading aloud (n=92)			3 (3.3)	2
Sentence processing tasks				
Sentence repetition (n=20)	15 (75.0)	1		
Reading sentences aloud (n=6)			0 (0.0)	1

Incorrect responses in tasks requiring auditory vs. visual input processing (percentages in parentheses). Auditory and visual stimuli are matched for structural and linguistic complexity. *Cut-off*: scores above which performance is pathological, based on the performance of 20 matched controls

auditorily presented word to one of two pictures, representing the target and a phonological foil (e.g., *finestra–minestra*, *window–soup*). Errors in all auditory verbal tasks never resulted in semantically based errors.

Performance on writing-to-dictation tasks shows response accuracy to be constrained by damaged auditory input. All the items repeated correctly were also spelled correctly (words: 35/46, 76.1%; nonwords: 9/25, 36%) and all those repeated incorrectly were misspelled (words: 11/46, 33.9%; nonwords: 16/25, 64%). For the latter items, the written response systematically matched repetition (e.g., when “*pezzo*”, piece was dictated, our subject repeated “*perso*”, lost, and wrote *perso*). Consistent with the view that errors in writing-to-dictation result from poor phonological input processing, similar errors never occurred in written picture naming.

Our subject was very frustrated by her difficulty performing verbal auditory tasks and was not available for a formal evaluation of non-verbal auditory processing. However, the few anecdotal and clinical data that are available clearly indicate that her disorder extends to non-verbal auditory processing. She claimed to be unable to identify familiar voices (immediate family) and environmental sounds, and on clinical testing misnamed 6/10 common environmental sounds (e.g., *footsteps>hammer*).

Discussion

Peripheral SNHL is detected in most MELAS subjects [2], but cortical auditory disorders are seldom acknowledged.

However, at least four published reports are consistent with cortical hearing damage. In a subject with SNHL, seizures and *cacosmia* following left temporal damage, a further stroke-like episode 5 months later caused bilateral temporal lesions, which resulted in auditory agnosia and evolved into global aphasia in 3 days [8]. Another case with consecutive temporal stroke-like lesions suffered from transient “*sensory aphasia*”, auditory hallucinations and word discrimination difficulties [9]. In yet another subject, sudden worsening of long-standing SNHL was associated with bitemporal damage [10]. Finally, in an additional case with extensive bitemporal lesions, severe SNHL may have completely masked a cortical auditory disorder [11]. In these cases, then, SNHL was the presenting auditory symptom and central auditory disorders developed at an advanced stage of the disease.

Our case contrasts with previous reports as auditory agnosia was the presenting auditory symptom. This peculiar clinical onset might result from relatively low levels of A3243G DNA mutations in muscle (50%). Since typically in MELAS a direct correlation is observed between percentage of DNA mutations in muscle and severity of SNHL [11], relatively low levels of mutations in our case may have yielded a mild SNHL, which did not mask the acute cortical auditory disorder. Noticeably, however, the same low percentage of DNA mutations did not correspond to a milder clinical course as repeated stroke-like episodes occurred in the ensuing two years.

Considering that both MELAS syndrome and auditory agnosia are extremely rare, their co-occurrence in 5 subjects is striking. This fact might be related to the frequent

occurrence of bilateral stroke-like episodes in MELAS. Our subject developed four lesions to essentially symmetric structures in the same episode – two large lesions in the superior and transverse temporal gyri (responsible for the auditory agnosia), and two smaller inferomesial temporal lesions. A review of 66 published cases with stroke-like episodes (Di Giacopo et al., unpublished) shows that symmetric lesions of simultaneous onset, particularly in the parietal, temporal and occipital lobes, are common. They are observed at onset in 27.7% (18/66) subjects and at some stage of the disease in 60% (39/66). Given the genetic nature of MELAS, it is reasonable to speculate that acute damage affects structures that are particularly vulnerable to metabolic imbalance. Consistent with this possibility, increased apparent diffusion coefficient (ADC map), suggesting vasogenic oedema, is observed in stroke-like lesions [13, 14]. Understanding why middle-posterior encephalic regions are the preferred targets of stroke-like lesions in MELAS is a much more complex issue, which can only be dealt with in the context of large case series.

From the clinical viewpoint, these observations mandate careful screening for cortical auditory disorders in young adults with sudden hearing loss and suggest that a sudden hearing loss in a young adult should raise the suspicion of MELAS.

Acknowledgements Support from MIUR, Telethon (GGP02253) and Università Cattolica is acknowledged.

Direct or potential Conflict of Interest statement The Authors declare that they have no conflict of interest related to the publication of this manuscript

References

- Hirano M, Pavlakis SG (1994) Mitochondrial myopathy, encephalopathy, lactic acidosis and stroke-like episodes (MELAS): current concepts. *J Child Neurol* 9:4–13
- Thambisetty M, Newman NJ (2004). Diagnosis and management of MELAS. *Expert Rev Mol Diagn* 5:631–644
- Sue CM, Lipsett LJ, Crimmins DS et al (1998) Cochlear origin of hearing loss in MELAS syndrome. *Ann Neurol* 43:350–359
- Simons JS, Lambon Ralph MA (1999) The auditory agnosias. *Neurocase* 5:379–406
- Shivashankar N, Shashikala HR, Nagaraja D et al (2001) Pure word deafness in two patients with subcortical lesions. *Clin Neurol Neurosurg* 103:201–205
- Otsuki M, Soma Y, Sato M et al (1998) Slowly progressive pure word deafness. *Eur Neurol* 39:135–140
- Tobias E, Mann C, Bone I et al (1994). A case of Creutzfeldt-Jakob disease presenting with cortical deafness. *J Neurol Neurosurg Psychiatry* 57:872–873
- Johns DR, Stein AG, Wityk R (1993) MELAS syndrome masquerading as herpes simplex encephalitis. *Neurology* 43:2471–2473
- Kamada K, Takeuchi F, Houkin K et al (2001) Reversible brain dysfunction in MELAS: MEG, and 1H MRS analysis. *J Neurol Neurosurg Psychiatry* 70:675–678
- Tawankanjanachot I, Channarong NS, Phantumchinda K (2005) Auditory symptoms: a critical clue for diagnosis of MELAS. *J Med Assoc Thai* 88:1715–1720
- Chinnery PF, Elliott C, Green GR et al (2000) The spectrum of hearing loss due to mitochondrial DNA defects. *Brain* 123:82–92
- Miceli G, Laudanna A, Burani A, Capasso R (1994) Batteria per l'Analisi dei deficit Afasici. CEPSAG, Rome
- Ohshita T, Oka M, Imon Y et al (2000). Serial diffusion-weighted imaging in MELAS. *Neuroradiology* 42:651–656
- Kolb SJ, Costello F, Lee AG et al (2003) Distinguishing ischemic stroke from the stroke-like lesions of MELAS using apparent coefficient mapping. *J Neurol Sci* 216:11–15