


This article was downloaded by: [George Mason University]

On: 24 December 2014, At: 22:48

Publisher: Routledge

Informa Ltd Registered in England and Wales Registered Number: 1072954 Registered office: Mortimer House, 37-41 Mortimer Street, London W1T 3JH, UK



## Applied Neuropsychology

Publication details, including instructions for authors and subscription information:

<http://www.tandfonline.com/loi/hapn20>

### Neuropsychological Profiling of Ischemic Deficit Secondary to Ruptured Dermoid Cyst: A Case Report

Robin Bhatia <sup>a</sup>, Stuart Anderson <sup>b</sup>, Veronica Bradley <sup>c</sup> & James A. Akinwunmi <sup>a</sup>

<sup>a</sup> Department of Neurosurgery, Hurstwood Park Neurological Centre, Haywards Heath, West Sussex, United Kingdom

<sup>b</sup> Sussex Rehabilitation Centre, Southlands Hospital, Shoreham-by-Sea, West Sussex, United Kingdom

<sup>c</sup> Department of Clinical Neuropsychology, Hurstwood Park Neurological Centre, Haywards Heath, West Sussex, United Kingdom

Published online: 20 Nov 2008.

To cite this article: Robin Bhatia, Stuart Anderson, Veronica Bradley & James A. Akinwunmi (2008) Neuropsychological Profiling of Ischemic Deficit Secondary to Ruptured Dermoid Cyst: A Case Report, *Applied Neuropsychology*, 15:4, 293-297, DOI: [10.1080/09084280802312478](https://doi.org/10.1080/09084280802312478)

To link to this article: <http://dx.doi.org/10.1080/09084280802312478>

PLEASE SCROLL DOWN FOR ARTICLE

Taylor & Francis makes every effort to ensure the accuracy of all the information (the "Content") contained in the publications on our platform. However, Taylor & Francis, our agents, and our licensors make no representations or warranties whatsoever as to the accuracy, completeness, or suitability for any purpose of the Content. Any opinions and views expressed in this publication are the opinions and views of the authors, and are not the views of or endorsed by Taylor & Francis. The accuracy of the Content should not be relied upon and should be independently verified with primary sources of information. Taylor and Francis shall not be liable for any losses, actions, claims, proceedings, demands, costs, expenses, damages, and other liabilities whatsoever or howsoever caused arising directly or indirectly in connection with, in relation to or arising out of the use of the Content.

This article may be used for research, teaching, and private study purposes. Any substantial or systematic reproduction, redistribution, reselling, loan, sub-licensing, systematic supply, or distribution in any form to anyone is expressly forbidden. Terms & Conditions of access and use can be found at <http://www.tandfonline.com/page/terms-and-conditions>

# Neuropsychological Profiling of Ischemic Deficit Secondary to Ruptured Dermoid Cyst: A Case Report

Robin Bhatia

*Department of Neurosurgery, Hurstwood Park Neurological Centre, Haywards Heath, West Sussex, United Kingdom*

Stuart Anderson

*Sussex Rehabilitation Centre, Southlands Hospital, Shoreham-by-Sea, West Sussex, United Kingdom*

Veronica Bradley

*Department of Clinical Neuropsychology, Hurstwood Park Neurological Centre, Haywards Heath, West Sussex, United Kingdom*

James A. Akinwunmi

*Department of Neurosurgery, Hurstwood Park Neurological Centre, Haywards Heath, West Sussex, United Kingdom*

This report presents a case of a 39-year-old male with a spontaneously ruptured fronto-temporal dermoid cyst. Intraoperatively, during surgical resection of the cyst, significant fat spillage occurred associated with a profound anterior circulation vasospasm. The patient underwent serial neuropsychological evaluation over five months, revealing a profile of initial deterioration, followed by delayed recovery of cognitive function. A review of the literature reveals three other case reports describing ischemic deficit after dermoid rupture, but the cognitive impairment associated with this pathology has never been formally profiled before, and it may be possible to draw analogies to the well-established ischemic deficit post-subarachnoid hemorrhage found in the literature. Neuropsychological profiling additionally informs us about the nature and progression of this entity from a cognitive perspective and whether the etiology of deficit caused by dermoid rupture could be localized, or global, secondary to diffuse fatty dissemination in the CSF.

*Key words:* cognition, dermoid rupture, ischemic deficit, neuropsychological, psychometric

## INTRODUCTION

Dermoid cysts are nonmalignant lesions with an incidence in the general population of between 0.04% and 0.6% of

all primary brain tumors (Rubin et al., 1989; Hamel et al., 1980). The most common theory of etiology is that dermoids are congenitally acquired epidermic inclusions arising within the neural groove at the time of closure (gestational weeks 4–6; O’Rahilly & Muller, 1987; Rubenstein, 1972). These cysts are lined by stratified squamous epithelium, as well as other dermal elements; therefore, they contain and enlarge by accumulation of

---

Address correspondence to R. Bhatia, Department of Neurosurgery, Hurstwood Park, Neurological Centre, Haywards Heath, West Sussex, RH16 4EX, UK. E-mail: robbhatia@yahoo.com

secretions of luminal sebaceous glands and desquamated epithelium, for example, hair, fat, and teeth.

Dermoid cysts may be detected coincidentally in an asymptomatic population, may give rise to symptoms related to a mass effect (Sugano et al., 2006), or rupture (Stendal et al., 2002). The latter can run a far from benign course, primarily due to intracranial spillage of dermoid contents and the effects that this material can have on neuroglial and neurovascular tissue, as revealed in the canine animal model (Saski et al., 1981). This case report highlights spontaneous rupture resulting in neurocognitive deficit, and postoperative deterioration related to vasospastic ischemic deficit. We believe that the directly visualized anterior cerebral vasospasm also resulted in the right caudate infarction.

### CASE REPORT

A 39-year-old, right-handed male was referred for neurological assessment by his local practitioner following a two-to-three-week history of headache, lethargy, and poor concentration. His past medical history was unremarkable apart from mild developmental dyslexia. He was neurologically intact on initial examination and fundoscopy revealed bilaterally clear disc margins. An immediate brain MRI was requested, revealing a right frontotemporal space-occupying cystic lesion returning a high signal intensity on T<sub>1</sub>-weighted imaging and isointensity on T<sub>2</sub>-weighted imaging (see Figure 1). The appearance of a fat-fluid level in the lateral ventricles was also apparent. The radiological diagnosis was of a ruptured dermoid cyst, and the patient was referred for a neurosurgical opinion. The decision was then made to conduct a craniotomy and cyst resection.

Prior to surgery a neuropsychological assessment was requested. See Table 1 for psychometric data. The results revealed impairment of verbal recall and learning, impairment of nonverbal recall, spared nonverbal learning, reduced verbal fluency, and poor divided attention. Problem solving, naming, and visual attention were spared. A short immediate-attention span also emerged. During the operation, after induction with propofol, general anesthesia was maintained by propofol and isoflurane. These anesthetic agents are standardly employed in neurosurgical operations, having value in terms of neuroprotection and a minimal side effect profile regarding memory and cognition (Yurdakoc et al., 2008; Becker et al., 2006; Wang et al., 2002). A right subfrontal craniotomy was performed and the cyst was found to be adherent to the right optic nerve and both anterior cerebral arteries. Dissection resulted in further rupture of the cyst and spillage of the dermoid fluid contents, prompting immediate and copious washout with normal saline with hydrocortisone. Complete resection of the

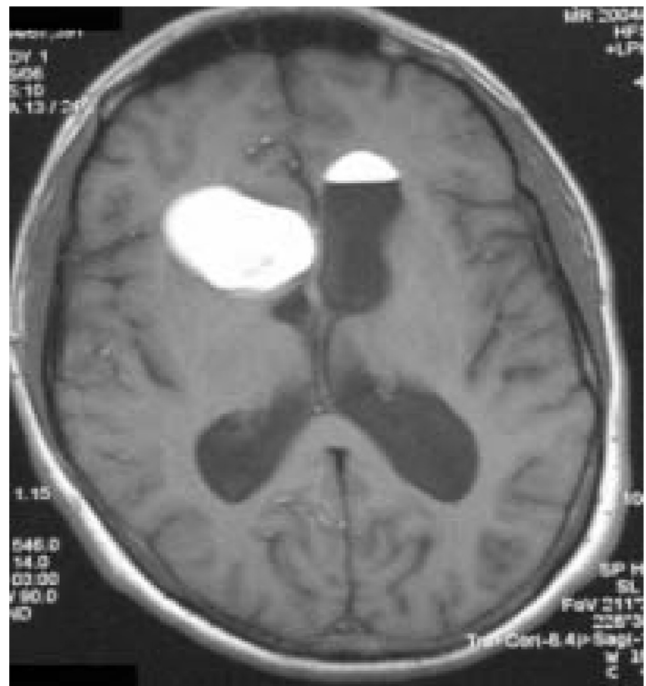

FIGURE 1 Preoperative axial T1-weighted MRI slice revealing the right frontotemporal dermoid cyst, fat-fluid level in the contralateral ventricle and diffuse subarachnoid dissemination of fat droplets notably in the right frontal lobe.

cyst was not possible, and a calcified remnant was left attached to the right anterior cerebral artery. The anterior circulation vessels visibly became vasospastic by the end of the operation. Phenytoin: 1 g intravenously (i.v.) was loaded on induction, and continued (300 mg daily) in the postoperative period. The patient was also commenced on dexamethasone (16 mg daily i.v., reducing to 4 mg daily over the next seven days), and nimodipine 60 mg 4 h i.v. Histology of the specimen confirmed a dermoid cyst capsule containing pilosebaceous units.

The patient awoke with a left-sided motor deficit (Medical Research Council grade: 3/5 arm, 4/5 leg), but this resolved completely over the next five days. Axial CT 10 days postoperatively revealed a right caudate hemorrhagic infarct. Cognition was also severely impaired, and a repeat neuropsychological assessment was requested on day nine (see Table 1). The patient was difficult to assess at this time, and found to be disorientated and confabulatory, with a markedly shortened attention span, prohibiting the administration of a full battery.

After four weeks of rehabilitation, neuropsychological assessment was possible and revealed a widespread impairment of cognitive function. Areas of greatest deficit included attention and working memory, immediate and delayed memory, and executive problem solving. By comparison, visuospatial abilities were unaffected (see Table 1). A dense, anterograde amnesia was evident

TABLE 1  
Pre- and Postoperative Psychometric Data

<i>Post-op follow up</i>					
<i>Measure</i>	<i>Pre-op</i>	<i>9 days</i>	<i>4 wks</i>	<i>9 wks</i>	<i>16 wks</i>
<i>Information processing</i>					
Digits forwards	38	38	30	30	38
Digits backwards	50	37	44	37	37
Trails A	41	–	21	35	31
Trails B	22	–	–	<10	22
Spatial span	–	–	30	47	53
LNS	–	–	27	37	40
<i>Memory</i>					
Story recall (Imm)	31	<10	–	–	–
Story recall (Del)	24	<10	–	–	–
Figure recall (Imm)	39	18	–	–	–
Figure recall (Del)	32	21	–	–	–
List learning	<10	–	–	–	–
Doors & people	–	–	–	–	27
<i>Intellectual</i>					
Vocabulary	–	–	–	60	–
Similarities	50	–	–	57	–
Block design	53	–	–	47	–
Matrix reasoning	–	–	–	50	–
<i>Executive function</i>					
Hayling test	–	–	34	37	37
Brixton test	–	–	27	31	34
Design fluency	–	–	–	37	40
Letter fluency	30	14	–	–	34
Category fluency	48	33	25	31	31
Stroop color/word	–	–	–	–	40
D-KEFS tower	–	–	–	40	37
BADS key search	–	–	38	–	61
<i>General screening</i>					
RBANS total score	–	–	19	23	25
Immediate memory	–	–	24	29	35
Visuospatial	–	–	50	51	51
Language	–	–	33	33	33
Attention	–	–	12	16	23
Delayed memory	–	–	10	13	10

T-scores expressed as range of performance: above average ( $\geq 58$ ), average (43–57), low average (38–42), borderline (31–37), impaired ( $\leq 30$ ). For practical purposes, scores  $\geq 39$  are generally considered as falling below the normal range. LNS=Letter Number Sequencing; D-KEFS=Delis-Kaplan Executive Function System; BADS (Behavioural Assessment of the Dysexecutive Syndrome); RBANS=Repeatable Battery for the Assessment of Neuropsychological Status; Imm=Immediate; Del=Delayed.

and prevented recall of events that had occurred a few minutes earlier. This was accompanied by disorientation, confusion (including reduplicative paramnesia), and retrograde amnesia. Further assessment was completed at nine weeks. Memory functioning remained largely unchanged, but significant gains were noted in visual attention, working memory, and sequencing/divided attention. Behaviorally, the patient remained disoriented, but had started to remember the names of hospital staff. Although nonverbal performance was comparatively weak, improvements in executive ability were accompanied by near normalization of scores on measures of intellectual function.

At four months postdermoid cyst resection, the patient remained in the rehabilitation center, but was

showing signs of cognitive improvement. A 16-week psychometric follow-up revealed continued gains in working memory and slightly better nonverbal recall, although the amnesic disorder persisted. Variable performance was noted on the executive function tasks. Social interactional skills were largely preserved and a positive mood was manifest throughout.

## DISCUSSION

The purpose of this case report is to provide greater insight into the neuropsychological profile and deficits associated with dermoid rupture, an important facet previously not described in the literature. In addition,

it is the goal of this study to elucidate the ability of serial neuropsychological assessment to track cognitive progression following such a CNS insult.

Stendal et al. (2002) reviewed 44 published cases of dermoid and epidermoid rupture, estimating frequencies of complications, including: headache (31.8%), seizures (29.5%), temporary sensor or motor syndrome (15.9%), chemical meningitis (6.9%), "psychosyndrome" (4.5%), visual disturbances (4.5%), and no symptoms (2.3%). The complication of transient and/or delayed ischemic deficit after dermoid rupture is interesting because it may be analogous to the delayed ischemic deficit after subarachnoid hemorrhage. This was first described by Ford et al. (1981) in a case report of a 30-year-old male manifesting transient focal ischemic deficit and the CT appearances of a ruptured dermoid cyst. Shortly after, Mikhael (1982) reported the case of a 37-year-old male with acute left hemiparesis and a ruptured dermoid, together with angiographic evidence of a right supraclinoid carotid vasospasm. In that case, after six weeks there was complete resolution of the clinical deficit and repeat angiography was normal (Mikhael, 1982). More recently, Ecker et al. (1983) reported the onset of right hemiparesis and mixed dysphasia two days post-"uneventful" resection of a left frontal dermoid in a 23-year-old female. Angiography revealed a right-middle cerebral artery vasospasm, and balloon angioplasty was attempted. The outcome at seven months was mild residual right deficit and incoordination (Ecker et al., 2003). In discussion, the dilemma of whether to copiously irrigate spilled contents (reducing local concentration versus further spread of fat droplets) was raised. There is also experimental evidence for the irritating effects of lipid hydroxyperoxides of arachidonic acid on cerebral blood vessels in animal studies (Saskiet al., 1981). Sufficient evidence is accumulating for us to suggest a syndromic entity of "dermoid rupture ischemic deficit"; the natural history and prognosis of this complication, as well as its similarities to or distinction from subarachnoid hemorrhage ischemic deficit, require further data from case series.

It is our belief that the necessary intraoperative manipulation of the cyst resulting in fat spillage was the primary cause for the cognitive deterioration (and preoperative deficit was undoubtedly due to fat spillage after the initial spontaneous rupture). However, we are unable to state with certainty the mechanism by which subarachnoid lipid induces ischemic deficit. The profound cognitive impairment noted after the operation gradually improved as far as information processing, working memory and executive problem-solving skills were concerned, and some of these had approached preoperation levels by the 16-week follow-up. Slight improvements were noted in nonverbal recall, although

significant deficits in learning, retrieval, and recognition memory persisted.

Similar profiles of preserved intellectual ability in the context of memory impairment have been associated with subarachnoid hemorrhage (Irle et al., 1992) and there is the suggestion that the cognitive deficit may be worsened by hydrocephalus and/or vasospasm triggered by collections of blood in the subarachnoid space (Hutter et al., 1998; Hutter et al., 1994). Reduced frontal cerebral blood flow secondary to vasospasm or hydrocephalus in the frontal regions has been proposed as a mechanism through which long-term cognitive deficits can occur, although confirmatory evidence for this is lacking (Ogden et al., 1990; Iddon et al., 1999). A combination of basal forebrain and striate lesions appear to be required to produce persisting memory deficit (Irle et al., 1992). The global cognitive deficit and persisting amnesic disorder described in this instance bears similarities to the neuropsychological profile associated with subarachnoid hemorrhage; it seems likely that this is due to the widely disseminated fat droplets in the subarachnoid space.

In conclusion, neuropsychological profiling plays a significant clinical role in tracking the sometimes quite subtle changes associated with frontal lobe vasospasm due to subarachnoid hemorrhage and dermoid rupture (and thereby alerts the clinician at an early stage to this serious condition). Also, profiling allows the similarities and differences to be made more apparent between blood- and lipid-mediated vasospasm, which may further inform us about the mechanisms underlying it.

## REFERENCES

- Bekker, A., Shah, R., Quartermain, D., Yong-Sheng, L., & Blanck, T. (2006). Isoflurane preserves spatial working memory in adult mice after moderate hypoxia. *Anaesthesia & Analgesia*, *102*, 1134–1138.
- Ecker, R. D., Atkinson, J. L., & Nichols, D. A. (2003). Delayed ischemic deficit after resection of a large intracranial dermoid: Case report and review of the literature. *Neurosurgery*, *52*, 706–710.
- Ford, K., Drayer, B., Osbourne, D., & Dubois, P. (1981). Case report: Transient cerebral ischaemia as a manifestation of ruptured intracranial dermoid cyst. *Journal of Computer Assisted Tomography*, *5*(6), 895–897.
- Hamel, E., Frowein, A., & Karimi-Nejad, A. (1980). Intracranial intradural epidermoids and dermoids. *Neurosurgical Review*, *3*, 215–219.
- Hutter, B. O., Gilsbach, J. M., & Kreitschmann, I. (1994). Is there a difference in cognitive deficits after aneurysmal subarachnoid hemorrhage and subarachnoid hemorrhage of unknown origin? *Acta Neurochirurgica*, *127*, 129–135.
- Hutter, B. O., Kreitschmann-Andermahr, I., & Gilsbach, J. (1994). Cognitive deficits in the acute stage after subarachnoid hemorrhage. *Neurosurgery*, *43*, 1054–1064.
- Iddon, J. L., Pickard, J. D., Cross, J. J. L., Griffiths, P. D., Czosnyka, M., & Sahakian, B. J. (1999). Specific patterns of cognitive impairment in patients with idiopathic normal pressure hydrocephalus and Alzheimer's disease: A pilot study. *Journal of Neurology, Neurosurgery and Psychiatry*, *67*, 723–732.

- Irle, E., Wowra, B., Kunert, H. J., Hample, J., & Kunze, S. (1992). Memory disturbance following anterior communicating artery rupture. *Annals of Neurology*, *31*, 473–480.
- Mikhael, M. A. (1982). Transient spasm of the carotid syphon complicating ruptured dermoid cyst. *Radiology*, *144*, 824–826.
- Ogden, J. A., Levin, P. L., & Mee, E. W. (1990). Long-term neuropsychological effects of subarachnoid hemorrhage. *Neuropsychiatry, Neuropsychology, and Behavioural Neurology*, *3*, 260–274.
- O’Rahilly, R., & Muller, F. (1987). The developmental anatomy and histology of the human central nervous system. In P. J. Vinken, G. W. Btuyn, & H. L. Klawans (Eds.), *Handbook of clinical neurology 50: Malformations* (1–17). New York: Elsevier Science Publishers.
- Rubenstein, L. (1972). Tumors of the central nervous system. *Atlas of Tumour Pathology*, *2*, 288–292.
- Rubin, G., Schienza, R., Pasqualin, A., Rosta, L., & Da Pian, R. (1989). Craniocerebral epidermoids and dermoids: A review of 44 cases. *Acta Neurochirurgica (Wien)*, *97*, 1–16.
- Saski, T., Wakasi, S., Asano, T., Watanabe, T., Kirino, T., & Sano, K. (1981). The effect of lipid hydroxperoxide of arachidonic acid on the canine basilar artery. *Journal of Neurosurgery*, *54*, 357–365.
- Stendel, R., Peitila, T., Lehman, K., Kurth, R., Suess, O., & Brock, M. (2002). Ruptured intracranial dermoid cysts. *Surgical Neurology*, *57*, 391–398.
- Sugano, H., Shimizu, H., Sunaga, S., Arai, N., & Tamagawa, K. (2006). Temporal lobe epilepsy caused by dermoid cyst. *Neurological Medico-Chirurgica*, *46*(4), 206–209.
- Wang, J., Yang, X., Camporesi, C., Yang, Z., Bosco, G., & Camporesi, E. (2002). Propofol reduces infarct size and striatal dopamine accumulation following transient middle cerebral artery occlusion: A microdialysis study. *European Journal of Pharmacology*, *452*, 303–308.
- Yurdakoc, A., Gunday, I., & Memiş, D. (2008). Effects of halothane, isoflurane, and sevoflurane on lipid peroxidation following experimental closed head trauma in rats. *Acta Anaesthesiologica Scandinavica*, *52*(5), 658–663.